

Contents lists available at [SciVerse ScienceDirect](http://SciVerse.Sciencedirect.com)

# Respiratory Medicine Case Reports

journal homepage: [www.elsevier.com/locate/rmcr](http://www.elsevier.com/locate/rmcr)

## Case report

# Pulmonary mucormycosis presenting with vocal cord paralysis

H.J. Gayathri Devi<sup>a,\*</sup>, K.N. Mohan Rao<sup>a</sup>, K.M. Prathima<sup>b</sup>, Riyaz Moideen<sup>a</sup><sup>a</sup> Department of Chest Diseases, MS Ramaiah Medical College, Bangalore – 560 054, India<sup>b</sup> Department of Pathology, MS Ramaiah Memorial Hospital, Bangalore – 560 054, India

## ARTICLE INFO

### Article history:

Received 13 January 2013

Received in revised form

10 March 2013

Accepted 12 March 2013

### Keywords:

Pulmonary mucormycosis

Vocal cord paralysis

## ABSTRACT

Pulmonary mucormycosis is a relatively uncommon infection. It can present in various forms. Very few cases of pulmonary mucormycosis presenting as vocal cord paralysis have been described in the literature. We report a case of pulmonary mucormycosis presenting as vocal cord paralysis in an uncontrolled diabetic patient.

© 2013 Elsevier Ltd. Open access under [CC BY-NC-ND license](http://creativecommons.org/licenses/by-nc-nd/3.0/).

## 1. Introduction

Pulmonary mucormycosis is an opportunistic infection occurring in immunocompromised conditions. Pulmonary mucormycosis can present as solitary nodule, pneumonia, cavitary lesion or in disseminated form. Endobronchial mucormycosis presenting as vocal cord paralysis has been reported earlier.<sup>1</sup> We report a case of pulmonary mucormycosis presenting with hoarseness due to vocal cord palsy.

## 2. Case report

A 52-year male patient presented with fever and cough of 1 month duration. He also had hoarseness of voice and haemoptysis of 2 weeks duration. Known case of uncontrolled Diabetes on oral hypoglycemic drugs from a general practitioner. He was a chronic smoker with 20 pack years. There was no history of tuberculosis in the past. He was treated with broad spectrum antibiotics elsewhere before presenting to our hospital.

On examination, his vitals were stable. He had slightly decreased air entry in the left infrascapular region. Cardiovascular examination and Abdomen was normal. His blood investigations revealed anaemia, leucocytosis and raised erythrocyte sedimentation rate. His Haemoglobin A1c was 9.3. Sputum for Acid fast bacilli, Fungal elements and malignant cells were negative. His HIV status was negative.

Chest x-ray revealed left perihilar opacity and left lower zone opacity suggestive of consolidation [Fig. 1]. CT scan of the Thorax

showed peribronchial lesion on left side with considerable narrowing of the left main bronchus with infiltrates in the lower lobe [Fig. 2]. Fiberoptic video laryngoscopy showed left vocal cord palsy. Mucosa appeared normal without any lesions. MRI of the Neck was done to look for local lesion for vocal cord paralysis and it was normal. Bronchoscopy was done with a presumptive diagnosis of bronchogenic carcinoma. Bronchoscopy revealed left vocal cord paralysis and extrinsic narrowing of the left main bronchus. However scope could be passed beyond the narrowing. There was mucosal thickening at the secondary carina. Transbronchial biopsy was taken from the left lower lobe bronchus which showed considerable narrowing as shown in the image [Fig. 3]. Histopathology examination revealed fungal hyphae in the subepithelial tissue suggestive of mucormycosis [Fig. 4A and B].

He was started on lipid complex Amphotericin B instead of liposomal amphotericin because of financial constraints. His renal status and electrolytes were closely monitored while on treatment. He was discharged at request after 2 weeks of treatment.

Subsequent follow up CT of the Thorax revealed considerable reduction in the size of the left perihilar opacity [Fig. 5]. There was no mediastinal or hilar lymphadenopathy. He was advised repeat bronchoscopy, which he declined.

## 3. Discussion

Mucormycosis term refers to infections caused by fungi of the order Mucorales.<sup>2</sup> These are opportunistic infections seen in immunocompromised conditions like Diabetes Mellitus, stem cell transplant patients, haematological malignancy and solid organ transplant patients.<sup>3</sup> Pulmonary mucormycosis is the second most common form of mucormycosis, first being Rhinocerebral form.<sup>4</sup>

\* Corresponding author. Tel.: +91 9916195235 (Mobile).

E-mail address: [gayathrijoshyev@gmail.com](mailto:gayathrijoshyev@gmail.com) (H.J. Gayathri Devi).

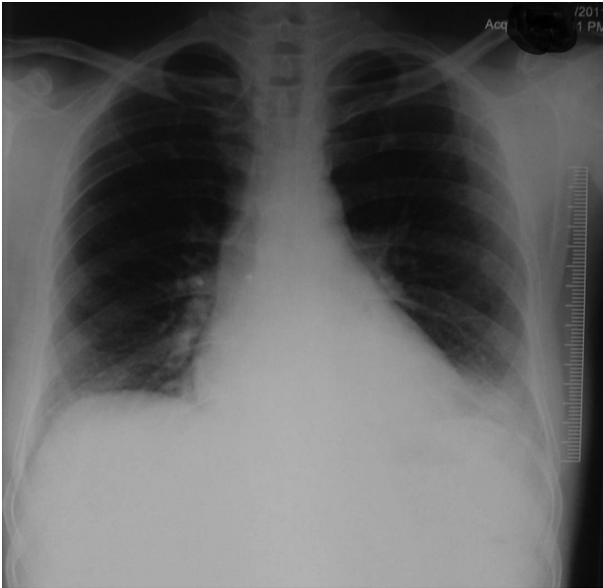


Fig. 1. Chest X-ray PA showing left perihilar and lower zone opacity.

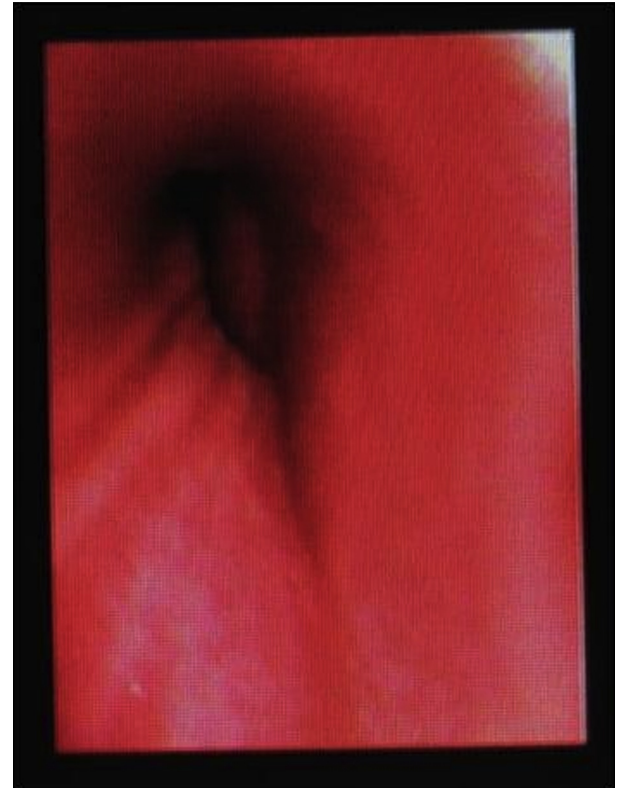


Fig. 3. Bronchoscopy showing narrowing of left lower lobe bronchus.

Cutaneous, gastrointestinal and disseminated forms of manifestations are also seen.<sup>5</sup>

Pulmonary mucormycosis is a relatively uncommon opportunistic fungal infection with high mortality rate. Mucormycosis is reported most commonly in diabetic patients.<sup>6</sup> Diwaker A et al have done an analysis of the mucormycosis cases in India and found that uncontrolled diabetes was the most common risk factor in India.<sup>7</sup> Pulmonary mucormycosis presents with cough, haemoptysis, fever, dyspnoea and chest pain. Pulmonary mucormycosis can present as pneumonia, solitary nodule, cavitary lesion or in disseminated form. It can also present as endobronchial polypoid lesion.<sup>8</sup>

Very few cases of pulmonary mucormycosis presenting as vocal cord palsy have been described in the literature. V. Suresh et al have reported a case of recurrent laryngeal nerve palsy due to pulmonary mucormycosis.<sup>1</sup> Left vocal cord palsy in our patient is suggestive of left recurrent laryngeal nerve involvement. Left

recurrent laryngeal nerve is closely apposed to the tracheo-oesophageal groove.<sup>1</sup> Mucormycosis has angioinvasive properties which can cause thrombosis leading to necrosis of the tissue. Invasion of the bronchial wall in the histopathology image is suggestive of the possibility of involvement of the recurrent laryngeal nerve by the necrotizing lesion due to mucormycosis.

Therapy involves systemic antifungal therapy, surgical resection and control of the underlying disease whenever possible.<sup>9</sup> Amphotericin B Deoxycholate is the only licenced agent for

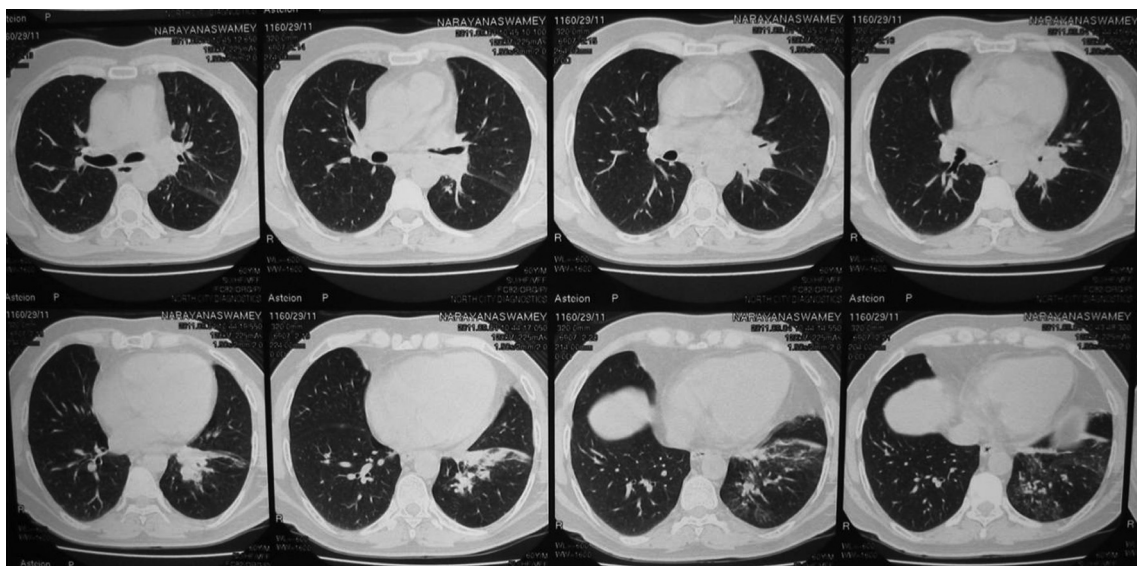


Fig. 2. CT Thorax showing peribronchial lesion on left side with considerable narrowing of the left main bronchus with infiltrates in the lower lobe.

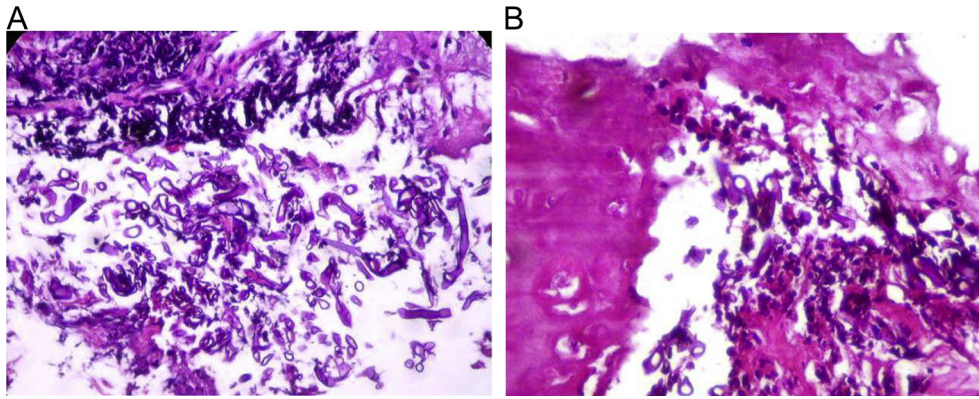


Fig. 4. Photomicrograph showing broad non-septate non-branching hyphae suggestive of mucormycosis, (PAS, 400 $\times$ ).

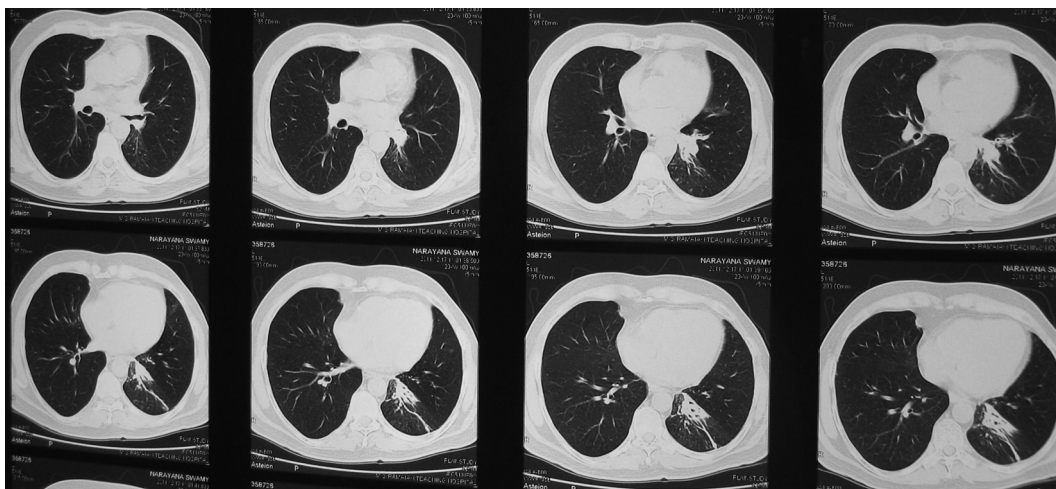

Fig. 5. CT Thorax post-treatment showing reduction in the peribronchial lesion.

treating mucormycosis. Lipid formulations of Amphotericin B are Amphotericin B lipid complex and liposomal Amphotericin B which are less nephrotoxic and safer to use. Posaconazole is useful as salvage therapy. Antifungal therapy should be given until there is clinical and radiological evidence of resolution of infection.<sup>4</sup> Prompt and effective therapy are essential for a successful outcome.

#### 4. Conclusion

In conclusion, it is important to consider unusual manifestations of mucormycosis for an early diagnosis in immunocompromised conditions.

Early diagnosis and prompt institution of appropriate antifungal treatment can bring down the mortality due to mucormycosis.

#### Source of support

None.

#### Conflict of interest

None.

#### Acknowledgement

The authors are thankful to Dr. Anjali Rao and Radiology Department, MS Ramaiah Medical College, Bangalore - 560 054, India.

#### References

- Suresh V, Bhansali A, Sridhar C, Dash RJ. Pulmonary mucormycosis presenting with recurrent laryngeal nerve palsy. *J Assoc Physicians India* 2003 Sep; **51**:912–3.
- Bigby TD, Serota ML, Tierney LM, Matthay MA. Clinical spectrum of pulmonary mucormycosis. *Chest* 1986; **89**:420–3.
- Sharma A, Gupta V, Singh RS, Kakkar N, Singh S, Bamberg P. Angioinvasive pulmonary mucormycosis presenting as multiple bilateral pulmonary nodules in a patient without obvious predisposing factors. *Singapore Med J* 2008 Oct; **49**(10):e269–71.
- Spellberg Brad, Walsh Thomas J, Kontoyiannis Dimitrios P, Edwards Jr John, Ibrahim Ashraf S. Recent advances in the management of mucormycosis: from bench to bedside. *Clin Infect Dis* 2009 June 15; **48**(12):1743–51.
- Miladipour A, Ghanei E, Nasrollahi A, Moghaddasi H. Successful treatment of mucormycosis after kidney transplantation. *Iranian J Kidney Dis* 2008; **2**(3):163–6.
- Pak Jane, Tucci Veronica T, Vincent Albert L, Sandin Ramon L, Greene John N. Mucormycosis in immunochallenged patients. *J Emerg Trauma Shock* 2008 Jul–Dec; **1**(2):106–13.
- Diwakar Amit, Dewan RK, Chowdhary Anuradha, Randhawa HS, Khanna Geetika, Gaur SN. Zygomycosis—a case report and overview of the disease in India. *Mycoses* 2007 July; **50**(4):247–54.
- Fishman's pulmonary diseases and disorders*. 4 ed. McGraw-Hill Professional; April 15, 2008:2318–9.
- Lee FYW, Mossad SB, Adal KA. Pulmonary mucormycosis: the last 30 years. *Arch Inter Med* 1999; **159**:1301–9.