



A case of small bowel mesenteric pneumatosis: A multidisciplinary approach to clinical interpretation and intervention



Christopher Johnstone^{a,*}, Tamir Salih^b, Arin Saha^b

^a St. James Hospital, Leeds, United Kingdom

^b Huddersfield Royal Infirmary, Huddersfield, United Kingdom

ARTICLE INFO

Article history:

Received 28 January 2016

Received in revised form 18 March 2016

Accepted 25 March 2016

Available online 1 April 2016

Keywords:

Case report

Mesenteric pneumatosis

Diagnostic laparoscopy

Multi-disciplinary team

ABSTRACT

INTRODUCTION: Pneumatosis of the small bowel mesentery is rare and the preserve of case reports. This case report describes the importance of a multi-disciplinary team (MDT) approach to rare pathologies.

CASE REPORT: A 78-year-old man presented to our unit with a two-day history of upper abdominal pain associated with nausea and intermittent vomiting. An urgent computed tomography (CT) scan was organised. The scan was grossly abnormal and difficult to interpret; it was reported as widespread intra-mural gas within the small bowel wall most likely secondary to extensive small bowel ischaemia. Although surgical intervention was very high risk (predicted P-possum mortality of over 60%) and there was a strong possibility that the patient would not recover from surgery, the disparity between clinical and radiological findings meant that a diagnostic laparoscopy was indicated. A diagnostic laparoscopy showed that the small bowel itself was normal but there was extensive gas within the mesentery, caused by a band adhesion which had eroded into the peritoneal layer of the small bowel mesentery.

DISCUSSION: Pneumatosis of the small bowel mesentery is a pathological sign rather than a diagnosis and is characterised by gas within the mesenteric sleeves. It is likely associated with significant morbidity and therefore rarely observed as the majority with this sign would not be deemed suitable for surgical intervention.

CONCLUSION: The case highlights an unusual pathology, rare imaging findings, the importance of a multi-disciplinary approach and the value of clear communication and informed consent when considering major intervention or surgery.

© 2016 The Authors. Published by Elsevier Ltd on behalf of IJS Publishing Group Ltd. This is an open access article under the CC BY-NC-ND license (<http://creativecommons.org/licenses/by-nc-nd/4.0/>).

1. Introduction

Pneumatosis of the small bowel mesentery is rare and the preserve of case reports within the surgical literature. This paper describes this condition and the difficulties associated with pre-operative diagnosis. Further, the case demonstrates the challenges associated with decision-making, informed consent and the importance of an MDT approach to rare pathologies.

1.1. Presentation of Case

A 78-year-old male presented acutely to our general surgery department with a two-day history of colicky upper abdominal pain that radiates to the back and which had begun to resolve at the time of admission. The patient felt nauseated with associated intermittent vomiting.

The patient had many co-morbid conditions which included end-stage chronic obstructive pulmonary disease for which he

required home oxygen, severe mitral regurgitation, atrial fibrillation for which he was on warfarin and a limited exercise tolerance of 25 yards.

An initial venous and arterial blood investigation along with a plain abdominal radiograph was normal but given the presenting history, an urgent computed tomography (CT) scan was organised. The scan was grossly abnormal ([Fig. 1](#)) and difficult to interpret. Inter-disciplinary consult with the gastrointestinal radiologist reported a widespread intramural and mesenteric gas pattern likely secondary to extensive small bowel ischaemia. Owing to his co-morbid conditions the CT findings if correct presented a diagnosis of a terminal illness. However, on review his pain had settled and the clinical condition of the patient was not in keeping with a diagnosis of bowel ischaemia. A discussion followed between the surgical team, anaesthetists, patient and his family.

Given the co-morbid conditions of this patient, surgical intervention was high risk with a predicted P-possum mortality of over 60%. If he was to require a laparotomy for small bowel resection it would be unlikely that he would survive this level of intervention. However, given the disparity between clinical and radiological findings it was considered in his best interests to perform a diagnostic

* Corresponding author at: St. James Hospital, Leeds, United Kingdom.

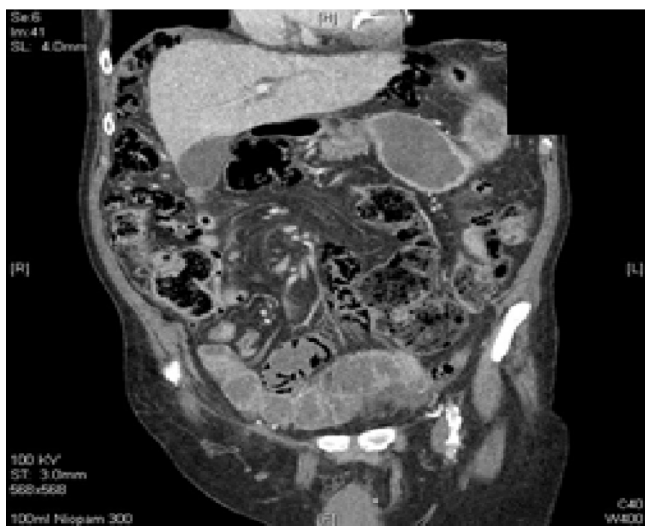

Fig. 1. CT imaging reveals gross mesenteric air.

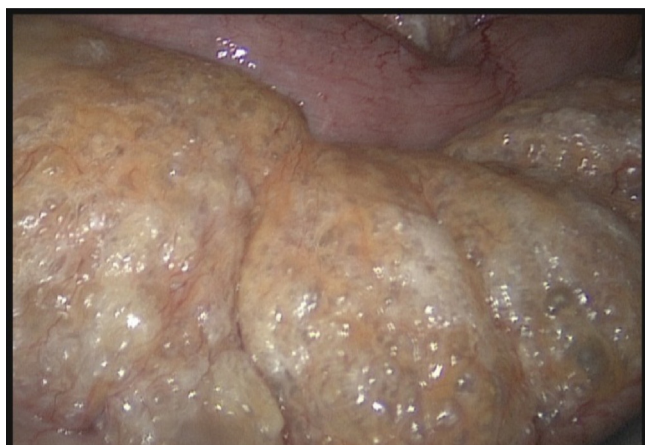

Fig. 2. Small bowel mesentery showing extensive gas infiltration.

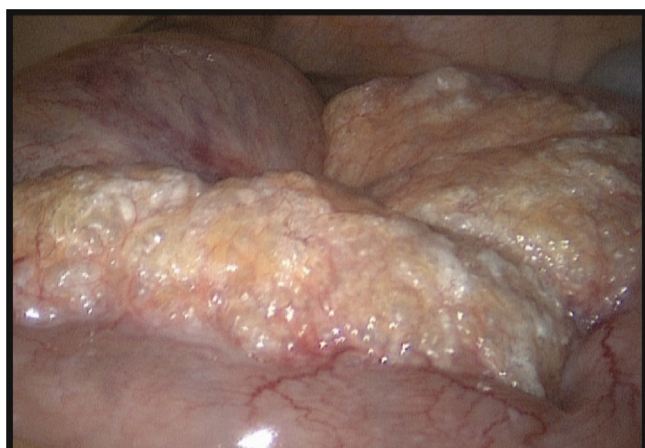

Fig. 3. Viable small bowel.

laparoscopy to identify the extent of any pathology. The patient made an informed decision to proceed with this.

A diagnostic laparoscopy showed that the small bowel itself was normal but there was extensive gas within the mesentery (Figs. 2 and 3), caused by a band adhesion which had eroded into the peritoneal layer of the small bowel mesentery (Fig. 4). This was

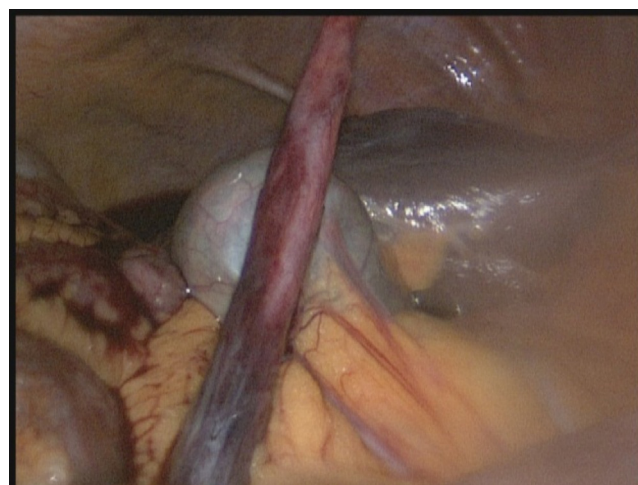


Fig. 4. Band adhesion visible.

causing imminent obstruction of the small bowel but had not yet resulted in small bowel ischaemia. This mesenteric gas accounted for the amount of air seen on the CT. The band adhesion was divided and the small bowel carefully checked. A subsequent laparotomy or bowel resection was not required.

Day 1 post operatively he was mobilising and drinking clear fluids. Over the proceeding 48 h he was eating and had opened his bowels. His blood tests remained unremarkable besides a rise in CRP secondary to laparoscopic intervention which began to fall at day 3 post-op. He was closely monitored on the ward and had physiotherapy to prevent atelectasis. he was discharged at day 5 post-op and reviewed in clinic at 6 weeks with no concerns raised.

2. Discussion

Pneumatosis is defined as the presence of air or gas in an abnormal location within the body.

Pneumatosis of the bowel wall and/or its mesentery can occur in adults and children. A high mortality rate is observed within the paediatric group as the majority of cases are secondary to necrotising enterocolitis [1].

The incidence of mesenteric pneumatosis in adults is difficult to ascertain as the majority of cases are of a benign nature and do not come to clinical attention such as those in association with COPD [2]. Those that are identified by imaging are either incidental or will have significant abdominal pathology such as perforation or ischaemia.

The mechanical theory of pneumatosis provides two hypotheses for the findings in this case.

Firstly, it could be of an incidental nature secondary to end-stage COPD. Alveolar rupture can lead to peri-vascular gas tracking towards the mediastinum which progresses through the diaphragm and to the mesenteric root [3]. However, the absence of mediastinal gas on CT would oppose this. Secondly, pneumatosis has an association with bowel obstruction which is in keeping with the patient's initial clinical presentation. Increased intraluminal pressure can lead to disruption of the mucosal integrity and allow subsequent gas tracking into the sub-mucosa and mesenteric sleeve [4]. This finding has been reproduced experimentally in cadaveric specimens by injecting air into colonic segments in which mucosal incisions have been made [5]. Pneumatosis of the gastrointestinal tract can also be observed with carbon dioxide insufflation at the time of laparoscopic induction [6]. This was not the underlying cause in this case as CT had confirmed its presence prior to laparoscopy.

The decision to perform a laparoscopy was particularly challenging given his co-morbid state and the CT interpretation. It was also taken into account that when performing acute laparoscopy, there is a significant chance the patient will require conversion to laparotomy if the pathology indicates. Ultimately in the case of this patient, the decision to laparoscope was of a diagnostic nature with minimal intervention if required as his clinical condition was in stark contrast to his imaging. If life threatening pathology such as infarction was to be identified, then the option to convert to an open procedure would not have been taken given the quality of life associated with his co-morbid state and his P-Poosum mortality prediction.

Multiple factors led to a successful outcome in this case. The patient's clinical presentation initially was stable with his pain and vomiting settling. Primary blood tests were reassuring with a blood lactate, renal function and markers of infection within normal parameters. There was a clear understanding regarding the extent of potential intervention which enabled a timely course to theatre. Finally, the patient was determined and engaged post operatively with our requests for mobilisation and oral intake and he fully adhered to his physiotherapy.

3. Conclusion

This case demonstrates the importance of clinical judgement and how a clinician's experience can bring clarity to a particularly challenging situation. The use of adjunct investigations is vital when creating a clinical picture but as portrayed here they can sometimes contradict existing information. In times of disparity, it is advocated that a clinician adheres to his overall judgement and not be bound by the results of investigations.

The case highlights an unusual pathology, rare imaging findings, the importance of a multi-disciplinary approach and the value of clear communication and informed consent when considering major intervention or surgery.

Conflicts of interest

None.

Funding

None.

Ethical Approval

None.

Consent

We have a written consent form.

Author contribution

All authors contributed to the writing of this paper. Dr. C. Johnstone was the primary author.

Guarantor

Dr. C. Johnstone.

References

- [1] J. Neu, Necrotizing enterocolitis: the search for a unifying pathogenic theory leading to prevention, *Pediatr. Clin. North Am.* 43 (1996) 409.
- [2] Y. Heng, M.D. Schuffler, R.C. Haggitt, C.A. Rohrmann, Pneumatosis intestinalis: a review, *Am. J. Gastroenterol.* 90 (1995) 1747.
- [3] W.S. Keyting, R.R. McCarver, J.L. Kovarik, A.L. Daywitt, Pneumatosis intestinalis: a new concept, *Radiology* 76 (1961) 733.
- [4] A.S. Pieterse, A.S. Leong, R. Rowland, The mucosal changes and pathogenesis of pneumatosis cystoides intestinalis, *Hum. Pathol.* 16 (1985) 683.
- [5] J.J. Kay-Butler, Interstitial emphysema of the caecum, *Gut* 3 (1962) 267.
- [6] L.Y. Kernagis, M.S. Levine, J.E. Jacobs, Pneumatosis intestinalis in patients with ischemia: correlation of CT findings with viability of the bowel, *AJR Am. J. Roentgenol.* 180 (2003) 733.

Open Access

This article is published Open Access at sciendoirect.com. It is distributed under the [IJSCR Supplemental terms and conditions](#), which permits unrestricted non commercial use, distribution, and reproduction in any medium, provided the original authors and source are credited.