

# Noninvasive Assessment of Coronary Flow Velocity and Coronary Flow Velocity Reserve in the Left Anterior Descending Coronary Artery by Doppler Echocardiography

## Comparison With Invasive Technique

TAKESHI HOZUMI, MD, KIYOSHI YOSHIDA, MD, FACC, TAKASHI AKASAKA, MD, YOSHIO ASAMI, MD, YUMIKO OGATA, MD, TSUTOMU TAKAGI, MD, SHUICHIRO KAJI, MD, TAKAHIRO KAWAMOTO, MD, YOSHIAKI UEDA, MD, SHIGEFUMI MORIOKA, MD

Kobe, Japan

**Objectives.** The purpose of this study was to evaluate whether transthoracic Doppler echocardiography (TTDE) can reliably measure coronary flow velocity (CFV) and coronary flow velocity reserve (CFVR) in the left anterior descending coronary artery (LAD) in the clinical setting.

**Background.** Coronary flow velocity measurement has provided useful clinical and physiologic information. Advancement in TTDE provides noninvasive measurement of CFV and CFVR in the distal LAD.

**Methods.** In 23 patients, CFV in the distal LAD was measured by TTDE (5 or 3.5 MHz) under the guidance of color Doppler flow mapping at the time of Doppler guide wire (DGW) examination. Coronary flow velocity in the distal LAD were measured at baseline and hyperemic conditions (intravenous administration of adenosine 0.14 mg/kg/min) by both TTDE and DGW techniques. Coronary flow velocity reserve was defined as the ratio of peak hyperemic to basal averaged peak velocity in the distal LAD.

**Results.** Clear envelopes of basal and hyperemic CFV in the distal LAD were obtained in 18 (78%) of 23 study patients by TTDE. There were excellent correlations between TTDE and DGW methods for the measurements of CFV (averaged peak velocity:  $r = 0.97$ ,  $y = 0.94x + 0.40$ ; averaged diastolic peak velocity:  $r = 0.97$ ,  $y = 0.94x + 0.69$ ; systolic peak velocities:  $r = 0.97$ ,  $y = 0.91x + 0.87$ ; diastolic peak velocity:  $r = 0.98$ ,  $y = 0.95x + 1.10$ ). Coronary flow velocity reserve from TTDE correlated highly with those from DGW examinations ( $r = 0.94$ ,  $y = 0.95x + 0.21$ ).

**Conclusions.** Noninvasive measurement of CFV and CFVR in the distal LAD using TTDE accurately reflects invasive measurement of CFV and CFVR by DGW method.

(J Am Coll Cardiol 1998;32:1251-9)

©1998 by the American College of Cardiology

Coronary flow velocity (CFV) and coronary flow velocity reserve (CFVR) measurements have provided useful clinical and physiologic information (1-6). They have been assessed by invasive or semiinvasive Doppler technique with a Doppler catheter (7-15), a Doppler guide wire (DGW) (16-27), an epicardial probe (28-32) and a transesophageal probe (33-35).

Transthoracic Doppler echocardiography (TTDE) is noninvasive, relatively inexpensive and widely used in the clinical setting. Several studies have reported that CFV in the left anterior descending coronary artery (LAD) can be measured using transthoracic two-dimensional and Doppler echocardiography with a high-frequency transducer (36-42). A recent study has shown CFV and CFVR in the distal LAD can be

measured by TTDE under the guidance of color Doppler flow mapping (43). If CFV and CFVR can be reliably measured by this noninvasive method, it would provide useful clinical information. To our knowledge, however, CFV and CFVR measurements in the distal LAD by TTDE have not been validated with other established methods in the clinical setting (44). Therefore, we designed this study to evaluate whether TTDE can reliably measure CFV and CFVR in the distal LAD.

## Methods

**Study patients.** We examined 23 consecutive patients (12 men and 11 women; mean age  $63 \pm 7$  years) in whom CFV in the distal LAD was measured by a DGW at the time of coronary angiographic study. Exclusion criteria were as follows: acute myocardial infarction, unstable angina, atrial fibrillation, second-degree atrioventricular block, severe chronic obstructive pulmonary disease or bronchospasm. All patients underwent TTDE at the time of DGW examination. Thirteen

From the Division of Cardiology, Kobe General Hospital, Kobe, Japan.

Manuscript received March 27, 1998; revised manuscript received June 25, 1998, accepted July 15, 1998.

Address for correspondence: Dr. Takeshi Hozumi, Division of Cardiology, Kobe General Hospital, 4-6 Minatogima-nakamachi, Chuo-ku, Kobe 650, Japan. E-mail: [jse@warp.or.jp](mailto:jse@warp.or.jp).

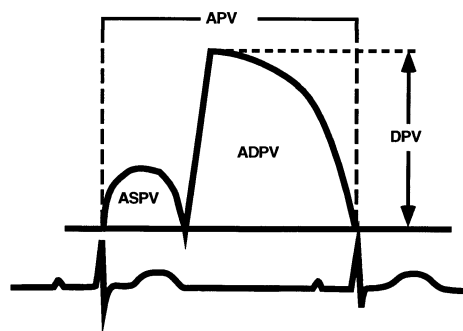
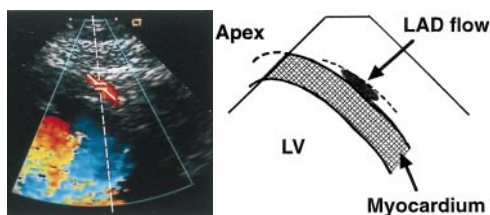
**Abbreviations and Acronyms**

ADPV	=	averaged diastolic peak velocity
APV	=	averaged peak velocity
ASPV	=	averaged systolic peak velocity
CFV	=	coronary flow velocity
CFVR	=	coronary flow velocity reserve
DGW	=	Doppler guide wire
DPV	=	diastolic peak velocity
LAD	=	left anterior descending coronary artery
TTDE	=	transthoracic Doppler echocardiography

patients had coronary artery disease (six patients with stenosis in the proximal LAD, the remainder with angiographically normal LAD), nine patients had valvular heart disease (four patients with aortic regurgitation, three with mitral regurgitation, one with mitral stenosis, one with aortic stenosis) and one had dilated cardiomyopathy. All participants gave informed consent to the protocol approved by the Committee for the Protection of Human Subjects in Research at Kobe General Hospital.

**TTDE.** The TTDE examinations were performed with a digital ultrasound system (Acuson; Sequoia, Mountain View, California) with a frequency of 5.0 or 3.5 MHz (Doppler frequency, 5.0 or 3.5 MHz). In color Doppler flow mapping, velocity range was set in the range of  $\pm 8.9$  to  $\pm 24.0$  cm/s. The color gain was adjusted to provide the optimal images. Acoustic window was around the midclavicular line in the fourth and fifth intercostal spaces in the left lateral decubitus position. The ultrasound beam was transmitted toward the heart to visualize coronary blood flow in the distal portion of the LAD by color Doppler flow mapping. First, the left ventricle was imaged in the long-axis cross-section; then the ultrasound beam was inclined laterally. Next, coronary blood flow in the distal LAD was searched under the guidance of color Doppler flow mapping (Fig. 1). Positioning a sample volume (2.0, 2.5 or 3.0 mm wide) on the color signal in the distal LAD, Doppler spectral tracings of flow velocity were recorded by fast Fourier transformation analysis. Although we tried to align ultrasound beam direction to distal LAD flow as parallel as possible, angle correction was needed in each examination because of incident Doppler angle (mean angle  $39^\circ$ , ranged from  $30^\circ$  to  $54^\circ$ ). The spectral Doppler of the LAD flow showed a characteristic biphasic flow pattern with a larger diastolic component and a

**Figure 1.** TTDE (left) and schematic representation (right) showing coronary blood flow (arrow) in the distal LAD. LV = left ventricle.



**Figure 2.** Measurements of variables of CFV recording. See text for abbreviations in remaining legends.

small systolic one. All studies were recorded on 0.5-in. s-VHS videotape for off-line analysis.

**CFV and CFVR measurements by TTDE.** Spectral Doppler signal recordings by TTDE were obtained during DGW examination. We first recorded baseline spectral Doppler signals in the distal LAD over five cardiac cycles at end-expiration by TTDE immediately after recording them by the DGW method. Intravenous adenosine was administered (0.14 mg/kg/min) to obtain spectral Doppler signals during peak hyperemic conditions. Immediately after Doppler signal recording during peak hyperemia using a DGW, they were recorded by TTDE over five cardiac cycles at end-expiration. A 12-lead surface electrocardiogram (ECG) and pressure waveform at the tip of the guiding catheter inserted into the left main coronary artery were monitored continuously.

Each study was analyzed by an experienced investigator who was unaware of the other patient data. Measurements were performed off-line by tracing the contour of the spectral Doppler signal using the computer incorporated in the ultrasound system. Averaged peak velocities (APV), averaged diastolic peak velocities (ADPV), averaged systolic peak velocities (ASPV), diastolic peak velocities (DPV) at baseline, and peak hyperemic conditions were measured from the Doppler signal recordings (Fig. 2). Measurements were averaged over three cardiac cycles. Coronary flow velocity reserve was assessed as the ratio of peak hyperemic to basal APV.

**Coronary angiography.** Coronary angiography was performed by the Judkins technique after intravenous injection of 4,000 IU of heparin. Coronary stenosis was evaluated using multiple projections by an experienced investigator unaware of the other data. Quantitative analysis was done using a MEDIS (medical imaging systems) CMS analysis software (45-47).

**DGW examinations.** After routine cardiac catheterization, coronary angiography and additional intravenous injection of 2,000 IU of heparin, a DGW was advanced into the LAD through a 5-F coronary angiography catheter (Selecon; Clinical Supply, Inc., Gifu, Japan). The DGW used in the present study was 0.014 in. (0.36 mm), 175 cm long, flexible and steerable, with a 15-MHz piezoelectric ultrasound transducer integrated on the tip (Flowire; Cardiometrics, Inc., Mountain View, California). The ultrasound beam diverges at  $28^\circ$  from

the transducer, and the sample volume was positioned at a distance of 4.2 mm from the transducer. The tip of the DGW was advanced to the distal portion of the LAD. An optimal Doppler signal was obtained by moving the guide wire slightly within the vessel lumen and adjusting the range gate control. We confirmed the position of the tip of the DGW under fluoroscopic monitoring and tried to set the tip of the DGW at the same site of the sample volume at end-expiratory phase in TTDE. Biphasic flow pattern with a larger diastolic component and a small systolic one was recorded with the use of the DGW and a velocimeter (FloMap; Cardiometrics, Inc.). During DGW study, a 12-lead surface ECG and pressure waveform at the tip of the guiding catheter were monitored continuously. All studies were recorded on 0.5-in. s-VHS videotape for off-line analysis.

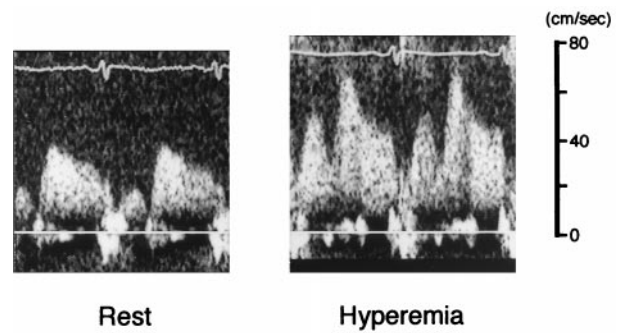
**CFV and CFVR measurements by the DGW.** After Doppler signals were recorded in the distal LAD at baseline condition, they were recorded to obtain the maximal velocity during hyperemic conditions after the intravenous administration of adenosine (0.14 mg/kg/min). Averaged peak velocity, ADPV, ASPV and DPV at baseline and peak hyperemic conditions were measured from the Doppler signal recordings by an experienced investigator who was unaware of the other patient data. Measurements were averaged over three cardiac cycles. Coronary flow velocity reserve was assessed as the ratio of peak hyperemic to basal APV.

**Analysis of CFV and CFVR data.** Data are expressed as mean value  $\pm$  SD. Linear regression analysis was used to compare TTDE with the DGW method for the assessment of APV, ADPV, ASPV, DPV and CFVR. An analysis of the differences of the measurements was performed according to the technique of Bland and Altman (48). To evaluate the effect of observational variability on the measurement of APV, ADPV, ASPV and DPV by TTDE, two independent observers analyzed 10 randomly selected Doppler velocity recordings. Each observer had no knowledge of the results of the other observer and the CFV data by the DGW method. Interobserver variability was calculated as the standard deviation of the differences between the two observers, expressed as a percent of the average value. Reproducibility was assessed in seven patients who underwent CFV measurements by TTDE twice, 10 min apart.

## Results

Clear envelopes of basal and hyperemic CFV in the distal LAD were obtained in 18 (78%) of 23 study patients by TTDE. Table 1 shows a summary of clinical characteristics and CFV and CFVR data in the 18 study patients.

**CFV data.** Figures 3 and 4 show an example of CFV recording in the distal LAD obtained from TTDE and DGW methods. There were excellent correlations between TTDE and DGW methods for the measurements of APV, ADPV, ASPV and DPV ( $r = 0.97$ ,  $y = 0.94x + 0.40$ ,  $SEE = 3.91$  cm/s;  $r = 0.97$ ,  $y = 0.94x + 0.69$ ,  $SEE = 4.20$  cm/s;  $r = 0.97$ ,  $y = 0.91x + 0.87$ ,  $SEE = 2.84$  cm/s;  $r = 0.98$ ,  $y = 0.95x + 1.10$ ,



**Figure 3.** Example of CFV recordings at rest (left) and during hyperemia (right) obtained from TTDE.

$SEE = 5.12$  cm/s, Figs. 5 to 8). For APV, ADPV, ASPV and DPV measurements, the mean differences between TTDE and DGW methods were  $-1.42 \pm 3.98$  cm/s,  $-1.59 \pm 4.31$  cm/s,  $-0.87 \pm 3.01$  cm/s and  $-1.72 \pm 5.21$  cm/s, respectively (Figs. 5 to 8).

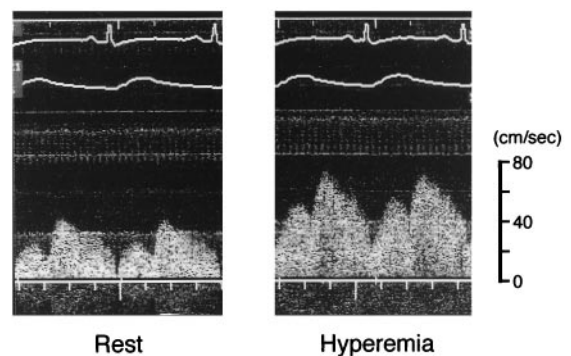
**Interobserver variability and reproducibility.** There was a good agreement between the two independent observers' measurements for APV, ADPV, ASPV and DPV ( $r = 0.99$ ,  $r = 0.99$ ,  $r = 0.99$  and  $r = 0.99$ ). Interobserver variabilities for APV, ADPV, ASPV and DPV were 4.2%, 3.9%, 4.5% and 4.9%, respectively. Reproducibility for APV, ADPV, ASPV and DPV were 6.5%, 6.3%, 6.8% and 6.9%, respectively.

**CFVR data.** Coronary flow velocity reserve obtained from TTDE correlated highly with those from DGW examinations ( $r = 0.94$ ,  $y = 0.95x + 0.21$ ,  $SEE = 0.18$ , Fig. 9). The mean difference between DGW and TTDE methods was  $0.10 \pm 0.18$  for CFVR measurements (Fig. 9).

## Discussion

In the present study, we evaluated the reliability of CFV and CFVR measurements in the distal LAD obtained from TTDE, and demonstrated both CFV and CFVR measured by this noninvasive method correlated highly with those by the

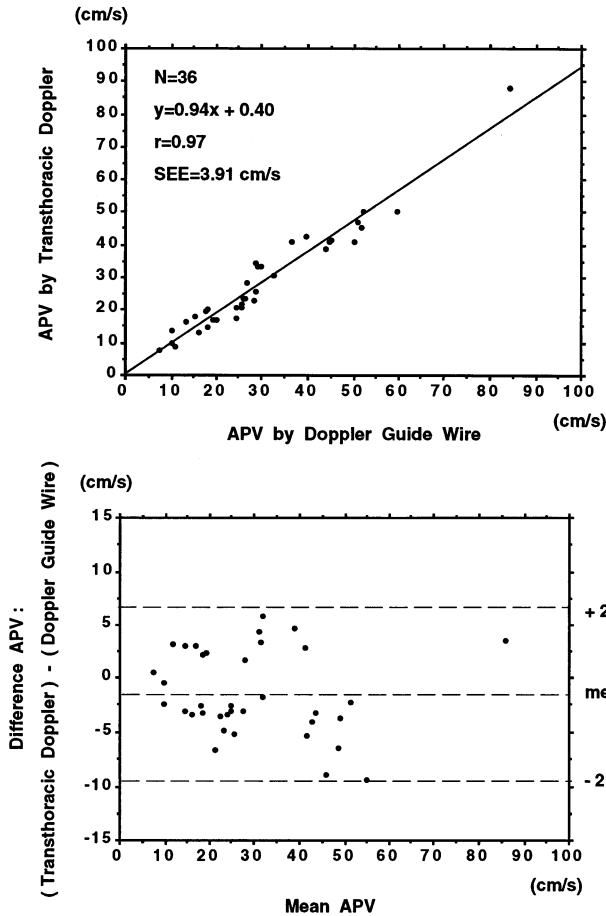
**Figure 4.** Example of CFV recordings at rest (left) and during hyperemia (right) obtained from a DGW in the same patient in Figure 3.



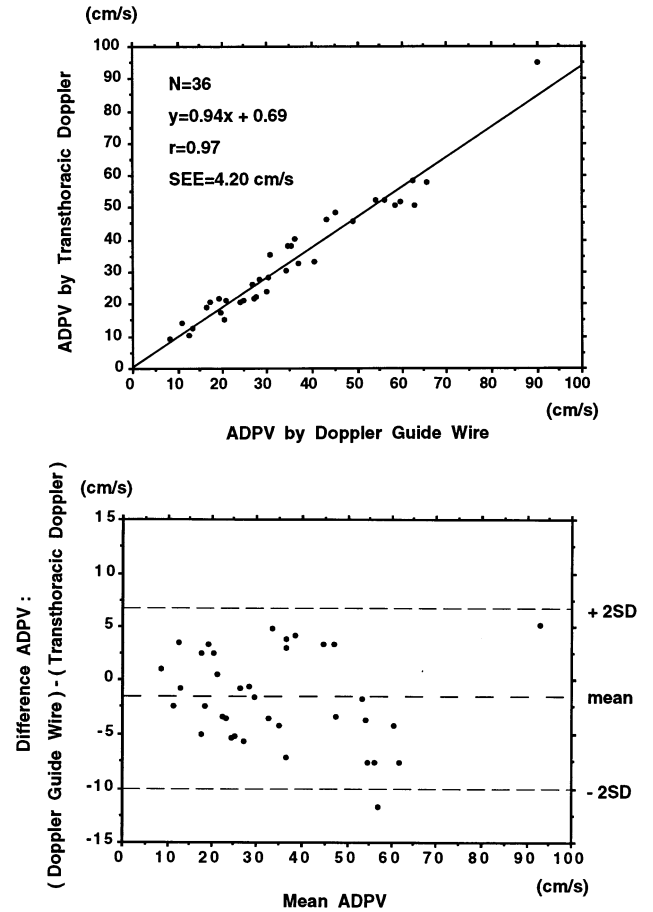
**Table 1.** Clinical Characteristics and Coronary Flow Velocity Data

No.	Age (yr)	Sex	Clinical Diagnosis	LAD Stenosis	Stenotic Site: % Diameter Stenosis	Baseline Condition								Hyperemic Condition								CFVR	
						APV (cm/s)		ADPV (cm/s)		ASPV (cm/s)		DPV (cm/s)		APV (cm/s)		ADPV (cm/s)		ASPV (cm/s)		DPV (cm/s)			
						TTDE	DGW	TTDE	DGW	TTDE	DGW	TTDE	DGW	TTDE	DGW	TTDE	DGW	TTDE	DGW	TTDE	DGW	TTDE	DGW
1	70	M	AR	–		23.0	28.2	24.3	29.9	18.9	23.0	47.8	56.2	50.2	59.7	52.1	59.8	47.3	55.3	88.2	96.1	2.18	2.12
2	54	F	Inferior MI	–		13.5	10.3	14.3	10.8	10.2	7.6	23.6	20.3	33.2	28.9	35.6	30.7	23.7	19.3	70.8	68.6	2.46	2.81
3	61	M	MR	–		13.2	16.2	15.3	20.3	8.2	9.2	22.3	24.3	45.3	51.7	50.6	58.3	32.3	35.2	77.6	83.7	3.43	3.19
4	69	M	Anterior MI	+	Proximal: 48%	16.2	13.2	19.0	16.5	8.8	7.2	23.0	21.9	34.6	28.7	38.2	34.4	19.8	18.3	48.2	45.0	2.14	2.17
5	71	F	DCM	–		19.7	17.5	21.4	20.8	17.0	16.0	30.7	29.1	41.2	36.5	46.4	43.0	34.5	32.3	58.2	56.8	2.09	2.09
6	54	M	Inferior MI	–		17.7	24.3	21.8	27.1	8.1	12.2	29.7	35.7	41.2	54.0	51.0	62.7	20.7	28.2	79.8	89.3	2.33	2.07
7	64	M	AP	–		7.9	7.3	9.2	8.2	6.3	5.2	14.6	12.9	18.2	15.1	20.8	17.4	11.7	9.4	33.2	27.3	2.30	2.07
8	57	M	AR	–		20.7	24.2	22.5	27.6	15.1	17.0	40.5	47.0	30.7	32.5	32.8	37.0	22.0	25.0	57.2	63.4	1.48	1.34
9	66	F	AS	–		20.4	18.0	21.8	19.2	13.7	11.2	34.3	30.2	42.5	39.6	48.6	45.2	25.6	23.2	66.4	64.3	2.08	2.20
10	55	M	Inferior MI	+	Proximal: 43%	8.8	11.1	10.2	12.5	4.7	5.0	17.7	21.5	25.8	28.8	30.7	34.2	12.1	14.4	51.3	56.2	2.93	2.59
11	48	F	AR	–		14.5	17.9	17.3	19.7	9.8	12.2	41.5	39.9	22.1	25.4	26.1	26.8	15.6	18.8	66.8	58.0	1.52	1.42
12	59	M	MS	–		20.6	25.4	33.1	40.2	7.1	9.8	41.2	46.9	38.7	44.1	57.8	65.4	12.8	13.6	80.7	90.9	1.88	1.74
13	75	F	AP	+	Proximal: 72%	23.3	26.4	27.8	28.3	15.8	17.8	39.8	40.6	40.8	44.8	45.8	49.2	36.5	40.3	61.2	67.5	1.75	1.70
14	52	F	MR	–		33.1	29.7	40.4	36.2	18.3	16.8	55.2	50.8	87.8	84.2	95.3	90.2	40.2	35.2	129.0	120.0	2.65	2.84
15	69	F	Inferior MI	+	Proximal: 21%	23.3	25.8	28.6	30.2	16.8	16.8	39.8	43.8	50.1	52.3	52.3	54.0	47.5	48.5	78.6	82.0	2.15	2.03
16	60	F	AP	–		16.8	20.1	20.6	24.2	7.2	8.1	27.8	32.1	41.8	45.3	52.3	56.5	23.5	27.3	68.2	78.3	2.49	2.25
17	75	M	MR	–		16.8	19.4	21.3	24.9	7.3	8.2	30.2	35.1	47.2	50.9	58.3	62.5	22.5	26.6	83.1	87.7	2.81	2.62
18	67	F	AP	–		9.67	10.1	12.5	13.2	4.1	4.3	15.3	15.5	28.6	26.8	38.2	35.1	12.1	10.4	45.6	42.3	2.96	2.65
Mean	63					18.0	19.4	21.8	23.3	10.7	11.2	32.1	33.5	39.4	40.6	46.3	47.6	23.8	24.8	67.2	68.6	2.24	2.12
SD	8					6.4	6.7	8.3	8.8	4.9	4.8	11.4	11.7	16.2	16.5	17.7	18.3	11.2	11.2	22.4	23.3	0.47	0.44

ADPV = averaged diastolic peak velocity; AP = angina pectoris; APV = averaged peak velocity; AR = aortic regurgitation; AS = aortic stenosis; ASPV = averaged systolic peak velocity; CFVR = coronary flow velocity reserve; DCM = dilated cardiomyopathy; DGW = Doppler guide wire; DPV = diastolic peak velocity; F = female; LAD = left anterior descending coronary artery; M = male; MI = myocardial infarction; MR = mitral regurgitation; MS = mitral stenosis; TTD = transthoracic Doppler echocardiography.



**Figure 5.** Regression (top) and difference (bottom) plots comparing APV measured by TTDE and DGW methods.



**Figure 6.** Regression (top) and difference (bottom) plots comparing ADPV measured by TTDE and DGW methods.

DGW method, which has already been validated for the measurement of CFV.

**CFV and CFVR measurements by invasive or semiinvasive Doppler methods.** Coronary flow velocity measurements have provided useful clinical and physiologic information (1-6). They have been assessed by several Doppler techniques with a Doppler catheter (7-15), a DGW (16-27), an epicardial probe (28-32) and a transesophageal probe (33-35). Doppler catheter (7) and a DGW (17) already have been validated for the measurement of CFV and CFVR and established as useful techniques in the clinical setting. However, they are available only in the catheterization laboratories. Transesophageal Doppler echocardiography is semiinvasive, although this approach is available in echocardiographic laboratories (33-35). Thus, it has been difficult to apply assessment of CFV to patients in routine clinical practice.

**CFV and CFVR measurements by TTDE.** Transthoracic Doppler echocardiography is noninvasive, relatively inexpensive and widely used in the clinical setting, and can be used for serial studies in echocardiographic laboratories. Several studies have reported that CFV can be measured by visualizing

LAD using transthoracic two-dimensional and Doppler echocardiography with a high-frequency transducer (36-42). A recent study has shown that CFV in the distal LAD can be measured at high success rate by TTDE under the guidance of color Doppler flow mapping, and assessment of CFVR in the LAD by this noninvasive technique is useful in the diagnosis of significant LAD stenosis (43). In the clinical study, however, reliability of CFV and CFVR measurements by TTDE has not been assessed yet. Only one animal study has reported measurements of CFV and CFVR by TTDE during harmonic contrast ultrasound imaging with simultaneous DGW measurements (44). Therefore, in the present study, we compared CFV and CFVR from TTDE in the clinical setting with those from the DGW method, which has already been validated (17).

All parameters representing CFV (APV, ADPV, ASPV and DPV) measured from TTDE correlated highly with those from the DGW method. These results suggest that CFV recording in the distal LAD is reliable and available by TTDE for the analysis of CFV characteristics. Furthermore, there is an excellent correlation between the TTDE and DGW meth-

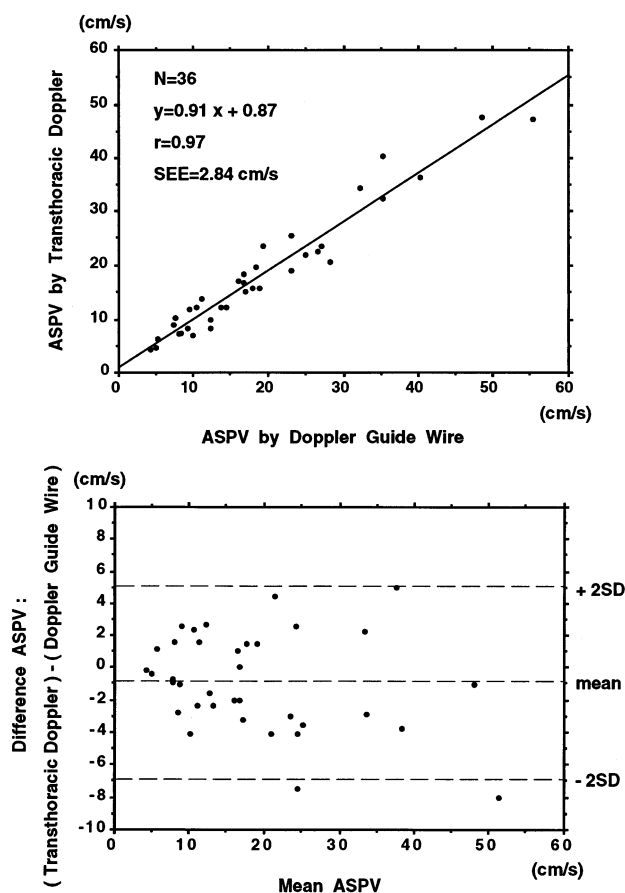


Figure 7. Regression (top) and difference (bottom) plots comparing ASPV measured by TTDE and DGW methods.

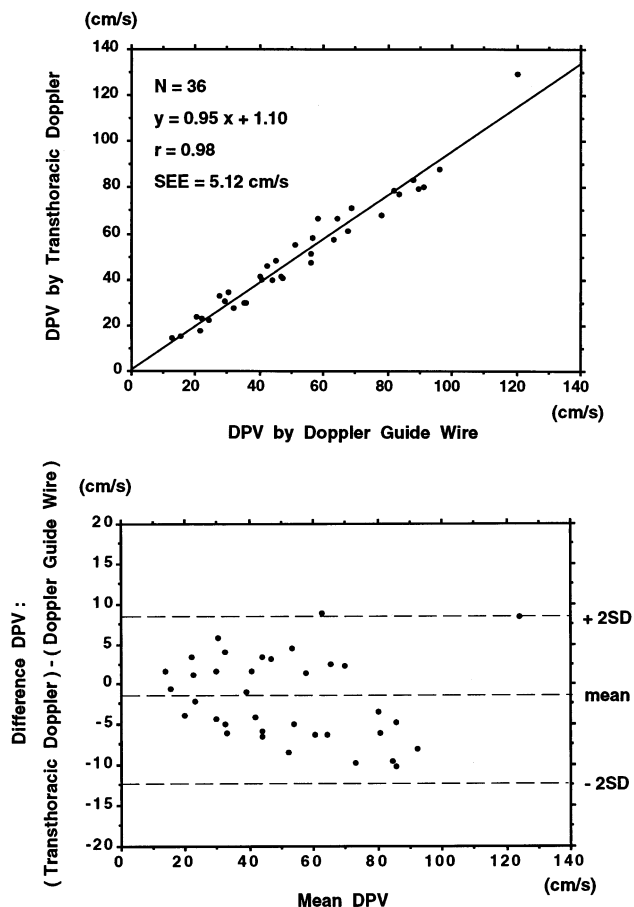


Figure 8. Regression (top) and difference (bottom) plots comparing DPV measured by TTDE and DGW methods.

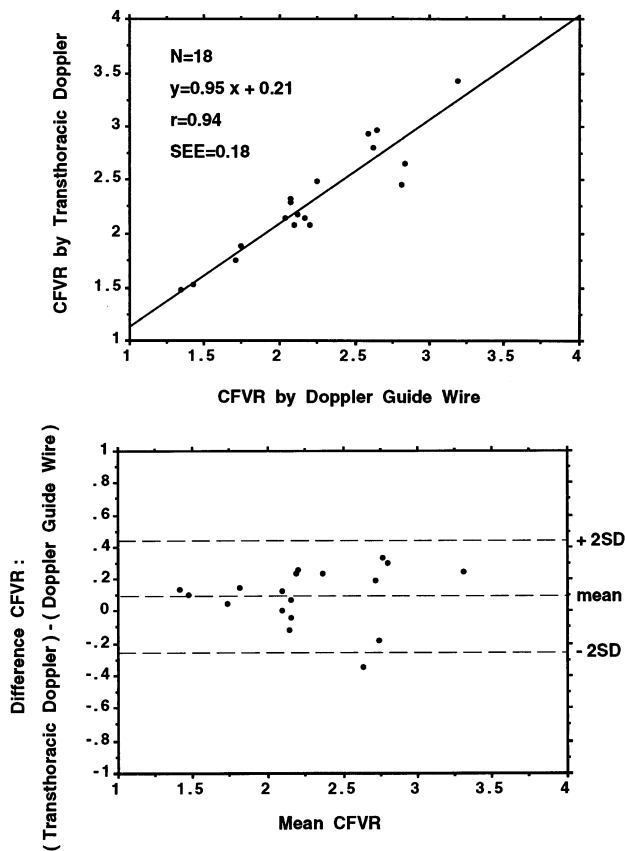
ods for CFVR measurement. This suggests that reliable non-invasive assessment of CFVR is possible in the echocardiographic laboratories.

In the present TTDE technique, success rate in the measurement of CFV in the distal LAD was high enough (78%) for the clinical application. There were several reasons for a high success rate in the present method. First, the reduction of the velocity range enhanced the visualization of the low velocity signal in the distal LAD by lowering the cut-off limit of the wall motion filter. Velocity range in conventional color Doppler flow mapping is usually set in the range from approximately  $\pm 60$  to  $\pm 70$  cm/s in routine echocardiographic examinations. On the other hand, our present method lowered the setting of the velocity range in color Doppler flow mapping ( $\pm 8.9$  to  $\pm 24.0$  cm/s). Application of this newly modified velocity range in color Doppler flow mapping provided improved visualization of coronary flow signal in the distal LAD. Second, the TTDE method under the guidance of color Doppler flow mapping facilitated the positioning of the sample volume in the distal LAD flow when compared with the previous studies, which only employed two-dimensional imaging. Finally, patients with chronic obstructive pulmonary disease

were not included in the present study, to avoid bronchospasm by intravenous infusion of adenosine. This study population may contribute to high success rate in the detection of CFV.

**Advantages of TTDE.** The present study demonstrated that CFV and CFVR in the distal LAD can be assessed reliably and noninvasively by TTDE under the guidance of color Doppler flow mapping in the clinical setting. This noninvasive method has some advantages. First, this method can be performed in an outpatient setting because TTDE is widely available in the clinical setting. Positron emission tomography provides noninvasive measurements of CFV and CFVR (49-51). However, it is an expensive and not generally available technique. Although transesophageal Doppler echocardiography can be used for CFV and CFVR measurement in echocardiographic laboratories, it is semiinvasive (33-35). At the present time, only TTDE provides noninvasive assessment of CFVR in routine clinical practice.

Second, in patients with ischemic heart disease this technique has potential in the prediction of functional significant coronary artery stenosis (33-35). A recent study has shown that CFVR in the distal LAD obtained from TTDE has high



**Figure 9.** Regression (top) and difference (bottom) plots comparing CFVR measured by TTDE and DGW methods.

sensitivity and specificity in detecting significant LAD stenosis (43).

Third, serial assessment can be performed by this technique because it is noninvasive and relatively inexpensive. It may be useful in the diagnosis of restenosis after coronary intervention, such as percutaneous transluminal coronary angioplasty or stent implantation. Furthermore, pharmacologic responses to CFV may be assessed serially by this noninvasive method.

Finally, it is possible to assess CFV or CFVR in routine clinical practice in patients with aortic stenosis (13,14,52), hypertrophic cardiomyopathy (15,53), hypertensive heart disease with left ventricular hypertrophy (54) and diabetes mellitus (25,55,56). Although characteristic CFV and CFVR have been reported in various cardiac diseases in the previous reports, they were assessed by a Doppler catheter, a DGW or positron emission tomography. Noninvasive assessment of CFV and CFVR by TTDE should be helpful in analyzing coronary flow dynamics in these conditions.

**Study limitations.** The present study has some important limitations. First, CFV and CFVR obtained from TTDE were compared with those from the DGW method. Although the DGW technique has been established for the assessment of CFV and CFVR in the clinical settings, there is a limitation in

CFV measurement by this technique. The value of the peak velocity is dependent on positioning of the wire, tortuous segments and regions with varying luminal dimensions or configurations (17). However, in the present study, we carefully positioned the tip of the guide wire to obtain a good signal of CFV and measured CFV in the distal LAD, which does not include the tortuous segment.

Second, it may be difficult to set the tip of a DGW at the exact same site as the sample volume set in TTDE, although we confirmed the location of the tip of a DGW under the guidance of fluoroscopy. Especially in patients with a stenotic lesion in the distal LAD, difference in the location of the sample point in each method may affect the CFV measurement. In the present method, however, CFV measurement by a DGW was performed distal enough to the stenotic lesion in patients with stenosis in the LAD because a DGW was advanced to the distal LAD beyond the stenotic lesion.

Third, the present study consisted of a small number of patients with each cardiac disease. However, the purpose of the present study was to evaluate the reliability of CFV and CFVR measurements by TTDE, not to evaluate the characteristics of CFV and CFVR in various cardiac diseases. The present results show excellent correlations and agreements for the measurement of CFV and CFVR between the TTDE and DGW methods. In future studies, larger numbers of patients with various cardiac diseases should be examined by the present method.

**Conclusion.** Noninvasive measurement of CFV and CFVR in the distal LAD using TTDE accurately reflects invasive measurement of CFV and CFVR by the DGW method.

We gratefully acknowledge Mr. Toshikazu Yagi, the sonographer, Mr. Junichi Yamashita, the radiological technician, for their assistance in the recording of coronary flow velocities in the present study, and the assistance of Phillip C. Yang, MD, in the preparation of the manuscript.

## References

- Gould KL, Lipscomb K, Hamilton GW. Physiologic basis for assessing critical coronary stenosis: instantaneous flow response and regional distribution during coronary hyperemia as measures of coronary flow reserve. *Am J Cardiol* 1974;33:87-94.
- Gould KL, Lipscomb K. Effects of coronary stenoses on coronary flow reserve and resistance. *Am J Cardiol* 1974;34:48-55.
- Marcus ML, Wright C, Doty D, et al. Measurements of coronary velocity and reactive hyperemia in the coronary circulation of humans. *Circ Res* 1981;49: 877-90.
- Hoffman JIE. Maximal coronary flow and the concept of coronary vascular reserve. *Circulation* 1984;70:153-9.
- Marcus ML, Wilson RF, White CW. Methods of measurement of myocardial blood flow in patients: a critical review. *Circulation* 1987;76:245-53.
- Klocke FJ. Measurements of coronary flow reserve: defining pathology versus making decisions about patient care. *Circulation* 1987;76:1183-9.
- Wilson RF, Laughlin DE, Ackell PH, et al. Transluminal subselective measurement of coronary artery blood flow velocity and vasodilator reserve in man. *Circulation* 1985;72:82-92.
- Wilson RF, White CW. Intracoronary papaverine: an ideal coronary vasodilator for studies of the coronary circulation in conscious humans. *Circulation* 1985;73:444-51.
- Wilson RF, Marcus ML, White CW. Prediction of the physiologic signifi-

- cance of coronary arterial lesions by quantitative lesion geometry in patients with limited coronary artery disease. *Circulation* 1987;75:723-32.
10. Wilson R, Wyche K, Christiansen B. Effects of adenosine on human coronary circulation. *Circulation* 1990;82:1595-606.
  11. Rossen JD, Quillen JE, Lopez AG, Stenberg RG, Talman CL, Winniford MD. Comparison of coronary vasodilation with intravenous dipyridamole and adenosine. *J Am Coll Cardiol* 1991;18:485-91.
  12. Kern MJ, Deligonul U, Tatineni S, Serota H, Aguirre F, Hilton TC. Intravenous adenosine: continuous infusion and low dose bolus administration for determination of coronary vasodilator reserve in patients with and without coronary artery disease. *J Am Coll Cardiol* 1991;18:718-29.
  13. Hongo M, Goto T, Watanabe N, et al. Relation of phasic coronary flow velocity profile to clinical and hemodynamic characteristics of patients with aortic valve disease. *Circulation* 1993;88:953-60.
  14. Yoshikawa J, Akasaka T, Yoshida K, Takagi T. Systolic coronary flow reversal and abnormal diastolic flow patterns in patients with aortic stenosis: assessment with an intracoronary Doppler catheter. *J Am Soc Echocardiogr* 1993;6:516-24.
  15. Akasaka T, Yoshikawa J, Yoshida K, et al. Phasic coronary flow characteristics in patients with hypertrophic cardiomyopathy: a study by coronary Doppler catheter. *J Am Soc Echocardiogr* 1994;7:9-19.
  16. Segal J, Kern MJ, Scott NA, et al. Alterations or phasic coronary artery flow velocity in humans during percutaneous coronary angioplasty. *J Am Coll Cardiol* 1992;20:276-86.
  17. Doucette JW, Corl D, Payne GM, et al. Validation of a Doppler guide wire for intravascular measurement of coronary artery flow velocity. *Circulation* 1992;85:1899-911.
  18. Ofili EO, Kern MJ, Lavovitz AJ, et al. Analysis of coronary blood flow velocity dynamics in angiographically normal and stenosed arteries before and after endolumen enlargement by angioplasty. *J Am Coll Cardiol* 1993;21:308-16.
  19. Miller DD, Donohue TJ, Younis LT, et al. Correlation of pharmacological <sup>99m</sup>Tc-Sestamibi myocardial perfusion imaging with poststenotic coronary flow reserve in patients with angiographically intermediate coronary artery stenoses. *Circulation* 1994;89:2150-60.
  20. Joye JD, Schulman DS, Lasorda D, Farah T, Donohue BC, Reichel N. Intracoronary Doppler guide wire versus stress single-photon emission computed tomographic Thallium-201 imaging in assessment of intermediate coronary stenoses. *J Am Coll Cardiol* 1994;24:940-7.
  21. Akasaka T, Yoshikawa J, Yoshida K, et al. Flow capacity of internal mammary artery grafts: early restriction and later improvement assessed by Doppler guide wire. Comparison with saphenous vein grafts. *J Am Coll Cardiol* 1995;25:640-7.
  22. Voudris V, Manginas A, Vassilikos V, Koutelou M, Kantzis J, Cokkinos DV. Coronary flow velocity changes after intravenous dipyridamole infusion: measurements using intravascular Doppler guide wire: a documentation of flow inhomogeneity. *J Am Coll Cardiol* 1996;27:48-55.
  23. Claves MJ, Vrints CJ, Bosmans J, Krug B, Blockx PP, Snoeck JP. Coronary flow reserve during coronary angioplasty in patients with a recent myocardial infarction: relation to stenosis and myocardial viability. *J Am Coll Cardiol* 1996;28:1712-9.
  24. Akasaka T, Yoshida K, Yamamoto A, et al. Phasic coronary flow characteristics in patients with constrictive pericarditis: comparison with restrictive cardiomyopathy. *Circulation* 1997;96:1874-81.
  25. Akasaka T, Yoshida K, Hozumi T, et al. Retinopathy identifies marked restriction of coronary flow reserve in patients with diabetes mellitus. *J Am Coll Cardiol* 1997;30:935-41.
  26. Akasaka T, Yoshida K, Hozumi T, et al. Comparison of coronary flow reserve between focal and diffuse vasoconstriction induced by ergonovine in patients with vasospastic angina. *Am J Cardiol* 1997;80:705-10.
  27. Heller LI, Cates C, Popma J, et al. Intracoronary Doppler assessment of moderate coronary artery disease: comparison with <sup>201</sup>Tl imaging and coronary angiography. *Circulation* 1997;96:484-90.
  28. Ogasawara Y, Hiramoto O, Kagiya M, et al. Evaluation of blood velocity profile by high frequency ultrasound pulsed Doppler velocimeter by multi-gated zero-cross method together with a Fourier transform method. *IEEE Comput Cardiol* 1984:447-50.
  29. Kajiya F, Ogasawara Y, Tsujioka K, et al. Evaluation of human coronary blood flow with an 80-channel pulsed Doppler velocimeter and zero-cross and Fourier transform methods during cardiac surgery. *Circulation* 1986;74 Suppl III:53-60.
  30. Kajiya F, Tsujioka K, Ogasawara Y, et al. Analysis of flow characteristics in poststenotic regions of the human coronary artery during bypass graft surgery. *Circulation* 1987;76:1092-100.
  31. Aragam JR, Main J, Guerrero JL, et al. Doppler color flow mapping of epicardial coronary arteries: initial observation. *J Am Coll Cardiol* 1993;21:478-87.
  32. Kenny A, Shapiro LM. Identification of coronary artery stenoses and poststenotic blood flow patterns using a miniature high-frequency epicardial transducer. *Circulation* 1994;89:731-9.
  33. Iliceto S, Marangelli V, Memmola C, Rizzon P. Transesophageal Doppler echocardiography evaluation of coronary blood flow in baseline conditions and during dipyridamole-induced coronary vasodilation. *Circulation* 1991;83:61-9.
  34. Redberg RF, Sobol Y, Chou TM, et al. Adenosine-induced coronary vasodilatation during transesophageal Doppler echocardiography: rapid and safe measurement of coronary flow reserve ration can predict significant left anterior descending coronary stenosis. *Circulation* 1995;92:190-6.
  35. Stoddard MF, Prince CR, Moriis GT. Coronary flow reserve assessment by dobutamine transesophageal Doppler echocardiography. *J Am Coll Cardiol* 1995;25:325-32.
  36. Fusejima K. Noninvasive measurement of coronary artery blood flow using combined two-dimensional and Doppler echocardiography. *J Am Coll Cardiol* 1987;10:1024-31.
  37. Ross JJ Jr, Mintz RG, Chandrasekaran K. Transthoracic two-dimensional high frequency (7.5 MHz) ultrasonic visualization of the distal left anterior coronary artery. *J Am Coll Cardiol* 1990;15:373-7.
  38. Kenny A, Shapiro LM. Transthoracic high-frequency two-dimensional echocardiography, Doppler and color flow mapping to determine anatomy and blood flow patterns in the distal left anterior descending coronary artery. *Am J Cardiol* 1992;69:1265-8.
  39. Kenny A, Wisbey CR, Shapiro LM. Measurement of left anterior descending coronary artery flow velocities by transthoracic Doppler ultrasound. *Am J Cardiol* 1994;73:12021-2.
  40. Kenny A, Wisbey CR, Shapiro LM. Profiles of coronary blood flow velocity in patients with aortic stenosis and the effect of valve replacement: a transthoracic echocardiographic study. *Br Heart J* 1994;71:57-62.
  41. Crowley JJ, Dardas PS, Harcombe AA, Shapiro LM. Transthoracic Doppler echocardiographic analysis of phasic coronary blood flow velocity in hypertrophic cardiomyopathy. *Heart* 1997;77:558-63.
  42. Crowley JJ, Shapiro LM. Transthoracic echocardiographic measurement of coronary blood flow and reserve. *J Am Soc Echocardiogr* 1997;10:337-43.
  43. Hozumi T, Yoshida K, Ogata K, et al. Noninvasive assessment of significant left anterior descending coronary artery stenosis by coronary flow velocity reserve using transthoracic color Doppler echocardiography. *Circulation* 1998;97:1557-62.
  44. Mulvagh SL, Foley DA, Aeschbacher BC, Klarich KK, Seward JB. Second harmonic imaging of an intravenously administered echocardiographic contrast agent: visualization of coronary arteries and measurement of coronary blood flow. *J Am Coll Cardiol* 1996;27:1519-25.
  45. Hasse J, van der Linden MM, Di Mario C, van der Giessen WJ, Foley DP, Serruys PW. Can the same edge-detection algorithm be applied to on-line analysis systems? *Am Heart J* 1993;126:312-21.
  46. Lesperance J, Waters D. Measuring progression and regression of coronary atherosclerosis in clinical trials: problems and progress. *Int J Card Imaging* 1992;8:165-73.
  47. Koning G, van der Zwet PM, von Land CD, Reiber JH. Angiographic assessment of dimensions of 6F and 7F Mallinckrodt Softouch coronary contrast catheters from digital and cine arteriograms. *Int J Card Imaging* 1992;8:153-61.
  48. Bland JM, Altman DG. Statistical methods for assessing agreement between two methods of clinical measurement. *Lancet* 1986;1:307-10.
  49. Gould K, Goldstein R, Mullani N. Noninvasive assessment of coronary stenoses by myocardial perfusion imaging during pharmacologic coronary vasodilation. VII: clinical feasibility of positron cardiac imaging without a cyclotron using generator-produced rubidium-82. *J Am Coll Cardiol* 1986;7:775-89.
  50. Isada L, Marwick TH, MacIntyre WJ. Physiologic evaluation of coronary flow: the role of positron emission tomography. *Cleve Clin J Med* 1993;60:19-24.
  51. Uren NG, Melin JA, Bruyne BD, Wijns W, Baudhuin T, Camici PG. Relation between myocardial blood flow and the severity of coronary artery stenosis. *N Engl J Med* 1994;330:1782-8.



52. Marcus RF, Doty DB, Hiratsuka LF, Wright CB, Eastham CL. Decreased coronary reserve: a mechanism for angina pectoris in patients with aortic stenosis and normal coronary arteries. *N Engl J Med* 1982;307:1362-7.
53. Cannon RO, Rosing DR, Maron BJ, et al. Myocardial ischemia in patients with hypertrophic cardiomyopathy: contribution of inadequate vasodilator reserve and elevated left ventricular filling pressures. *Circulation* 1985;71:234-43.
54. Houghton JL, Frank MJ, Carr AA, Dohlen TW, Prisant LM. Relations among impaired coronary flow reserve, left ventricular hypertrophy and thallium perfusion defects in hypertensive patients without obstructive coronary artery disease. *J Am Coll Cardiol* 1990;15:43-51.
55. Nitenberg A, Valensi P, Sachs R, Dali M, Aptecar E, Attali J. Impairment of coronary vascular reserve and Ach-induced coronary vasodilation in diabetic patients with angiographically normal coronary arteries and normal left ventricular systolic function. *Diabetes* 1993;91:635-40.
56. Nahser PJ, Brown RE, Oskarsson H, Winniford MD, Rossen JD. Maximal coronary flow reserve and metabolic coronary vasodilation in patients with diabetes mellitus. *Circulation* 1995;91:635-40.