



Alexandria University Faculty of Medicine
Alexandria Journal of Medicine

<http://www.elsevier.com/locate/ajme>



3DCRT for posterior fossa: Sparing of surrounding organs at risk



Azza Helal ^{a,*}, Mohamed Farouk Mostafa ^b, Rasha Elsaka ^b, Shady Fadel ^b

^a Medical Physics Unit, Diagnostic Imaging Department, Faculty of Medicine, Alexandria University, Egypt

^b Clinical Oncology Department, Faculty of Medicine, Alexandria University, Egypt

Received 11 March 2013; accepted 16 May 2013

Available online 25 June 2013

KEYWORDS

Medulloblastoma;
Post fossa boost irradiation;
3DCRT;
Cochlea sparing

Abstract *Introduction:* Radiotherapy of the posterior fossa is routinely delivered using 3DCRT parallel-opposed lateral fields. However high incidence of sensorineural hearing loss, hypothalamic–pituitary dysfunction, thyroid and gonadal dysfunction during radiotherapy makes the need for treatment plan which provides adequate coverage of the target volume while sparing of the cochlea and other surrounding organs at risk (OARs) at same time inevitable.

Aim of the work: To compare the coverage of posterior fossa and the dose to surrounding OARs including non-posterior fossa brain, pituitary, cochlea, eyes, optic nerves, optic chiasm, cervical spinal cord, thyroid gland, pharynx, parotid glands and mandible using three different 3DCRT plans.

Methods: Ten patients underwent CT simulation for treatment planning of posterior fossa boost. The CT data were transferred to Precise Elekta treatment planning system where posterior fossa, non-posterior fossa brain, pituitary, cochlea, parotid glands, cervical spinal cord, thyroid gland, pharynx, mandible, eyes, lenses, optic nerves and optic chiasm were all contoured.

For each patient, three plans were carried out; two parallel opposed open lateral photon fields, a pair of wedged posterior oblique fields, and a pair of wedged posterior oblique fields and an open vertex field.

Abbreviations: 3DCRT, three dimensional onformal radiotherapy; OARs, organs at risk; DVPs, dose volume histogram parameters; CNS, central nervous system; COG, children's oncology group; ACOD, alexandria clinical oncology department; CT, computed tomography; CSI, craniospinal irradiation; PTV, planning target volume; MLCs, multi-leave collimators; DVH, dose volume histograms; Rt.C, right cochlea; Lt. C, left cochlea; Non P.F, non posterior fossa brain.

* Corresponding author. Present address: Diagnostic Imaging Department, Faculty of Medicine, Alexandria University, Egypt.

E-mail addresses: helals2002@yahoo.com, helals2002@yahoo.com (A. Helal), roshaomar@yahoo.com (R. Elsaka), shadyfadel@hotmail.com (S. Fadel).

Peer review under responsibility of Alexandria University Faculty of Medicine.

<http://dx.doi.org/10.1016/j.ajme.2013.05.003>

2090-5068 © 2013 Alexandria University Faculty of Medicine. Production and hosting by Elsevier B.V. All rights reserved.

For all plans, the dose distributions and dose volume histogram parameters (DVPs) for the PTV and OARs were compared and analyzed statistically using excel sheet 2003 and SPSS spreadsheet (SPSS base 18).

Results: Posterior fossa dose coverage and its homogeneity were adequate and comparable for the three plans. A part from high mean dose received by cochlea, plan 1 shows the best sparing for other OARs.

Conclusion: 3DCRT using parallel opposed fields is recommended for posterior fossa irradiation boost as it minimizes the exit dose to all structures other than the cochlea, however its mean dose was within the tolerance.

© 2013 Alexandria University Faculty of Medicine. Production and hosting by Elsevier B.V. All rights reserved.

1. Introduction

Primary central nervous system (CNS) tumors are the most common solid tumors in children. The posterior fossa is the site of about half of these tumors, including medulloblastomas, cerebellar and brainstem astrocytomas, and fourth ventricular ependymomas.¹ In Egypt medulloblastoma is a common tumor, and constitutes about 19% of primary intracranial neoplasms.²

Most children with brain tumors (including medulloblastoma) will require radiotherapy during the course of their management. Radiotherapy of posterior fossa tumors is technically challenging, and radiation-induced side effects have been a primary concern in those patients. The concern has been the greatest for patients with average-risk medulloblastoma, for whom long-term disease control is expected, and the side effects of therapy have more significant lasting impact.³

Radiotherapy of the posterior fossa is routinely delivered using 3DCRT parallel-opposed lateral fields. However it is technically challenging because of radiation-induced side effects for surrounding OARs. Although the exit doses may be in the surrounding normal brain and other critical structures; the entrance dose from a vertex field may also contribute to additional dose to the normal supra tentorium.³

Although five-year free and overall survival rates were 81 and 86% respectively in one of the COG trials, ototoxicity was reported in approximately 25% of the patients in this trial.^{4,5}

Ototoxicity is the most important adverse effect of treatment as radiation beams cover the inner ear. It impairs the child's cognitive function and quality of life.⁶ Although the tolerance of the cochlea to radiation is not known, the incidence of Ototoxicity was low for a cochlear mean dose of 30 Gy or less and increased at doses greater than 40–45 Gy.⁷ Ototoxicity has been found to be more significant when radiotherapy and cisplatin chemotherapy are used in combination.^{8,9} Hearing loss occurred after doses greater than 50–60 Gy.¹⁰

There has been some concern in the pediatric radiation oncology community regarding this method of delivering the posterior fossa boost. In two-dimensional radiotherapy, opposed lateral fields are used to treat the posterior fossa compartment; exit doses of each field are confined mainly to the posterior fossa. The high incidence of sensorineural hearing loss during radiotherapy treatment planning of post fossa makes the need for treatment plan which provides adequate

coverage of the target volume while sparing the cochlea at same time inevitable.¹

2. Aim of the work

This study aimed to compare the coverage of posterior fossa and the dose to surrounding OARs including non-posterior fossa brain, pituitary, cochlea, eyes, optic nerves, optic chiasm, cervical spinal cord, thyroid gland, pharynx, parotid glands and mandible for three different 3DCRT plans in a way to create an optimum plan that shows adequate target coverage and sparing of these OARs.

3. Methods

Ten children diagnosed as having medulloblastoma included in the present study were referred to Alexandria Clinical Oncology Department (ACOD), Alexandria Faculty of Medicine from January 2011 to March 2012 for craniospinal irradiation and post fossa irradiation boost. A computed tomography (CT) simulation was performed at a slice thickness of 3 mm from the top of the head to the mid-pelvis. Patients were immobilized using individual thermoplastic head masks with shoulder fixation which extended to the base of the skull to ensure reproducible positioning.

The CT data were transferred to Precise Elekta treatment planning system. After all patients had received craniospinal irradiation (CSI) with two lateral parallel opposed fields to the head and a matched posterior spine field, all required structures necessary for posterior fossa irradiation were contoured. They include posterior fossa and OARs. The PTV was constructed by adding a margin of 7 mm around the posterior fossa. OARs including non-posterior fossa brain, pituitary, cochlea, parotid glands, cervical spinal cord, thyroid gland, pharynx, mandible, eyes, lenses, optic nerves and optic chiasm were all contoured.

For each patient three plans were created using 6 MV photon beams; (a) two parallel opposed lateral open fields, (b) a pair of posterior oblique wedged fields, and (c) a pair of posterior oblique wedged fields and an open vertex field (Fig. 1). The gantry and collimator angles of obliques and vertex beams were adjusted to spare most of OARs. Wedge angles used were 15°, 25° and 30°. Couch angle was 90° for vertex. The field size was defined by the beam's eye view of the PTV and MLCs were used to shape the beams and to spare close by OARs. The dose prescribed was 18 Gy to posterior fossa in

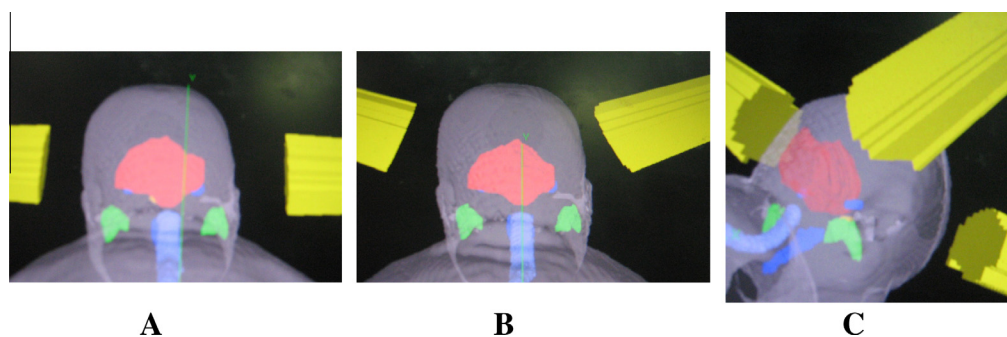


Figure 1 Field arrangements for the three techniques used in irradiating the posterior fossa: (A) parallel-opposed lateral fields; (B) two posterior oblique wedged fields; (C) two posterior oblique wedged fields with a vertex field. It also shows post fossa in red, both parotids in green, cochlea and pharynx in blue, spinal cord in violet.

10 fractions over 2 weeks (subsequent to a craniospinal treatment of 36 Gy).

For all plans, isodose distributions and DVHs were generated. Plan evaluation and comparison depend on dose coverage of PTV, its conformity and homogeneity and the sparing of OARs. The coverage of PTV was evaluated using $D_{95\%}$ and maximum dose. Dose homogeneity index within PTV was calculated for all patients by dividing the maximum dose of the PTV by its minimum. The DVPs which determine the tolerance and so the sparing of OARs were also compared.

4. Statistical analysis

For all patients, DVPs were recorded. The differences and % of reduction of the DVPs of PTV and different OARs between the plans were calculated and analyzed statistically using excel sheet 2003 and SPSS Wilcoxon signed Rank test (version 18).

5. Results

By reviewing the DVPs of the three treatment plans for all patients, the followings are the results as regards the dose distribution of the PTV and OARs including non-posterior fossa brain, pituitary, cochlea, parotid glands, cervical spinal cord, thyroid gland, pharynx, mandible, eyes, lenses, optic nerves and optic chiasma (Table 1 and Fig. 2): Table 1 gives the statistical analysis and DVPs for PTV and OARs comparing the three plans.

5.1. PTV dosimetry

PTV coverage ($D_{95\%}$) is adequate and comparable for plans 1 and 2 and it is significantly better for plan 3. PTV max. dose is comparable for plans 1 and 2 and it is significantly lower for plan 3 compared to plan 1. Although the dose is more homogeneous for plan 3 compared to plans 1 and 2, these differences are not significant. Body max dose is accepted and comparable for the three plans.

5.2. OAR dosimetry

Using two parallel opposed lateral open fields (plan 1) shows the least mean doses for parotids, pharynx and mandible followed by plan 3 and then plan 2. Plan 1 also shows the least

mean dose for pituitary and eyes and the least max. point dose to the spinal cord, optic chiasm, optic nerves and lenses followed by plan 2 and then plan 3.

Although Plan 2 shows the least mean dose for both cochlea followed by plan 3 then plan 1, Plan 1 & 2 show the least mean dose for non posterior fossa brain followed by plan 3. On the other hand, plan 3 shows the least mean dose for thyroid followed by plan 1 & 2. Table 1 shows the percentage of reduction in DVPs of different OARs between the three plans and whether these reductions are significant or not.

Although the three plans show adequate dose coverage and homogeneity within PTV, using two parallel opposed lateral open fields (plan 1) shows some advantages; the least mean dose for parotids, pharynx and mandible, pituitary, non post fossa brain and eyes and the least max. point dose to the spinal cord, optic chiasm, optic nerves and lenses. On the other hand it shows non significant greatest dose to both cochlea as they are entirely present within the parallel opposed fields. However, the advantage of using a pair of posterior oblique wedged fields (plan 2) and a pair of posterior oblique wedged fields with vertex field (plan 3) is sparing of the cochlea.

6. Discussion

3DCRT for post. fossa boost allows delivery of the prescribed dose to posterior fossa while minimizing the dose to surrounding OARs. This is important in children with medulloblastoma which is a common childhood malignancy with various critical structures such as the developing brain, bone, thyroid gland, pituitary gland, and cochlea may not be fully developed.³ Also, as the majority of patients will survive (long-term survival in this disease is about 55–65%).¹¹ Recent reports highlighted the importance of minimizing the dose to these OARs below their tolerance values during cranio spinal and/or posterior fossa boost irradiation, otherwise, late effects of radiation therapy such as somatic and carcinogenic effects may be observed during the follow-up period.^{3,11}

The current study compared three techniques for irradiation of post. fossa: two parallel opposed open lateral photon fields, a pair of wedged posterior oblique fields, and a pair of wedged posterior oblique fields with an open vertex field. In the current study, although the average of the mean dose received by both cochlea was greater for plans 2 and 3 (98%, 89% and 90%) respectively compared with the figures

Table 1 Comparison of the average of DVPs of PTV and OARs irradiated by three different techniques for post fossa patients (all are in %). *P* values for the differences between the plans are also shown.

DVPs	Plan 1	Plan 2	Plan 3	Differences % plan 1/ 2 <i>P</i> values	Differences % plan 1/ 3 <i>P</i> values	Differences % plan 2/ 3 <i>P</i> values
PTV D _{95%}	98.5	98	99	0.5 0.892	-0.5 0.041	-1 0.026
PTV _{max}	110	110	108	0 0.952	1.8 0.014	1.8 0.098
Homogeneity index	1.27	1.27	1.24	0 0.959	2 0.444	2 0.059
Rt. Parotid mean	20	30.5	28	-34 0.005	-28.5 0.005	8 0.005
Lt. Parotid mean	19	28	26	-32 0.065	-27 0.074	7 0.073
Rt.C mean	98	85	87	13 0.139	11 0.153	-2 0.007
Lt. C. mean	98	93	93	5 0.138	5 0.202	0 0.165
Pharynx mean	3	6	6	-50 0.004	-50 0.005	0 0.683
Thyroid mean	0.6	0.6	0.5	0 1	17 0.317	17 0.317
Mandible mean	2.5	4.5	4	-44 0.010	-37.5 0.008	11 0.317
Pituitary mean	35.5	48	57	-26 0.011	-38 0.005	-16 0.005
Spinal cord max	38	47	48	-19 0.047	-21 0.059	-2 0.645
Non P.F.brainmean	21	21	30	0 0.234	-30 0.005	-30 0.005
Optic chiasm max	29	39	51	-26 0.018	-43 0.005	-23.5 0.005
Rt. optic nerve max	6	8	21	-25 0.096	-71 0.005	-62 0.008
Lt. optic nerve max	12	12	24	0 0.340	-50 0.017	-50 0.007
Rt. Eye mean	1	1	3	0 0.083	-67 0.039	-67 0.109
Lt. Eye mean	2	3	4.5	-33 0.071	-55 0.011	-33 0.033
Rt lens max.	0.7	0.9	3	-22 0.414	-77 0.008	-70 0.011
Lt lens max.	1.4	1.7	2	-17 0.414	-30 0.034	-15 0.180
Body max dose	108	108	107	0 0.535	0.9 0.581	0.9 0.280

achieved by Paulino et al.³ (100%, **50%** and **42%**) respectively, on the other hand, the average in the current study was still within tolerance (52 Gy = 16 Gy + 36 Gy; 16 Gy delivered by post fossa boost (90% X 18 Gy) added to 36 Gy from craniospinal irradiation).

In the current study the average of the mean dose to non-posterior fossa brain using plans 1 and 2 was comparable and lower than plan 3 which showed the highest average of the mean dose among the three plans (21%, 21% and **30%**) respectively. Although these figures were comparable to those achieved by Paulino et al.³ (22%, 22% and **39%**) respectively, on the other hand, the mean dose of plan 3 in the current study was lower than what they achieved. In contrast to Paulino et al.³ results, the average of the mean dose to the pituitary

gland using plans 2 and 3 was far higher in the current study (35.5%, **48%** and **57%**) respectively compared to in their study (36%, **19%** and **21%**) respectively.

The average of the mean dose to the mandible was the least for plan 1 followed by plan 3 and then plan 2 (2.5%, 4.5% and 4%) respectively this is in accordance to Paulino et al.³ results (8%, 14% and 11%), but our figures were far lower.

The average of the mean dose to thyroid was lower in the current study (0.6%, 0.6%, and 0.5%) respectively compared to Paulino et al.³ study (0%, 1% and 3%) respectively.

The average of the mean dose to both parotids was lower in plan 1 followed by plan 3 then plan 2 (19%, 29% and 27%) respectively this agrees with Paulino et al.³ (13%, 34% and 25%) respectively.

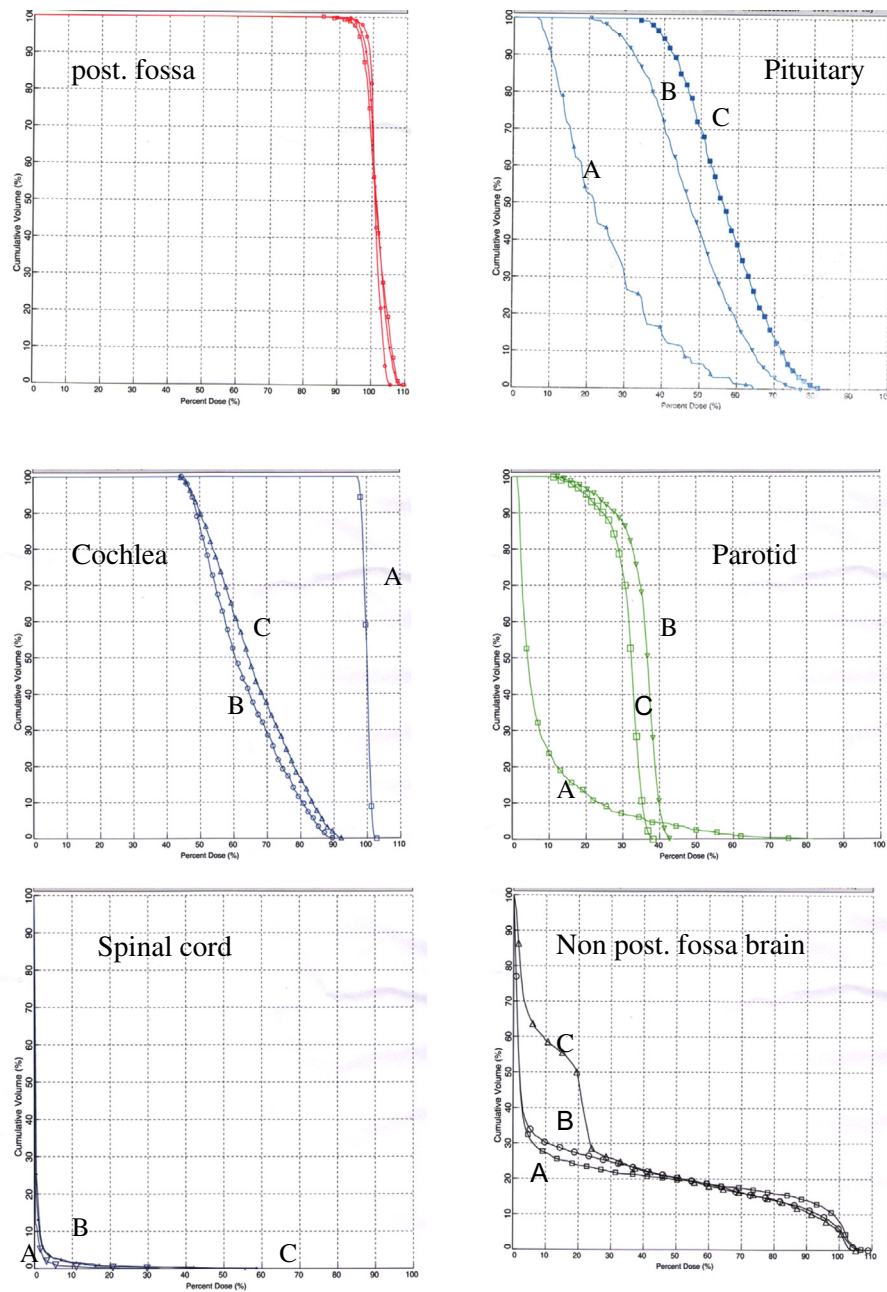


Figure 2 Dose volume histograms for OARs. (A) parallel-opposed lateral fields; (B) two posterior oblique wedged fields; (C) two posterior oblique wedged fields with a vertex field. All are in %.

In contrary to Paulino et al.³ study, the current study showed the average of the mean dose to the pharynx was far lower for the three plans (3%, 6% and 6%) respectively compared to the figures in their study (8%, 13% and 12%).

So the results of the current work agree with Paulino et al.³ in; plan 1 shows the lowest mean dose to mandible, parotids and pharynx, plans 1 and 2 show the lowest mean dose to non post fossa brain, and plans 2 and 3 achieve the lowest mean dose to cochlea. For both studies thyroid dose was very low for all plans. On the other hand the results are different in; the lowest dose to pituitary was in plan 1 in the current study and in plan 2 in their work.

In both studies; the main advantage of using posterior obliques and post obliques with vertex is minimizing the dose to both cochlea while the main disadvantage is higher dose to parotid glands, mandible and pharynx, and to non post fossa brain when a vertex field is used.

Fukunaga-Johnson et al.¹² compared the dose received by both cochlea, pituitary and mandible using plans 1 and 2. The cochlear dose for each patient was calculated as an average between the right and the left cochlea due to symmetry of the problem so the dose distributions between the right and left cochlea were essentially equivalent. For plans 1 and 2, the average of the mean dose of both cochlea was (100%

and 70%) respectively of the prescribed dose compared to (98% and 89%) respectively in the current work. The average of the mean dose to the pituitary was far higher in their work (48% and 68%) respectively compared to (35.5% and 48%) respectively in the current work. On the other hand, the average of mean dose of the mandible was far lower in their work (0.8% and 1.8%) respectively compared to (2.5% and 4.5%) respectively in the current work.

So for both studies; plan 1 shows the highest dose to cochlea, and the lowest dose to pituitary and mandible compared to plan 2. Moreover in the current study our figures for pituitary only were far lower than those achieved in their study.

In Breen et al.¹ study using opposing and oblique fields, the average of the mean dose to the cochlea delivered by both plans respectively was lower (97–100% and 65–84%) respectively compared to (98% and 89%) respectively in our work. For none post fossa brain; the average of the mean dose was far higher (46–61% and 36–51%) respectively compared to (21% and 21%) in our work. For optic nerves; the max point dose was lower (2–2.8% and 4–13%) respectively compared to (6% and 12%) respectively in our work. For lenses; max. Point dose was higher (0.9–1.4% and 1.8–2.3%) respectively compared to (0.7–0.9% and 1.4–1.7%) respectively in our work. For pituitary; the average of the mean dose was higher (15–38% and 56–60%) respectively compared to (35.5% and 48%) respectively in our work. For the spinal cord; the max point dose was higher (14–77% and 14–78%) respectively compared to (38% and 47%) respectively in our work). They attributed their results to; the use of posterior oblique fields can exclude the cochlea from the fields, thereby reducing their dose, however, as the exit dose will be in structures anterior and close by to the posterior fossa so their doses are increased compared to opposed lateral fields. Comparing both studies, except for the mean dose of cochlea and max. point dose of optic nerve which were higher in the current study, our figures are far lower than those achieved in their study.

3DCRT open opposed lateral fields showed the lowest dose to all critical structure except both cochlea which received the target dose because of their proximity to the target volume. However as the average of the mean dose to cochlea (53.6Gy) was still within tolerance (17.6Gy delivered by posterior fossa boost (98% X 18Gy) added to 36Gy from craniospinal irradiation) so we recommend to use it for posterior fossa boost irradiation.

7. Conclusion

3DCRT using parallel opposed fields is recommended for posterior fossa irradiation boost as it minimizes the exit dose to all structures other than the cochlea, however its mean dose was within the tolerance.

Conflict of interest

None declared.

References

1. Breen SL, Kehagioglou P, Usher U, Plowman PN. A comparison of conventional, conformal and intensity-modulated coplanar radiotherapy plans for posterior fossa treatment. *British J Radiol* 2004;**77**:768–74.
2. El-Gaidi MA. Descriptive Epidemiology of Pediatric Intracranial Neoplasms in Egypt. *Pediatr Neurosurg* 2011;**47**:385–95.
3. Paulino AC, Ashwatha Narayana M, Najeeb Mohideen, Andsam Jeswani, C. Posterior Fossa Boost In Medulloblastoma An Analysis Of Dose To Surrounding Structures Using 3Dimensional Conformal Radiotherapy. *Int J Radiation Oncology Biol Phys* 2000;**46**(2):281–6.
4. Packer RJ, Gajjar A, Vezina G, et al. Phase III study of craniospinal radiation therapy followed by adjuvant chemotherapy for newly diagnosed average-risk medulloblastoma. *J Clin Oncol* 2006;**24**:4202–8.
5. Merchant TE, Wang MH, Haida T, et al. Medulloblastoma. Long-term results for patients treated with definitive radiation therapy during the computed tomography era. *Int J Radiat Oncol Biol Phys* 1996;**36**:29–35.
6. Fukunaga-Johnson N, Lee JH, Sandler HM, et al. Patterns of failure following treatment for medulloblastoma: is it necessary to treat the entire posterior fossa? *Int J Radiat Oncol Biol Phys* 1998;**42**:143–6.
7. Hua C, Bass JK, Khan R, et al. Hearing loss after radiotherapy for pediatric brain tumors: effect of cochlear dose. *Int J Radiat Oncol Biol Phys* 2008;**72**:892–9.
8. Kortmann RD, Kuhl J, Timmermann B, et al. Postoperative neoadjuvant chemotherapy before radiotherapy as compared to immediate radiotherapy followed by maintenance chemotherapy in the treatment of medulloblastoma in childhood: results of the German prospective randomized trial HIT '91. *Int J Radiat Oncol Biol Phys* 2000;**46**:269–79.
9. Paulino AC, Lobo M, Teh BS, et al. Ototoxicity after intensity-modulated radiation therapy and cisplatin-based chemotherapy in children with medulloblastoma. *Int J Radiat Oncol Biol Phys* 2010;**78**:1445–50.
10. Huang E, Teh BS, Strother DR, et al. Intensity-modulated radiation therapy for pediatric medulloblastoma: early report on the reduction of ototoxicity. *Int J Radiat Oncol Biol Phys* 2002;**52**:599–605.
11. Kun LE. Malignant brain tumors including medulloblastoma, embryonal neuroectodermal tumors, and tumors of the pineal region, with a special discussion of the management of brain tumors in children of 3 years and younger. In: Cassady JR, editor. *Radiation Therapy in Pediatric Oncology*. first ed. Berlin, Heidelberg: Springer-Verlag; 1994. p. 197–213.
12. Fukunaga-Johnson N, Sandler HM, Marsh R, et al. The use of 3D conformal radiotherapy (3D CRT) to spare the cochlea in patients with medulloblastoma. *Int J Radiat Oncol Biol Phys* 1998;**41**:77–82.