

available at <http://www.tzuchimedjnl.com/>



Tzu Chi Medical Journal

## Case Report

# Hairy Neck Skin Flap in a Pharyngostoma: An Unusual Complication of Total Laryngectomy

*Erdogan Gultekin<sup>1</sup>, Omer N. Develioglu<sup>2</sup>, Kursat Yelken<sup>3</sup>,  
Murat Yener<sup>1\*</sup>, Hakan Koleli<sup>2</sup>*

<sup>1</sup>Department of Otorhinolaryngology, Faculty of Medicine, Namık Kemal University, Tekirdag, Turkey

<sup>2</sup>Department of Otorhinolaryngology, Taksim Education and Research Hospital, Istanbul, Turkey

<sup>3</sup>Department of Otorhinolaryngology, Faculty of Medicine, Gaziosmanpasa University, Tokat, Turkey

## Article info

### Article history:

Received: November 5, 2009

Revised: December 30, 2009

Accepted: February 9, 2010

### Keywords:

Complication

Fistula

Flap

Laryngectomy

Pharyngocutaneous fistula

## Abstract

Postoperative pharyngocutaneous fistula is a common complication after total laryngectomy. A 58-year-old man had a pharyngocutaneous fistula after a total laryngectomy. Because of the prolonged hospital stay and expensive postoperative care, he refused to stay in the clinic until fistula closure. After 7 months, he returned with a hairy neck skin flap in the fistula region. This case emphasizes the importance of appropriate postoperative wound care and the possibility of neck skin curling throughout the fistula tract during fistula closure. (*Tzu Chi Med J* 2010;22(4):203–205)

\*Corresponding author. Department of Otorhinolaryngology, Namık Kemal Üniversitesi Tıp Fakültesi Hastanesi, Tekirdag, Turkey.

E-mail address: [hmuratyener@gmail.com](mailto:hmuratyener@gmail.com)

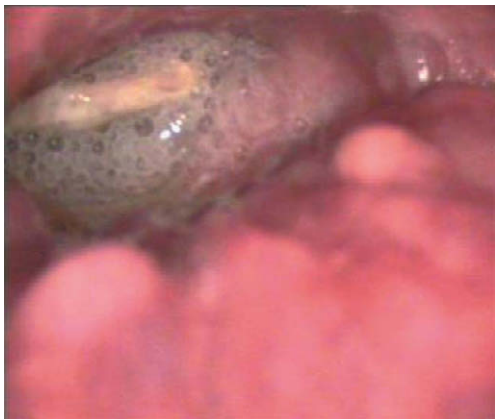## 1. Introduction

Postoperative pharyngocutaneous fistula is the most common complication after total laryngectomy. It prolongs hospital stay and increases patient morbidity. The incidence rate varies from 2.6% to 65.5% (1). Fistula management ranges from conservative treatment, reconstructive surgery. In conservative treatment, the fistula tract is expected to close when it fills with connective tissue. However, when the fistula persists for more than 4 weeks, surgical closure is indicated (2).

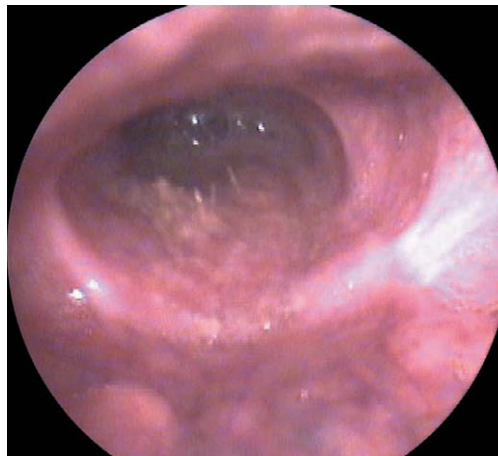
In this report, we present a laryngectomy patient with a hairy neck skin flap in the pharyngostoma region after unsuccessful conservative treatment of a pharyngocutaneous fistula. According to our knowledge, this complication is unique in the literature.

## 2. Case report

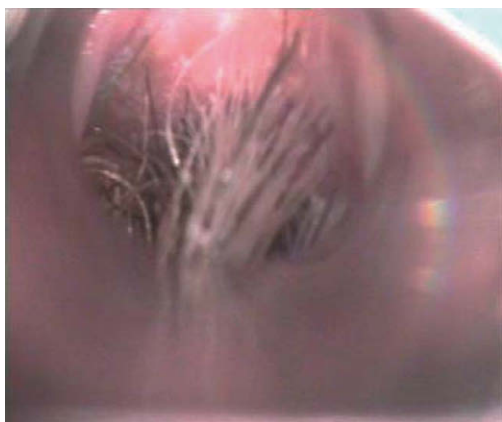
A 58-year-old man was treated by total laryngectomy with right-side radical and left-side functional neck dissection because of T3 squamous cell laryngeal



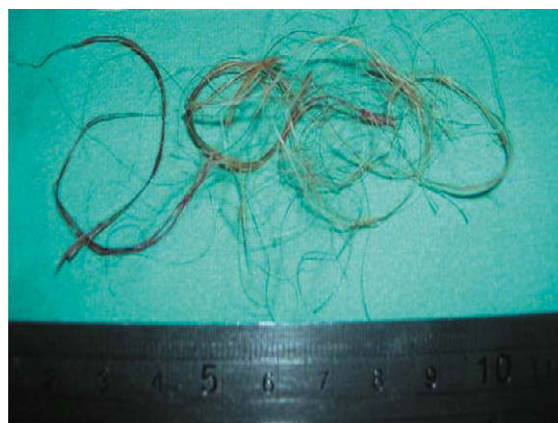**Fig. 1** — Laryngeal endoscopy view of the hairy skin flap surrounded by salivary accumulation in the pharyngostoma region.



**Fig. 3** — Laryngeal endoscopy view of the skin flap after hair removal.



**Fig. 2** — Direct laryngoscopic appearance of the hairy skin flap attached to the anterior wall of the pharynx.



**Fig. 4** — Resected hair.

carcinoma. Although no complications were observed in the early postoperative period, a pharyngocutaneous fistula was detected on the 12th postoperative day. Wound care was initiated with daily dressing changes and cleaning with antiseptic solutions. However, after 4 weeks, the patient refused to remain in the hospital. He was discharged and was lost to further follow-up.

Seven months postoperatively, he was readmitted to the clinic with complaints of hypersalivation and dysphagia. On physical examination, there was no pharyngocutaneous fistula and no sign of neck disease or local recurrence. Laryngeal endoscopy revealed a foreign body surrounded by salivary accumulation in the hypopharynx region.

Surgery was performed to remove the foreign body (Fig. 1). Direct laryngoscopy under general anesthesia identified an island of hairy skin attached to the anterior wall of the pharynx (Fig. 2). The hair was removed and the patient was encouraged to have laser treatment (Figs. 3 and 4).

### 3. Discussion

Laryngectomy is a very common operation for the management of laryngeal cancer. Improvements in the surgical approach, suture materials and appropriate postoperative care have led to improved surgical outcomes with a very low complication rate. However, pharyngocutaneous fistula, the most common complication after laryngectomy, cannot be avoided. This morbid complication not only increases hospital stay but also increases the cost of the procedure. A continuous salivary leak significantly increases postoperative morbidity, and delays oral feeding and initiation of postoperative radiotherapy (3–5). After considering the prolonged hospital stay and high cost of intensive postoperative care, our patient refused to stay in the clinic until the fistula closed.

Although there is still much controversy about prevention of pharyngocutaneous fistulas, it is generally believed that most heal with conservative management

consisting of medical treatment with antibiotics and anti-inflammatory drugs, suspension of oral feeding with positioning of a nasogastric tube or parenteral nutrition and daily local wound care. Wound treatment includes drainage of fluids from the fistulous tract, local cleaning with antiseptic and antibiotic solutions, and removal of all necrotic tissue, followed by curettage of the fistulous borders and a pressure dressing above the neck flaps (6,7). Surgical closure is needed if conservative management fails. The reported closure periods for a fistula vary between 5 and 81 days (mean, 29 days) (2). Options are direct surgical repair in two layers, and repair by local and distant flaps. However, if care of the fistula is not done in special institutions by skilled physicians, complications such as wound infection, hemorrhage and pneumonia can occur (8). After discharge from our clinic, our patient received poor conservative management in private clinics by personnel not trained for this situation. We believe that as a result of excessive and inaccurate dressing pressure on his neck flap, hairy neck skin was turned inside of the fistula through his pharyngostoma. Continuous pressure above the neck flap led the fistula to close, but it also left an island of hairy neck skin inside the pharyngostoma that partly formed the anterior wall of the pharyngostoma. Another explanation for this situation is spontaneous epithelial migration through the fistula tract and iatrogenic epithelial seeding during the operation, but inappropriate wound care seems to be the most favorable explanation. The skin flap produced excessive saliva and its hairy surface caused a foreign body sensation as well as dysphagia. We did not perform a histopathologic examination of the hairy material, but the location, history of fistula and appearance of the removed surgical material (Fig. 4) favored a diagnosis of hairy skin flap.

Clinicians should be aware of the possibility of neck skin curling throughout a fistula in patients with hypersalivation after pharyngocutaneous fistula closure.

## References

1. Paydarfar JA, Birkmeyer NJ. Complications in head and neck surgery: a meta-analysis of postlaryngectomy pharyngocutaneous fistula. *Arch Otolaryngol Head Neck Surg* 2006;132:67-72.
2. Konstantinos DM, Konstantinos CV, Angelos CN, Dimitrios GP, Athanasios IK, Ioannis CD. Incidence and predisposing factors of pharyngocutaneous fistula formation after total laryngectomy. Is there a relationship with tumor recurrence? *Eur Arch Otorhinolaryngol* 2004;261:61-7.
3. Ikiz AO, Uca M, Guneri EA, Erdag TK, Sutay S. Pharyngocutaneous fistula and total laryngectomy: possible predisposing factors, with emphasis on pharyngeal myotomy. *J Laryngol Otol* 2000;114:768-71.
4. Rees R, Cary A, Shack RB, Harris PF. Pharyngocutaneous fistulas in advanced cancer: closure with musculocutaneous or muscle flaps. *Am J Surg* 1987;154:381-3.
5. Virtaniemi JA, Kumpulainen EJ, Hirvikoski PP, Johansson RT, Kosma VM. The incidence and aetiology of postlaryngectomy pharyngocutaneous fistulae. *Head Neck* 2001; 23:29-33.
6. Galli J, De Corso E, Volante M, Almadori G, Paludetti G. Postlaryngectomy pharyngocutaneous fistula: incidence, predisposing factors, and therapy. *Otolaryngol Head Neck Surg* 2005;133:689-94.
7. Redaelli de Zinis LO, Ferrari L, Tomenzoli D, Premoli G, Parrinello G, Nicolai P. Postlaryngectomy pharyngocutaneous fistula: incidence, predisposing factors, and therapy. *Head Neck* 1999;21:131-8.
8. Herranz J, Sarandeses A, Fernandez MF, Barro CV, Vidal JM, Gavilan J. Complications after total laryngectomy in nonradiated laryngeal and hypopharyngeal carcinomas. *Otolaryngol Head Neck Surg* 2000;122:892-8.