




Available online at  
 ScienceDirect  
[www.sciencedirect.com](http://www.sciencedirect.com)

Elsevier Masson France  
 EM|consulte  
[www.em-consulte.com](http://www.em-consulte.com)

 Orthopaedics  
& Traumatology  
Surgery & Research

ORIGINAL ARTICLE

# Tibial intercondylar eminence fractures in children: The long-term perspective

A. Casalonga<sup>a</sup>, S. Bourelle<sup>a</sup>, F. Chalencon<sup>c</sup>, L. De Oliveira<sup>c</sup>,  
V. Gautheron<sup>b</sup>, J. Cottalorda<sup>d,\*</sup>

<sup>a</sup> Children's Surgery Department, Northern Hospital, 2055 Saint-Étienne cedex 2, France

<sup>b</sup> Pediatric Rehabilitation Department, Bellevue Hospital, 42055 Saint-Étienne cedex 2, France

<sup>c</sup> Orthopedic Surgery Department, Mutualistic Surgical Private Hospital, 3, rue Le-Verrier, 42100 Saint-Étienne, France

<sup>d</sup> Pediatric Orthopedics Department, Lapeyronie Hospital, 371, avenue Doyen-Gaston-Giraud, 34295 Montpellier cedex 05, France

Accepted: 19 January 2010

## KEYWORDS

Tibial intercondylar  
eminence fracture;  
Child;  
Adolescent;  
Skeletally immature  
athletes, KT 1000  
arthrometer

## Summary

*Purpose of the study:* To analyze objective and subjective results on medium-term follow-up of intercondylar fractures of the tibia in children.

*Material and methods:* A retrospective, single-center study of 32 fractures (17 boys, 14 girls) was performed. Fractures were itemized on the Meyers and McKeever classification as modified by Zaricznyj: there were eight type-I, 17 type-II, five type-III and two type-IV fractures. Treatment was conservative for type-I and II fractures (with mild displacement) and for the others surgical. Seven patients were lost to follow-up and one had insufficient follow-up for inclusion. Thirteen patients were assessed on a KT 1000 arthrometer and a dynamometer, and on the IKDC and ARPEGE scoring systems. Ten patients chose to answer only the subjective IKDC questionnaire, by mail.

*Results:* The mean IKDC score of subjects answering by mail was 91 and of those with clinical examination was 80. Mean ARPEGE score was 8.3. Subjective IKDC score classified four patients as A, four as B, four as C and one as D. Mean difference in tibial anterior translation between affected and unaffected knees was 0.88 mm for type I fractures, 0.82 mm for type II and 0.30 mm for types III and IV together.

*Discussion:* The mean difference in tibial anterior translation between affected and unaffected knees was greater in patients with conservative treatment (0.96 mm for conservative vs. 0.29 mm for surgical treatment). Seventy per cent of patients reported pain at follow-up. Only two had pathological knee laxity. Twelve out of thirteen had returned to sport activity, half of them at the same level as before injury.

\* Corresponding author. Tel.: +33 4 67 33 87 61; fax: +33 4 67 33 82 48.  
E-mail address: [jerome.cottalorda@gmail.com](mailto:jerome.cottalorda@gmail.com) (J. Cottalorda).

**Conclusion:** The cases treated surgically had a better objective result than those treated conservatively. Nevertheless there was no correlation between subjective evaluation and degree of knee laxity. Overall, intercondylar fractures of the tibial eminence in children have good long-term prognosis, at least subjectively. This study shows that, in spite of a very satisfactory subjective result for most patients, results were not so good on objective measures.

Level of evidence: Level IV: retrospective study.

© 2010 Elsevier Masson SAS. All rights reserved.

## Introduction

Tibial intercondylar eminence fractures are relatively rare (3 per 100,000 of the population [1]) and mainly found in children [1–3]. The ligaments' capacity of resistance in children means that, in case of trauma to the knee, it is the base of the anterior cruciate ligament insertion that gives way, taking with it an osteochondral fragment of greater or lesser size [4]. Although diagnosis and treatment strategy is well codified and consensual [1,4–6], medium to long-term functional and subjective evolution has been little studied.

Residual laxity may be found after both conservative and surgical management [2,3,7]. Few series [1,4,7] have as yet made use of a KT1000<sup>®</sup> arthrometer to assess the difference in tibial anterior translation between the affected and contralateral knee, although it is important to analyze this laxity, even if it does not necessarily correlate with anterior instability [3,7,8]. The present retrospective study analyzed the medium-term evolution of tibial eminence fracture in children with, whenever possible, objective assessment of residual laxity, and subjective and objective IKDC scores [9].

## Material and methods

A single-center retrospective study assessed the medium-term evolution of tibial eminence fracture in children on a series of 32 fractures (17 boys, 1 of whom presented with fractures of both tibial eminences at 1 year's interval; 14 girls) treated and followed up in our Department between 1988 and 2008. Mean age at trauma was 12 years (range, 7–16 1/2 yrs). Fifty percent of cases concerned sports trauma (50% of which concerned skiing accidents), 31% road accidents and 19% home accidents.

Table 1 shows patient data for gender, affected side and trauma circumstances. Imaging systematically comprised AP and lateral knee X-ray views. CT-scan was performed in two cases and MRI in one.

Table 1 shows the distribution of radiologic fracture types. Two of the five type-III fractures were in a single patient. Associated lesions included four incarcerations of the anterior horn of the medial meniscus, two collateral ligament fibular insertion tears and one lateral tibial plate compaction associated with fracture of the superior quarter of the fibula. The radiologic classification used was that of Meyers and McKeever [10] as modified by Zaricznyj [11]: type I is virtually no displacement; type II, partial anterior "duck-bill" elevation of the fragment

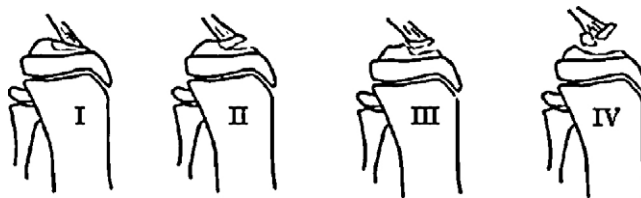**Table 1** Descriptive data for the 32 children.

	Modality	n
Sex	Male	18
	Female	14
Laterality	Right	15
	Left	17
Circumstances	Sports accident	16
	Road accident	10
	Home accident	6
Fracture type	I	8
	II	17
	III	5
	IV	2

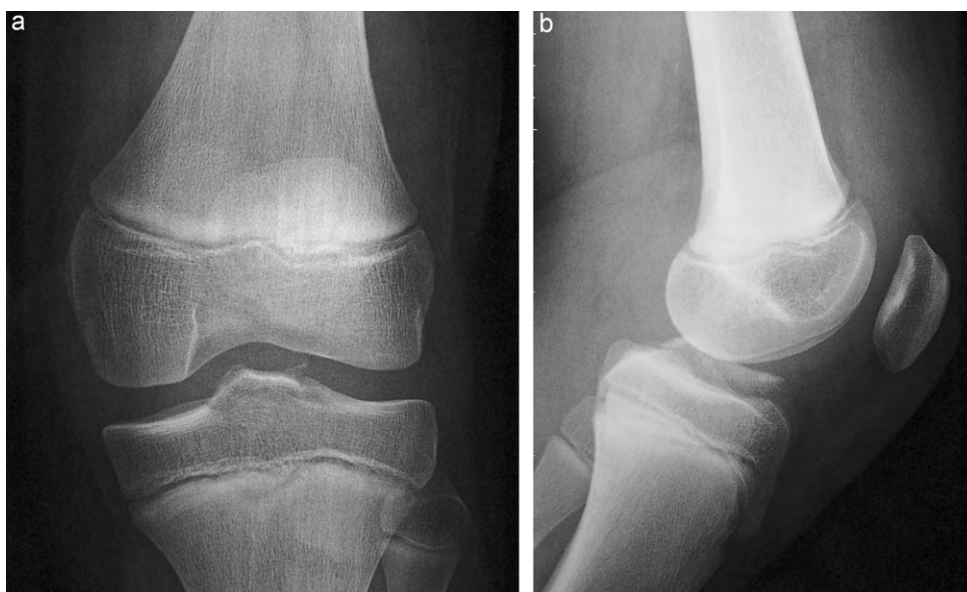but conserving a posterior hinge with the tibial eminence; type III, complete fragment elevation, both anteriorly and posteriorly; and type IV, displaced comminutive fracture (Figs. 1 and 2).

In type I, treatment was conservative, with 4–6 weeks' half-leg cast immobilization, knee in extension. In type II, treatment was surgical (11 cases) when displacement was  $\geq 3$  mm or reduction was imperfect, or otherwise (6 cases) conservative as in type I. In types III and IV, treatment was surgical, comprising testing under general anesthesia then fracture reduction and fixation by suture (4 cases) or screwing (3 cases), by arthrotomy in all cases. Mean post-surgical cast immobilization was 5.8 weeks (range, 4–8 weeks).

All patients were scheduled for follow-up, but seven were lost and one was excluded from analysis as having less than two years' follow-up. Thirteen patients agreed to come for KT 1000<sup>®</sup> (MEDmetric<sup>®</sup> Corp.) arthrometry. Ten declined but agreed to complete the International Knee Documentation Committee (IKDC) subjective questionnaire [9], comprising 18 items (symptoms, level of activity, overall knee function) and giving a score between nine and



**Figure 1** Fracture classification according to Meyers and McKeever as modified by Zaricznyj.



**Figure 2** AP (2a) and lateral (2b) pre-operative X-ray of type-II tibial eminence fracture; 12 year-old boy.

100, 100 representing maximal everyday and sports activity without restriction or symptom. The 13 patients seen for arthrometry were assessed by two examiners, external to the hospital in which the children had been operated on, so as to optimize objectivity. Table 2 presents data for this subpopulation. All 13 patients completed the subjective IKDC [9] and ARPEGE [12] questionnaires. Physiotherapeutic assessment was performed on both knees with manual testing to assess laxity and mobility and complete the IKDC clinical checklist. Mean anterior ligament laxity was calculated from the KT 1000® data and compared between knees. Ipsilateral quadriceps force was measured in kg using a dynamometer and expressed as a percentage of the contralateral (healthy) value.

Patients were classified into three groups according to reduction quality on postoperative and end-of-follow-up AP and lateral X-ray: group 1 showed anatomic reduction; group 2, < 2 mm reduction defect; and group 3, incomplete reduction with > 2 mm defect.

**Table 2** Clinical and radiological descriptive data of the 13 children with clinical examination.

	Modality	n
Sex	Male	4
	Female	9
Laterality	Right	7
	Left	6
Circumstances	Sports accident	5
	Road accident	5
	Home accident	3
Fracture type	I	6
	II	4
	III	1
	IV	2

## Results

Few complications were found over follow-up: one deep venous thrombosis and three cases of joint stiffness in the type-II fracture group. One of these three cases was lost to follow-up. Another underwent arthrolysis under general anesthesia and fully recovered joint amplitude. The 3rd showed normal knee mobility at one year's follow-up, but residual stiffness was unfortunately found when the patient was re-examined for the study. There were no cutaneous or infectious complications, no in-cast displacement, and no non-union.

## Subjective assessment

The 10 patients who mailed back the IKDC questionnaire had a mean score of 91 (range, 72–100). All resumed their pre-trauma sports activities. Mean FU was 14 years 11 months (range, 5–21 yrs).

Mean subjective IKDC score for the 13 patients who came to follow-up consultation was 80 (range, 36–100). Table 3 details these results. There were two outlying poor results, scoring 49 and 36: the first was a type-I case free of post-operative complication but with a high BMI of 33.6; the second (the lowest in the series) was the one type-II case not to have surgery. Two patients complained of anterior knee instability.

On ARPEGE evaluation, two patients were classified as sedentary – the two with the lowest subjective IKDC scores. Mean ARPEGE score was 8.3 (cf. Table 3).

## Objective results

Table 4 details the objective results. Mean follow-up was 9 years 7 months (range, 2–16 yrs). The IKDC clinical checklist scored four knees as A (normal), four as B (nearly normal), four as C (abnormal) and one as D (very abnormal).

**Table 3** Subjective results of the 13 children with clinical examination.

	Type I	Type II	Type III	Type IV
IKDC F	89 (49–100)	70 (36–99)	78	67 (62–72)
ARPEGE				
C	1	1	1	/
L	3	1	/	2
A	1	1	/	/
S	1	1	/	/
Stability	8.7	8.8	9.0	8.9
Pl & FR	8.5	6.5	9.0	8.0
Mobility	8.7	8.0	8.0	8.0
Mean	8.6	7.8	8.2	8.3

C: competition; L: leisure; A: active; S: sedentary. Pl: pain; FR: fatigue resistance.

**Table 4** Objective results of the 13 children with clinical examination.

	Type I	Type II	Type III	Type IV
IKDC O				
A	3	1	/	/
B	2	/	1	1
C	1	2	/	1
D	/	1	/	/
Total	6	4	1	2
KT 1000				
AD 7 Kg	0.67 (0–3)	1.00 (0–3)	1.00	0.00 (0–0)
AD 9 Kg	0.67 (0–3)	0.75 (0–2)	1.00	–0.50 (–1–0)
MMD	1.50 (0–7)	0.75 (0–2)	0.00	0.00 (0–0)
AQD	0.67 (–1–3)	0.75 (0–2)	0.00	–0.50 (–1–0)
MEAN	0.88	0.82	0.30	
Muscle Force	111.7% (66.7–166.7)	73.2% (35–100)	80%	70% (60–80)

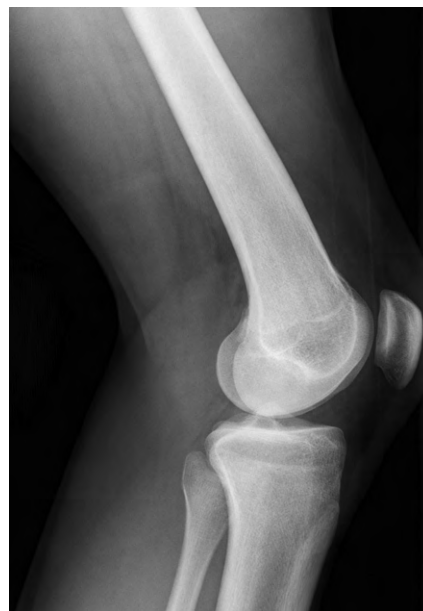AD: anterior drawer; MMD: maximum manual displacement; AQD: active quadriceps displacement.

Quadriceps force and mean ligamentary laxity data are presented in **Table 4**: the two patients complaining of anterior knee instability showed > 3 mm anterior laxity. Postoperative radiographic reduction evaluation classified 14 knees in group 1 (**Fig. 3**), 15 in group 2 and three in group 3. Groups 1 and 2 showed no significant difference in laxity; the three group-3 children (postoperative anatomic reduction >2 mm) who were tested all showed laxity.

## Overall results

Seven of the 13 patients re-examined had very satisfactory results. Five out of six type-I cases, one type-II and one type-III rated A or B on objective IKDC evaluation with subjective scores between 92 and 100 (maximum); mean IKDC score for this group was 97. The other six patients could be split into two groups.

The first comprised two type-II fractures and the two type-IV, and showed good recovery despite objective IKDC ratings of B or C, inasmuch as the subjective ARPEGE and IKDC assessments testified to sports activity and virtually unrestricted everyday activity. The patients judged their knees stable and resistant to effort, complaining simply of some moderate pain during sport.



**Figure 3** Lateral X-ray at the longest follow-up: age 18 years (i.e., 6 yrs FU).

The second group comprised one type-I fracture and one non-operated type-II. Final results were poor. Objective IKDC ratings were C and D respectively with subjective scores <50. These patients complained of pain and restricted everyday activity and estimated their functional recovery at not more than 50%; their subjective impression of knee instability was borne out by the KT 1000®.

## Discussion

Tibial eminence fracture is rare in children, but with incidence growing with increasing and earlier practice of at-risk sports [13]. Clinical examination and AP and lateral X-ray are usually sufficient for diagnostic purposes. In case of doubt, several authors [1,2] recommend MRI rather than arthroscore, which is more invasive and thus more aggressive for children. Management in the present series was in line with that usually reported in the literature [1,2,4,5,14]. The series was small, but with a mean FU of 14 years 11 months for the 10 patients who mailed back their IKDC questionnaires and of nine years 7 months for the 13 re-examined in consultation.

The KT1000® used to measure laxity found at least 1 mm difference in five of the 13 patients. Mean laxity difference was 0.88 mm in type-I fractures, 0.82 mm in type-II and 0.3 mm in types III and IV taken together. Only two patients showed pathological laxity of 3 mm or more on at least one measurement. According to Wiley and Baxter [3], residual laxity of 1–3 mm is acceptable, causing no long-term complications. Differential laxity was, paradoxically, less in severe fractures. The cases operated on (which showed the greatest displacements) showed a mean difference of 0.29 mm, versus 0.96 mm in cases managed conservatively. Such lower laxity differential in surgical cases was also reported by Iborra et al. [1] (1.5 mm vs. 1.9 mm). Other authors reported much greater differentials, especially in operated patients: Willis et al. [7] found a mean 3.5 mm residual laxity on KT1000® in type-II fractures and 4.5 mm in types III and IV (i.e., 64% of patients re-examined); only 18 of the 50 patients re-examined had undergone surgery, although there were 29 patients with type-III or IV fracture, which is classically managed by surgery, and 18 type-II for whom surgery was probably indicated. Janarv et al. [8], using a KSS® device, reported a 3 mm differential in types III and IV (38% of their series of 47 fractures, of which 20 type III or IV and 22 type II, only 11 of which were managed surgically). Wiley and Baxter [3], using a Genucom® arthrometer, found mean differentials of 3.5–4 mm in types III and IV: i.e., residual anterior laxity in 70% of patients re-examined; only 17 of the 45 patients were operated on, although there were 13 type-II cases and 24 type III or IV. Laxity results in these three studies were less good than in the present series, and it is noteworthy that they were also “less surgical”. The present results and a review of the literature are in favor of surgical management of displaced tibial eminence fracture, conservative treatment apparently giving poorer objective results. Admittedly, objective and subjective assessments do not necessarily correlate, and good short-to-medium term results may argue for a resolutely conservative attitude. We failed to find any very

long-term assessments in the literature, but it is generally agreed that residual anterior laxity may induce meniscal lesions and early arthritis in the long term; for this reason, we recommend surgery to reduce laxity. Some patients with objective IKDC ratings of B or C associated to differential laxity on KT1000® still practiced sport, sometimes at their pre-trauma level, without pain or perceived restriction. Several other studies confirm this non-correlation between subjective and objective estimates [1,3,7,8,15,17]. Some of the present patients reporting excellent results on the subjective IKDC questionnaire may have objectively rated B or C. Certain reports, in which subjective results are analyzed without reference to objective data, are therefore to be interpreted with caution: patients reporting good subjective results in the medium term may not necessarily do the same in the long term. The present study shows that, despite very satisfactory results for most patients, results were not always perfect on purely objective parameters.

Smith [15] found laxity not to correlate with quality of reduction, which seems discrepant with the present findings in which surgical cases with good-quality reduction showed less laxity than cases managed conservatively; it must, however, be said that residual laxity was low overall, except in two cases.

Many authors [1,4,13] consider knee laxity to be secondary to plastic deformation (stretching) of the anterior cruciate ligament (ACL) immediately prior to fracture. According to Grönkvist et al. [16], under-10 year-olds may show spontaneous correction of laxity over the growth period; the present series included too few such cases to shed light. Louis et al. [2] recommend hollowing out the tibial plate before surgically reinserting the tibial eminence, to restore ACL tension, thereby preventing residual laxity; this seems a logical trick, but we have no experience to report. The three group-3 children (reduction defect >2 mm) showed laxity, but no conclusion can be drawn from so small a number. On the other hand, no difference in laxity was found between groups 1 and 2 (anatomic reduction, and reduction defect <2 mm, respectively), which is not surprising as a reduction defect of less than 2 mm is unlikely as such to induce laxity.

Joint mobility was conserved in most series [2,5,7,15,17] or at least remained moderate [1,4]. Only Wiley et al. [3] reported systematic extension deficit (of 4° to 15°), but gave no convincing explanation for this. Aderinto et al. [14], in an adult series of 83 tibial eminence fractures at a mean 12 months (i.e., short) follow-up, found joint stiffness in 60% of cases managed surgically, versus only 19% of those managed conservatively. In the present series, with longer follow-up, there was only one case of flexion deficit (25° compared to the contralateral side), and one case lost to follow-up. Ipsilateral quadriceps force in the present series (91.6%) was comparable to the 96% reported by Janarv et al. [8].

Twelve of the 13 patients re-examined resumed their sports activity, half of them at the pre-trauma level. Certain authors [2,16,17] reported 100% resumption, although not always at the same level; others, such as De Courtivron et al. [4] or Willis et al. [7], reported rates (79 and 84%, respectively) comparable to the present.

## Conclusion

Tibial intercondylar eminence fracture in children may leave quantifiable residual anterior knee laxity despite well-conducted treatment. Paradoxically, the simpler forms, managed conservatively, showed the greatest differential laxity. It is, however, noteworthy that the associated medium-term functional impact was slight, with few subjective complaints. Surgical management induced few complications apart from a moderate esthetic blemish. Surgical indications may therefore reasonably be extended to moderately displaced fractures, to obtain optimal objective results. Although subjective and objective assessments do not seem to correlate, reducing differential laxity may provide long-term benefit.

## Conflict of interest

None.

## References

- [1] Iborra JP, Mazeau P, Louahem D, Diméglio A. Fractures de l'éminence intercondylaire du tibia de l'enfant : à propos de 25 cas avec un recul moyen de 1 à 20 ans. *Rev Chir Orthop* 1999;85:563–73.
- [2] Louis ML, Guillaume JM, Launay F, Toth C, Jouve JL, Bollini G. Surgical management of type II tibial intercondylar eminence fractures in children. *J Pediatr Orthop B* 2008;17:231–5.
- [3] Wiley JJ, Baxter MP. Tibial spine fractures in children. *Clin Orthop Rel Res* 1990;255:54–60.
- [4] De Courtivron B, Mauny C. Les fractures des épines tibiales. *Ann Orthop Ouest* 1996;28:180–3.
- [5] Rademakers MV, Kerkhoffs J, Kager J, Goslings JC, Marti RK, Raaymakers B. Tibial spine fractures: a long-term follow-up study of open reduction and internal fixation. *J Orthop Trauma* 2009;23:203–7.
- [6] Owens BD, Plante T, Busconi BD. Intercondylar eminence fractures. *eMedicine Orthopedic Surgery*, 2009 <http://emedicine.medscape.com/article/1249302>.
- [7] Willis RB, Blokker C, Stoll TM, Paterson DC, Galpin RD. Long term follow-up of anterior tibial eminence fractures. *J Pediatr Orthop* 1993;13:361–4.
- [8] Janarv PM, Westblad P, Johansson C, Hirsch G. Long-term follow-up of anterior tibial spine fractures of children. *J Pediatr Orthop* 1995;15:63–8.
- [9] Millerand RK, Carr A. The knee. In: Pynset P, Fairbank J, editors. Carr A: outcome measures in orthopaedics. Butterworth Heinemann; 1993. p. 228–43.
- [10] Meyers MH, McKeever FM. Fractures of the intercondylar eminence of the tibia. *J Bone Joint Surg (Am)* 1959;41:209–22.
- [11] Zaricznyj B. Avulsion fracture of the tibial eminence: treatment by open reduction and pinning. *J Bone Joint Surg (Am)* 1970;59:1111–4.
- [12] Christel P, Djian P, Darman Z, Witvoët J. Étude des résultats de l'intervention de Marshall-Macintosh selon trois systèmes d'évaluation (ARPEGE, Lysholm, IKDC). 90 cas revus avec un recul d'au moins un an. *Rev Chir Orthop* 1993;79:473–83.
- [13] Bergerault F, Le Carrou T, De Courtivron B, Bonnard C. Entorses du genou. In: Fractures de l'enfant, Monographie du GEOP, Sauramps Médical, Montpellier, 2002. p. 237–45.
- [14] Aderinto J, Walmsley P, Keating JF. Fractures of the tibial spine: Epidemiology and outcome. *The Knee* 2008;15:164–7.
- [15] Smith JB. Knee instability after fractures of the intercondylar eminence of the tibia. *J Pediatr Orthop* 1984;4:462–4.
- [16] Grönkvist H, Hirsch G, Johansson L. Fracture of the anterior tibial spine in children. *J Pediatr Orthop* 1984;4:465–8.
- [17] Ahn JH, Yoo JC. Clinical outcome of arthroscopic reduction and suture for displaced acute and chronic tibial spine fractures. *Knee Surg Sports Traumatol Arthrosc* 2005;13:116–21.