

# Anterior Cervicothoracic Approach to the Superior Sulcus for Radical Resection of Lung Tumor Invading the Thoracic Inlet

Philippe Dartevelle and Sacha Mussot

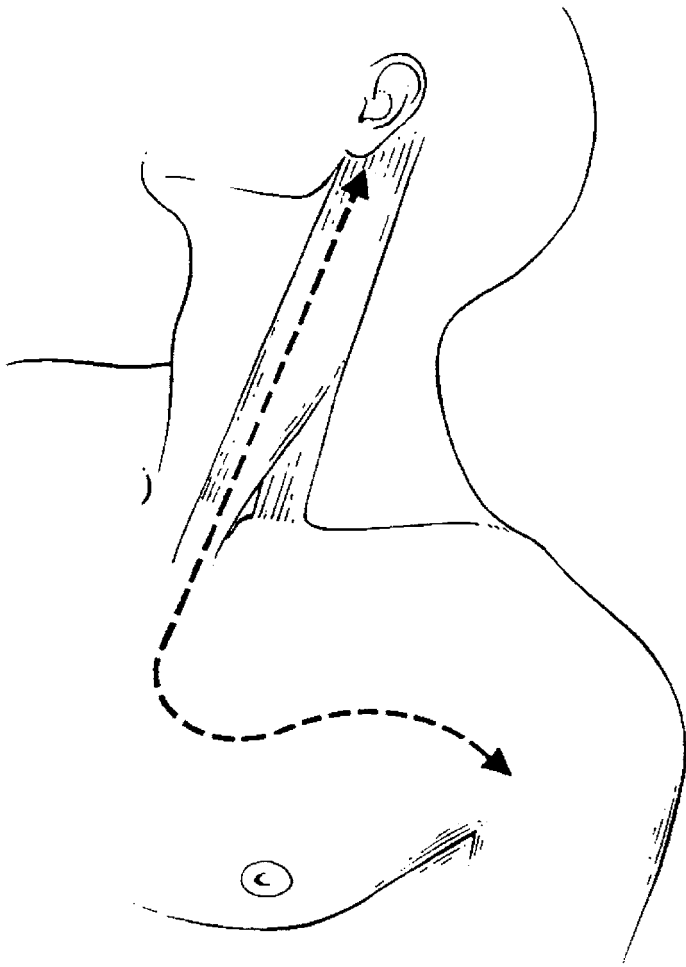
**T**he anterior cervicothoracic approach to the thorax is used for radical resection of superior sulcus tumors invading the thoracic inlet. These tumors are small sized neoplasms situated at a definite location of the thoracic inlet that evoke a characteristic clinical picture called Pancoast-Tobias syndrome.<sup>1-4</sup> The local nerve and bone involvement produces this syndrome at an early stage of the disease, generally before the mass is well defined radiographically, and lymphatic and distant metastasis occurs.<sup>1,5</sup>

For many years, these tumors were considered inoperable, and treatment consisted of palliative radiation therapy. However, during the last few decades, it became evident that the best treatment is the combination of preoperative radiation therapy (30 Gy) followed by surgical resection.<sup>1,6-12</sup> As reported by Shaw and colleagues, the preferred surgical procedure consists of an extended en bloc resection of the chest wall (usually including posterior portions of the first 3 ribs and the transverse processes), the intercostal nerves, the lower trunk of the brachial plexus together with the involved lung, resected usually with lobectomy or segmental re-

section, performed with a posterior interscapulo-vertebral approach.<sup>6</sup> This combined treatment modality usually results in long-term survival (ie, 5-year rates approximately 30% to 34%) and cure for select patients.<sup>6-12</sup> The presence of positive mediastinal lymph nodes and extensive vertebral body, brachial plexus, and subclavian vascular invasion represent poor prognostic factors and, thus, contraindications for surgical resection.<sup>2,7,12-14</sup>

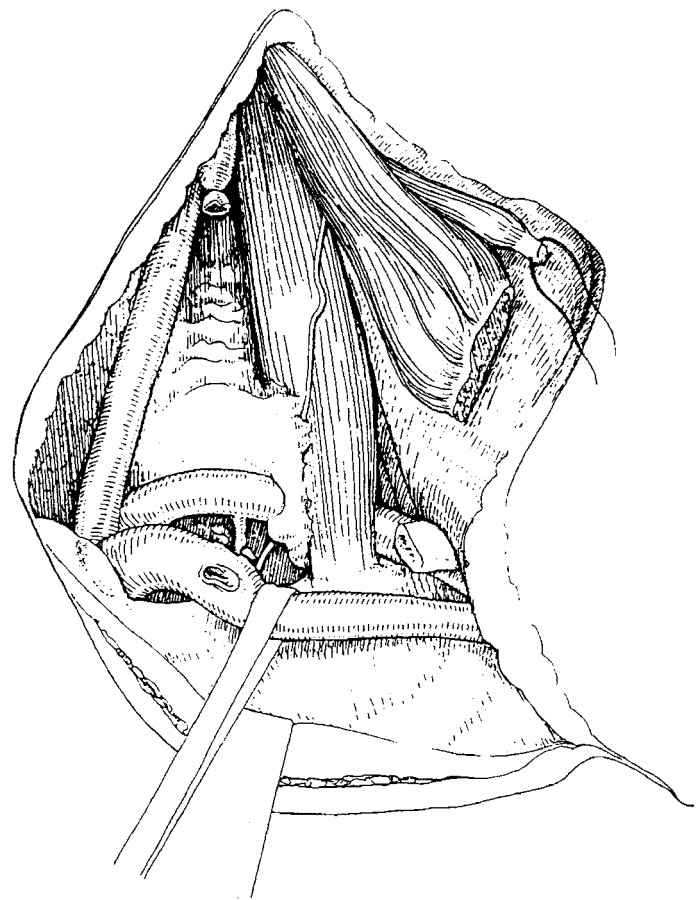
Several years ago, we described a combined cervicothoracic approach for resection of apical lesions invading the thoracic inlet.<sup>15,16</sup> During the course of our 15-year experience with the transclavicular approach, we have learned how to perform the entire resection with a single anterior approach, provided some modifications and improvements to our initial technique. We describe the procedure as we presently perform it routinely, including technical modifications we made to resect the upper lobe along with the invaded bony, vascular<sup>17</sup> and soft tissues with the cervical approach alone, without complementary thoracotomy.

## SURGICAL TECHNIQUE

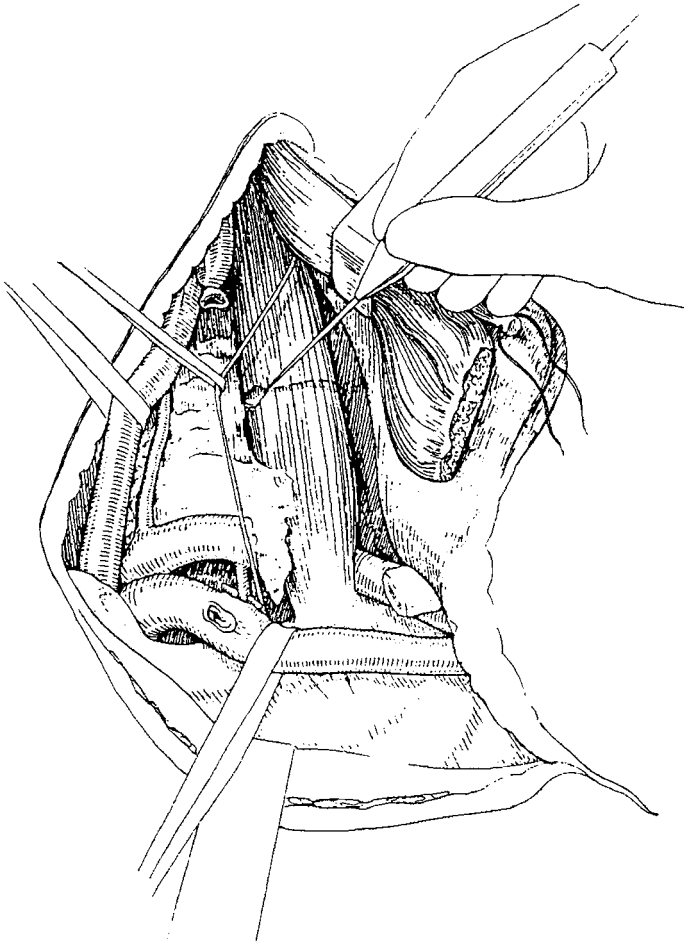


**1** The patient is placed in the supine position with the neck hyperextended, and the head is turned away from the involved side. A bolster is placed behind the shoulder to elevate the operative field. The skin preparation extends from the mastoid downwards to the xiphoid process, and from the middle axillary line laterally to the contralateral hemiclavicular line. An adhesive plastic draping is then placed over the skin.

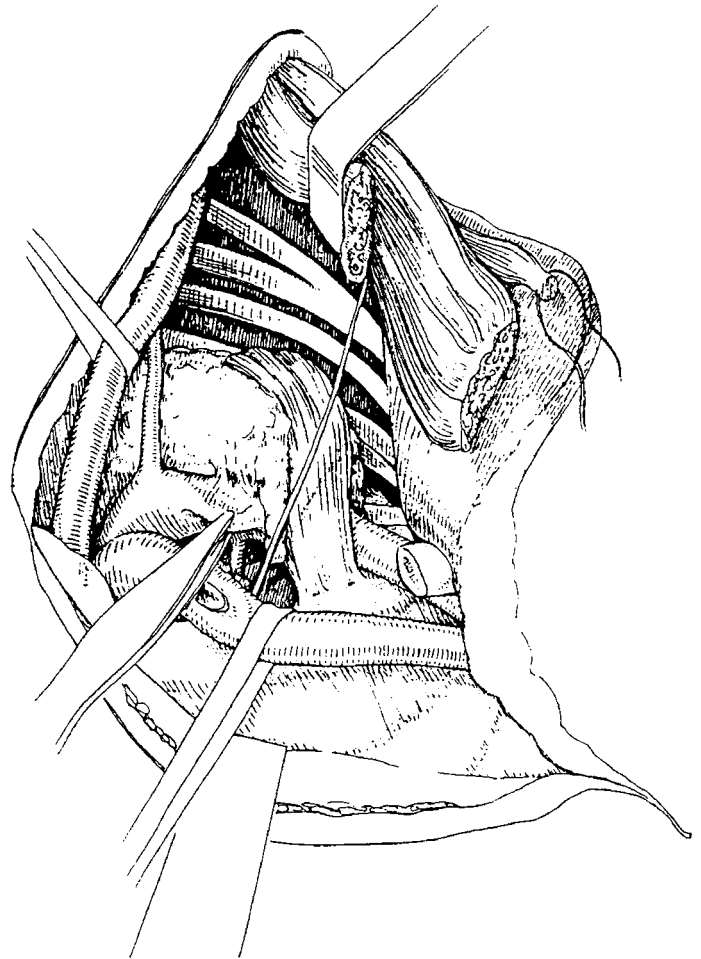
An L-shaped incision cervicotomy is performed and includes a vertical presternocleidomastoid incision prolonged horizontally below the clavicle up to the delto-pectoral groove. However, to increase the exposure and make the entire resection through this incision only, interception between the vertical and horizontal branches of the L-shaped incision is lowered at the level of the second or third intercostal space. The incision is then deepened with cautery. The sternal attachment of the sternocleidomastoid muscle is divided. The cleidomastoid muscle, along with the upper muscle fibers of the major pectoralis muscle, is scraped from the clavicle, creating a well-vascularized myocutaneous flap that when folded back, gives full exposure of the neck, thoracic inlet, and upper part of the anterolateral chest wall. Once the inferior belly of the omohyoid muscle is transected, the scalene fat pad is dissected and pathologically examined to exclude scalene lymph node micrometastasis. Inspection of the ipsilateral superior mediastinum is then made by the surgeon's finger along the lateral aspect of the tracheoesophageal groove. Tumor extension to the thoracic inlet is then carefully assessed. We recommend resection of the internal half of the clavicle only if the tumor is considered resectable.




**2** Once the sternal head of the sternocleidomastoid and the inferior belly of the omohyoid muscles have been divided, and the scalene fat pad and the internal half of the clavicle have been resected, the exposure, dissection, and division of the external and internal jugular vein significantly facilitates the exposure of the subclavian vein and permits the assessment of tumor resectability. The jugular veins are first dissected so that branches to the subclavian vein can eventually be divided. On the left side, ligation of the thoracic duct is usually required. Division of the distal part of the internal, external, and anterior jugular veins makes visualization of the venous confluence at the origin of the innominate vein easier. Do not hesitate to suture-ligate the internal jugular vein to increase the exposure to the subclavian vein. If the subclavian vein is involved, it can be easily resected after its proximal and distal control has been achieved. Tumor direct extension to the innominate vein does not preclude resection.



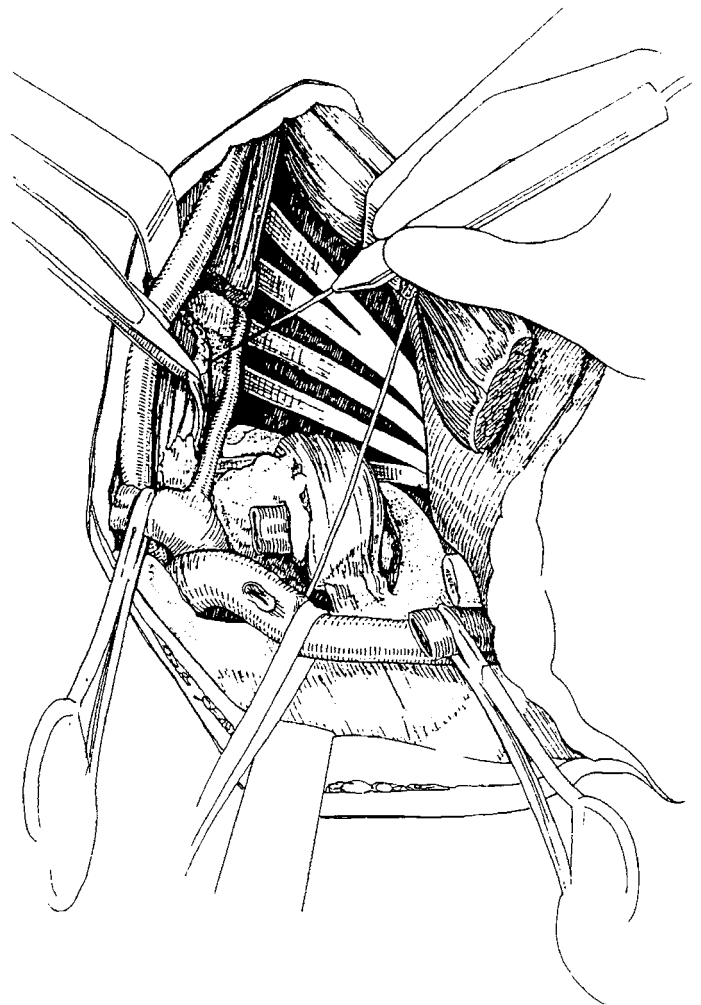
**3** Next, the scalenus anterior muscle is divided either on its insertion on the scalene tubercle on the first rib or in tumor-free margins with cautery. If the tumor has invaded the upper part of this muscle, it needs to be divided at insertion on the anterior tubercles of the transverse processes of C3 through C6. Before dealing with the anterior scalenus muscle, the status of the phrenic nerve is carefully assessed because its unnecessary division has a deleterious influence on the postoperative course. It should be preserved whenever possible.



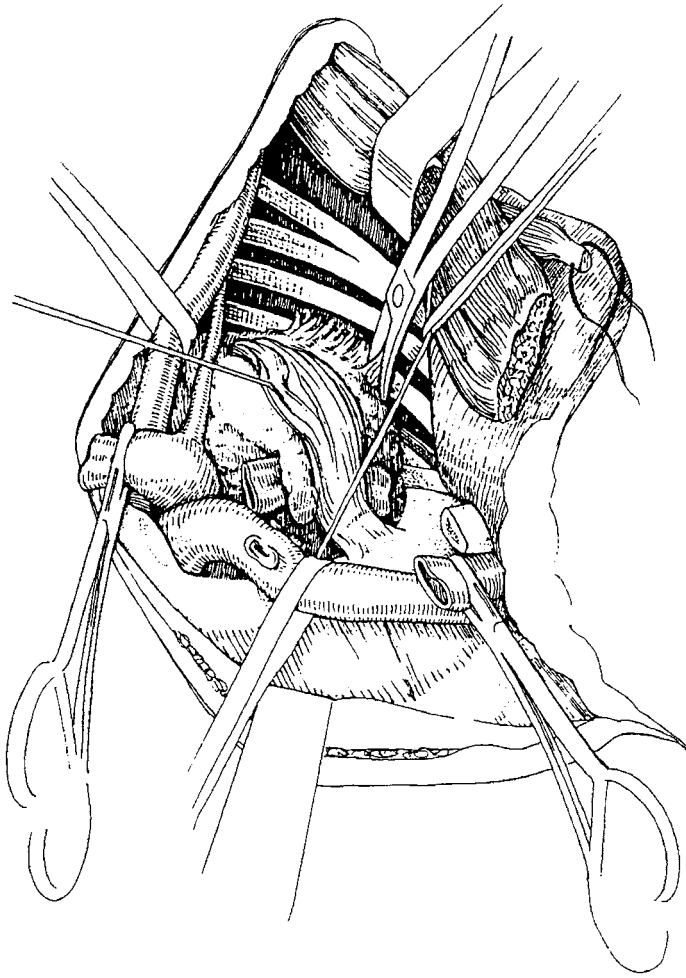
**4** To improve immobilization of the subclavian artery, its branches are divided. The vertebral artery is resected only if invaded and provided that no significant extracranial occlusive disease was detected on preoperative Doppler ultrasound. If the tumor rests against the wall of the subclavian artery, the artery can be freed following a subadventitial plane.



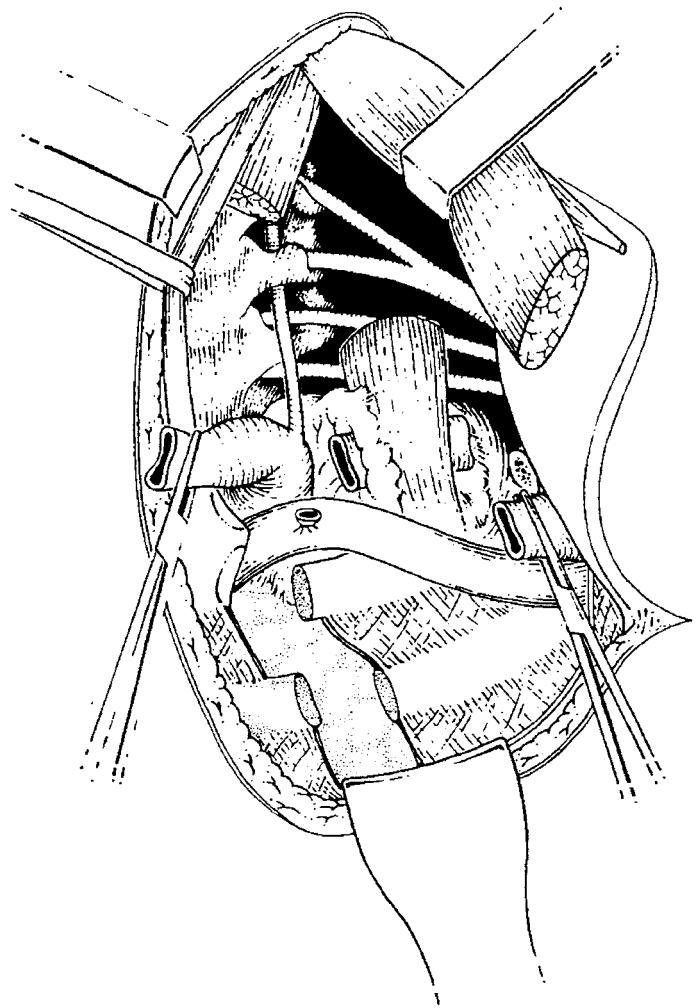
**5** If there is invasion of the arterial wall, resection of the artery to obtain tumor-free margins is necessary. After cross-clamping it proximally and distally, the artery is divided on either side. Revascularization is performed with end-to-end anastomosis or less frequently with a polytetrafluoroethylene ringed graft (i.e., 6 or 8 mm). During these maneuvers, the pleural space might be opened by dividing the Sibson fascia, which is a fascia on the deep surface of the scalenus muscles forming a subpleural membrane arching over the cupula of the pleura. The middle scalenus muscle is divided above its insertion on the first rib or higher, as indicated by the extension of the tumor. It might require, especially for apical tumors invading the middle compartment of the thoracic inlet, division of its insertions on the posterior tubercles of the transverse processes of the second through seventh cervical vertebrae. The nerve roots of C8 and T1 are then easily identified and dissected in an out to inside fashion until they converge to form the lower trunk of the brachial plexus.



**6** Thereafter, the prevertebral muscles are systematically and en bloc detached along with the dorsal sympathetic chain and stellate ganglion from the anterior surface of the vertebral bodies of C7 and T1. This procedure permits visualization of the intraspinal foramina. The T1 nerve root is usually divided beyond the visible tumor, just lateral to the T1 intraspinal foramen.

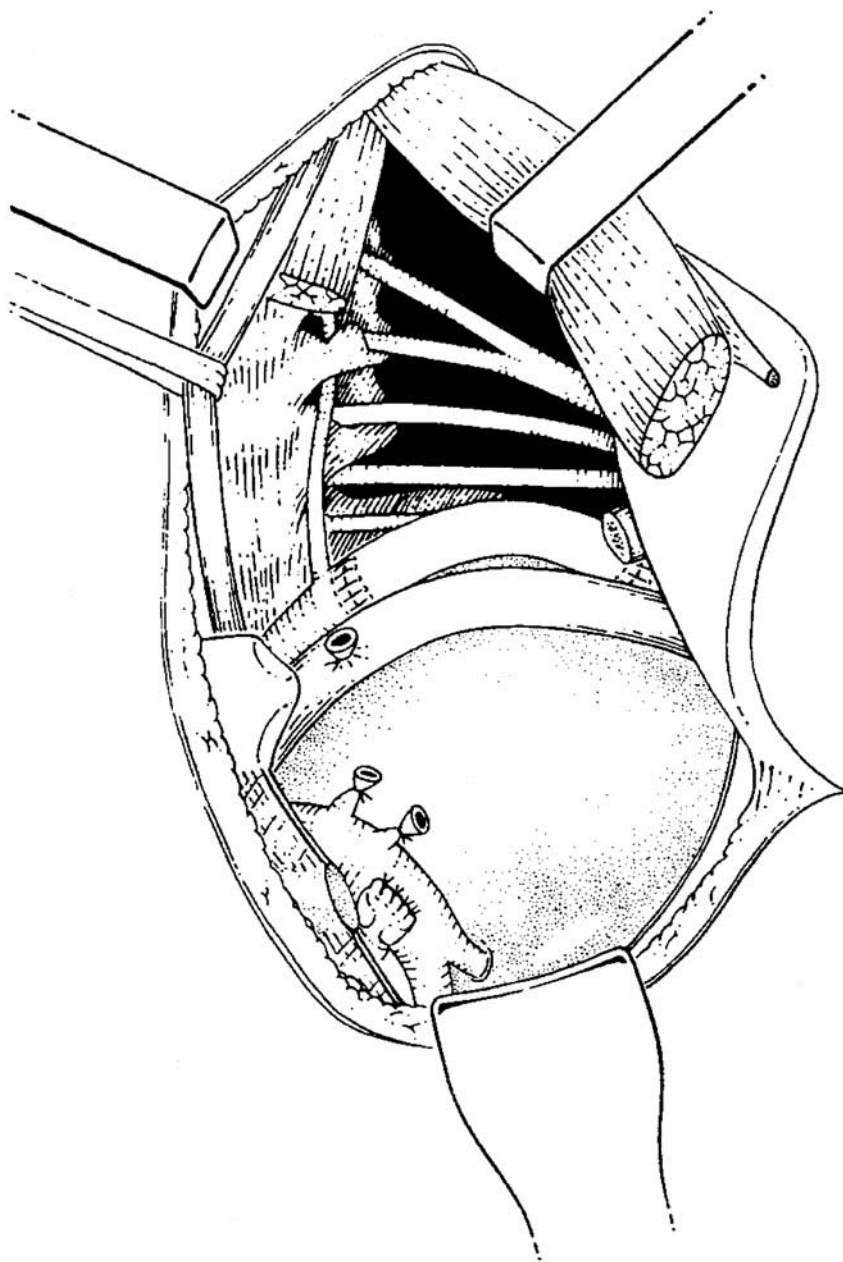


**7** Although tumor spread to the brachial plexus may be high, neurolysis is usually achieved without division of the nerve roots above T1. Damage of the lateral and long thoracic nerves should be avoided because this may result in winged scapula.

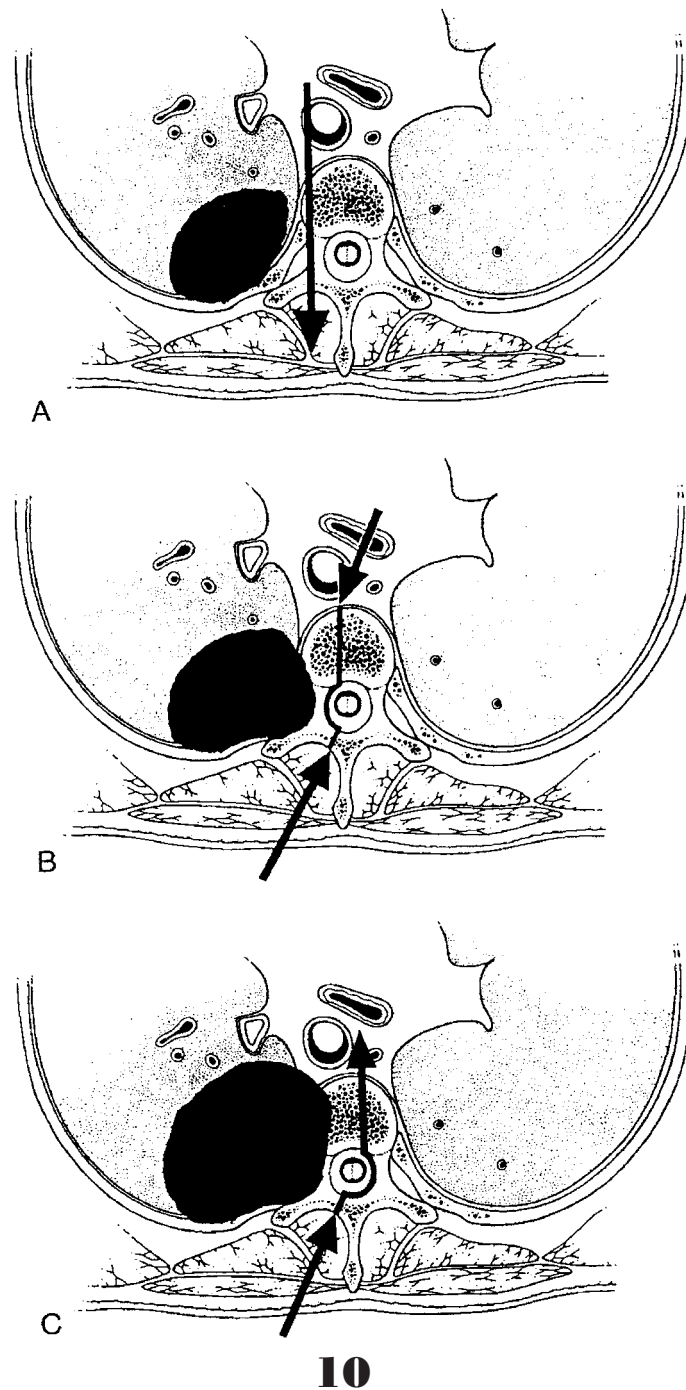


**8** Before performing pulmonary resection, the chest wall resection is completed. The anterolateral arch of the first rib is divided at the costochondral junction, while the second rib is divided at the level of its middle arch, and the third is scraped on the superior border towards the costovertebral angle. The specimen is then progressively freed, and the first ribs are disarticulated from the transverse processes of the first 2 or 3 thoracic vertebrae.





**9** It is through this hole created with bony resection that the operation is completed by performing en bloc the upper lobectomy. With more experience, we favored upper lobectomy rather than limited resection.



A. Tumors involving transverse processes can be resected with the anterior approach. The maneuver is similar to what is used with the posterior approach but from the front to the back, with a finger placed behind the transverse process of T1 and T2 to give the correct direction of the chisel. We recommend maintaining meticulous hemostasis throughout the procedure to ensure clear visual exposure at all times, and careful inspection and verification of all vascular structures previously resected or ligated to prevent postoperative hemorrhage and lymphatic leakage. The cervical incision is closed in 2 layers after sternal insertion of the sternocleidomastoid muscle is sutured and a conventional drainage of the ipsilateral chest cavity is placed.

B. A limitation of the surgery for apical tumors is the spread of the tumor to the vertebral body, as mainly seen in posteriorly located apical lesions.

C. One should not resect tumors extending inside the spinal canal but only those abutting the costovertebral angle or extending into the intraspinal foramen without intraspinal extension. Two approaches must be combined to perform hemivertebrectomy (usually T1 to T3), followed by spinal fixation with metal rods interposed between screws placed into the vertebral pedicles. The cervical anterior approach is started first to (1) assess operability, (2) safely dissect the anterolateral aspects of the invaded vertebra(e) in tumor-free margins to be subsequently individualized from the posterior approach, and (3) perform lobectomy and the anterior section of the chest wall, as described previously. After completing this anterior approach, the patient is placed in a ventral position, and a median vertical incision is performed at the level of the cervicothoracic junction. Following unilateral laminectomy on 3 levels, the nerve roots are divided inside the spinal canal at the emergence of the external sheath covering the spinal cord. After cutting the vertebral bodies on the middle part, the specimen is resected en bloc with the lung, ribs, and vessels through this midline posterior incision. On the side of the tumor, spinal fixation is performed in the pedicle above and below resection of hemivertebrae; on the contralateral side, there is a screw in each pedicle.

## COMMENTS

The surgical complications for patients undergoing resection of apical tumors are similar to any patient undergoing a major pulmonary resection.<sup>17</sup> However, specific complications are (1) spinal fluid leakage, (2) Horner syndrome and nerve deficits, (3) hemothorax, and (4) chylothorax. During the last 20 years, 70 patients (mean age  $53 \pm 12$  years) presenting with malignant, bronchogenic apical lesions were treated with this approach. The majority of the lesions were nonsmall-cell histology ( $n = 51$ ), right-sided ( $n = 41$ ), and extending to the anterior ( $n = 23$ ), middle ( $n = 5$ ), or posterior ( $n = 42$ ) compartments of the thoracic inlet. All tumors were completely resected with the anterior approach, either alone ( $n = 33$ ) or with ( $n = 37$ ) an additional posterior approach, early on in our experience. A total of 47 lobectomies, 21 wedge resections, and 2 pneumonectomies were performed. The majority ( $n = 55$ ) of the patients were without pathologic diseased lymph nodes, while 5, 7, and 3 had N1, N2, or N3 disease, respectively. The 28 invaded subclavian arteries were revascularized 16 times with a synthetic graft and 12 with end-to-end anastomosis; 9 vertebral arteries were also invaded and resected. The T1 nerve root was invaded either alone ( $n = 25$ ) or along with the phrenic nerve ( $n = 21$ ). The first rib was invaded and resected in all patients either alone ( $n = 8$ ) or with the second ( $n = 29$ ), third ( $n = 17$ ), fourth ( $n = 15$ ), and fifth ( $n = 1$ ) ribs. There were no hospital deaths. The overall 5 and 10-year survival rates were 35% and 20%, respectively, and the only predictor of long-term, disease-free survival was the presence of N2 disease. The 2-year survival rate for 13 patients who underwent hemivertebrectomy was 59%.

## REFERENCES

1. Pancoast HK: Superior sulcus tumors. *JAMA* 99:1391, 1932
2. Paulson DL: The importance of defining location and staging of superior pulmonary sulcus tumors. *Ann Thorac Surg* 15:549, 1973
3. Teixeira JP: Concerning the Pancoast tumor: What is the superior pulmonary sulcus? *Ann Thorac Surg* 35:577, 1983
4. Tobias JW: Síndrome apico-costal-vertebral-doloroso por tumor apical: Su valor diagnóstico en el cáncer primitivo del pulmón. Tese, Imp. Mercatali, Buenos Aires, 1931
5. Shahian DM, Wildford BN, Ellis FH Jr: Pancoast tumors: Improved survival with preoperative and postoperative radiotherapy. *Ann Thorac Surg* 43:32, 1987
6. Shaw RR, Paulson DL, Kee JL Jr: Treatment of the superior sulcus tumor by irradiation followed by resection. *Ann Surg* 154:29, 1961
7. Paulson DL: *General Thoracic Surgery*. Philadelphia, PA, Lea & Febiger, 1989
8. Miller JL, Mansour KA, Hatcher CR: Carcinoma of the superior pulmonary sulcus. *Ann Thorac Surg* 28:44, 1979
9. Attar S, Miller JE, Satterfield J, et al: Pancoast's tumor: Irradiation or surgery? *Ann Thorac Surg* 28:578, 1979
10. Standford W, Barnes RP, Tucker AR: Influence of staging in superior sulcus (Pancoast) tumors of the lung. *Ann Thorac Surg* 29:406, 1979
11. Devine JW, Mendenhall WM, Million RR, et al: Carcinoma of the superior pulmonary sulcus treated with surgery and/or radiation therapy. *Cancer* 57:941, 1986
12. Paulson DL: Carcinomas in the superior pulmonary sulcus. *J Thorac Cardiovasc Surg* 70:1095, 1975
13. Anderson TM, Moy PM, Holmes EC: Factors affecting survival in superior sulcus tumors. *J Clin Oncol* 4:1598, 1985
14. Pancoast HK: Importance of careful roentgen-ray investigations of apical chest tumors. *JAMA* 83:1407, 1924
15. Darteville P, Chapelier A, Macchiarini P, et al: Anterior transcervical-thoracal approach for radical resection of lung tumors invading the thoracic inlet. *J Thorac Cardiovasc Surg* 105:1025, 1993
16. Macchiarini P, Darteville P, Chapelier A, et al: Surgical management of non-bronchogenic tumors invading the thoracic outlet. *Ann Thorac Surg* 55:611, 1993
17. Fadel E, Chapelier A, Cerrina J, et al: Subclavian artery and reconstruction for thoracic inlet cancers. *J Vasc Surg* 28:581, 1999

---

From the Department of Thoracic and Vascular Surgery and Heart-Lung Transplantation, Marie-Lannelongue Hospital (Paris-Sud University), Le Plessis Robinson, France.

Address reprint requests to Philippe Darteville, MD, Department of Thoracic and Vascular Surgery and Heart-Lung Transplantation, Marie-Lannelongue Hospital (Paris-Sud University), 133 Av. de la Resistance, F-92350 Le Plessis Robinson, France; e-mail: phdart@wanadoo.fr.

© 2003 Elsevier Inc. All rights reserved.  
 1522-2942/03/0802-0000\$30.00/0  
 doi:10.1053/S1522-9042(03)00029-3