

Airway Remodeling in Asthma

Yuki Sumi¹ and Qutayba Hamid¹

ABSTRACT

Airway remodeling can be defined as changes in the composition, content, and organization of the cellular and molecular constituents of the airway wall. Airway remodeling is a characteristic feature of asthma, and has important functional implications. These structural changes include epithelial detachment, subepithelial fibrosis, increased airway smooth muscle (ASM) mass, decreased distance between epithelium and ASM cells, goblet cell hyperplasia, mucus gland hyperplasia, proliferation of blood vessels and airway edema and changes in the cartilage. Each can contribute to airway hyperreactivity (AHR), and may eventually lead to irreversible airflow obstruction with disease progression.

Structural changes can be observed from early onset of the disease and thus remodeling is thought to be characteristic of asthma. Some aspects of airway remodeling can be explained as a consequence of TH2 inflammation, although it has also been suggested that the exaggerated inflammation and remodeling seen in asthmatic airways is the consequence of abnormal injury and repair responses stemming from the susceptibility of bronchial epithelia to components of the inhaled environment. According to this view, remodeling occurs by way of a noninflammatory mechanism, where inflammation of airways and altered structure and function of the airways are parallel and interacting factors.

Airway remodeling in established asthma is poorly responsive to current therapies, such as inhalation of corticosteroids and administration of β 2-agonists, antileukotrienes, and theophylline.

KEY WORDS

airway hyperreactivity, airway inflammation, airway remodeling, Asthma, review

INTRODUCTION

Asthma is characterized by inflammation of the airway wall, variable airway limitation and/or airway hyperreactivity (AHR). Characteristic structural changes in the airways of asthma patients, described as airway remodeling, are related to the severity of the disease. These structural changes include epithelial detachment, subepithelial fibrosis, increased airway smooth muscle (ASM) mass, decreased distance between ASM and epithelium, mucous gland and goblet cell hyperplasia, proliferation of blood vessels, and development of airway edema.

Historically, asthma is defined as a chronic inflammatory disorder of airways in which many cells play a role. Some aspects of airway remodeling can be explained as a consequence of TH2 inflammation, and until recently, airway remodeling has only been thought of as a secondary phenomenon, representing a repair response to inflammation and developing late in the disease process as a consequence of persistent

inflammation.

Recent studies, however, have shown that airway remodeling is observed from early onset of the disease and may, therefore, be characteristic of asthma. Morphometry has revealed that airway remodeling of asthmatic airways accounts for a large component of AHR and excessive airway narrowing. Since remodeling processes occur in parallel to, or may even be obligatory for, the establishment of persistent inflammation, the pathogenesis of airway remodeling and the implications of therapeutic interventions that are designed to diminish airway remodeling remain important areas of research. Although there is some evidence that points to the development of promising therapeutic strategies, particularly in relation to cysteinyl leukotrienes, the efficacy of existing anti-asthma therapies for the treatment of airway remodelling continues to be debated.

¹Meakins-Christie Laboratories, McGill University, Montreal, Québec, Canada.

Correspondence: Dr. Qutayba Hamid, Meakins-Christie Laboratories, 3626 St. Urbain Street, Montréal H2X2P2, Québec Canada.

Email: qutayba.hamid@mcgill.ca

Received 2 July 2007.

©2007 Japanese Society of Allergology

AIRWAY REMODELING

EPITHELIAL DETACHMENT

Epithelial detachment is a characteristic feature of airway remodeling (Fig. 1),¹ although it is not uncommon to find epithelial detachment in bronchial biopsy specimens from healthy subjects.² However, epithelial detachment has also been observed in postmortem studies and increase in epithelial cell has been reported in bronchoalveolar lavage (BAL) and sputum analysis, suggesting that it is not merely an artifact.^{3,4} Using TUNEL and p85 PARP staining, it has been shown that bronchial epithelial cells in patients with asthma undergo more apoptosis than do epithelial cells in normal controls.^{5,6} Epithelial damage may, in part, be a consequence of ongoing inflammation^{6,7} or mechanical stress caused by bronchoconstriction,⁸ but also may reflect host susceptibility factors.^{5,9} Re-

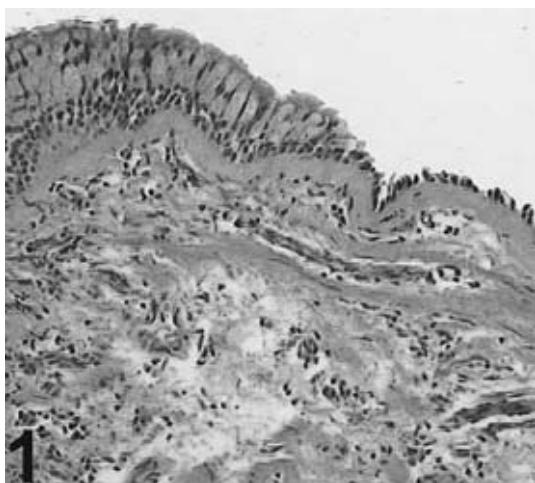


Fig. 1 Epithelial detachment is a characteristic feature of airway remodeling.

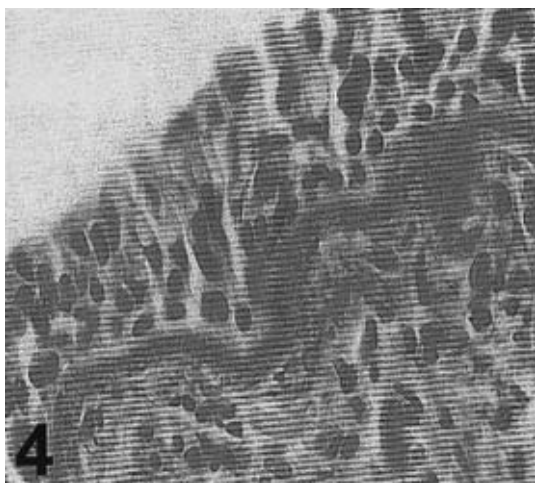


Fig. 2 Subepithelial fibrosis from patient with mild asthma (Van Gieson stainin)

cent studies suggest a change in the phenotype of epithelial cells in asthmatic subjects and an increase in the ability of these cells to produce cytokines, chemokines, and profibrotic growth factors.¹⁰

SUBEPITHELIAL FIBROSIS

Subepithelial fibrosis is an important feature of airway remodeling that can range from simple thickening (Fig. 2) to extensive fibrosis (Fig. 3). In asthmatics, the true basement membrane is of normal appearance on electron microscopic examination.¹¹ Beneath this layer, in control subjects, there is a loose array of collagen fibrils. In contrast, in asthmatic subjects, this layer is replaced by a dense network of collagen fibrils.¹¹ Fibrosis of this sort is due to increased deposition of extracellular matrix, particularly collagen type I and III, fibronectin, and proteoglycans. This increased deposition of extracellular matrix is due to fibroblast activation,¹¹ a result of upregulation of a number of cytokines and growth factors, such as tumor growth factor beta (TGF- β) and interleukin 11 (IL-11), which are produced by both structural cells and inflamed cells, particularly eosinophils.

INCREASE IN AIRWAY SMOOTH MUSCLE MASS

An increase in airway smooth muscle (ASM) mass is a common observation in asthmatic airways,¹² and can be demonstrated in endoscopic biopsy specimens (Fig. 4). There is little doubt that an increase in ASM mass in the airways of asthmatic patients is comprised, in part, by hyperplasia.¹³⁻¹⁶ Increases in ASM cell number might occur through increased rates of division,¹⁷ decreased rates of apoptosis¹⁸ or, more speculatively, through migration of mesenchymal cells to ASM bundles.¹⁹⁻²⁴

One reason why ASM cells in asthma patients proliferate faster than cells from nonasthmatic patients may be a result of stimulation of ASM by mitogenic

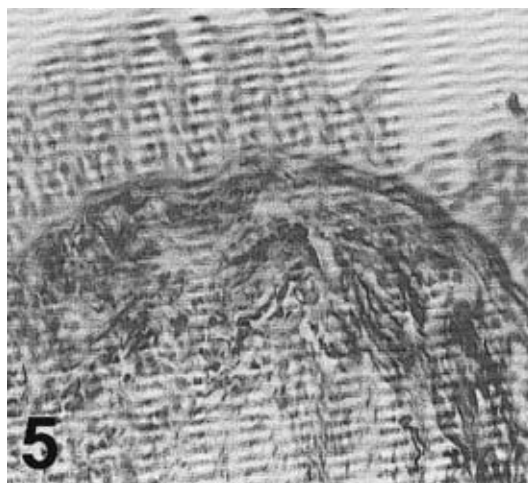


Fig. 3 Subepithelial fibrosis from patient with severe asthma (Van Gieson stainin)

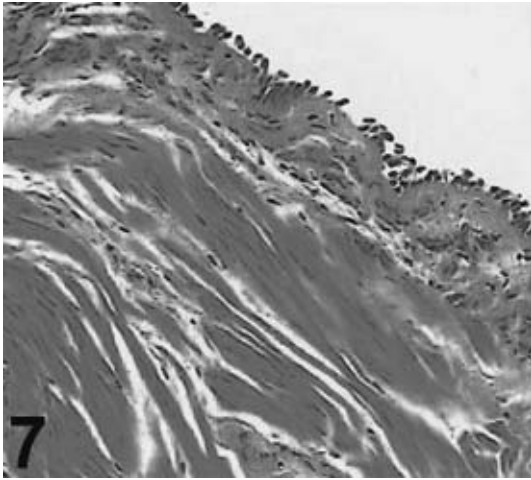


Fig. 4 Increases in smooth muscle mass could be demonstrated in endoscopic biopsy specimens, particularly in those from patients with severe asthma. Smooth muscle cells could be demonstrated in close proximity to epithelial cells

or inflammatory stimuli. To date, mitogenic stimuli that have been identified include TGF- β , EGF, IGF, PDGF isoforms, FGF-2, β -hexosaminidase, β -glucuronidase, α -thrombin, tryptase, sphingosine 1-phosphate, endothelin-1, substance P, phenylephrine, serotonin, thromboxane A₂, leukotriene D₄, mechanical stress and reactive oxygen species (ROS).²⁵ The other explanation may be that the profile of extracellular matrix protein components is altered in asthmatic cells and this altered profile may have the potential to influence the proliferation of these cells.²⁶ Moreover, one recent study has shown that ASM cells cultured from biopsies from patients with asthma lack the transcription factor C/EBP α that inhibits proliferation, whereas this is not seen in control cases.²⁷

Hypertrophy is defined as the increased size of constituent cells and there are conflicting reports as to the significance of increased ASM mass stemming from hypertrophy. Autopsy and airway biopsy studies have led to varying conclusions regarding the manifestation of hypertrophy in larger airways. It has been shown that cell diameters are increased in some of asthmatics across the whole airway²⁸ and in proximal airways of patients with severe persistent asthma.²⁹ In these studies, hypertrophy is defined as increased width of smooth muscle cells, and results may be subject to artifacts associated with shortening. On the other hand one group, using a stereologic approach, did not find evidence of ASM hypertrophy in bronchial biopsies of patients with mild to moderate asthma.³⁰ It has been suggested that increased levels of stretch, TGF- β , IL-1 β and cardiotrophin may be hypertrophic influences on human ASM.³¹

Airway smooth muscle cells in asthmatic patients

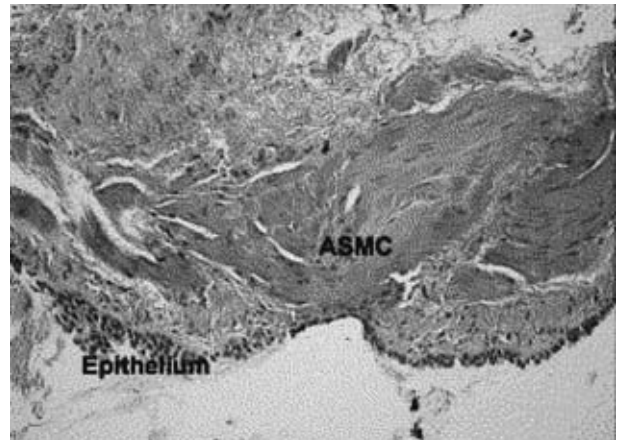


Fig. 5 Hematoxylin and eosin preparation from a biopsy specimen of an asthmatic subject shows smooth muscle bundles close to the epithelium.

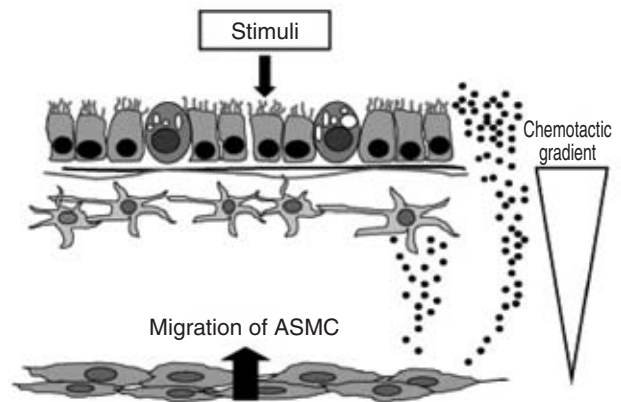


Fig. 6 Model representing the migration of ASM cells toward the epithelium, possibly mediated by chemokines.

can be seen in close proximity to epithelial cells (Fig. 5). This may result from conversion of mesenchymal cells to ASM cells or migration of ASM cells toward the epithelium (Fig. 6).³² Whether or not this phenomenon occurs *in vivo* remains unknown.

CHANGE OF AIRWAY SMOOTH MUSCLE CELLS

There is strong evidence to suggest that smooth muscle cells in asthma can act as inflammatory cells through their increased capacity to produce chemokines and cytokines³³ (Fig. 7). Airway remodeling may be a result of the action of some of these secreted inflammatory mediators.

Emerging evidence also suggests ASM contraction *per se* is changed in asthmatic airways by the inflammatory milieu.³⁴

MUCUS GLAND AND GOBLET CELL HYPERPLASIA

An additional feature of airway remodeling is in-

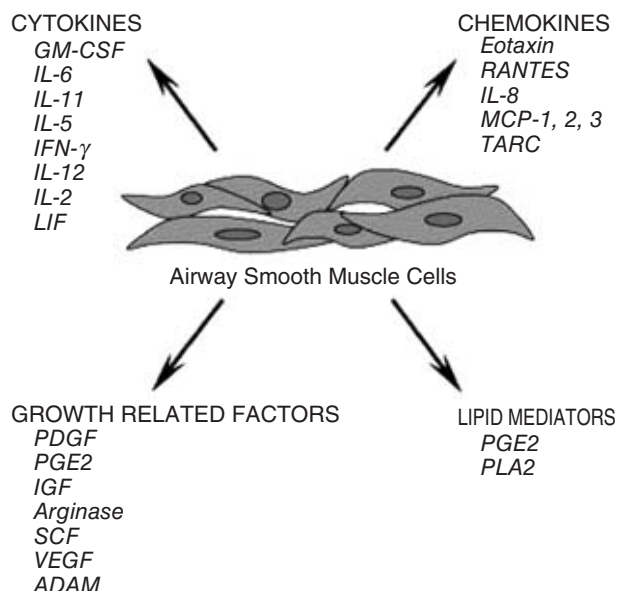


Fig. 7 ASMCs express a wide variety of mediators involved in asthma pathogenesis, including cytokines, chemokines, growth factors, and lipid mediators. LIF, leukocyte inhibitory factor; TARC, thymus- and activation-regulated chemokine; PDGF, platelet-derived growth factor; PGE2, prostaglandin E2; SCF, stem cell factor; VEGF, vascular endothelial growth factor; ADAM, a disintegrin and metalloprotease; PLA2, phospholipase A2.

creased numbers of goblet cells in the airway epithelia and increased size of submucosal glands (Fig. 8) leading to excessive mucus production. Mucus hypersecretion may eventually lead to airflow obstruction. IL-9 and IL-13 can induce mucus hypersecretion.³⁵⁻³⁸

VASCULAR CHANGE AND AIRWAY EDEMA

Changes in the airway wall microvasculature that come about as a consequence of angiogenesis can contribute to airway wall edema. Increased airway vascularity has been demonstrated in bronchoscopic biopsies of patients with mild asthma³⁹ and in the bronchial mucosa of both stable and newly diagnosed asthma patients using a novel bronchovideoscope technique.⁴⁰ This increased vascularity is closely associated with increased expression of the multifunctional angiogenic and permeability factor vascular endothelial growth factor (VEGF),⁴¹ which is well known for its capacity to induce edema.

CARTILAGINOUS CHANGE

Airway cartilage is an important determinant of wall stiffness and integrity. Structural and biochemical changes in cartilage, therefore, will have an effect on airway function. Both decreased volume of the cartilage and fibronectin deposition have been observed in asthmatic airways.⁴² These alterations in cartilage

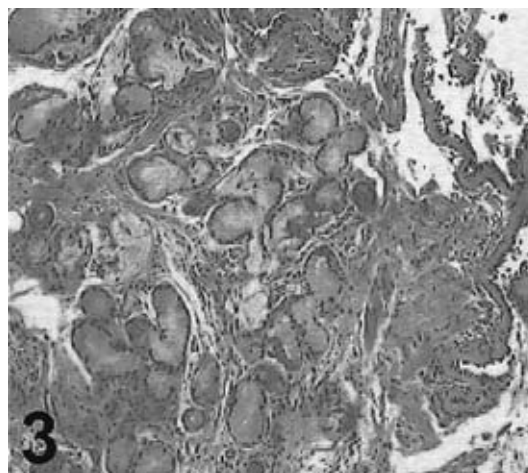


Fig. 8 An example of mucus gland hyperplasia in biopsy specimens from asthmatic subjects.

integrity may result in more powerful bronchoconstriction from ASM load reduction.

PATHOPHYSIOLOGY

AIRWAY NARROWING

Airway narrowing is the final common pathway leading to symptoms and physiological changes in asthma. Airway edema, mucus hypersecretion, and airway thickening due to airway remodeling and airway smooth muscle contraction all contribute to the development of airway narrowing in asthma. Recently, peripheral airways, including lung tissue, have been recognized as a predominant site of airflow obstruction in asthmatics. Yanai *et al.*,⁴³ for example, have demonstrated dramatically increased contributions of distal airways to the total lung resistance in patients who have moderate to severe asthma, as compared to nonasthmatics or to patients who have mild asthma.

AIRWAY HYPERREACTIVITY

Airway hyperreactivity is a characteristic functional abnormality of asthma which is linked to both inflammation and airway dysfunction. It is partially reversible with therapy. It has been suggested that increased volume and contractility of airway smooth muscle cells causes excessive contraction.⁴⁴ In addition, edematous thickening of airway walls, along with structural changes in the wall itself, amplify airway narrowing for purely geometric reasons. Thickening of the adventitial layer between the ASM and the surrounding parenchyma of this layer might also increase the ability of the ASM to narrow the airway. Lung parenchymal recoil provides an important load for ASM, and thickening of this layer functionally uncouples the ASM from the surrounding recoil. The muscle is thus able to shorten to a greater degree before the surrounding parenchyma is distorted than it

would if the layer were not thickened.⁴⁵

Some patients with severe asthma develop progressive, persistent airflow limitation. They show longer disease duration, a greater inflammatory process and more airway abnormalities, further suggesting that airway remodeling may account for the reduced lung function associated with asthma.⁴⁶

Although remodeling is believed to enhance airway narrowing, it might also protect against excessive narrowing. Lambert *et al.*⁴⁷ have suggested that when airways narrow, the folding of the mucosal membrane internal to the ASM layer provides a load to the muscle. Thickening and stiffening of this layer might increase the load and attenuate the ability of ASM to narrow the airway lumen. Although thickening of the inner wall will undoubtedly enhance the effect of ASM shortening, this thickening itself might attenuate the ability of the muscle to shorten.

PATHOGENESIS OF AIRWAY REMODELING

Asthma is a TH2-mediated inflammatory response and TH2 cells orchestrate many features of airway remodeling in asthma.⁴⁸

Eosinophilic inflammation in the airway is the result of TH-2 inflammation. Eosinophils are developed in the bone marrow under the influence of IL-4, IL-13, and GM-CSF. TH-2-mediated cytokines also control their movement to the lung and their activation.⁴⁹ Eosinophils are the main source of TGF- β which is the most potent profibrotic cytokine.

TH-2 cytokines also promote the production leukotrienes related to airway remodeling. IL-4 and IL-13 stimulation followed by CD40 L stimulation by activated T cells drives B cells to undergo an immunoglobulin isotype switch, shifting from IgM to IgE.⁵⁰

Mast cells constitutively express FcRI (a high affinity receptor for IgE) and, through the binding of IgE, mast cells are activated, leading to degranulation, the production of lipid mediators, and the generation of various cytokines and chemokines.

TH2 cytokines, including IL-4, IL-5, IL-9 and IL-13, can lead to goblet cell metaplasia.⁵¹ IL-9 appears to play a major role and has been shown to induce mucus gene expression in airway epithelial cells.⁵²

Some evidence, however, shows that TH2 airway inflammation is not the only cause of airway remodeling. First, structural changes in established asthma are poorly responsive to corticosteroids.⁵³ Second, changes induced by remodeling have been observed in childhood asthma and precede the development of the disease,⁵⁴⁻⁵⁶ indicating that the process begins early in the development of asthma and might occur in parallel with inflammation or even be required for the establishment of persistent inflammation. Moreover, inhaled corticosteroids cannot modify subsequent development of asthma in preschool children at high risk for asthma.⁵⁷

Another observation that supports the view that

asthma can be explained by more than TH2-mediated inflammation is found in severe asthma. Severe refractory asthma is characterized by neutrophilic airway inflammation in the presence or absence of eosinophils and is characterized by increased tissue injury and remodeling. Despite the use of high doses of inhaled corticosteroids, such patients remain symptomatic.

From these observations Holgate *et al.* have introduced the idea of epithelial mesenchymal trophic unit (EMTU) (Fig. 9).^{58,59} They postulate that exaggerated inflammation and remodeling in asthmatic airways are consequences of abnormal injury and repair responses from the susceptibility of bronchial epithelium to components of the inhaled environment. Airway inflammation and airway remodeling, in this view, are parallel and interacting factors.

In addition, many genes and loci that are associated with increased susceptibility to asthma are expressed in the mucus and epidermis, indicating that events at epithelial cell surfaces might also be driving the disease process.⁶⁰

THERAPEUTIC IMPLICATIONS

CORTICOSTEROIDS

Inhaled glucocorticosteroids (ICS) are currently the most effective anti-inflammatory medications for the treatment of persistent asthma. Most cases of asthma are well controlled by ICS. Some studies have also shown ICS to be effective in preventing or reducing the decline of airway function in asthmatic patients over time,⁶¹ with a greater benefit if therapy with ICS is started early after asthma diagnosis.⁶² However, others report no significant long term prevention in the decline of lung function with ICS in children presenting mild to moderate asthma.⁶³ Whether or not this decline in lung function is preventable needs to be confirmed by further studies.

As several divergent models have been studied, the effect of corticosteroids on epithelial cells is still controversial, although they may be beneficial by stimulating a decrease in mucus production. To date, the effect of corticosteroids on fibroblasts has been poorly studied. In one *in vitro* study, dexamethasone has been shown to increase 3H-thymidine incorporation in asthmatic bronchial fibroblasts, without having any significant effect on normal fibroblast proliferation, suggesting that the corticosteroids can influence some aspects of the bronchial fibroblast phenotype.⁶⁴ In another, the use of corticosteroids was shown to elicit a decrease in smooth muscle cell proliferation.⁶⁵

Other studies have shown that corticosteroids have no effect on the activation of nuclear factor-B transcription factor, suggesting a possible non-immunosuppressive effect of corticosteroids on ASM.⁶⁶ Neither were they shown to be effective in reducing extracellular matrix (ECM) protein production by human ASM.⁶⁷ Thus, corticosteroids may im-

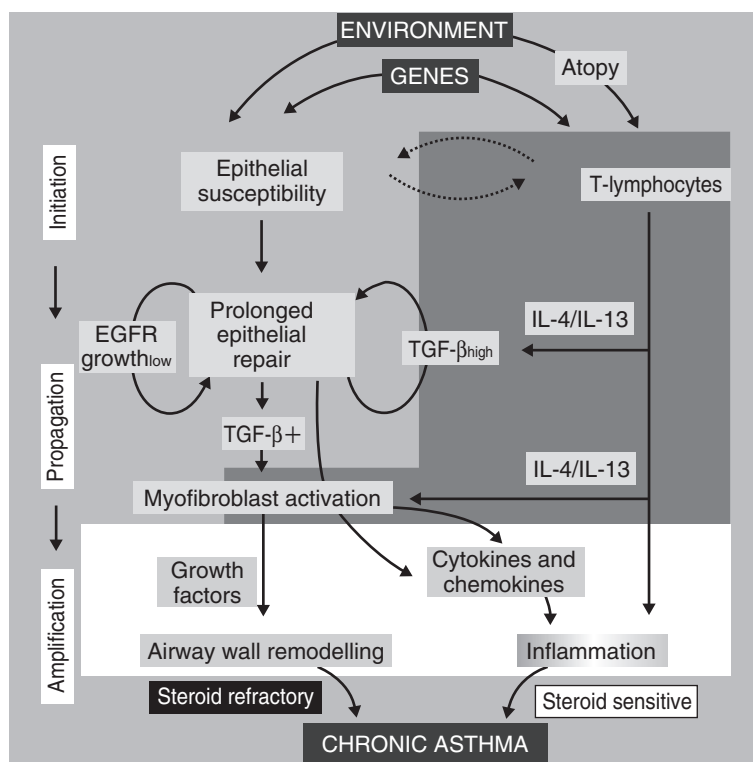


Fig. 9 The interaction between TH2 inflammation and the EMTU in asthma pathogenesis. A parallel model for asthma pathogenesis in which an inherited or acquired epithelial susceptibility to environmental agents leads to induction of stress-injury and repair responses is shown. Growth arrest and prolonged repair enhances cell-cell communication within the EMTU, leading to myofibroblast activation and propagation of remodeling responses into the submucosa. At each level, TH2 cytokines are able to interact with the EMTU to enhance or amplify these responses. Adapted with permission from Holgate and Davies D.E. Davies, J. Wicks, R.M. Powell, S.M. Puddicombe and S.T. Holgate, Airway remodeling in asthma: new insights, *J. Allergy Clin. Immunol.* 2003;111:215-225.

prove asthma control through decreased smooth muscle cell proliferation, but are probably less effective in modulating the synthesis of ECM proteins and cytokines.

ICS may be effective in reducing reticular basement membrane (RBM) thickness when used for a long period of time and at high doses. Some authors have reported that there is no change in basement membrane thickness following either long (3,7, and 10 years⁶⁸) or short (8 weeks) term use of ICS. Others have suggested that treatments with ICS lasting 6 weeks,⁶⁹ 4 months, 6 months, 1 year and 2 years results in a modest decrease in basement membrane thickness.

OTHER ASTHMA DRUGS

Cysteinyl leukotrienes (CysLT) play an important role in the pathogenesis of airway remodeling and anti-leukotrienes work to exert a certain degree of anti-

inflammatory effect.⁷⁰ The cysteinyl leukotriene antagonist Montelukast, for example, has been shown to significantly inhibit ovalbumin induced airway smooth muscle hyperplasia and subepithelial fibrosis in sensitized mice. Further studies are needed, however, to fully elucidate the role of the CysLT pathway in human asthmatic patients.

There is little evidence that β_2 -agonists affect airway structure and influence airway remodeling. Theoretically, the synergy between β_2 -agonists and glucocorticoids rests on observations that glucocorticoids increase expression of β_2 -agonist receptors, whereas the β_2 -agonists facilitate nuclear translocation of the glucocorticoid receptor.

As for theophylline, there is no evidence regarding its influence on airway remodeling.

REFERENCES

1. Naylor B. The shedding of the mucosa of the bronchial

- tree in asthma. *Thorax* 1962;**17**:69-72.
2. Ordonez C, Ferrando R, Hyde DM, Wong HH, Fahy JV. Epithelial desquamation in asthma: artifact or pathology? *Am. J. Respir. Crit. Care Med.* 2000;**162**:2324-2329.
 3. Carroll N, Elliot J, Morton A, James A. The structure of large and small airways in normal and fatal asthma. *Am. Rev. Respir. Dis.* 1993;**147**:405-410.
 4. Laitinen LA, Heino M, Laitinen A, Kava T, Haahtela T. Damage of the airway epithelium and bronchial reactivity in patients with asthma. *Am. Rev. Respir. Dis.* 1985;**131**:599-606.
 5. Bucchieri F, Puddicombe SM, Lordan JL *et al.* Asthmatic bronchial epithelium is more susceptible to oxidant-induced apoptosis. *Am. J. Respir. Cell Mol. Biol.* 2002;**27**:179-185.
 6. Trautmann A, Schmid-Grendelmeier P, Kruger K *et al.* T-cells and eosinophils cooperate in the induction of bronchial cell apoptosis in asthma. *J. Allergy Clin. Immunol.* 2002;**109**:329-337.
 7. White SR. Epithelium as a target. In: Barnes PJ, Grunstein MM, Leff AR, Woolcock AJ (eds). *Asthma*. Philadelphia: Lippencott-Raven, 1997;875-900.
 8. Tschumperlin DJ, Drazen JM. Mechanical stimuli to airway remodeling. *Am. J. Respir. Crit. Care Med.* 2001;**164**:S90-S94.
 9. Cookson W. The immunogenetics of asthma and eczema: a new focus on the epithelium. *Nat. Rev. Immunol.* 2004;**4**:978-988.
 10. Panettieri RA Jr. Airway smooth muscle: an immunomodulatory cell. *J. Allergy Clin. Immunol.* 2002;**110**:S269-S274.
 11. Roche WR, Beasley R, Williams JH, Holgate ST. Subepithelial fibrosis in the bronchi of asthmatics. *Lancet* 1989;**1**:520-524.
 12. Carroll N, Elliot J, Morton A, James A. The structure of large and small airways in normal and fatal asthma. *Am. Rev. Respir. Dis.* 1993;**147**:405-410.
 13. Heard BE, Hossain S. Hyperplasia of bronchial smooth muscle in asthma. *J. Pathol.* 1973;**110**:319-332.
 14. Ebina M, Takahashi T, Chiba T, Motomiya M. Cellular hypertrophy and hyperplasia of airway smooth muscles underlying bronchial asthma: a 3-D morphometric study. *Am. Rev. Respir. Dis.* 1993;**148**:720-726.
 15. Hossain S. Quantitative measurement of bronchial muscle in men with asthma. *Am. Rev. Respir. Dis.* 1973;**107**:99-109.
 16. Ebina M, Yaegashi H, Chiba R, Takahashi T, Motomiya M, Tanemura M. Hyperreactive site in the airway tree of asthmatic patients revealed by thickening of bronchial muscles: a morphometric study. *Am. Rev. Respir. Dis.* 1990;**141**:1327-1332.
 17. Johnson PR, Roth M, Tamm M *et al.* Airway smooth muscle cell proliferation is increased in asthma. *Am. J. Respir. Crit. Care Med.* 2001;**164**:474-477.
 18. Martin JG, Ramos-Barbon D. Airway smooth muscle growth from the perspective of animal models. *Respir. Physiol. Neurobiol.* 2003;**137**:251-261.
 19. Schmidt M, Sun G, Stacey MA, Mori L, Mattoli S. Identification of circulating fibrocytes as precursors of bronchial myofibroblasts in asthma. *J. Immunol.* 2003;**171**:380-389.
 20. Beqaj S, Jakkaraju S, Mattingly RR, Pan D, Schuger L. High RhoA activity maintains the undifferentiated mesenchymal cell phenotype, whereas RhoA down-regulation by laminin-2 induces smooth muscle myogenesis. *J. Cell Biol.* 2002;**156**:893-903.
 21. Hashimoto S, Gon Y, Takeshita I, Matsumoto K, Maruoka S, Horie T. Transforming growth factor- β 1 induces phenotypic modulation of human lung fibroblasts to myofibroblast through a c-Jun-NH₂-terminal kinase-dependent pathway. *Am. J. Respir. Crit. Care Med.* 2001;**163**:152-157.
 22. Vancheri C, Gili E, Failla M *et al.* Bradykinin differentiates human lung fibroblasts to a myofibroblast phenotype via the B2 receptor. *J. Allergy Clin. Immunol.* 2005;**116**:1242-1248.
 23. Hirst SJ, Martin JG, Bonacci JV *et al.* Proliferative aspects of airway smooth muscle. *J. Allergy Clin. Immunol.* 2004;**114**:S2-S17.
 24. Johnson PR, Burgess JK, Underwood PA *et al.* Extracellular matrix proteins modulate asthmatic airway smooth muscle cell proliferation via an autocrine mechanism. *J. Allergy Clin. Immunol.* 2004;**113**:690-696.
 25. Roth M, Johnson PR, Borger P *et al.* Dysfunctional interaction of C/EBP α and the glucocorticoid receptor in asthmatic bronchial smooth-muscle cells. *N. Engl. J. Med.* 2004;**351**:560-574.
 26. Ebina M, Takahashi T, Chiba T, Motomiya M. Cellular hypertrophy and hyperplasia of airway smooth muscles underlying bronchial asthma: a 3-D morphometric study. *Am. Rev. Respir. Dis.* 1993;**148**:720-726.
 27. Benayoun L, Druilhe A, Dombret MC, Aubier M, Pretolani M. Airway structural alterations selectively associated to severe asthma. *Am. J. Respir. Crit. Care Med.* 2003;**167**:1360-1368.
 28. Woodruff PG, Dolganov GM, Ferrando RE *et al.* Hyperplasia of smooth muscle in mild to moderate asthma without changes in cell size or gene expression. *Am. J. Respir. Crit. Care Med.* 2004;**169**:1001-1006.
 29. Zhou D, Zheng X, Wang L *et al.* Expression and effects of cardiotrophin-1 (CT-1) in human airway smooth muscle cells. *Br. J. Pharmacol.* 2003;**140**:1237-1244.
 30. Madison JM. Migration of airway smooth muscle cells. *Am. J. Respir. Cell Mol. Biol.* 2003;**29**:8-11.
 31. Howarth P, Knox A, Amrani Y, Tliba O, Panettieri R, Johnson M. Synthetic responses in airway smooth muscle. *J. Allergy Clin. Immunol.* 2004;**114**:S32-S50.
 32. Fernandes DJ, Mitchell RW, Lakser O, Dowell M, Stewart AG, Solway J. Do inflammatory mediators influence the contribution of airway smooth muscle contraction to airway hyperresponsiveness in asthma? *J. Appl. Physiol.* 2003;**95**:844-853.
 33. Vermeer PD, Harson R, Einwalter LA, Moninger T, Zabner J. Interleukin-9 induces goblet cell hyperplasia during repair of human airway epithelia. *Am. J. Respir. Cell Mol. Biol.* 2003;**28**:286-295.
 34. Reader JR, Hyde DM, Schelegle ES *et al.* Interleukin-9 induces mucous cell metaplasia independent of inflammation. *Am. J. Respir. Cell Mol. Biol.* 2003;**28**:664-672.
 35. Wills-Karp M, Chiaramonte M. Interleukin-13 in asthma. *Curr. Opin. Pulm. Med.* 2003;**9**:21-27.
 36. Kuperman DA, Huang X, Koth LL *et al.* Direct effects of interleukin-13 on epithelial cells cause airway hyperreactivity and mucus overproduction in asthma. *Nat. Med.* 2002;**8**:885-889.
 37. Li X, Wilson JW. Increased vascularity of the bronchial mucosa in mild asthma. *Am. J. Respir. Crit. Care Med.* 1997;**156**:229-233.
 38. Tanaka H, Yamada G, Saikai T *et al.* Increased airway vascularity in newly diagnosed asthma using a high-magnification bronchovideoscope. *Am. J. Respir. Crit. Care Med.* 2003;**168**:1495-1499.
 39. Hoshino M, Takahashi M, Aoike N. Expression of vascular endothelial growth factor, basic fibroblast growth fac-

- tor, and angiogenin immunoreactivity in asthmatic airways and its relationship to angiogenesis. *J. Allergy Clin. Immunol.* 2001;**107**:295-301.
40. Haraguchi M, Shimura S, Shirato K. Morphometric analysis of bronchial cartilage in chronic obstructive pulmonary disease and bronchial asthma. *Am. J. Respir. Crit. Care Med.* 1999;**159**:1005-1013.
 41. Yanai M, Sekizawa K, Ohru T, Sasaki H, Takishima T. Site of airway obstruction in pulmonary disease: direct measurement of intrabronchial pressure. *J. Appl. Physiol.* 1992;**72**:1016-1023.
 42. Black JL. Asthma-More muscle cells or more muscular cells? *Am. J. Respir. Crit. Care Med.* 2004;**169**:980-981.
 43. Wang L, McParland BE, Paré PD. The functional consequences of structural changes in the airways: Implications for airway hyperresponsiveness in asthma. *Chest* 2003;**123**:S356-S362.
 44. Bumbacea D, Campbell D, Nguyen L *et al.* Parameters associated with persistent airflow obstruction in chronic severe asthma. *Eur. Respir. J.* 2004;**24**:122-128.
 45. Lambert RK, Codd SL, Alley MR, Pack RJ. Physical determinants of bronchial mucosal folding. *J. Appl. Physiol.* 1994;**77**:1206-1216.
 46. Ying S, Durham SR, Corrigan CJ, Hamid Q, Kay AB. Phenotype of cells expressing mRNA for TH2-type (interleukin 4 and interleukin 5) and TH1-type (interleukin 2 and interferon gamma) cytokines in bronchoalveolar lavage and bronchial biopsies from atopic asthmatic and normal control subjects. *Am. J. Respir. Cell Mol. Biol.* 1995;**12**:477-487.
 47. Wills-Karp M, Karp CL. Biomedicine: Eosinophils in asthma: Remodeling a tangled tale. *Science* 2004;**305**:1726-1729.
 48. Oettgen HC. Regulation of the IgE isotype switch: new insights on cytokine signals and the functions of epsilon germline transcripts. *Curr. Opin. Immunol.* 2000;**12**:618-623.
 49. Fahy JV. Remodeling of the airway epithelium in asthma. *Am. J. Respir. Crit. Care Med.* 2001;**164**:S46-S51.
 50. Longphre M, Li D, Gallup M *et al.* Allergen-induced IL-9 directly stimulates mucin transcription in respiratory epithelial cells. *J. Clin. Invest.* 1999;**104**:1375-1382.
 51. Bergeron C, Hauber HP, Gotfried M *et al.* Evidence of remodeling in peripheral airways of patients with mild to moderate asthma: effect of hydrofluoroalkane-flunisolide. *J. Allergy Clin. Immunol.* 2005;**116**:983-989.
 52. Barbato A, Turato G, Baraldo S *et al.* Epithelial damage and angiogenesis in the airway of children with asthma. *Am. J. Respir. Crit. Care Med.* 2006;**174**:975-981.
 53. Payne DN, Rogers AV, Adelroth E *et al.* Early thickening of the reticular basement in children with difficult asthma. *Am. J. Respir. Crit. Care Med.* 2003;**167**:78-82.
 54. Cokugras H, Akcakaya N Seckin, Camcioglu Y, Sarimurat N, Aksoy F. Ultrastructural examination of bronchial biopsy specimens from children with moderate asthma. *Thorax* 2001;**56**:25-29.
 55. Guilbert TW, Morgan WJ, Zeiger RS *et al.* Long-term inhaled corticosteroids in preschool children at high risk for asthma. *N. Engl. J. Med.* 2006;**354**:1985-1997.
 56. Holgate ST, Polosa R. The mechanisms, diagnosis, and management of severe asthma in adults. *Lancet* 2006;**368**:780-793.
 57. Davis DE, Wicks J, Powell RM *et al.* Airway remodeling in asthma: New insights. *J. Allergy Clin. Immunol.* 2003;**111**:215-225.
 58. Holgate ST, Holloway J, Wilson S, Bucchieri F, Puddicombe S, Davis DE. Epithelial-mesenchymal communication in the pathogenesis of chronic asthma. *Proc. Am. Thorac. Soc.* 2004;**1**:93-98.
 59. Cookson W. The immunogenetics of asthma and eczema: a new focus on the epithelium. *Nat. Rev. Immunol.* 2004;**4**:978-000.
 60. Grol MH, Gerritsen J, Vonk JM *et al.* Risk factors for growth and decline of lung function in asthmatic individuals up to age 42 years: a 30-year follow-up study. *Am. J. Respir. Crit. Care Med.* 1999;**160**:1830-1837.
 61. Selroos O, Pietinalho A, Lofroos AB, Riska H. Effect of early vs late intervention with inhaled corticosteroids in asthma. *Chest* 1995;**108**:1228-1234.
 62. The Childhood Asthma Management Program Research Group. Long-term effects of budesonide or nedocromil in children with asthma. *N. Engl. J. Med.* 2000;**343**:1054-1063.
 63. Dube J, Chakir J, Laviolette M *et al.* *In vitro* procollagen synthesis and proliferative phenotype of bronchial fibroblasts from normal and asthmatic subjects. *Lab Invest.* 1998;**78**:297-307.
 64. Stewart AG, Fernandes D, Tomlinson PR. The effect of glucocorticoids on proliferation of human cultured airway smooth muscle. *Br. J. Pharmacol.* 1995;**116**:3219-3226.
 65. Lazaar AL, Panettieri RA. Airway smooth muscle as an immunomodulatory cell: a new target for pharmacotherapy? *Curr. Opin. Pharmacol.* 2001;**1**:259-264.
 66. Johnson PR, Black JL, Carlin S, Ge Q, Underwood PA. The production of extracellular matrix proteins by human passively sensitized airway smooth-muscle cells in culture: the effect of beclomethasone. *Am. J. Respir. Crit. Care Med.* 2000;**162**:2145-2151.
 67. Lundgren R, Soderberg M, Horstedt P, Stenling R. Morphological studies of bronchial mucosal biopsies from asthmatics before and after ten years of treatment with inhaled steroids. *Eur. Respir. J.* 1988;**1**:883-889.
 68. Olivieri D, Chetta A, Del Donno M *et al.* Effect of short-term treatment with low-dose inhaled fluticasone propionate on airway inflammation and remodeling in mild asthma: a placebo-controlled study. *Am. J. Respir. Crit. Care Med.* 1997;**155**:1864-1871.
 69. Ogawa Y, Calhoun WJ. The role of leukotrienes in airway inflammation. *J. Allergy Clin. Immunol.* 2006;**118**:789-798.
 70. Henderson WR Jr, Chiang GK, Tien YT, Chi EY. Reversal of allergen-induced airway remodeling by CysLT1 receptor blockade. *Am. J. Respir. Crit. Care Med.* 2006;**173**:718-728.