

unstable symptoms preoperatively. Their medical records were reviewed for fatal and nonfatal adverse events.

Results: Perioperative death occurred in 1 pt (3%) due to cardiogenic shock from acute myocardial infarction (AMI). Perioperative morbidity included:

	Cardiac	Non-Cardiac
Angina	10 (32%)	Renal Failure 2 (6%)
AMI	2 (6%)	CVA 1 (3%)
CHF	6 (26%)	Sepsis 1 (3%)
Arrhythmia	4 (13%)	Transfusion 6 (19%)

Conclusions: Perioperative mortality and noncardiac morbidity in pts with class III or IV angina pectoris undergoing isolated TMR is low. Compared to conventional coronary artery bypass surgery, TMR pts are at higher risk for perioperative cardiac events, likely reflecting the lack of immediate benefit from the procedure in the setting of severe CAD. These pts merit vigilant surveillance for adverse cardiac events and aggressive medical management in the perioperative period.

1119-46 Clinical Experience With Transmyocardial Revascularization Utilizing a Holmium:YAG Laser

K.B. Allen, R.D. Dowling, D.A. Helmansohn, E. Reitama, L.T. Didelot, C.J. Shaar. *St. Vincent Hospital, Indianapolis, Indiana; University of Louisville, Louisville, Kentucky, USA*

Background: In the United States, studies have been underway since 1995 to assess the safety and efficacy of Transmyocardial revascularization (TMR) using a holmium:YAG laser.

Methods: TMR was performed in 42 patients with refractory angina who were not candidates for PTCA or CABG (mean age 62 ± 11 , range 38-79 years). Patients had either Class IV angina ($n = 23$) or had unstable angina ($n = 19$) and were unweanable from intravenous nitroglycerin. Preoperative thallium studies identified the extent and location of reversible ischemia. Operative exposure was via a limited left anterior thoracotomy. An average of 45 ± 11 laser channels were created with a mean operative time of 106 ± 38 minutes.

Results: At three months follow-up ($n = 23$) mean angina class was 1.5 ± 0.1 ($p < 0.001$), and at six months follow-up ($n = 11$) mean angina class was 1.1 ± 0.1 ($p \leq 0.002$); versus 4.0 ± 0 at baseline. Mortality was 12% (5/42) with no late deaths. Complications included ventricular arrhythmias 12% (5/42), intraaortic balloon placement 12% (5/42), reoperation for chest wall hemorrhage 2% (1/42), and respiratory failure requiring reintubation 2% (1/42). Median postoperative length of stay was 5.5 ± 4.9 (range 1-25) days.

Conclusion: Transmyocardial revascularization with a Ho:YAG laser results in a significant reduction in angina class and is beneficial in patients with refractory angina untretable by conventional methods.

1120 Long-Term Outcome of Congenital Heart Disease: Adult With Congenital Heart Disease

Tuesday, March 31, 1998, Noon-2:00 p.m.
Georgia World Congress Center, West Exhibit Hall Level
Presentation Hour: Noon-1:00 p.m.

1120-154 Outcome in Patients With Clinically Silent Coronary Artery Fistulae

M.C. Sherwood, S. Rockenmacher, S.D. Colan, T. Geva. *Children's Hospital, Boston, Massachusetts, Lahey Hitchcock Clinic, Manchester, New Hampshire, USA*

Background: With the advent of high resolution 2-D and color echo the detection rate of clinically silent coronary artery fistulae (CAF) has increased. Because the clinical significance and outcome of these CAF has not been defined, this study aims to determine the clinical significance of echo diagnosed, clinically silent CAF.

Methods: The echo, clinical, ECG, and angiographic findings and documented follow-up of 31 patients, mean age 7.2 ± 8.4 years (range 0.01-39.9) at presentation, with an unsuspected echo finding of CAF (1986-1997), were analyzed. Sinusoids and small fistulae following intracardiac surgery were excluded.

Results: The indications for echo were known heart disease ($n = 2$), murmur ($n = 23$), cardiomegaly ($n = 2$), chest pain ($n = 1$), stridor ($n = 1$), syncope ($n = 1$) and chest trauma ($n = 1$). Cardiac anomalies ($n = 10$) were ASD, VSD, bicuspid aortic valve, mild Ebstein's anomaly, coarctation LV aneurysm, and RA appendage hemangioma. CAF were detected with color

Doppler in all patients. The origin was from the left coronary system ($n = 27$), right coronary system ($n = 3$) and bilateral ($n = 1$). The entry sites were the PA ($n = 18$), RV ($n = 8$), RA ($n = 2$) and LV ($n = 3$). The entire length of CAF was visualized in 14 patients. Angiography ($n = 5$) confirmed the echo findings ($n = 2$), and delineated the origin ($n = 2$) or entry point of CAF ($n = 1$). Follow-up was to mean age 8.0 ± 8.4 years (range 0.3-42.0). Spontaneous closure of CAF ($n = 7$) occurred at mean age 6.8 ± 4.3 years (range 0.3-13.7). In 23 patients CAF persisted, without intervention. All patients remained asymptomatic, with no adverse clinical events or ECG evidence of ischemia at mean age at follow-up of 9.3 ± 9.1 years (range 0.3-42.0).

Conclusion: Based on this experience there was no evidence that clinically silent CAF that are diagnosed incidentally by echo are associated with adverse clinical outcomes. Conservative management of these patients appears to be appropriate.

1120-155 Outcomes of Aortic Valve Stenosis Presenting in Neonates

S. Baram, B.W. McCrindle, R.M. Freedom, D. Nykanen. *The Hosp. for Sick Children, Univ. of Toronto, Canada*

Background: Management of isolated aortic valve stenosis (AVS) requiring intervention at age < 3 mo is controversial. We sought to define factors associated with outcomes after neonatal presentation.

Methods: From 1/85 to 12/96, 62 infants presented with AVS at < 3 mo of age; 7 were excluded due to significant mitral valve abnormalities (4 died). Clinical, echo, hemodynamic and angiographic, management and outcome data were obtained.

Results: Median age at presentation was 6d, with only murmur in 30, signs of CHF in 20 and poor perfusion/shock in 5 pts. Initial echo showed reduced LV function in 26%, with a mean peak instantaneous gradient of 69 ± 30 mmHg in those with normal function. There were 4 deaths (7%), all with poor function and before age 1.4 mo, with survival thereafter of 92% (95%CI, 85-99.6%) up to age 11.9 yrs. Initial intervention was transcatheter dilation in 23 and surgical valvotomy in 20 pts, with 12 having no intervention to date. Freedom from intervention for AVS was 69% at age 1 wk, 56% at 1 mo, 35% at 3 mo, 29% at 1 yr and 19% at age 5 yr. Additional interventions were required in 14 pts. Patients without poor perfusion/shock, normal LV function and peak instantaneous gradients < 60 mmHg at presentation ($n = 19$, Group I) vs. pts with poor function or initial gradients ≥ 60 mmHg ($n = 36$, Group II) had better survival (I-0 vs. II-4 deaths), and longer freedom from intervention at age 1 wk (I-100% vs. II-53%), 1 mo (I-95% vs. II-39%), and 6 mo (I-79% vs. II-12%) ($p = 0.0001$).

Conclusions: The majority of neonates presenting with AVS require intervention, although this may be safely delayed in selected patients with lower initial gradients and good LV function.

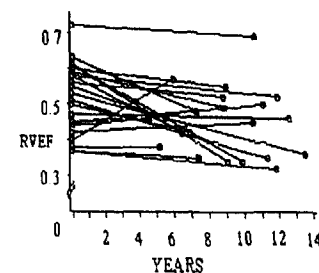
1120-156 Course of Right Ventricular Function in Patients With Pulmonary Insufficiency After Repair of Tetralogy of Fallot

M.S. Schamberger, R.A. Hurwitz. *Indiana University, Indianapolis, IN, USA*

Background: Surgical repair of Tetralogy of Fallot (ToF) frequently results in pulmonary insufficiency (PI). Nevertheless, little information is available on the long term impact of PI on right ventricular function.

Methods: 21 patients with at least moderate PI after repair of ToF were studied serially by radionuclide angiocardiology. The first (baseline) study was obtained a mean of 1.2 years (range 0.1 to 6.4) after surgery. The last study was performed a mean of 10.2 years (range 4.6 to 16.9) after surgery.

Results: The mean RVEF at baseline was 0.52 ± 0.1 (normal: 0.53 ± 0.06 ; n.s.). At the time of the last study the mean RVEF had decreased significantly to 0.45 ± 0.1 ($p < 0.01$).



At the last study, 7 patients (33%) had a RVEF < 0.42 , which is > 2 SD below our laboratory normal. Using 0.05 as our reproducibility factor for change in RVEF, 2 patients showed improvement in RVEF, 7 patients showed no change and 12 patients (57%) showed a decrease in RVEF.