



Journal of Coloproctology

www.jcol.org.br



Original article

Total mesorectal excision and sphincter preservation — the early steps of rectal cancer surgery

Rodrigo O. Perez^{a,*}, Guilherme P. São Julião^b, Igor Proscurshim^b, Charles Sabbagh^b, Esteban Grzona^b, Patricio B. Lynn^b, Joaquim Gama-Rodrigues^{b,c}

^aColorectal Surgery Division, Faculdade de Medicina, Universidade de São Paulo, São Paulo, SP, Brazil

^bAngelita & Joaquim Gama Institute, São Paulo, SP, Brazil

^cFaculdade de Medicina, Universidade de São Paulo, SP, Brazil

ARTICLE INFO

Article history:

Received 15 October 2013

Accepted 11 December 2013

Keywords:

Rectal cancer

Sphincter preservation

Total mesorectal excision

Intersphincteric resection

ABSTRACT

The treatment of rectal cancer has evolved significantly over the last 100 years. Standardization of total mesorectal excision and the development of techniques for sphincter preservation have resulted in significant improvements in the management of this disease. Still, local disease control and functional outcomes of sphincter preserving procedures remain a relevant issue. In this historical paper, the oncological and functional outcomes of patients with rectal cancer treated between 1960 and 1971 by a pioneer woman surgeon using a sphincter preserving approach and a technique resembling total mesorectal excision performed at that time are reported. The results reflect one of the earliest steps of partial intersphincteric resection and total mesorectal excision with good oncological outcomes (2% local recurrence) and acceptable functional outcomes in a highly selected group of patients.

© 2014 Sociedade Brasileira de Coloproctologia. Published by Elsevier Editora Ltda.

Este é um artigo Open Access sob a licença de [CC BY-NC-ND](http://creativecommons.org/licenses/by-nc-nd/4.0/)

Excisão total do mesorreto e esfíncter — os primeiros passos de uma cirurgia de câncer retal

RESUMO

O tratamento do câncer de reto tem evoluído significativamente ao longo dos últimos 100 anos. A padronização da excisão total do mesorreto e o desenvolvimento de técnicas com preservação do esfíncter resultaram em melhorias significativas no tratamento da doença. Ainda assim, o controle local da doença e os resultados funcionais dos procedimentos de preservação do esfíncter continuam a ser uma questão relevante. Nesse documento histórico, são relatados os resultados oncológicos e funcionais de pacientes com câncer retal, tratados entre 1960 e 1971, utilizando-se uma abordagem com preservação do esfíncter e uma técnica parecida com a excisão total do mesorreto realizada por uma cirurgiã pioneira naquela época. Os resultados refletem um dos primeiros passos de ressecção parcial interesfínctérica

Palavras-chave:

Câncer retal

Preservação do esfíncter

Excisão total do mesorreto

Ressecção interesfínctérica

* Corresponding author.

E-mail: rodrigo.operez@gmail.com (R.O. Perez).

2237-9363 © 2014 Sociedade Brasileira de Coloproctologia. Published by Elsevier Editora Ltda.

Este é um artigo Open Access sob a licença de [CC BY-NC-ND](http://creativecommons.org/licenses/by-nc-nd/4.0/) <http://dx.doi.org/10.1016/j.jcol.2013.12.007>

e a excisão total do mesorreto com bons resultados oncológicos (2% de recidiva local), e os resultados funcionais aceitáveis em um grupo altamente selecionado de pacientes.

© 2014 Sociedade Brasileira de Coloproctologia. Publicado por Elsevier Editora Ltda.

Este é um artigo Open Access sob a licença de [CC BY-NC-ND](#)

Introduction

Rectal cancer management has evolved significantly over the past 100 years.¹ In fact, many contributions in the fields of surgery, radiology, pathology, and medical and radiation oncology have led to improved oncological outcomes. In surgery, perhaps the two most significant contributions have been standardization of total mesorectal excision and sphincter preserving operations. A total mesorectal excision with precise, sharp dissection of the mesorectum through an avascular plane, initially described by Heald in the early 1980's, led to a significant decrease in local recurrence rates.² Many surgeons have claimed they routinely performed total mesorectal excision prior to its standardized description in medical journals and long before computers and internet were available. Sphincter preservation however was initially considered possible only for the most upper rectal cancers, commonly referred to the distal part of the pelvic colon, as early as 1950.^{3,4} Up until the early 1970's, middle and distal rectal cancers were most commonly treated by proctectomy without primary anastomosis (Miles' operation).⁵

There was a common belief that primary restoration of bowel continuity for patients with mid/distal rectal cancers was unsuitable and would inevitably lead to unacceptable functional results. Fortunately, a few surgeons were already "thinking outside the box". In 1972, a most improbable scientific work was presented suggesting successful outcomes following primary anterior resection with primary colorectal anastomosis for mid/distal rectal cancers. In the male world of surgery, a woman surgeon (first in her country) was able to break through and treat a number of patients undergoing restorative proctectomy with a technique whose detailed description matches that of a total mesorectal excision. In addition, circular staplers were not available at the time and hand-sewn low colorectal and coloanal anastomoses were performed through the anal canal, similar to how intersphincteric resections are performed today.

In this historical paper, the oncological and functional outcomes of patients with mid/distal rectal cancers treated by radical proctectomy, total mesorectal excision and delayed coloanal anastomosis between 1960 and 1971 are documented. The methods, results and illustrations described here were taken from the original thesis entitled "Indicações e resultados da retocolectomia abdominoendoanal no tratamento do câncer do reto/ Indications and results of abdominal-endoanal rectocollectomy in the treatment of rectal cancer" presented to the University of São Paulo School of Medicine by Angelita Habr-Gama in 1972 to obtain the title of Associate Professor of Surgery.⁶ Not only the scientific data is of interest but also the historical setting in which a woman surgeon, clearly ahead of her time, challenged the surgical community in a call for a change in the management of rectal cancer. This thesis describes one of the predecessor techniques of the par-

tial intersphincteric resection with delayed coloanal anastomosis following previous descriptions by Bacon and Black on techniques for proctectomies with sphincter preservation.^{7,8}

Methods

Between 1960 and 1971, consecutive patients with resectable extraperitoneal rectal cancer were managed (handled/treated) by a single surgeon at the Hospital das Clínicas of the University of São Paulo School of Medicine. Initial assessment included a physical and digital rectal examination, rigid proctoscopy, barium enema and chest radiograph

Patients received no preoperative radiation or chemotherapy treatments. Patients with hepatic and/or peritoneal metastases detected intraoperatively or with unresectable disease were excluded from the study. Prior to surgery all patients received full bowel preparation including low-residue diet, laxatives and enemas for three days. All patients received oral antibiotic prophylaxis with Neomycin and Sulfamycin.

Surgery

The original description of the surgery included a two-staged procedure, the primary resection and at a later date, delayed endocoloanal anastomosis:

FIRST STAGE

Abdominal phase. The patient was positioned in supine position with legs apart and flexed at a 45-degree angle. A midline incision was performed between the pubis and xiphoid. Systematic examination of the abdominal cavity in search of liver metastases and peritoneal implants was followed by the placement of a Gosset's abdominal wall retractor. The small bowel was retracted upward and to the right by the first assistant and protected with sterile towels.

Incision of the mesosigmoid was performed laterally to identify the left ureter and gonadal vessels and continued anteriorly to reach the level of the base of the bladder or vagina. At this point, the surgeon decided on the resectability of the tumor.

Once the tumor was considered resectable, the left colon was completely mobilized including the splenic flexure in all cases. The proximal colon above the tumor was occluded using gauze to avoid possible dissemination of cancerous cells. The left ureter and gonadal vessels were again identified, now in this more cranial position, and the mesocolon was incised proximal to the ligament of Treitz. The inferior mesenteric vein (IMV) was identified and ligated close to the inferior border of the pancreas. The inferior mesenteric artery (IMA) was ligated close to its origin in the aorta and prior to the exit of the left colic branch (Fig. 1).

The dissection of the rectum began by its posterior aspect, releasing adhesions to the presacral fascia in an avascular

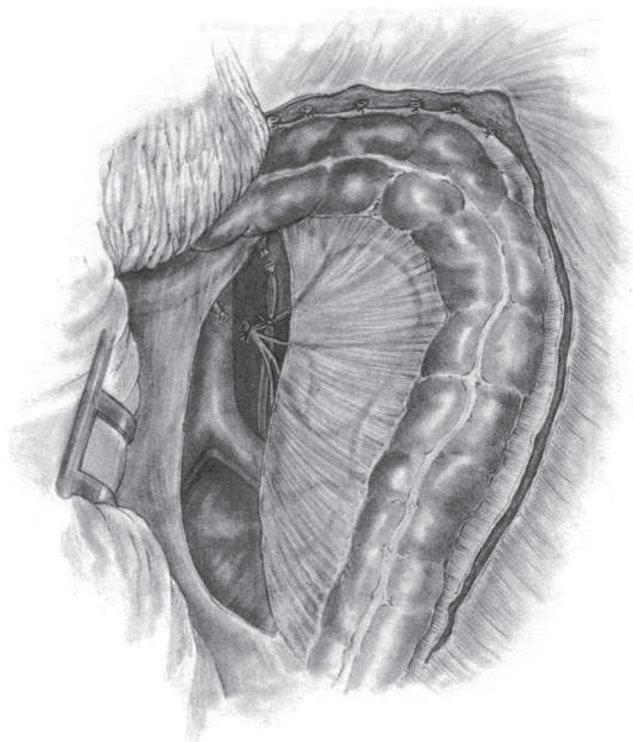


Fig. 1 – Illustration showing high-ligation of the inferior mesenteric vein and artery.

plane down to the level of the levator muscles. The anterior wall was dissected, preferably behind Denonvillier's fascia: in male patients down to the level of the prostate gland preserving the seminal vesicles and deferens ducts; and in female patients, posterior dissection of the uterine wall to the vaginal dome. The lateral ligaments of the rectum were taken near the pelvic wall. Dissection of the rectum was then completed to the level of levator muscles and its distal end, was tied with gauze (Fig. 2).

Once the proximal colon was completely mobilized and the rectum completely dissected, the selection of the descending colon segment to be lowered to the anal canal was performed taking into consideration its reach over the pubic bone without any significant tension. Adequacy of the arterial blood flow at this point was routinely evaluated prior to resection.

The surgeon moved to the perineum while the assistant remained in the abdomen to help with the final passage of the descending colon through the pelvis.

Perineal phase. Following standard antiseptic rinsing of the perineum, gentle digital dilatation of the anus was performed and Allis' clamps were placed at the cardinal points of the anus to allow good exposure of the anorectal region. A circumferential incision 0.5 cm above the dentate line was made starting at the posterior wall, followed by submucosal dissection along with the identification of the internal sphincter muscle (Fig. 3). An incision was made through the muscular layer of the rectal wall (with partial resection of the cranial portion of the internal sphincter) circumferentially and distal to the previously made occlusion of the rectum (tied gauze),

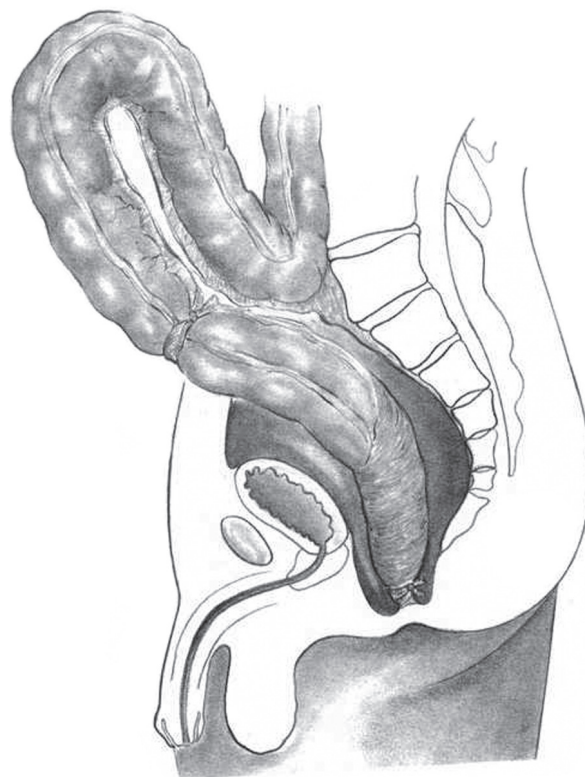


Fig. 2 – Illustration showing complete mobilization of the rectum through an avascular plane suggesting total mesorectal excision (there are no vessel ligatures).

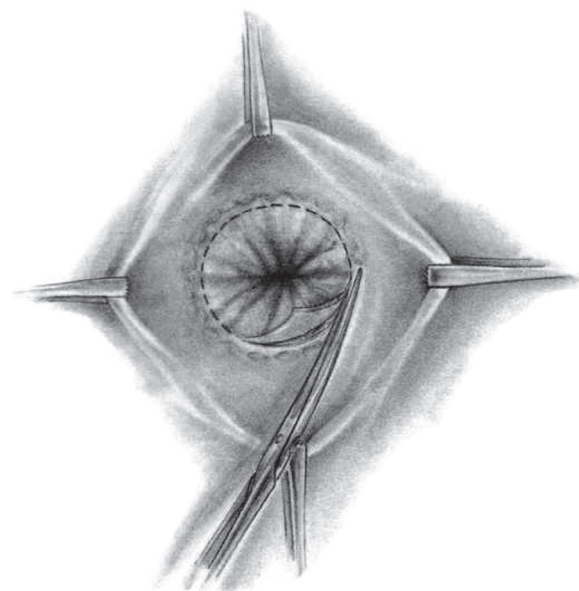


Fig. 3 – Illustration of the circumferential incision of the rectal wall allowing access to the intersphincteric plane.

thus communicating with the abdominal dissection (Fig. 4). The rectal stump was then closed with interrupted sutures and the specimen extracted through the abdomen.

The descending colon was gently brought through the anal canal and a small segment was kept exteriorized as a perineal

colostomy. Cardinal sutures were placed between the dentate line and the descending colon (Fig. 5). Special care was taken in order to maintain the anastomosis tension free and properly vascularized. A tubular drain was placed in the presacral space and the abdominal wall was closed.

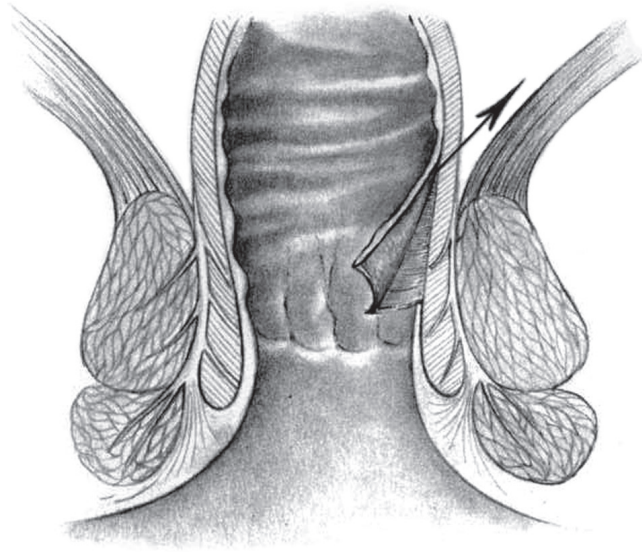


Fig. 4 – Illustration of the intersphincteric dissection showing a partial resection of the internal anal sphincter (arrow).

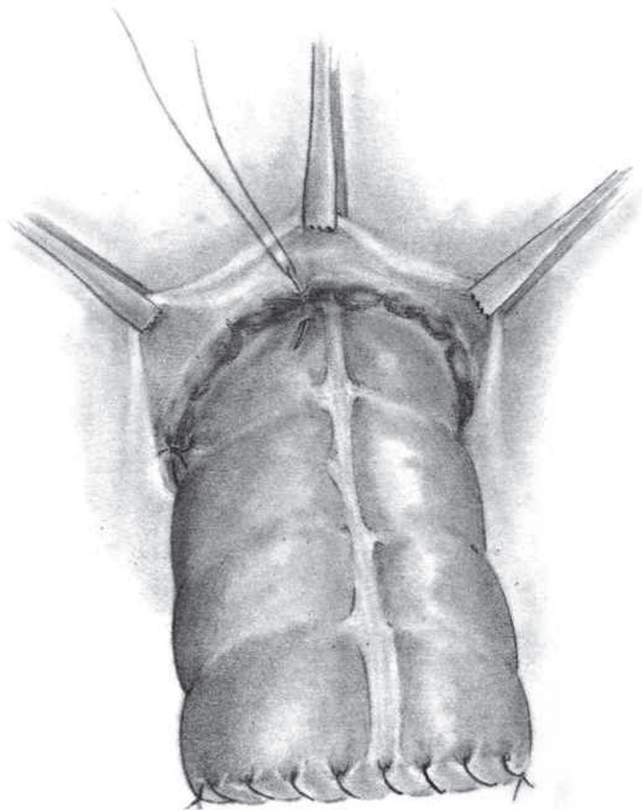


Fig. 5 – Perineal colostomy created through exteriorization of a segment of well-vascularized and tension-free proximal colon.

SECOND STAGE (Resection of the perineal colon stump)

Ideally, the second stage of the operation was planned to be performed within 10 to 20 days from the original procedure. Under spinal anesthesia, the patient was positioned in gynecological position with the aid of leg stirrups. A circular incision of the colon at the level of coalescence to the dentate line was made and the marginal arcade was ligated. Reinforcements to the previously sutured coloanal anastomoses were performed with additional interrupted sutures.

Postoperative complications were considered immediate when occurring up to 30 days from the initial surgical procedure and late when occurring after that period.

None of the patients underwent postoperative chemotherapy. Follow-up included visits to the colorectal surgeon one month after surgery and then every three months during the first year and every 6 months thereafter. Recurrence was considered local in the presence of endoluminal confirmation of adenocarcinoma. Systemic recurrences were considered in the presence of clinical or radiological evidence (with or without pathological confirmation) of distant metastases.

All patients underwent assessment for urological, sexual and anorectal function. Urological assessment included a questionnaire of urological symptoms (dysuria, urinary incontinence) and cystometry 2 months after surgery. Sexual function was assessed with a questionnaire of postoperative sexual function (retrograde ejaculation, orgasm and erection). Fecal continence was assessed with a questionnaire of postoperative events specifically addressing gas, liquids or solids incontinence every 6 months until 2 years of follow-up completion. In addition, patients underwent a radiographic enema and manometry. All questionnaires included objective questions to the presence or absence for each of the mentioned symptoms.

Results

Fifty patients with resectable rectal cancer were included. Patients' demographics are described in Table 1.

Median hospital stay was 18 days and the median interval for resection of the perineal colostomy was 20 days. Immediate postoperative mortality was 8% (4 patients). Postoperative complications, included necrosis (mucosal or transmural) of the large bowel used for anastomosis, were detected in 5 patients (10%) (Table 2). Postoperative complications and difficulties in hospital admittance (a public University Hospital) for resection of the perineal colostomy led to a significant increase in the interval time between the stages of the procedure. Long term complications were mainly related to stricture of the anastomosis occurring in 7 patients (14%). Nearly half of these strictures were short in extent (3

Table 1 – Patient's demographics.

N	50 (100%)
Age (yrs)	55.7 (28-81)
Gender (male/female)	31 – 19 (62%)
Mean distance from anal verge (cm)	9.6 (5-15)
Previous surgery (diverting colostomy)	4 (8%)
Palliative procedures	5 (10%)

Table 2 – Surgical outcomes.

Mean hospital stay (days)	18.6
Mean interval for perineal colostomy removal (days)	20 (11-60)
Overall Morbidity	24 (48%)
Early complications (<30 days)	
Urinary retention	3 (6%)
Urinary retention with infection	4 (8%)
Renal failure	1 (2%)
Heart failure	1 (2%)
Stroke	1 (2%)
Pseudomembranous Enteritis	2 (4%)
Wound infection	4 (8%)
Evisceration	2 (4%)
Partial colonic necrosis (mucosal ischemia)	2 (4%)
Complete colonic necrosis (transmural ischemia)	3 (6%)
Pelvic sepsis	5 (10%)
Late complications (>30 days)	
Anastomotic dehiscence	3 (6%)
Short anastomotic stricture	3 (6%)
Long anastomotic stricture	4 (8%)

patients) while the remaining developed long tubular strictures (4 patients) (Table 2).

Pathology was available for 31 patients and classified using Dukes' staging system. Dukes A (pT1-2N0) tumor was present in one patient, Dukes B (pT3-4N0) in 19 patients and Dukes C in 11 (5 with C1/pT1-2N+ and 6 with C2/pT3-4N+) (Table 3).

Median follow-up was 60 months. There was one local recurrence (2%) and 10 systemic recurrences (20%). Eight patients died due to disease progression during the study period. Three year and 5 year cancer specific survival was 87% and 71% respectively.

Only 6.5% of patients had any urinary symptoms during the postoperative period (> 30 days). All were transitory and all patients became asymptomatic at 2 months of follow-up. Cystometric values were normal 2 months after surgery in all cases.

Five out of 12 male patients that completed the postoperative questionnaire complained of sexual dysfunction after surgery (48%). There were 2 patients with exclusively retrograde ejaculation and 3 with impaired erection and orgasm.

Table 3 – Pathology and long-term outcomes.

Dukes	
A	1 (3.2%)
B	19 (61.2%)
C1	6 (19.3%)
C2	5 (16.1%)
Recurrence	
Local	1 (2.0%)
Dukes A	0 (0.0%)
Dukes B	0 (0.0%)
Dukes C	1 (9.0%)
Systemic	10 (20.0%)
Dukes A	0 (0.0%)
Dukes B	5 (26.3%)
Dukes C	5 (45.4%)
Mortality	
Immediate postoperative mortality	4 (8.0%)
Late cancer-specific mortality	8 (16.0%)
3-year cancer-specific survival	87%
5-year cancer specific survival	70.8%

Tables 4 and 5 provide information on bowel function and episodes of gas, liquids and solids incontinence. Bowel functional outcomes were obtained from 40 patients. In general, 50% of patients had bowel function perceived as normal (no diarrhea or constipation) after 1 year from the primary surgical procedure. Complete continence to solid stool increased from 30% in the immediate postoperative period to 92% after 2 years of follow-up. Continence to gas increased from 9% to 75% during the same period. Finally, among the 20 patients that underwent radiographic enema, all were able to completely retain the contrast during the study.

Discussion

Even though the retrospective observations of the present study may not seem a breakthrough in the management of rectal cancer today, it is clearly an outstanding accomplishment when the data and the results are put into historical perspective. After all, more than 50 years ago and 50 years after Miles original description of the abdominal perineal excision of the rectum, preservation of the anus with coloanal anastomosis for tumors as low as 5cm from the anal verge was unthinkable by most surgeons, perhaps considered madness by many. Still, the idea that sphincter preservation for these patients was considered a merely pleasant possibility and never a necessarily required outcome is clearly emphasized in the thesis.^{6,9}

Apart from the obvious differences in terms of hospital stay (18 days!), immediate postoperative mortality and absence of stapling devices, this paper draws attention for the similarity to “modern” rectal cancer management. First, the fact that an operation resembling total mesorectal excision was used during proctectomy stands out immediately, even though not as clearly described as Heald did years later.² The description of the surgical procedure specifically mentioning the dissection through an avascular plane close to the presacral fascia, also indicated by the drawing, clearly illustrates an embryonary total mesorectal excision with no vessel ligation and what appears to be an intact mesorectal plane. In addition to the actual description and illustration of the technique, the 2% local recurrence rate strongly suggests that an operation very close to TME had been performed and contributed to the excellent local disease control. This by no means

Table 4 – Functional outcomes - bowel function.

Bowel function	Normal	Diarrhea
After 3 months	6 (13.9%)	32 (74.4%)
After 6 months	12 (30.0%)	20 (50.0%)
After 1 year	20 (50.0%)	10 (25.0%)

Table 5 – Functional outcomes - continence.

Continence	Solid stools	Liquid stools and gas
After 6 months	13 (32.2%)	4 (9.3%)
After 12 months	35 (87.5%)	20 (50.0%)
After 24 months	37 (92.5%)	30 (75.0%)

diminishes the relevance of Heald's proper and meticulous description of the technique, or confirmation of its relevance in terms of local disease control done some years later in properly designed studies.¹⁰⁻¹² The efforts and works of Prof. Heald allowed widespread education and training of surgeons worldwide with a significant impact in the practice and outcomes for rectal cancer surgery.^{10,11} The early use of TME presented in this study merely reinforces that total mesorectal excision is so appropriate that to some surgeons it was nearly instinctive. Still, one should take into account that strict selection of patients may also have accounted for this excellent result in local disease control since many more advanced or aggressive cases could have been managed by alternative abdominal perineal resection during the same study period.

Second, the concern of the colorectal surgeon with the urinary, sexual and fecal continence consequences after rectal surgery with sphincter preservation is rather remarkable. The observation that fecal incontinence improved over time, confirmed much later in randomized controlled trials, was already observed after straight colorectal or coloanal anastomosis.¹²⁻¹⁴ None of the currently used fecal incontinence scores were available at the time (most proponents were not even born yet!) and the author used a simple assessment of gas, liquids and solids incontinence for dysfunction evaluation.¹⁵ The same applies to the attempt of assessing sexual and urinary functions.^{16,17}

Third, is the description of what we know today as a partial intersphincteric resection (ISR). Instead of a complete removal of the internal anal sphincter, partial intersphincteric resections include the most cranial portion of the internal sphincter as described by Yamada et al.¹⁸ In fact, sphincter preservation with coloanal anastomoses had already been clearly described at that time, particularly by works from Babcock and Bacon in the late 40's.^{7,19} Also known as "abdomino-anal pull-through", these authors described a technique with removal of the lining of the anal canal and bringing the mobilized colon through the canal leaving a segment of nearly 5cm protruding beyond the anal verge. By this technique, the anal sphincters were divided and then sutured to the protruding colon. It was Black, nearly 10 years later that modified the technique to preserve the anal canal lining and anal sphincters (by dilation instead of sectioning).⁸ The former description is the closest to the technique employed in the present manuscript that had also been described for the treatment of Chagasic megacolon in 1961.²⁰

Still, at that time, a 5cm distal free margin was the rule for curative rectal cancer surgery. Therefore, sphincter preservation would rarely be considered for distal tumors (< 5cm) from the anal verge. Progressively, the 5cm has been replaced by 2cm, 1cm and now distal margins even less than 1cm are currently considered appropriate for most patients with rectal cancer, particularly for tumors undergoing neoadjuvant therapies and without direct invasion of the sphincters.²¹ This incision of the rectum at (or closely higher to) the dentate line with delayed coloanal anastomosis is clearly described in the manuscript and illustrated by the drawings of the time. In fact, in a time where surgical staplers were still unavailable, this was the only technical option for the preservation of large bowel continuity to the anus. Curiously the same year, 1972, Sir Alan Parks published the technique

for transanal coloanal anastomosis with primary suturing.²² Years later, intersphincteric resection for rectal cancer became increasingly popular.^{23,24} The only difference between today's partial intersphincteric resection and the technique described in the 1972 manuscript is that delayed anastomosis with perineal colostomy is now rarely used. This has currently been replaced by temporary stomas (most frequently ileostomies).²⁵ Still, considering that none of the patients required stomas in the author's series and that the mean interval between the final resection of the perineal stoma and definitive colonanal anastomosis was 20 days, leads to a reflection whether this approach should be revisited and considered in specific situations by the experienced colorectal surgeon. This is particularly relevant considering the morbidity and mortality directly associated with stoma creation and closure.^{26,27}

Finally, if all of this was not already a significant leap in rectal cancer management between 1960's and 1970's, the fact that all patients had been exclusively intervened by a single woman surgeon is significant. At that time, there were very few women in surgery and did not usually play key roles in the advancement of our specialty. In order to introduce so many new concepts in rectal cancer management, one needed to literally invade an almost exclusively men's world.

Sphincter preservation and functional outcomes following rectal cancer surgery has been a matter of interest and concern for many years. However, there is still controversy in the use of sphincter preservation and ISR for the management of distal rectal cancer. Particularly, appropriate comparison of oncological, functional and quality of life outcomes to abdominal perineal excision in the setting of proper cylindrical (also known as extra-levator APE) is warranted.²⁸ While technical advancements seem to have been overcome, it is our task to take the next step to provide definitive answers for its use. Otherwise, we will continue teaching new dogs old tricks instead of teaching old dogs new tricks.

Conflicts of interest

The authors declare no conflicts of interest.

REFERENCES

- Campos FG, Habr-Gama A, Nahas SC, Perez RO (2012) Abdominoperineal excision: evolution of a centenary operation. *Dis Colon Rectum* 55:844-853. doi:10.1097/DCR.0b013e31825ab0f7
- Heald RJ, Husband EM, Ryall RD (1982) The mesorectum in rectal cancer surgery--the clue to pelvic recurrence? *Br J Surg* 69:613-616
- Goligher JC, Dukes CE, Bussey HJ (1951) Local recurrences after sphincter saving excisions for carcinoma of the rectum and rectosigmoid. *Br J Surg* 39:199-211
- Dixon CF (1948) Anterior Resection for Malignant Lesions of the Upper Part of the Rectum and Lower Part of the Sigmoid. *Ann Surg* 128:425-442
- Miles WE (1971) A method of performing abdominoperineal excision for carcinoma of the rectum and of the

- terminal portion of the pelvic colon (1908). *CA Cancer J Clin* 21:361-364
6. Habr-Gama A (1972) *Indicações e Resultados da Retocolectomia Abdminoendoanal no Tratamento do Câncer de Reto*. University of Sao Paulo, Sao Paulo
 7. Bacon HE, Giambalvo GP (1948) Cancer of the rectum; its surgical management without colostomy and with preservation of the internal and external sphincter. *J Int Coll Surg* 11:452-463
 8. Black BM (1952) Combined abdominoendorectal resection; technical aspects and indications. *AMA Arch Surg* 65:406-416
 9. d AF, Morgan CN, Lloyd-Davies OV (1950) Discussion on conservative resection in carcinoma of the rectum. *Proc R Soc Med* 43:697-710
 10. Kapiteijn E, Putter H, van de Velde CJ, Cooperative investigators of the Dutch ColoRectal Cancer G (2002) Impact of the introduction and training of total mesorectal excision on recurrence and survival in rectal cancer in The Netherlands. *Br J Surg* 89:1142-1149. doi:10.1046/j.1365-2168.2002.02196.x
 11. Martling A, Holm T, Rutqvist LE, Johansson H, Moran BJ, Heald RJ, Cedermark B (2005) Impact of a surgical training programme on rectal cancer outcomes in Stockholm. *Br J Surg* 92:225-229. doi:10.1002/bjs.4834
 12. Fazio VW, Zutshi M, Remzi FH, Parc Y, Ruppert R, Furst A, Celebrezze J, Jr., Galanduk S, Orangio G, Hyman N, Bokey L, Tîret E, Kirchdorfer B, Medich D, Tietze M, Hull T, Hammel J (2007) A randomized multicenter trial to compare long-term functional outcome, quality of life, and complications of surgical procedures for low rectal cancers. *Ann Surg* 246:481-488; discussion 488-490. doi:10.1097/SLA.0b013e3181485617
 13. Heriot AG, Tekkis PP, Constantinides V, Paraskevas P, Nicholls RJ, Darzi A, Fazio VW (2006) Meta - analysis of colonic reservoirs versus straight coloanal anastomosis after anterior resection. *Br J Surg* 93:19 - 32. doi:10.1002/bjs.5188
 14. van Duijvendijk P, Slors F, Taat CW, Heisterkamp SH, Obertop H, Boeckxstaens GE (2003) A prospective evaluation of anorectal function after total mesorectal excision in patients with a rectal carcinoma. *Surgery* 133:56-65. doi:10.1067/msy.2003.3
 15. Baxter NN, Rothenberger DA, Lowry AC (2003) Measuring fecal incontinence. *Dis Colon Rectum* 46:1591-1605. doi:10.1097/01.DCR.0000098906.61097.1C
 16. Lange MM, van de Velde CJ (2011) Urinary and sexual dysfunction after rectal cancer treatment. *Nat Rev Urol* 8:51-57. doi:10.1038/nrurol.2010.206
 17. Ho VP, Lee Y, Stein SL, Temple LK (2011) Sexual function after treatment for rectal cancer: a review. *Dis Colon Rectum* 54:113-125. doi:10.1007/DCR.0b013e3181fb7b82
 18. Yamada K, Ogata S, Saiki Y, Fukunaga M, Tsuji Y, Takano M (2009) Long-term results of intersphincteric resection for low rectal cancer. *Dis Colon Rectum* 52:1065-1071. doi:10.1007/DCR.0b013e31819f5fa2
 19. Babcock WW (1947) Radical single stage extirpation for cancer of the large bowel, with retained functional anus. *Surg Gynecol Obstet* 85:1-7
 20. Haddad J, Simonsen O, Raia A, Netto AC (1961) [Complications of abdominoperineal rectosigmoidectomy in the treatment of acquired megacolon]. *Rev Paul Med* 59:1-8
 21. Fitzgerald TL, Brinkley J, Zervos EE (2011) Pushing the envelope beyond a centimeter in rectal cancer: oncologic implications of close, but negative margins. *J Am Coll Surg* 213:589-595. doi:10.1016/j.jamcollsurg.2011.07.020
 22. Parks AG (1972) Transanal technique in low rectal anastomosis. *Proc R Soc Med* 65:975-976
 23. Lyttle JA, Parks AG (1977) Intersphincteric excision of the rectum. *Br J Surg* 64:413-416
 24. Schiessel R, Karner-Hanusch J, Herbst F, Teleky B, Wunderlich M (1994) Intersphincteric resection for low rectal tumours. *Br J Surg* 81:1376-137825.
 25. Matthiessen P, Hallbook O, Rutegard J, Simert G, Sjodahl R (2007) Defunctioning stoma reduces symptomatic anastomotic leakage after low anterior resection of the rectum for cancer: a randomized multicenter trial. *Ann Surg* 246:207-214. doi:10.1097/SLA.0b013e3180603024
 26. Perez RO, Habr-Gama A, Seid VE, Proscurshim I, Sousa AH, Jr., Kiss DR, Linhares M, Sapucahy M, Gama-Rodrigues J (2006) Loop ileostomy morbidity: timing of closure matters. *Dis Colon Rectum* 49:1539 - 1545. doi:10.1007/s10350-006-0645-8
 27. Chow A, Tilney HS, Paraskeva P, Jeyarajah S, Zacharakis E, Purkayastha S (2009) The morbidity surrounding reversal of defunctioning ileostomies: a systematic review of 48 studies including 6,107 cases. *Int J Colorectal Dis* 24:711-723. doi:10.1007/s00384-009-0660-z
 28. West NP, Finan PJ, Anderin C, Lindholm J, Holm T, Quirke P (2008) Evidence of the oncologic superiority of cylindrical abdominoperineal excision for low rectal cancer. *J Clin Oncol* 26:3517-3522. doi:10.1200/JCO.2007.14.5961