



Ain Shams University

The Egyptian Journal of Medical Human Genetics

www.ejmhg.eg.net
www.sciencedirect.com



CASE REPORT

Bilateral iris, choroid, optic nerve colobomas and retinal detachment in an Egyptian patient with mild Baraitser–Winter syndrome

Rabah M. Shawky *, Heba Salah Abd-Elkhalek Elabd, Radwa Gamal

Pediatric Department, Genetics Unit, Ain Shams University, Egypt

Received 26 October 2013; accepted 4 November 2013

Available online 5 December 2013

KEYWORDS

Baraitser–Winter syndrome;
Optic nerve coloboma;
Ptosis;
Mental retardation

Abstract *Background:* Baraitser–Winter syndrome (BRWS) is a malformation syndrome, characterized by facial dysmorphism, ocular colobomata, pachygyria, and intellectual defects.

Case report: A 3.5 year old female child with BRWS has bilateral congenital ptosis, microcornea, iris, choroid, and optic nerve coloboma, retinal detachment, and mental retardation. She has also frontal bossing, prominent forehead, thick eyebrows, transverse slanting, hypertelorism, wide palpebral fissures, and nystagmus. The nose is broad, and bulbous with wide nares, and broad nasal tip. She has also low set posteriorly rotated ears, full cheeks, long philtrum, large mouth (macrostomia), gum hypertrophy, decayed teeth, high arched palate, pointed chin, short neck, low posterior hair line, partial left simian crease, and short fingers. MRI brain shows frontal polymicrogyria.

Conclusion: This patient represents a mild case of Baraitser–Winter syndrome.

© 2014 Production and hosting by Elsevier B.V. on behalf of Ain Shams University.

1. Introduction

Baraitser–Winter syndrome (BRWS), is a well-defined disorder characterized by distinct craniofacial features, ocular colobomata and neuronal migration defect [1]. Neuronal migration defect is a process by which nerve cells (neurons) move to their proper position in the developing brain. The most important brain abnormality related to this syndrome is pachygyria. Less

commonly, affected individuals have lissencephaly. These structural changes can cause mild to severe intellectual disability, developmental delay, and convulsions [2]. Actins are a family of essential cytoskeletal proteins implicated in nearly all cellular processes [3]. Among the six human genes encoding actins, only ACTB, and ACTG1 are ubiquitously expressed [1]. ACTB, and ACTG1 mutations have been reported to cause BRWS [4].

We report a patient with the features of BRWS after taking consent of the parents and approval of the ethics committee of our university.

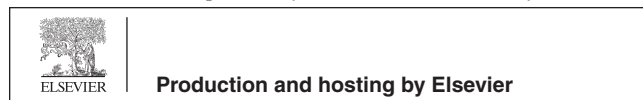
2. Case report

A 3.5 year old female child, fifth in order of birth of healthy first cousin consanguineous Egyptian parents. The patient

* Corresponding author. Tel.: +20 2 22585577.

E-mail address: shawkyrabah@yahoo.com (R.M. Shawky).

Peer review under responsibility of Ain Shams University.



was delivered at full term by cesarean section. Her birth weight was appropriate for gestational age. No problems were noted during pregnancy. The patient was referred to the Genetics Clinic, Pediatric Hospital, Ain Shams University because of delayed speech as well as abnormal features.

On examination the skull circumference is 51 cm (75th percentile), height is 89 cm (3rd percentile), and weight is 14.5 kg (50th percentile). The patient has coarse features, frontal bossing, prominent forehead, thick eyebrows. The eyes show transverse slanting, hypertelorism, bilateral microcornea, bilateral iris colobomata, wide palpebral fissures, bilateral congenital partial ptosis, and nystagmus. The patient has a broad bulbous nose, with broad nasal tip, and wide nares. The ears are low set, and posteriorly rotated. Also she has full cheeks, long philtrum, large mouth (macrostomia), gum hypertrophy, decayed teeth, high arched palate, pointed chin, short neck, low posterior hair line, and partial left simian crease, with short fingers. There is no limitation in joint movement (Figs. 1 and 2).

The patient has mild mental retardation, now she can walk, dress, and feed herself but she has delayed speech as she can say few words only. She started her first word at 2.5 years old.

Chest, cardiac, abdominal, neurological, and genital examinations are normal. Hearing is also normal.

ECHO cardiography, pelviabdominal ultrasonography are normal. Audiometry shows bilateral normal hearing. Karyotype revealed 46, XX normal female. Skeletal survey is normal. MRI brain shows frontal polymicrogyria, and IQ equals 56%.

Fundus examination revealed bilateral choroid coloboma and optic nerve coloboma. B-scan ultrasonography of the LT eye revealed normal ocular contour with an axial length of 20.00 mm, acoustic evidence of clear lens, and clear vitreous. There is localized retinal detachment over the coloboma, and acoustic evidence of optic nerve head coloboma. B-scan ultrasonography of the RT eye revealed normal ocular contour with an axial length of 20.00 mm, acoustic evidence of clear lens, and clear vitreous. Retina is acoustically in place with acoustic evidence of optic nerve head coloboma.

The patient has an older normal male, and a female sib. She has also another female sib with cleft lip and palate, who had repeated chest infection, poor weight gain and died at the age of 4 months from chest infection.

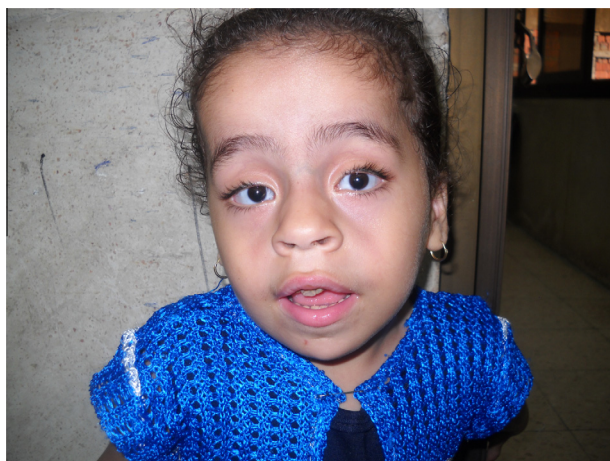

Figure 1 Facial features including frontal bossing, transverse slanting of palpebral fissures, bilateral partial ptosis, bilateral iris colobomata, microcornea, low set ears, and pointed chin.

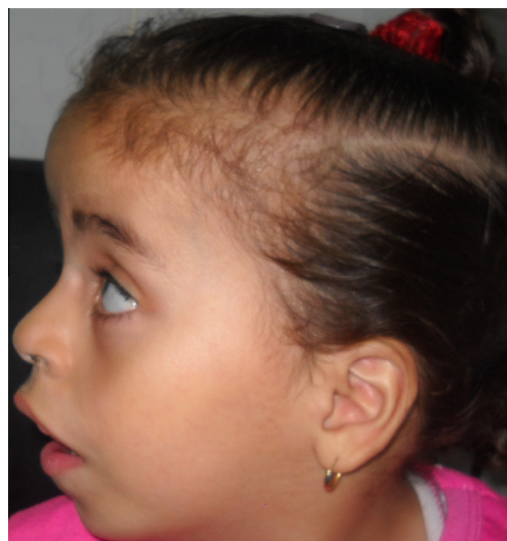

Figure 2 Showed short neck, and low set posteriorly rotated ears.

3. Discussion

Baraitser–Winter syndrome (BRWS), was originally described in a brother and sister and in an unrelated girl in 1988 [5]. It is a rare multiple congenital anomaly or a mental-retardation syndrome characterized by developmental delay, dysmorphic features, iris, ocular coloboma, congenital ptosis, hypertelorism, high-arched eyebrows, mental retardation, and multiple malformations also involving the brain. Other typical features include postnatal short stature, microcephaly, and intellectual disability, seizures and hearing loss [6,7,1,8]. BRWS may be considered another example of syndromic neuronal migration defect [6].

Diagnosis in our patient is based on clinical features which included the presence of bilateral colobomata of the iris, congenital ptosis, hypertelorism, mild mental retardation, short stature, wide nasal bridge, prominent cheeks which slope down to a pointed chin, long philtrum, large mouth, thin upper lip, and short neck with low posterior hair line. However our patient has a normal head size and although the forehead is prominent the metopic suture is normal with no trigonocephaly.

Although the ears are low set and posteriorly rotated, hearing is normal. Congenital or later onset progressive hearing loss is a common feature of BRWS. So our patient should be followed for hearing loss.

Our patient had bilateral iris, optic nerve, and choroidal colobomas, as well as retinal detachment. All reports about BRWS include iris coloboma only. To our knowledge there is only one report of a patient with BRWS who has iris, optic nerve, and choroidal colobomas [9].

Patients suffering from this syndrome have been also found to show brain anomalies such as pachygyria, cortical dysplasia, subcortical-band heterotopia (SBH), hippocampal malformations, periventricular heterotopia, and anterior predominant lissencephaly [7]. This specific pattern of brain anomalies falls in the agyria-pachygyria-band spectrum [6]. In most severe cases, the brain has a lissencephalic aspect, but some patients have a normal MRI. Intellectual disabilities range from mild

to profound. Drug resistant convulsions may be present. These findings usually correlate with severity of brain anomalies [10]. In our patient MRI brain showed frontal polymicrogyria (to our knowledge it was not described before) which explains the mild degree of mental retardation as well as the absence of convulsions.

In our patient there is no limitation of movement of large joints, however this may be apparent in adolescent and affect walking abilities in adulthood, kyphoscoliosis may also develop [10].

There is a report of another Arab female child, the product of an Egyptian mother and a Kuwaiti father whose phenotype fits BRWS. She has in addition a cardiac defect (patent ductus arteriosus), previously undescribed brain anomaly (choroid plexus cyst of cavum septum pellucidum), seizures, hypotonia and developmental delay [8].

In our patient no family history of similarly affected person was detected. So our patient most probably represents a sporadic occurrence in the family. However the presence of consanguinity does not exclude an autosomal recessive inheritance although the consanguinity rate among Egyptians is high (35.3%), especially among first cousins (86%) [11]. Two of the children reported by Baraitser and Winter (1988) were sibs, which is consistent with autosomal recessive inheritance [5]. However Riviere et al [1] reported that, with one exception, all reported patients with Baraitser–Winter syndrome have been sporadic. The genetic basis of BRWS was likely to result from de novo point mutations as neither familial recurrence nor consanguinity have been observed. They considered the sibs included in the original report by Baraitser and Winter (1988) to probably not have Baraitser–Winter syndrome as brain imaging was not performed, and cryptic chromosomal imbalance was not excluded [1].

A patient with a phenotype resembling that of BRWS was reported to have a pericentric inversion of chromosome 2, which was inherited from a phenotypically normal mother [12]. Since pericentric inversion of chromosome 2 does not cause an abnormal phenotype most probably this chromosomal anomaly does not allow any phenotype karyotype correlation [13]. The karyotype of our patient was normal.

Baraitser–Winter syndrome – 2 is caused by heterozygous mutation in the *ACTG1* gene on chromosome 17q25.3 [4]. Riviere et al. (2012) suggested a dominant-negative or gain-of-function mechanism for the disease-causing mutations as none of their subjects had deletions or protein-truncating mutations, which are an indication of haploinsufficiency. Further, 11 of 18 mutations detected (61%) disrupt the same two amino-acids (*ACTB* Arg196 and *ACTG1* Ser155). Although these could be hypermutable sites, mutation clustering suggests a gain-of-function effect. Also, patients with complete deletion or duplication of *ACTB* on chromosome 7p22-p12 most probably do not have Baraitser–Winter syndrome [1].

Mutations in *ACTB* cause a distinctly more severe phenotype (BRWS-1) than *ACTG1* mutations, despite the structural similarity of beta- and gamma-actins and their overlapping expression pattern. The spectrum of BRWS was expanded to include Fryns–Aftimos syndrome which is a rare severe multiple

congenital anomaly syndrome whose symptoms partially overlap with that of BRWS as an early and severe manifestation of BRWS [4].

In BRWS patients with *ACTB* mutation, short stature was present in 60%, post natal microcephaly in 66.7%, trigonocephaly in 80%, hearing loss in 50%, iris or retinal coloboma in 60%, while hypertelorism, high arched eyebrows, congenital ptosis, intellectual disabilities, and seizures are present in 100% of patients. On the other hand in patients with *ACTG1* mutations short stature was present in 42.9%, post natal microcephaly in 57.1%, trigonocephaly in 100%, hypertelorism in 87.5%, high arched eyebrows, congenital ptosis, and intellectual disabilities in 100%, hearing loss in 83.3%, iris or retinal coloboma in 71.4%, and seizures in 87.5% of the patients [1].

To conclude: Our patient was most probably a mild case of BRWS, and probably belongs to *ACTG1* mutation.

References

- [1] Riviere JB, van Bon BW, Hoischen A, Kholmanskikh SS, O'Roak BJ, Gilissen C, et al. De novo mutations in the actin genes *ACTB* and *ACTG1* cause Baraitser–Winter syndrome. *Nat Genet* 2012;44(4):440–4.
- [2] GTR Home > conditions/phenotypes > Baraitser–Winter syndrome 2. Available from: www.ncbi.nlm.gov/gtr/conditions/c3281235/.
- [3] Lambrechts A, Van Troys M, Ampe C. The actin cytoskeleton in normal and pathological cell mobility. *Int J Biochem Cell Biol* 2004;36:1890–909.
- [4] Donato DN, Rump A, Koenig R, Der Kaloustian VM, Halal F, Sonntag K, et al. Severe forms of Baraitser–Winter syndrome are caused by *ACTB* mutations rather than *ACTG1* mutations. *Eur J Hum Genet* 2013;12.
- [5] Baraitser M, Winter RM. Iris coloboma, ptosis, hypertelorism, and mental retardation: a new syndrome. *J Med Genet* 1988;25:41–3.
- [6] Rossi M, Guerrini R, Dobyns WB, Andria G, Winter RM. Characterization of brain malformations in the Baraitser–Winter syndrome and review of the literature. *Neuropediatrics* 2003;34(6):287–92.
- [7] Shiihara T, Maruyama K, Yamada Y, Nishimura A, Matsumoto N, Kato M, et al. A case of Baraitser–Winter syndrome with unusual brain MRI findings: pachygyria, subcortical-band heterotopia, and periventricular heterotopia. *Brain Dev* 2010;32(6):502–5.
- [8] Abo Henedy MMA, Marafie MJ, Abulhasan SJ. Baraitser–Winter syndrome: an additional Arab patient. *Egypt J Med Hum Genet* 2010;11(2):187–91.
- [9] Ganesh A, Al-Kindi A, Jain R, Raeburn S. The phenotypic spectrum of baraitser-winter syndrome: a new case and review of literature. *J AAPOS* 2005;9(6):604–6.
- [10] Orphanet. Baraitser–Winter syndrome. Available from: http://www.orpha.net/consor/cgi-bin/OC_Exp.php?Lng=EN&Expert=2995.
- [11] Shawky RM, El-Awady YM, Elsayed SM, Hamadan GE. Consanguineous matings among Egyptian population. *Egypt J Med Hum Genet* 2011;12(2):157–63.
- [12] Pallotta R. Iris coloboma, ptosis, hypertelorism, and mental retardation: a new syndrome possibly localised on chromosome 2. *J Med Genet* 1991;28(5):342–4.
- [13] Pallotta R, Dalpora L, Morgese G, et al. 5 di un caso di inversione pericentrica del cr 2. *Riv Siciliana Med Prenat Neonat Peditr Genet* 1983;4:183–5.