

Research article

## Resveratrol inhibits nonalcoholic fatty liver disease in rats

Luis Bujanda\*<sup>1</sup>, Elizabeth Hijona<sup>1</sup>, Mikel Larzabal<sup>2</sup>, Marta Beraza<sup>1</sup>, Pablo Aldazabal<sup>3</sup>, Nerea García-Urkiá<sup>3</sup>, Cristina Sarasqueta<sup>4</sup>, Angel Cosme<sup>1</sup>, Belen Irastorza<sup>5</sup>, Alberto González<sup>6</sup> and Juan I Arenas Jr<sup>1</sup>

Address: <sup>1</sup>Department of Gastroenterology, University of Country Basque, Donostia Hospital, Centro de Investigación Biomédica en Enfermedades Hepáticas y Digestivas (CIBERehd), San Sebastián, Spain, <sup>2</sup>Department of Pathology, Donostia Hospital, San Sebastián, Spain, <sup>3</sup>Department of Experimental Surgery, Donostia Hospital, San Sebastián, Spain, <sup>4</sup>Department of Epidemiology, Donostia Hospital, San Sebastián, Spain, <sup>5</sup>Department of Pharmacology, Donostia Hospital, San Sebastián, Spain and <sup>6</sup>Department of Microbiology, Donostia Hospital, San Sebastián, Spain

Email: Luis Bujanda\* - [medik@telefonica.net](mailto:medik@telefonica.net); Elizabeth Hijona - [castro@medynet.com](mailto:castro@medynet.com); Mikel Larzabal - [castro@medynet.com](mailto:castro@medynet.com); Marta Beraza - [medik@telefonica.net](mailto:medik@telefonica.net); Pablo Aldazabal - [medik@telefonica.net](mailto:medik@telefonica.net); Nerea García-Urkiá - [medik@telefonica.net](mailto:medik@telefonica.net); Cristina Sarasqueta - [medik@telefonica.net](mailto:medik@telefonica.net); Angel Cosme - [medik@telefonica.net](mailto:medik@telefonica.net); Belen Irastorza - [medik@telefonica.net](mailto:medik@telefonica.net); Alberto González - [castro@medynet.com](mailto:castro@medynet.com); Juan I Arenas - [castro@medynet.com](mailto:castro@medynet.com)

\* Corresponding author

Published: 9 September 2008

Received: 1 March 2008

*BMC Gastroenterology* 2008, **8**:40 doi:10.1186/1471-230X-8-40

Accepted: 9 September 2008

This article is available from: <http://www.biomedcentral.com/1471-230X/8/40>

© 2008 Bujanda et al; licensee BioMed Central Ltd.

This is an Open Access article distributed under the terms of the Creative Commons Attribution License (<http://creativecommons.org/licenses/by/2.0>), which permits unrestricted use, distribution, and reproduction in any medium, provided the original work is properly cited.

### Abstract

**Background:** The prevalence of nonalcoholic fatty liver disease (NAFLD) is high. NAFLD is linked to obesity, diabetes mellitus, and hypertriglyceridemia. Approximately 20% of patients with NAFLD will eventually develop cirrhosis. Our purpose was to investigate whether resveratrol decreased hepatic steatosis in an animal model of steatosis, and whether this therapeutic approach resulted in a decrease in tumor necrosis factor  $\alpha$  (TNF- $\alpha$ ) production, lipid peroxidation and oxidative stress.

**Methods:** Male Wistar CRL: Wi (Han) (225 g) rats were randomized into three groups. A control group (n = 12) was given free access to regular dry rat chow for 4 weeks. The steatosis (n = 12) and resveratrol (n = 12) groups were given free access to feed (a high carbohydrate-fat free modified diet) and water 4 days per week, and fasted for the remaining 3 days for 4 weeks. Rats in the resveratrol group were given resveratrol 10 mg daily by the oral route. All rats were killed at 4 weeks and assessed for fatty infiltration and bacterial translocation. Levels of TNF- $\alpha$  in serum, hepatic malondialdehyde (MDA), oxidative stress (superoxide dismutase, glutathione peroxidase, catalase and nitric oxide synthase) and biochemical parameters were measured.

**Results:** Fat deposition was decreased in the resveratrol group as compared to the steatosis group (Grade I vs Grade 3,  $P < 0.05$ ). TNF- $\alpha$  and MDA levels were significantly increased in the steatosis group (TNF- $\alpha$ ;  $33.4 \pm 5.2$  vs  $26.24 \pm 3.47$  pg/ml and MDA;  $9.08 \pm 0.8$  vs  $3.17 \pm 1.45$   $\mu$ M respectively,  $P < 0.05$ ). This was accompanied by increased superoxide dismutase, glutathione peroxidase and catalase and decreased nitric oxide synthase in the liver of resveratrol group significantly ( $P < 0.05$  vs steatosis group). Bacterial translocation was not found in any of the groups. Glucose levels were decreased in the group of rats given resveratrol ( $P < 0.05$ ).

**Conclusion:** Resveratrol decreased NAFLD severity in rats. This effect was mediated, at least in part, by TNF- $\alpha$  inhibition and antioxidant activities.

## Background

Nonalcoholic fatty liver disease (NAFLD) is characterized by histological changes similar to those seen in subjects with alcoholic hepatitis but in whom alcohol intake is absent or poorly significant. Factors promoting NAFLD development include obesity and diabetes. From 69% to 100% of patients with NAFLD are obese [1]. NAFLD prevalence in severe obesity is greater than 30% [2,3]. Because of all these reasons, it is important to have animal models that allow us to study the effect of different substances on NAFLD.

Polyphenols have a variety of biological functions, including antioxidant, anti-inflammatory, and anticancer effects [4]. Resveratrol is a phytoalexin polyphenolic compound occurring in various plants, including grapes, berries, and peanuts. Multiple lines of compelling evidence suggest its beneficial effects on neurological, hepatic, and cardiovascular systems. The potential mechanisms responsible for its biological activities include downregulation of the inflammatory response through inhibition of the synthesis and release of pro-inflammatory mediators, modification of eicosanoid synthesis, inhibition of Kupffer cells and adhesion molecules, inhibition of inducible nitric oxide synthase and cyclooxygenase-2 (COX-2) via its inhibitory effects on nuclear factor ( $\kappa$ B) (NF- $\kappa$ B) or the activator protein-1 (AP-1) (5,6). In our previous studies, resveratrol was seen to decrease the liver lesions and transaminase elevations caused by alcohol in mice [7].

Our purpose now was to investigate first whether resveratrol decreased hepatic steatosis in an animal model of steatosis, and second, whether this therapeutic approach resulted in a decrease in tumor necrosis factor  $\alpha$  (TNF- $\alpha$ ) production and oxidative stress.

## Methods

### Animals and diets

Wistar CRL: Wi (Han) male rats (Charles River) weighing approximately 225 g were used. All experiments were conducted in accordance with the Guide for the Care and Use of Laboratory Animals published by the US Public Health Service. Animals were kept on a regular 12-hour light period at a controlled temperature ( $25 \pm 2^\circ\text{C}$ ). The modified diet (high carbohydrate-fat free) consisted of carbohydrates (80%, as starch), protein (16%, as casein), and vitamins and minerals (4%) (PANLAB, Barcelona, Spain). The standard diet consisted of a balanced diet containing carbohydrates (51%), protein (16%), vitamins and minerals (4%), and lipids (3%). The standard diet contained 2.9 kcal/g, and the modified diet 3.58 kcal/g. The model was based on the model reported by Delzenne in 1997 [8].

## Experimental procedures

Rats were distributed into three groups: control, steatosis and resveratrol. The control group was given free access to feed and drink. The control group was fed a standard diet. The steatosis and resveratrol groups were given free access to feed and water 4 days per week, and were fasted for the remaining 3 days (access to water was only allowed). Feed consisted of a modified diet. During the dietary restriction cycles, steatosis and resveratrol groups were fed a modified diet (Figure 1). Rats in the resveratrol group were given resveratrol 10 mg daily by the oral route through an orogastric catheter. Resveratrol was diluted in 1 mL of water. Resveratrol was obtained from SIGMA Chemical, (Pool, Dorset, UK).

All rats were killed after completing 4 cycles of feeding and fasting, i.e. 28 days after study start. The timing of killing was decided based on previous trials in which hepatic damage was seen to be very high after four weeks in the steatosis group. Feed taken by the rats and weight of the animals were controlled at the end of the study. At the end of the study, all rats were anesthetized using an intraperitoneal injection of an overdose (45 mg/kg) of sodium pentobarbital.

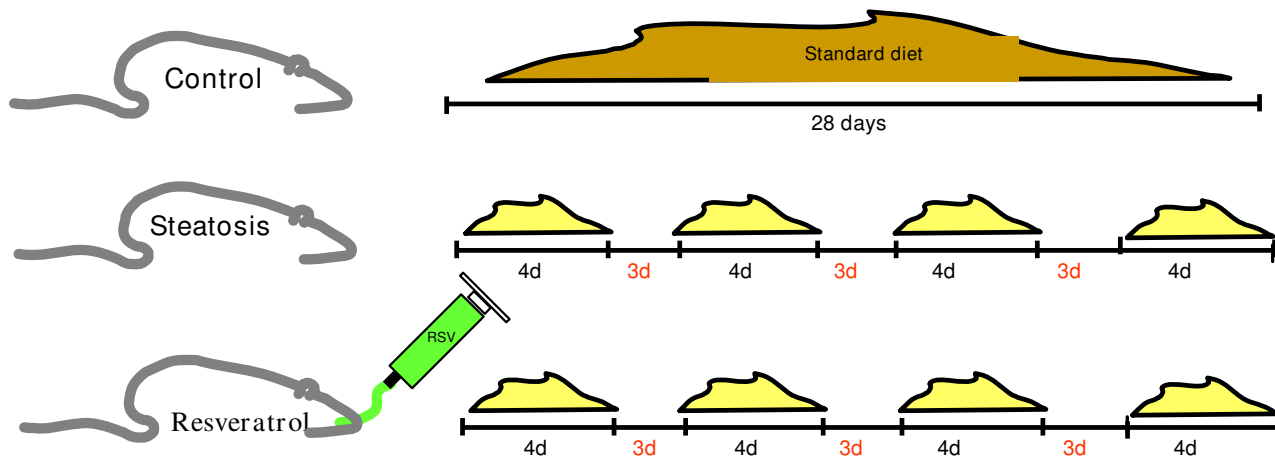
## Pathological evaluation

A histological study was performed following a midline laparotomy to remove the liver. Liver was weighed, and liver tissue samples taken at the time the rat was killed were immediately placed in 10% buffered formalin and subsequently embedded in paraffin. Hepatic index was obtained by dividing liver weight by rat weight  $\times 100$ . Liver sections were stained with hematoxylin and eosin using standard techniques. Sections were viewed without knowing the treatment group to which each animal belonged. Biopsies were classified into four grades depending on fat accumulation using the Brunt et al [9] classification, assigning grade 0 when no fat was found in the liver, grade 1 when fat vacuoles were seen in less than 33% of hepatocytes, grade 2 when 33%–66% of hepatocytes were affected by fat vacuoles, and grade 3 when fat vacuoles were found in more than 66% of hepatocytes. The deposit of fat was classified in macrovesicular, microvesicular and mixed. Two experienced pathologists blinded to the experiment evaluated all samples. Agreement between both pathologists was determined.

## Biochemical measurements

Laboratory parameters such as ALT, glucose, and albumin were measured using an automatic analyzer (Roche/Hitachi Modular Analytics, Roche Diagnostics, Mannheim, Germany) at  $37^\circ\text{C}$ .

## Model of steatosis



**Figure 1**  
**NAFLD model used in the study.**

Serum TNF- $\alpha$  levels was measured using ELISA kits (R&D Systems, Boston, MA-Catalog Number RTA00). TNF- $\alpha$  levels was expressed in pg/mL.

### Lipid peroxidation

Malondialdehyde (MDA) was measurement in hepatic tissue. For hepatic malondialdehyde (MDA) determination, weigh 25 mg of tissue and add 250  $\mu$ l of RIPA buffer with protease inhibitors. Sonicate for 15 seconds at 40 V over ice and centrifuge at 1.600  $\times$  g for 10 minutes at 4°C. We use the supernatant for analysis. MDA was quantified using the thiobarbituric acid reaction as described by Ohkawa [10]. MDA levels were measured using Cayman's TBARS Assay Kit. MDA levels were expressed in  $\mu$ M.

### Oxidative stress

Superoxide dismutase, catalase, glutathione peroxidase, and nitric oxide synthase levels as oxidant/antioxidant biochemical parameters were measurement in hepatic tissue. Levels were quantified using Cayman's (Cayman Chemical Company, Ann Arbor – Michigan, USA) assay kit following the instructions of the manufacturer.

### Bacterial translocation determination

Samples of mesenteric lymph nodes and portal and peripheral blood when available were collected under sterile conditions before rat death and cultured in MacConkey agar (Oxoid), Columbia sheep blood (Oxoid), and

Esculin-Bile-Azide agar (Merck), and incubated at 37°C for 48 h. Bacterial translocation was defined as a positive culture of mesenteric lymph nodes. Systemic infections were defined as a positive culture of any of the remaining biological samples.

### Statistical analysis

Data are expressed as the mean  $\pm$  SD statistical analysis was performed with non-parametric Mann-Whitney test. Standard calculations were performed using SPSS version 16.0. Results were considered statistically significant at  $P < 0.05$ .

### Results

Rat weight significantly increased in the control group ( $221 \pm 10$  g to  $355 \pm 16$  g), remained similar in the group with fatty liver disease ( $222 \pm 12$  g to  $226 \pm 14$  g), and decreased in the resveratrol group ( $218 \pm 9$  g to  $201 \pm 11$  g). Hepatic index was  $4.47 \pm 0.63$ ,  $4.38 \pm 0.34$ , and  $3.9 \pm 0.31$  in the steatosis, resveratrol, and control groups respectively.

### Histological evaluation

No fatty infiltration was seen in the control group (Figure 2). Mean fatty infiltration in the steatosis group was 3 (Table 1). Fat deposit in the steatosis group was classified as macrovesicular. Mean fatty infiltration in the resveratrol group was 1, and fat deposit was mixed. Fatty infiltra-

**Table 1: Grades of fatty infiltration in rats and groups.**

Group	Rats (n°)	Steatosis grades			
		0	1	2	3
Control	12	12	-	-	-
Steatosis	12	-	-	2	10
Resveratrol	12	-	10	2	-

tion in the resveratrol group was significantly lower than in the steatosis group ( $P < 0.05$ ). Inter-observer agreement was 0.84 and intra-observer agreement was 0.79.

**Laboratory findings**

ALT levels were  $40 \pm 11$  IU/L in the control group,  $34 \pm 9$  IU/L in the steatosis group, and  $34 \pm 11$  IU/L in the resveratrol group ( $P < 0.05$  between control group vs steatosis and resveratrol groups). Glucose levels were  $230 \pm 45$  mg/dl in the control group,  $162 \pm 25$  mg/dl in the steatosis group, and  $145 \pm 33$  mg/dl in the resveratrol group. Statistically significant differences in glucose levels were seen between the control and steatosis groups and the resveratrol group ( $P < 0.05$  between control group vs steatosis and resveratrol groups). Albumin levels were  $38.1 \pm 2.3$  g/dl in the control group,  $40.54 \pm 1.87$  g/dl in the steatosis group, and  $41.1 \pm 2.9$  g/dl in the resveratrol group ( $P < 0.05$  between control group vs steatosis and resveratrol groups).

**TNF- $\alpha$  and lipid peroxidation (MDA)**

Figure 3 shows that TNF- $\alpha$  levels were increased in the steatosis group as compared to the other two groups ( $P < 0.05$ ). MDA was significantly elevated in the steatosis group as compared to the control group ( $\mu\text{M}$ ). MDA liver levels were lower in the resveratrol group than in the steatosis group ( $P < 0,001$ ).

**Oxidative stress**

The data in table 2 demonstrate that resveratrol administration significantly decreased the effects of the stress oxidative in the hepatic tissue.

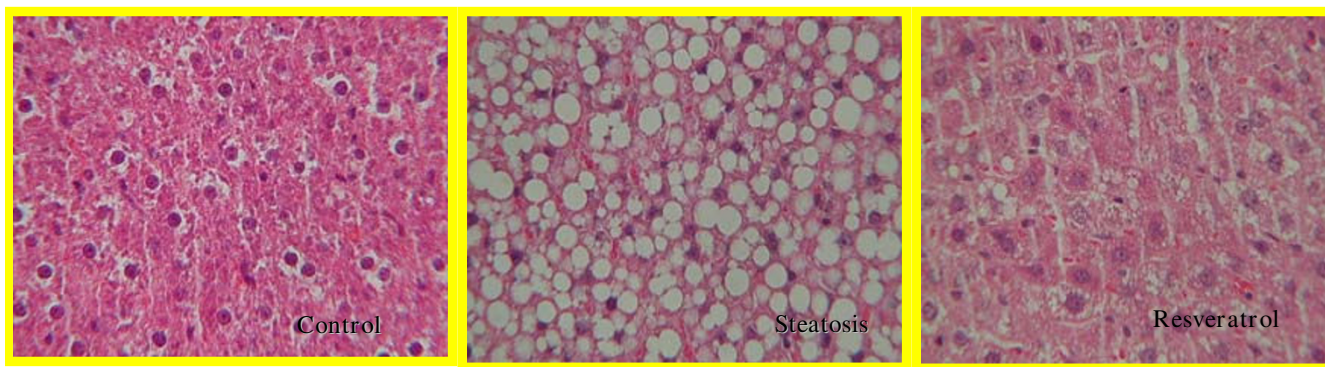
**Bacterial translocation and systemic infections**

Cultures of samples of portal blood, peripheral blood, and perihepatic lymph nodes were negative in all three groups tested.

**Discussion**

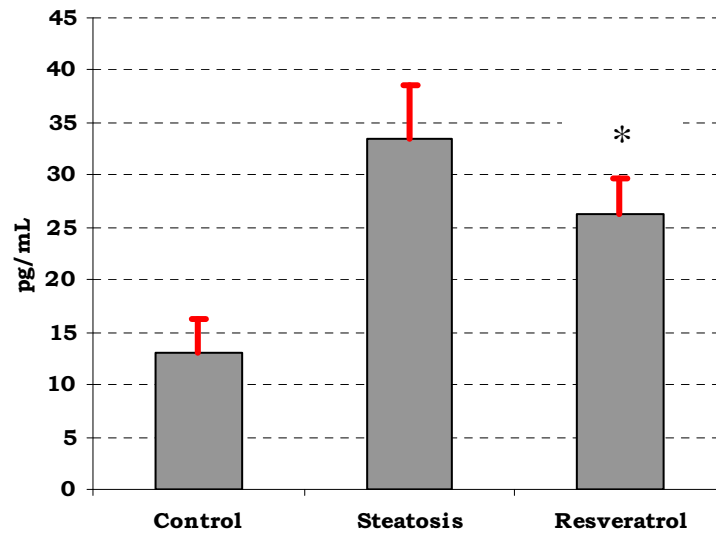
NAFLD represents a wide spectrum of disorders, the hallmark of which is hepatic steatosis. NAFLD was considered a benign condition, but is now increasingly recognized as a major cause of liver-related morbidity and mortality. Insulin resistance is the basis for accumulation of free fatty acids and triglyceride storage in hepatocytes or steatosis. Oxidative stress from steatotic hepatocytes leads to lipid peroxidation, impaired mitochondrial and peroxisomal oxidation of fatty acids, and cytokine release [11]. Endotoxins and endotoxin-inducible cytokines, particularly TNF- $\alpha$ , are required for the pathogenesis of NAFLD in experimental animals. Therefore the TNF- $\alpha$  plays an important role in NAFLD [12,13].

In our study, hepatic steatosis was significantly decreased in rats treated with resveratrol. This effect was associated to a decreased TNF- $\alpha$  production. Different studies have shown that resveratrol decreases TNF- $\alpha$  production. We therefore think that the decreased liver damage in a model of liver steatosis could be related to its anti-TNF- $\alpha$  effect. Other studies [14-16] have shown a relationship between NAFLD and TNF- $\alpha$  levels. Our study shows that TNF- $\alpha$  levels were increased in both the steatosis and resveratrol groups as compared to the control group, suggesting that TNF- $\alpha$  is an important factor in liver damage occurring in NAFLD. However, TNF- $\alpha$  levels were lower in the resvera-



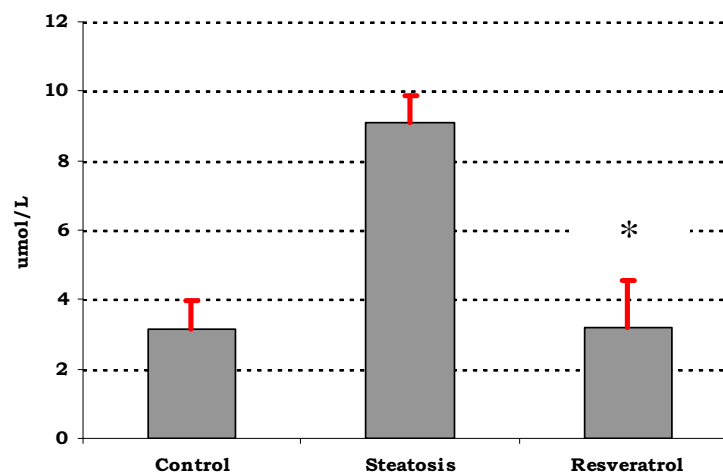
**Figure 2**  
**Histological study in the different groups (control, steatosis, and resveratrol).** Thus, the control group is shown to have no fat vacuoles. A great number of vacuoles were seen in the steatosis group, while the resveratrol group had much less vacuoles of a lower size. Hematoxylin and eosin staining of liver tissue  $\times 40$ .

A.



\* $P < 0.05$  as compared to steatosis group

B.



\* $P < 0.05$  as compared to steatosis group

**Figure 3**

**TNF- $\alpha$  and MDA levels.** A. TNF- $\alpha$  levels in different groups (pg/mL). TNF- $\alpha$  levels were lower in the resveratrol groups as compared to the control and steatosis groups. B. Levels of MDA in different groups ( $\mu$ M). MDA levels were lower in the resveratrol groups as compared to the steatosis group (\* $P < 0.05$ ).

**Table 2: Changes of superoxide dismutase, catalase, glutathione peroxidase and nitric oxide synthase in each group.**

	Control	Steatosis	Resveratrol
Superoxide dismutase (U/ml)	2.74 ± 2.08	1.15 ± 2.1	3.1 ± 3.2*
Catalase (nmol/min/ml)	3807 ± 315	284 ± 26	713 ± 50*
Glutathione peroxidase (nmol/min/ml)	449 ± 27	6.5 ± 3	406 ± 25*
Nitric oxide synthase (uM)	1.9 ± 0.6	9.17 ± 0.9	4.19 ± 0.7*

\**P* < 0.05 vs steatosis group

control group than in the steatosis group. We therefore think that TNF- $\alpha$  is an important factor for development of this condition. In agreement with other authors [17-19], we did not consider administration of anti-TNF- $\alpha$  or use of another group given repeated TNF- $\alpha$  doses because adequate evidence was already available. Infliximab (anti-TNF- $\alpha$ ) reverses the steatosis and the expression of the proinflammatory markers (TNF- $\alpha$ , IL6, IL-1B) and improves insulin signal transduction in a model of steatosis in rats [20]. The presence of a control group (reference group) allows to compare the effects of the modified diet (high carbohydrate-fat free) on the liver (steatosis group) and the effect of the resveratrol (resveratrol group).

Bacterial translocation from the intestinal lumen to mesenteric lymph nodes is considered to be one of the main events in the pathogenesis of spontaneous bacterial peritonitis and other infections in cirrhosis. TNF- $\alpha$  is involved in the occurrence of bacterial translocation in rats with cirrhosis [21]. We therefore considered whether bacterial translocation acting as a stimulus for TNF- $\alpha$  production occurred in our model. Cultures of samples of portal blood, peripheral blood, and perihepatic lymph nodes were negative in all three groups tested, which rules out this mechanism as responsible for TNF- $\alpha$  elevation.

There are many models of NAFLD liver injuries in animals [22,23]. In rats, cycles of feeding and fasting with hyper-tonic high calorie diets have been seen to induce fatty liver [8]. In this study, we used feeding and fasting cycles with a modified diet because it is a fast, easy procedure that results in pathological changes similar to those occurring in humans. In our model the deposit of fatty acids and triglyceride storage in hepatocytes is produced by insulin resistance [8,11]. Insulin resistance is the basis for accumulation of free fatty acids and triglyceride storage in hepatocytes, and represents the "first hit" in the pathogenesis of NAFLD [11]. Body mass significantly decreased with the high carbohydrate-fat free diet and dietary restriction. This may be due to a metabolic imbalance of carbohydrate, protein, and fat. However, hepatic index was higher in the group with steatosis as compared to the resveratrol and control groups. Such higher hepatic index occurred despite the increased rat weight in the steatosis group, which means that resveratrol acts by decreasing fat

accumulation in the liver and fat weight, and therefore decreases hepatic index.

ALT is a relatively liver-specific aminotransferase. Elevation of ALT activity in serum is the result of leakage from damaged cells and therefore reflects hepatocyte damage. Elevated transaminase levels correlated strongly with NAFLD [2]. ALT levels were significantly lower in the resveratrol group as compared to the control group (34 IU/L versus 40 IU/L) and similar to steatosis group levels. In the group treated with resveratrol, lower glucose levels and higher serum albumin levels as compared to untreated rats were also found. Studies have reported increases in serum TNF- $\alpha$  levels in humans with insulin resistance [24]. Hyperglycemia and insulin resistance are associated to the presence of NAFLD [2,25]. Changes in plasma levels of markers predicting for the onset of diabetes occurred with a high carbohydrate-fat free diet [25]. Glucose levels were decreased in the resveratrol group [26], as occurred in our study. Other studies have also noted that resveratrol improved insulin sensitivity, lowered plasma glucose, and increased mitochondrial capacity in obese mice [27]. Insulin resistance was not analyzed in our study.

High hepatic MDA levels were found in the steatosis group, in agreement with other studies [28]. Resveratrol improved MDA levels. Oxidative stress is believed to play an important role in pathogenesis of NAFLD. It is likely to be involved in disease progression from steatosis to steatohepatitis and potentially cirrhosis. It has been shown that chronic oxidative stress, generated through oxidation of cytotoxic free fatty acids, may lead to cytokine upregulation and depletion of hepatic antioxidant levels [29,30]. In addition, enhanced lipid peroxidation leads to the generation of by-products, such as MDA, which have been shown to further stimulate cytokine production. They are involved in hepatic stellate cell activation, fibrogenesis, and enhanced extracellular matrix protein deposition [28]. Resveratrol caused increased of hepatic antioxidant levels as superoxide dismutase, glutathione peroxidase and catalase and decreased nitric oxide synthase in the liver.

Fatty acid oxidation is an important source of reactive oxygen species in fatty livers. Some consequences of increased

reactive oxygen species levels include an impaired protein stability, membrane destruction via lipid peroxidation, and release of proinflammatory cytokines (increased TNF- $\alpha$  levels) [31]. Reactive oxygen species may attack polyunsaturated fatty acids and initiate lipid peroxidation within the cell, which results in MDA formation. Oxidants may not only act as toxic substances, but also as second messengers (activation of transcription factor NF- $\kappa$ B) [32]. Resveratrol increases insulin sensitivity and insulin-like growth factor-1 levels (IGF-1) [28]. Resveratrol would also act by decreasing lipid peroxidation and reactive oxygen species release, thereby decreasing inflammatory response and liver lesions [33,34]

Recently, researches suggest that other mechanisms the resveratrol improve in NAFLD are by the activation of AMP-activated protein kinase and the activation of SIRT1 [35-37].

## Conclusion

In summary, our study shows that resveratrol decreases liver steatosis in rats and that its effect is mediated, at least partly, by TNF- $\alpha$  and antioxidant activities. In our model, bacterial translocation was not responsible for TNF- $\alpha$  elevation. Further studies are warranted to determine whether resveratrol decreases or prevents liver steatosis.

## Competing interests

The authors declare that they have no competing interests.

## Authors' contributions

LB, EH, MB, PA, and NG-U participated in study conception and design, manuscript preparation, and practical conduct of the study. CS collected and analyzed data and was involved in study conduct. AC and JA critically reviewed the manuscript. AG and BI carried out biochemical and microbiological tests. ML and EH performed the pathological examinations. All authors have read and approved the manuscript.

## Acknowledgements

We thank Koro Berasarte for her technical assistance.

This work was supported by grants from the Plan Nacional I+D, Instituto de Salud Carlos III, Madrid, Spain (FIS: PI04/1730) and the Department of Health of the Basque Government (2005-111096 y 2007-021011). CIBERehd is funded by the Instituto de Salud Carlos III.

## References

- Sheth SG, Gordon FD, Chopra S: **Nonalcoholic steatohepatitis.** *Ann Intern Med* 1997, **126(2)**:137-45.
- Gholam PM, Flancbaum L, Machan JT, Charney DA, Kotle DP: **Non-alcoholic fatty liver disease in severely obese subjects.** *Am J Gastroenterol* 2007, **102(2)**:399-408.
- Arun J, Clements RH, Lazenby AJ, Leeth RR, Abrams GA: **The prevalence of nonalcoholic steatohepatitis is greater in morbidly obese men compared to women.** *Obes Surg* 2006, **16(10)**:1351-1358.
- Shapiro H, Halpern Z, Bruck R: **Polyphenols in the treatment of inflammatory bowel disease and acute pancreatitis.** *Gut* 2007, **56(3)**:426-435.
- Jang M, Cai L, Udeani GO, Slowing KV, Thomas CF, Beecher CW, Fong HH, Farnsworth NR, Kingonorn AD, Metha RG, Moon RC, Pezzuto JM: **Cancer chemopreventive activity of resveratrol, a natural product derived from grapes.** *Science* 1997, **275(5297)**:218-220.
- de la Lastra CA, Villegas I: **Resveratrol as an anti-inflammatory and anti-aging agent: mechanisms and clinical implications.** *Mol Nutr Food Res* 2005, **49(5)**:405-430.
- Bujanda L, García-Barcina M, Gutiérrez-de Juan V, Bidaurrezaga J, Fernández de Luco M, Gutiérrez-Stampa MA, Larzabal M, Hijona E, Sarasqueta C, Echenique-Elizondo M, Arenas JI: **Effect of resveratrol on alcohol-induced mortality and liver lesions in mice.** *BMC Gastroenterology* 2006, **6**:35.
- Delzenne NM, Hernaux NA, Taper HS: **A new model of acute liver steatosis induced in rats by fasting followed by refeeding a high carbohydrate-fat free diet. Biochemical and morphological analysis.** *J Hepatol* 1997, **26(4)**:880-885.
- Brunt EM, Janney CG, Di Bisceglie AM, Neuschwander-Tetri BA, Bacon BR: **Nonalcoholic steatohepatitis: a proposal for grading and staging the histological lesions.** *Am J Gastroenterol* 1999, **94(9)**:2467-2474.
- Ohkawa H, Ohishi N, Yagi K: **Assay for lipid peroxides in animal tissues by thiobarbituric acid reaction.** *Anal Biochem* 1979, **95(2)**:351-358.
- Parekh S, Anania FA: **Abnormal lipid and glucose metabolism in obesity: implications for nonalcoholic fatty liver disease.** *Gastroenterology* 2007, **132(6)**:2191-2207.
- James O, Day C: **Non-alcoholic steatohepatitis: another disease of affluence.** *Lancet* 1999, **353(9165)**:1634-1636.
- Day CP: **Genes or environment to determine alcoholic liver disease and non-alcoholic fatty liver disease.** *Liver International* 2006, **26(9)**:1021-1028.
- Chu CJ, Lu RH, Wang SS, Chang FY, Wu SL, Lu CL, Chun BC, Chang CY, Wu MY, Lee SD: **Risk factors associated with non-alcoholic fatty liver disease in Chinese patients and the role of tumor necrosis factor- $\alpha$ .** *Hepatogastroenterology* 2007, **54(79)**:2099-2102.
- Jarrar MH, Baranova A, Collantes R, Ranard B, Stepanova M, Bennett C, Fang Y, Elariny H, Goodman Z, Chandhoke V, Younossi ZM: **Adipokines and cytokines in non-alcoholic fatty liver disease.** *Aliment Pharmacol Ther* 2008, **27(5)**:412-421.
- Manco M, Marcellini M, Giannone G, Nobili V: **Correlation of serum TNF- $\alpha$  levels and histologic liver injury scores in pediatric nonalcoholic fatty liver disease.** *Am J Clin Pathol* 2007, **127(6)**:954-960.
- Seo YS, Kim JH, Jo NY, Choi KM, Baik SH, Park JJ, Kim JS, Byun KS, Bak YT, Lee CH, Kim A, Yeon JE: **PPAR agonists treatment is effective in a nonalcoholic fatty liver disease animal model by modulating fatty-acid metabolic enzymes.** *J Gastroenterol Hepatol* 2008, **23(1)**:102-109.
- Lieber CS, DeCarli LM, Leo MA, Mak KM, Ponomarenko A, Ren C, Wang X: **Beneficial effects versus toxicity of medium-chain triacylglycerols in rats with NASH.** *J Hepatol* 2008, **48(2)**:318-26.
- Yalniz M, Bahcecioglu IH, Kuzu N, Poyrazoglu OK, Bulmus O, Celebi S, Ustundag B, Ozercan IH, Sahin K: **Preventive role of genistein in an experimental non-alcoholic steatohepatitis model.** *J Gastroenterol Hepatol* 2007, **22(11)**:2009-14.
- Barbuio R, Milanski M, Bertolo MB, Saad MJ, Velloso LA: **Infliximab reverses steatosis and improves insulin signal transduction in liver of rats fed a high-fat diet.** *J Endocrinol* 2007, **194(3)**:539-550.
- Francés R, Chiva M, Sánchez E, González-Navajas JM, Llovet T, Zapater P, Soriano G, Muñoz C, Balanzó J, Pérez-Mateo M, Song X, Guarner C, Such J: **Bacterial translocation is downregulated by anti-TNF- $\alpha$  monoclonal antibody administration in rats with cirrhosis and ascites.** *J Hepatol* 2007, **46(5)**:797-803.
- Lieber CS, Leo MA, Mak KM, Xu Y, Cao Q, Ren C, Ponomarenko A, DeCarli LM: **Model of nonalcoholic steatohepatitis.** *Am J Clin Nutr* 2004, **79(3)**:502-509.
- Koteish A, Diehl AM: **Animal models of steatosis.** *Semin Liver Dis* 2001, **21(1)**:89-104.
- Shoelson SE, Herrero L, Naaz A: **Obesity, inflammation and insulin resistance.** *Gastroenterology* 2007, **132(6)**:2169-2180.

25. Ota T, Takamura T, Kurita S, Matsuzawa N, Kita Y, Uno M, Akahori H, Misu H, Sakurai M, Zen Y, Nakamura Y, Kaneko S: **Insulin resistance accelerates a dietary rat model of nonalcoholic steatohepatitis.** *Gastroenterology* 2007, **132(1)**:282-293.
26. Baur JA, Pearson KJ, Price NL, Jamieson HA, Lerin C, Kalra A, Prabhu VV, Allard JS, Lopez-Lluch G, Lewis K, Pistell PJ, Poosala S, Becker KG, Boss O, Gwinn D, Wang M, Ramaswamy S, Fishbein KW, Spencer RG, Lakatta EG, Le Couteur D, Shaw RJ, Navas P, Puetzserver P, Ingram KD, de Cabo R, Sinclair DA: **Resveratrol improves health and survival of mice on a high-calorie diet.** *Nature* 2006, **444(7117)**:337-342.
27. Milne JC, Lambert PD, Schenk S, Carney DP, Smith JJ, Gagne DJ, Jin L, Boss O, Perni RB, Vu CB, Bemis JE, Xie R, Disch JS, Ng PY, Nunes JJ, Lynch AV, Yang H, Galonek H, Israelian K, Choy W, Iffland A, Lavu S, Medvedik O, Sinclair DA, Olesfsky JM, Jirousek MR, Elliott PJ, Westphal CH: **Small molecule activators of SIRT1 as therapeutics for the treatment of type 2 diabetes.** *Nature* 2007, **450(7170)**:712-716.
28. Thong-Ngam D, Samuhasaneeto S, Kulaputana O, Klaikeaw N: **N-acetylcysteine attenuates oxidative stress and liver pathology in rats with non-alcoholic steatohepatitis.** *World J Gastroenterol* 2007, **13(38)**:5127-5132.
29. Garcia-Ruiz C, Colell A, Morales A, Kaplowitz N, Fernandez Checa JC: **Role of oxidative stress generated from the mitochondrial electron transport chain and mitochondrial glutathione status in loss of mitochondrial function and activation of transcription factor nuclear factor-kappa B: studies with isolated mitochondria and rat hepatocytes.** *Mol Pharmacol* 1995, **48(5)**:825-834.
30. Weltman MD, Farrell GC, Liddle C: **Increased hepatocytes CYP2E1 expression in a rat nutritional model of hepatic steatosis with inflammation.** *Gastroenterology* 1996, **111(6)**:1645-1653.
31. Browning JD, Horton JD: **Molecular mediators of hepatic steatosis and liver injury.** *J Clin Invest* 2004, **114(2)**:147-152.
32. Kono H, Rusyn I, Yin M, Gäbele E, Yamashina S, Dikalova A, Kadiiska MB, Connor HD, Mason RP, Segal BH, Bradford BU, Holland SM, Thurman RG: **NADPH oxidase-derived free radicals are key oxidants in alcohol-induced liver disease.** *J Clin Invest* 2000, **106(7)**:867-872.
33. Leonard SS, Xia C, Jiang BH, Stinefelt B, Klandorf H, Harris GK, Shi X: **Resveratrol scavenges reactive oxygen species and effects radical-induced cellular responses.** *Biochem Biophys Res Commun* 2003, **309(4)**:1017-1026.
34. Wu SL, Yu L, Meng KW, Ma ZH, Pan CE: **Resveratrol prolongs allograft survival after liver transplantation in rats.** *World J Gastroenterol* 2005, **11(30)**:4745-4749.
35. Deng XQ, Chen LL, Li NX: **The expression of SIRT1 in non-alcoholic fatty liver disease induced by high fat diet in rats.** *Liver Int* 2007, **27(5)**:708-715.
36. Pfluger PT, Herranz D, Velasco-Miguel S, Serrano M, Tschop MH: **SIRT1 protects against high-fat diet-induced metabolic damage.** *Proc Natl Acad Sci USA* 2008, **105(28)**:9793-9798.
37. Shang J, Chen L, Xiao F, Sun H, Ding H, Xiao H: **Resveratrol improves non-alcoholic fatty liver disease by activating AMP-activated protein kinase.** *Acta Pharmacol Sin* 2008, **29(6)**:698-706.

### Pre-publication history

The pre-publication history for this paper can be accessed here:

<http://www.biomedcentral.com/1471-230X/8/40/prepub>

Publish with **BioMed Central** and every scientist can read your work free of charge

"BioMed Central will be the most significant development for disseminating the results of biomedical research in our lifetime."

Sir Paul Nurse, Cancer Research UK

Your research papers will be:

- available free of charge to the entire biomedical community
- peer reviewed and published immediately upon acceptance
- cited in PubMed and archived on PubMed Central
- yours — you keep the copyright

Submit your manuscript here:  
[http://www.biomedcentral.com/info/publishing\\_adv.asp](http://www.biomedcentral.com/info/publishing_adv.asp)

