

Case report

Open Access

## Metastatic duodenal GIST: role of surgery combined with imatinib mesylate

Kamran Mohiuddin<sup>1,2</sup>, Saira Nizami<sup>1,2</sup>, Asma Munir<sup>1</sup>, Breda Memon<sup>2</sup> and Muhammed A Memon<sup>\*2</sup>

Address: <sup>1</sup>Department of Surgery, Aga Khan University Hospital, Karachi, Pakistan and <sup>2</sup>Department of Surgery, Whiston Hospital, Warrington Road, Prescot, Merseyside, UK

Email: Kamran Mohiuddin - drkamran@cyber.net.pk; Saira Nizami - k\_khawaja@hotmail.com; Asma Munir - asmamunir@yahoo.com; Breda Memon - bmemon@yahoo.com; Muhammed A Memon\* - mmemon@yahoo.com

\* Corresponding author

Published: 29 March 2007

Received: 14 February 2007

*International Seminars in Surgical Oncology* 2007, **4**:9 doi:10.1186/1477-7800-4-9

Accepted: 29 March 2007

This article is available from: <http://www.issoonline.com/content/4/1/9>

© 2007 Mohiuddin et al; licensee BioMed Central Ltd.

This is an Open Access article distributed under the terms of the Creative Commons Attribution License (<http://creativecommons.org/licenses/by/2.0>), which permits unrestricted use, distribution, and reproduction in any medium, provided the original work is properly cited.

### Abstract

**Background:** The best possible treatment of metastatic high grade large duodenal GIST is controversial. Surgery (with or without segmental organ resection) remains the principal treatment for primary and recurrent GIST. However, patients with advanced duodenal GIST have a high risk of early tumour recurrence and short life expectancy.

**Method:** We present a case of a young man treated with a combined modality of surgery and imatinib for an advanced duodenal GIST.

**Results:** He remains asymptomatic and disease free 42 months following this combined approach.

**Conclusion:** Treatment with imatinib has dramatically improved the outlook for patients with advanced, unresectable and/or metastatic disease.

### Background

Gastrointestinal stromal tumours or GISTs are the most common mesenchymal neoplasms of the gastrointestinal tract demonstrating positive c-kit (CD117) immunohistochemical staining. Approximately 50–70% originates in the stomach whereas 20–30% of from the small bowel, with duodenum being the least common site. Less frequent sites include the colon and rectum (5–15%) and esophagus (< 5%). These tumours usually grow submucosally but may also manifest as exophytic extraluminal subserosal growth. We report a case of a young man with a large extraluminal advanced duodenal GIST treated successfully with combination of surgery and imatinib mesylate.

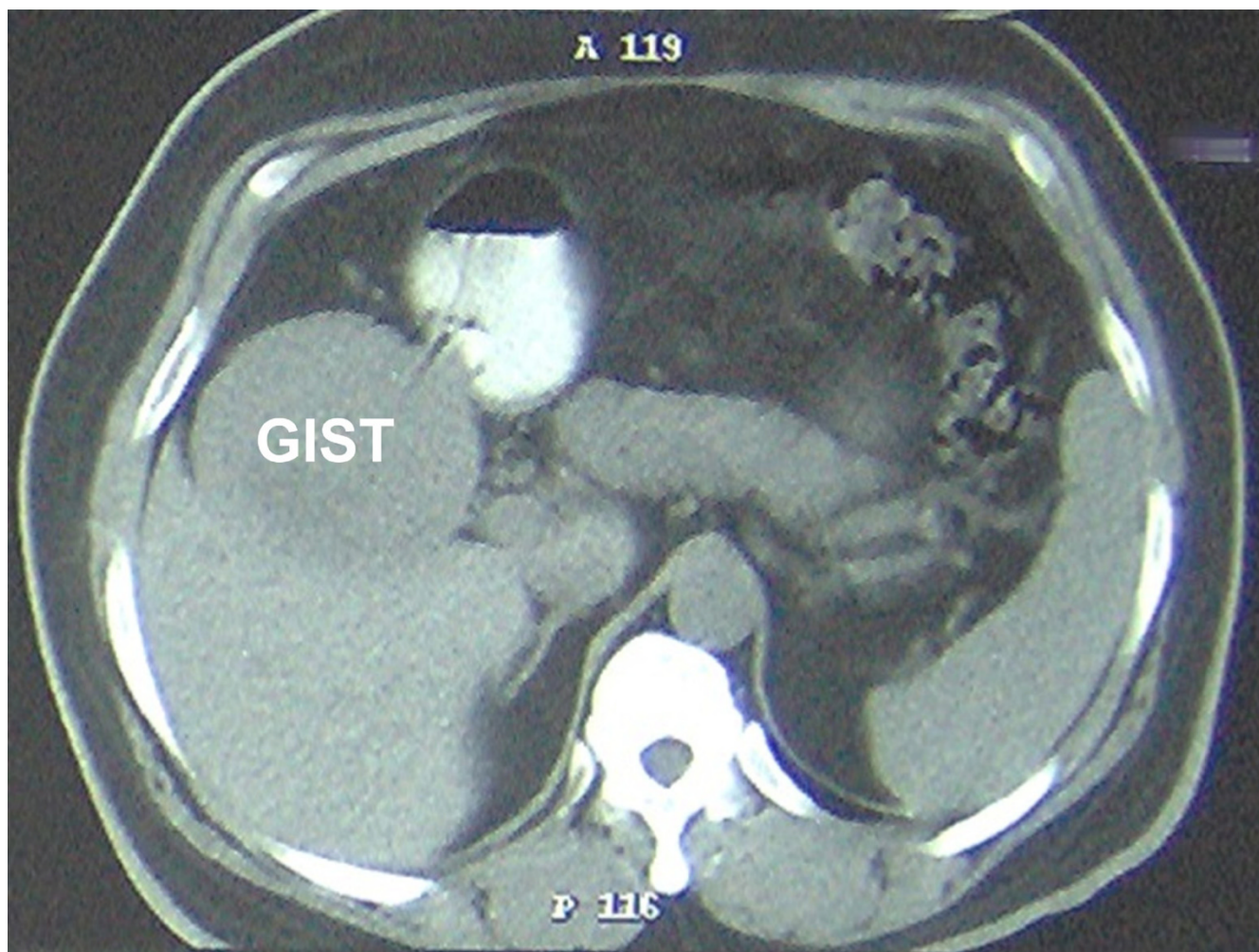
### Case report

A 56 year old man, who was on regular aspirin following coronary artery bypass surgery, presented with an eight month history of intermittent malaena requiring an emergency admission to the hospital. At the time of admission the only positive finding was that of pallor. His full blood count revealed microcytic anaemia with haemoglobin of 7 g/dl. He was therefore transfused 4 units of packed red cells. He underwent an urgent upper gastrointestinal endoscopy which revealed a bulge in the 2<sup>nd</sup> part of the duodenum without any visible mucosal abnormality or intraluminal blood. The duodenal biopsies revealed mild duodenitis and the CLO test for *Helicobacter Pylori* was negative. A computerized tomography scan of the abdomen demonstrated a well demarcated enhancing 9.5 × 9.0

cm mass arising from the lateral wall of the 2<sup>nd</sup> part of the duodenum without any intra-abdominal lymphadenopathy or liver metastases (Figure 1). A provisional diagnosis of duodenal GIST was entertained. The patient underwent an elective exploratory laparotomy which revealed a 10 × 10 cm fleshy friable multi-lobulated exophytic mass arising from the anterior wall of the 2<sup>nd</sup> part of duodenum on a narrow pedicle (Figure 2). Tumour deposits were also seen on the adjacent mesocolon. A wedge excision of the antimesenteric portion of the duodenum containing the pedicle was performed (Figure 3, 4). A frozen section of the duodenum was obtained to confirm tumour free margins before primarily closing it with 2/0 Vicryl in an interrupted fashion. Also the adjacent mesocolon containing tumour deposits was also excised and the defect closed with interrupted sutures. The patient's postoperative recovery was uneventful and he was discharged home seven days later. Histopathology revealed that the tumour

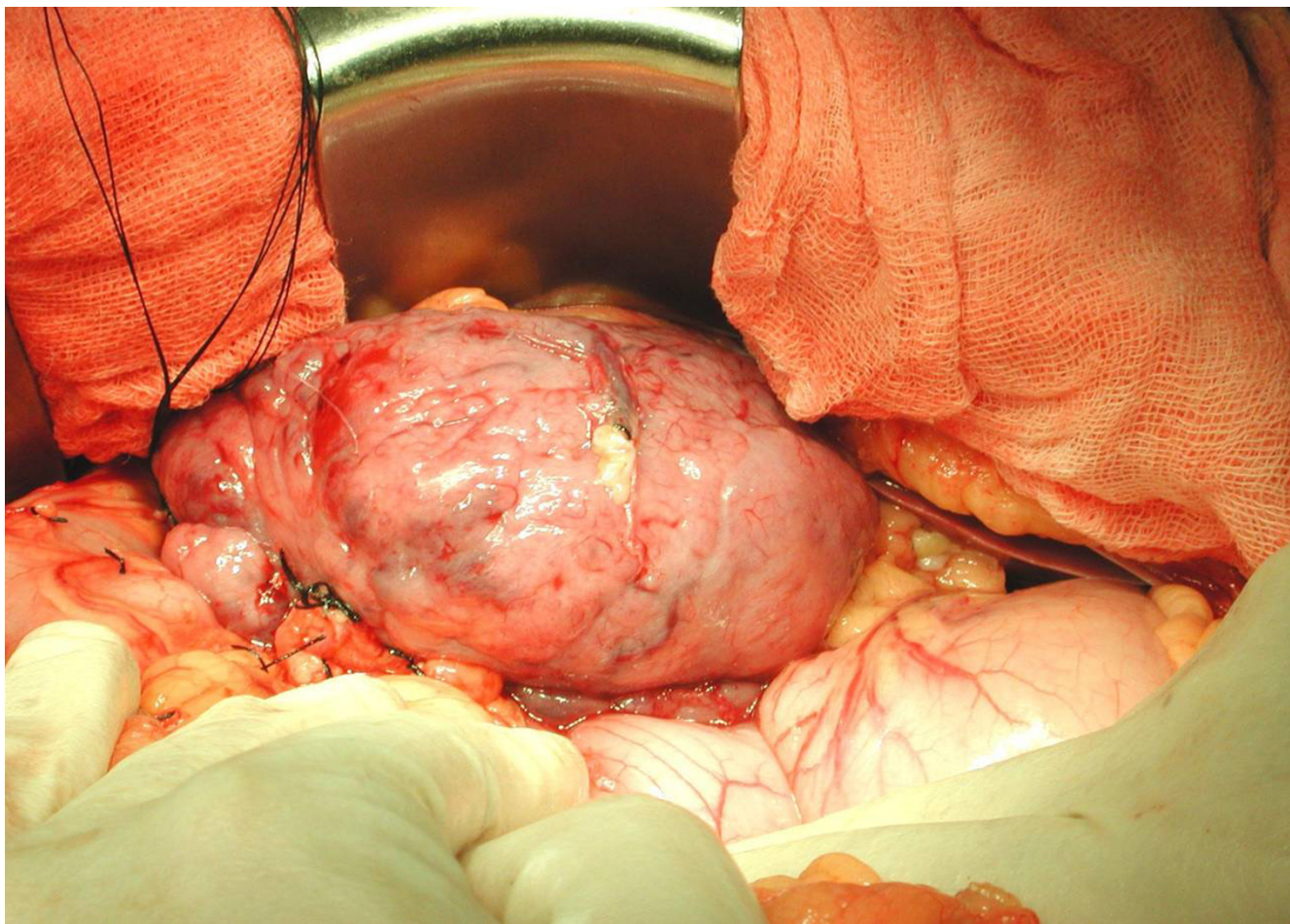
consists of spindle cells which in areas were arranged in fascicles. There was associated haemorrhage and the cells exhibited moderate pleomorphism. Furthermore the duodenal margins were free from tumour (R0 resection). Immunohistochemistry was strongly positive for CD117. Moreover, the mesocolon deposits consists of spindle shaped cells once again positive for CD117. The final diagnosis was that of a high grade metastatic gastrointestinal stromal tumour (GIST).

Because of size of the tumour, histopathological and immunochemistry findings and the presence of tumour deposits in the adjacent mesocolon, the patient was given two years of imatinib mesylate therapy. A follow-up CT scans of chest, abdomen and pelvis have failed to reveal any evidence of recurrence. The patient is still alive and well without any signs of recurrence 42 months following this treatment.



**Figure 1**  
CT scan of patient showing duodenal GIST.





**Figure 2**  
Intra-operative view of the duodenal GIST.

**Discussion**

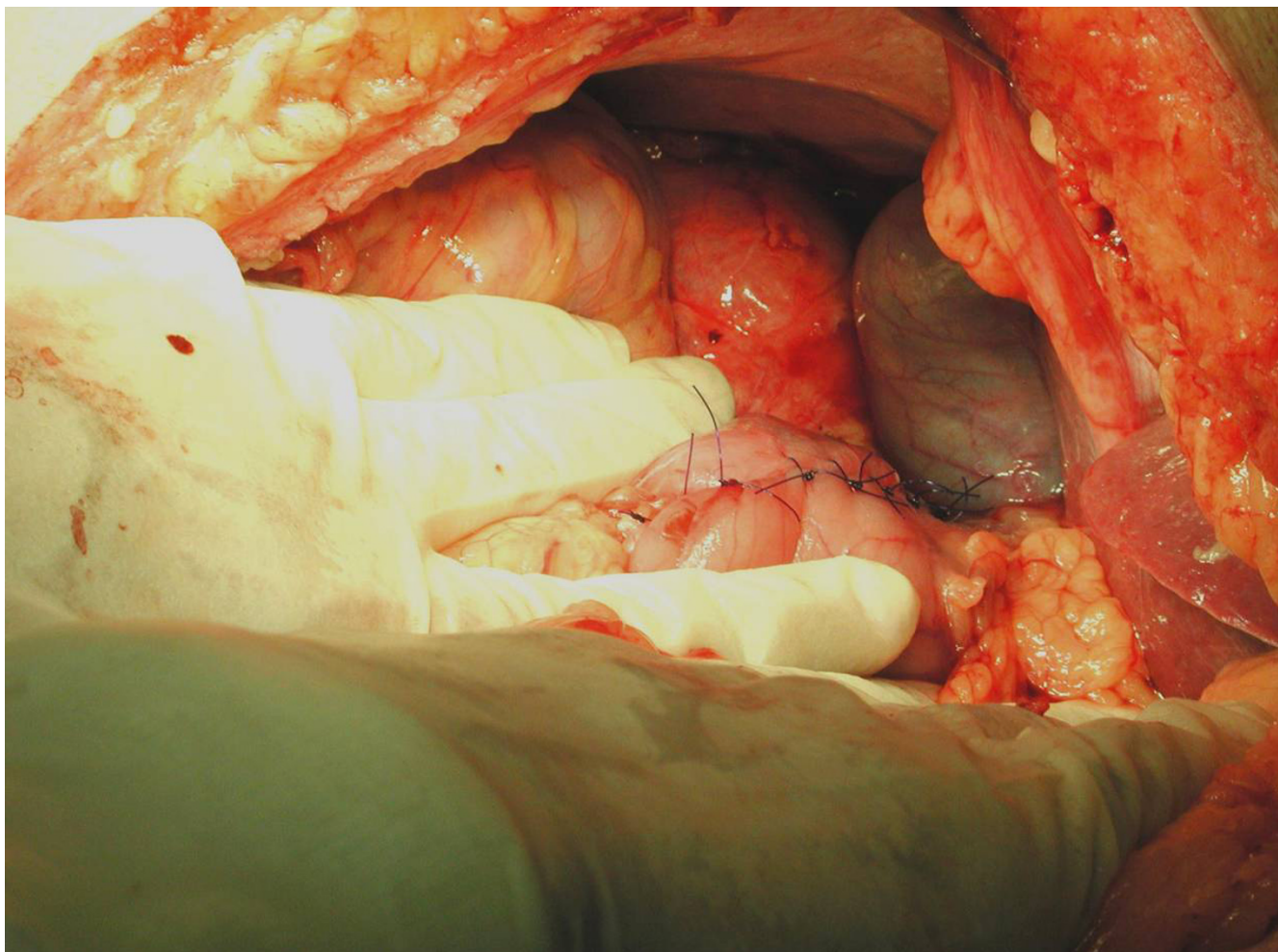
Duodenal GIST can present with vague and non-specific symptoms such as upper abdominal pain (50% to 70%), gastrointestinal haemorrhage (20% to 50%) and an abdominal mass [1,2]. A patient presenting with gastrointestinal haemorrhage may reveal a submucosal mass on endoscopy and biopsies are diagnostic in only 50% of cases [3]. In our patient the endoscopy and biopsies were

not helpful because the tumour was subserosal. The CT scan however raised the suspicion of duodenal GIST.

At laparotomy a large duodenal tumour on a narrow pedicle was encountered. It was felt that a wedge duodenal resection would be adequate provided tumour free margins could be obtained. A frozen section confirmed histologic tumour-free margins. Furthermore the adjacent mesocolon containing tumour deposit was also excised.

**Table 1: Parameters used in evaluation of GIST malignancy**

Authors (year)	Site	Size	Mitosis	Histological Type	Cytological Atypia	Necrosis
Amin MB et al (1993) <sup>5</sup>	-	+	+	-	-	-
Kindblom et al (1998) <sup>6</sup>	-	-	+	-	+	+
Fletcher et al (1998) <sup>7</sup>	-	-	+	+	+	-
Panizo et al (2000) <sup>8</sup>	-	+	+	-	-	-
Trupiano et al (2002) <sup>9</sup>	-	+	+	+	+	-
Miettinen et al (2002) <sup>10</sup>	+	+	+	-	-	-



**Figure 3**  
Post resectional view with primary closure of the duodenum.

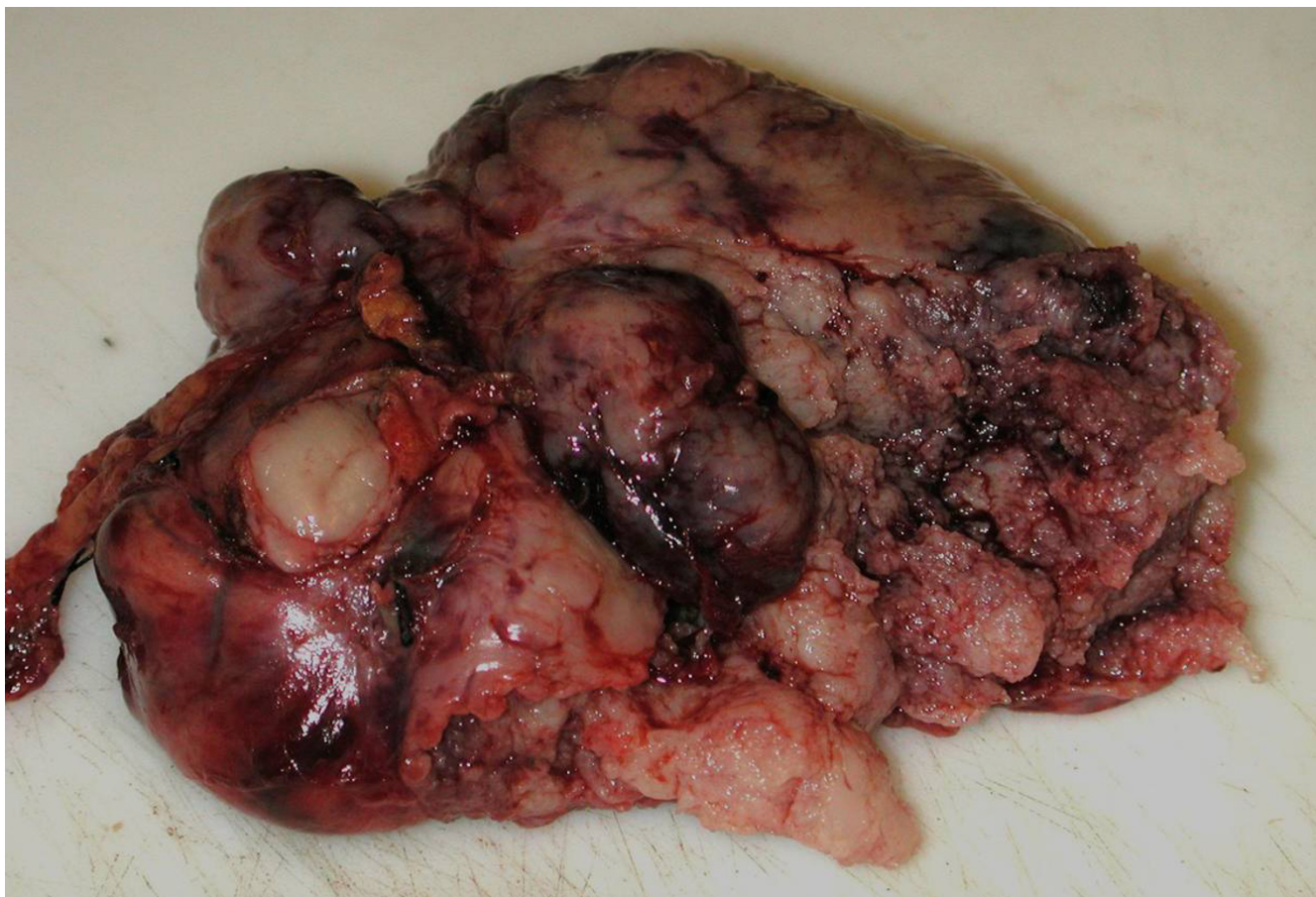
There is a wide variation in the clinical behaviour of gastrointestinal GIST's, most being benign. However, small bowel (jejunum, duodenum and the ileum) GISTs which constitute 20% to 30% of gastrointestinal stromal tumours have a high propensity for malignant behaviour [4]. The factors used in evaluation of GIST are summarized in Table 1[5-10]. Certainly larger size tumours with high mitotic figures, cytological atypia, necrosis and pleomorphism favours malignancy. Our patients had all such features along with implantation over the adjacent mesocolon and therefore it was considered not only high grade but metastatic in nature.

The overall 5 year survival for completely resected GISTs ranges from 30 – 80% [11]. The relapse rate for patients having surgery ranges from 5% in those that have a complete resection, to 90% in those with unresectable and/or metastatic disease. The median survival for patients with unresectable and/or metastatic disease is 12 months

(ranging from 2–20 months) [12]. Patients with advanced stage disease have shown that the disease progresses after approximately 1.5 months without effective therapy [13].

Imatinib mesylate, a specific tyrosine kinase inhibitor, is one of the first targeted molecular therapies, and works by disrupting specific aspects of tumour growth. This treatment has revolutionised the treatment of unresectable and/or metastatic GIST. Following the successful treatment of a Finish patient with imatinib in a chemotherapy-resistant metastatic GIST [14], a number of studies have shown encouraging results with imatinib. In a large randomized multicentre trial conducted by Demetri et al [15], imatinib induced a sustained objective response in over half of patients with advanced unresectable or metastatic GIST. The estimated one year survival was 88%. A number of other trials [16-19] similarly have shown good response rate and survival in patients with advanced GIST (Table 2).





**Figure 4**  
Macroscopic appearance of duodenal GIST specimen.

We felt that our patient being at an increased risk of recurrence because of his operative and histological findings, would need adjuvant treatment with imatinib (a) to stabi-

lise his disease and (b) to prolong his recurrence-free period and survival. He was therefore started on 400 mg of imatinib once daily. He was followed up at six monthly

**Table 2: Summary of Imatinib Trials**

Trial	Source	Phase	Patients no	Imatinib Dosage	Follow-up	Response Rate
Multicentre Randomized USA Trial	Demetri et al NEJM 2002 <sup>15</sup>	II	147	400 mg od 600 mg od	34 months median	CR 1% PR – 67% SD – 16% Survival – median NR
EORTC, ISG and AGITG	Van Glabbeke M et al Eur J Cancer <sup>16,17</sup>	III	946	400 mg od 400 mg bid	17 months median	CR – 6% PR – 45% SD – 33% Survival – median NR
The Sarcoma Intergroup	Rankin et al Journal of Clinical Oncology 2004 <sup>18</sup>	III	746	400 mg od 800 mg od	24 months median	CR – 3% PR – 45% SD – 26% Survival – median NR
EORTC	Van Oosterum, Lancet 2001 <sup>19</sup>	I/II	40	Dose finding 400–1000 mg od	9–13 months	PR – 53% SD – 16%

CR – complete response, NR – Not reached, PR – partial response, SD – stable disease

intervals with a full body CT scan for the first two years. Surprisingly enough, he did not suffer from any major side effects from imatinib at all. At two years imatinib was stopped and further CT scans were performed at six monthly intervals which have not shown any evidence of recurrence and the patient remains asymptomatic and disease free at 42 months following his treatment. The future plan is to monitor him closely with CT scans for another eighteen months.

### Conclusion

We feel that imatinib, a targeted tyrosine kinase inhibitor treatment in combination with surgery, has prolonged our patient's disease free survival and therefore have provided an effective adjuvant treatment for the metastatic duodenal GIST.

### Conflict of interest/funding

The author(s) declare that they have no competing interests.

### References

1. Sturgeon C, Chejfec G, Epat NJ: **Gastrointestinal stromal tumors: a spectrum of disease.** *Surg Oncol* 2003, **12**:21-26.
2. DeMatteo RP, Lewis JJ, Leung D, Mudan SS, Woodruff JM, Brennan MF: **Two hundred gastrointestinal stromal tumors: recurrence patterns and prognostic factors for survival.** *Ann Surg* 2000, **231**:51-58.
3. Chack A, Canto MI, Rosch T: **Endoscopic differentiation of benign and malignant stromal cell tumors.** *Gastrointestinal Endosc* 1997, **45**:468-473.
4. DeMatteo RP, Heinrich MC, El-Rifai WM, Demetri G: **Clinical management of gastrointestinal stromal tumors: Before and after STI-571.** *Human Pathol* 2002, **33**:466-67.
5. Amin MB, Ma CK, Linden MD, Kubus JJ, Zarbo RJ: **Prognostic value of proliferating cell nuclear antigen index in gastric stromal tumors. Correlation with mitotic count and clinical outcome.** *Am J Clin Pathol* 1993, **100**:428-32.
6. Kindblom LG, Remotti HE, Aldenborg F, Meis-Kindblom JM: **Gastrointestinal pacemaker cell tumor (GIPACT): gastrointestinal stromal tumors show phenotypic characteristics of the interstitial cells of Cajal.** *Am J Pathol* 1998, **152**:1259-1269.
7. De Saint Aubain Somerhausen N, Fletcher CDM: **Gastrointestinal Stromal Tumors. An Update.** *Sarcoma* 1998, **2**:133-141.
8. Panizo-Santos A, Sola I, Vega F, de Alava E, Lozano MD, Idoate MA, Pardo-Mindan J: **Predicting Metastatic Risk of Gastrointestinal Stromal Tumors: Role of Cell Proliferation and Cell Cycle Regulatory Proteins.** *Int J Surg Pathol* 2000, **8**:133-44.
9. Trupiano JK, Stewart RE, Misick C, Appelman HD, Goldblum JR: **Gastric stromal tumors: a clinicopathologic study of 77 cases with correlation of features with nonaggressive and aggressive clinical behaviors.** *Am J Surg Pathol* 2002, **26**:705-14.
10. Miettinen M, El-Rifai W, H L, Sobin L, Lasota J: **Evaluation of malignancy and prognosis of gastrointestinal stromal tumors: a review.** *Hum Pathol* 2002, **33**:478-83.
11. Casper ES: **Gastrointestinal stromal tumors.** *Curr Treat Options Oncol* 2000, **1**:267-273.
12. Roberts PJ, Eisenberg B: **Clinical presentation of gastrointestinal stromal tumors and treatment of operable disease.** *Eur J Cancer* 2002, **38**(suppl 5):S37-38.
13. Singer S, Rubin BP, Lux ML, Chen CJ, Demetri GD, Fletcher CD, Fletcher JA: **Prognostic value of KIT mutation type, mitotic activity, and histologic subtype in gastrointestinal stromal tumors.** *J Clin Oncol* **20**:3898-905. 2002 Sep 15
14. Joensuu H, Roberts PJ, Sarlomo-Rikala M, Andersson LC, Tervahartala P, Tuveson D, Silberman S, Capdeville R, Dimitrijevic S, Druker B, Demetri GD: **Effect of the tyrosine kinase inhibitor STI571 in a patient with a metastatic gastrointestinal stromal tumor.** *N Engl J Med* 2001, **344**:1052-56.
15. Demetri GD, von Mehren M, Blanke CD, Van den Abbeele AD, Eisenberg B, Roberts PJ, Heinrich MC, Tuveson DA, Singer S, Janicek M, Fletcher JA, Silverman SG, Silberman SL, Capdeville R, Kiese B, Peng B, Dimitrijevic S, Druker BJ, Corless C, Fletcher CD, Joensuu H: **Efficacy and safety of imatinib mesylate in advanced gastrointestinal stromal tumors.** *N Engl J Med* 2002, **347**:472-80.
16. Van Glabbeke M, Verweij J, Casali PG, Simes J, Le Cesne A, Reichardt P, Issels R, Judson IR, van Oosterom AT, Blay JY: **Predicting toxicities for patients with advanced gastrointestinal stromal tumours treated with imatinib: a study of the European Organisation for Research and Treatment of Cancer, the Italian Sarcoma Group, and the Australasian Gastro-Intestinal Trials Group (EORTC-ISG-AGITG).** *Eur J Cancer* 2006, **42**:2277-85.
17. Silberman S, Joensuu H: **Overview of issues related to imatinib therapy of advanced gastrointestinal stromal tumours: a discussion amongst experts.** *Eur J Cancer* 2002, **38**(suppl 5):S66-S69.
18. Rankin C, Von Mehren M, Blanke C, Benjamin R, D C, Fletcher M, Bramwell V, Crowley J, Borden E, D G: **Demetri. Dose effect of imatinib (IM) in patients (pts) with metastatic GIST – Phase III Sarcoma Group Study S0033.** *J Clin Oncol* 2004, **22**(14S):9005.
19. van Oosterom AT, Judson I, Verweij J, Stroobants S, Donato di Paola E, Dimitrijevic S, Martens M, Webb A, Sciort R, Van Glabbeke M, Silberman S, Nielsen OS, European Organisation for Research and Treatment of Cancer Soft Tissue and Bone Sarcoma Group: **Safety and efficacy of imatinib (STI571) in metastatic gastrointestinal stromal tumours: a phase I study.** *Lancet* 2001, **358**:1421-1423.

Publish with **BioMed Central** and every scientist can read your work free of charge

"BioMed Central will be the most significant development for disseminating the results of biomedical research in our lifetime."

Sir Paul Nurse, Cancer Research UK

Your research papers will be:

- available free of charge to the entire biomedical community
- peer reviewed and published immediately upon acceptance
- cited in PubMed and archived on PubMed Central
- yours — you keep the copyright

Submit your manuscript here:  
http://www.biomedcentral.com/info/publishing\_adv.asp

