



A mini-open technique for Achilles tenotomy in infants with clubfoot

Rhett MacNeille¹ · William Hennrikus¹ · Brian Stapinski¹ · Garrett Leonard¹

Received: 9 September 2015 / Accepted: 19 January 2016 / Published online: 29 January 2016
© The Author(s) 2016. This article is published with open access at Springerlink.com

Abstract

Purpose A tendoachilles lengthening (TAL) is indicated in over 85 % of cases treated with the Ponseti technique. A percutaneous TAL is often performed in the clinic. Reported complications from a TAL performed in the clinic include: bleeding due to injury to the peroneal artery, posterior tibial artery, or lesser saphenous vein; injury to the tibial or sural nerves; and incomplete release. The purpose of the present study is to report the results and complications of a mini-open TAL performed in the operating room (OR).

Methods The current study is a retrospective review performed among infants with idiopathic clubfoot who underwent a mini-open TAL from 2008 to 2015.

Results Forty-one patients underwent 63 TALs via a mini-open technique in day surgery. The average Pirani score was 5.8 prior to casting. The average number of casts applied prior to surgery was 5.2. The average age at the time of the TAL was 12.5 weeks (range 5–48 weeks). The average weight at the time of surgery was 7.3 kg (range 3.6–13 kg). No child had a delay in discharge or stayed overnight in the hospital. No anesthesia-related complications or neurovascular injuries occurred. No child needed a repeat TAL due to an incomplete tenotomy.

Conclusions In conclusion, mini-open TAL performed in the OR is safe and effective in infants with clubfeet. No

complications occurred and all patients were discharged on the day of surgery. Direct visualization of the Achilles tendon via a mini-open technique minimizes the risk of neurovascular injury and incomplete tenotomy.

Keywords Ponseti · Clubfoot · Achilles tenotomy · Mini-open · TAL

Introduction

Complications resulting from percutaneous Achilles tendon release (tendoachilles lengthening, TAL) performed in the clinic for the treatment of infants with clubfoot include: bleeding due to injury to the peroneal artery, posterior tibial artery, or lesser saphenous vein; injury to the tibial or sural nerves; and incomplete release [1–4]. Although Dr. Ponseti performed the TAL in the office under local anesthesia, some surgeons now perform the procedure in the operating room (OR) to optimize the child's analgesia, improve safety, improve control of the procedure, and minimize complications [5, 6]. The purpose of this study is to report the outcomes of infants with clubfoot treated with a TAL in the OR via a mini-open approach.

Materials and methods

A retrospective review was performed of infants with idiopathic clubfoot who underwent a mini-open TAL from 2008 to 2015. The data abstracted included: gender, number of casts, age at tenotomy, Pirani score, foot involvement, weight at surgery, anesthesia complications, need for admission, vascular or nerve injury, wound complications, and need for repeat surgery. All patients included in the

✉ William Hennrikus
whennrikus@hmc.psu.edu
Rhett MacNeille
rmacneille@hmc.psu.edu

¹ Department of Orthopaedics, Penn State Milton S. Hershey Medical Center, 30 Hope Drive, Entrance B, Suite 2200, Hershey, PA 17033, USA

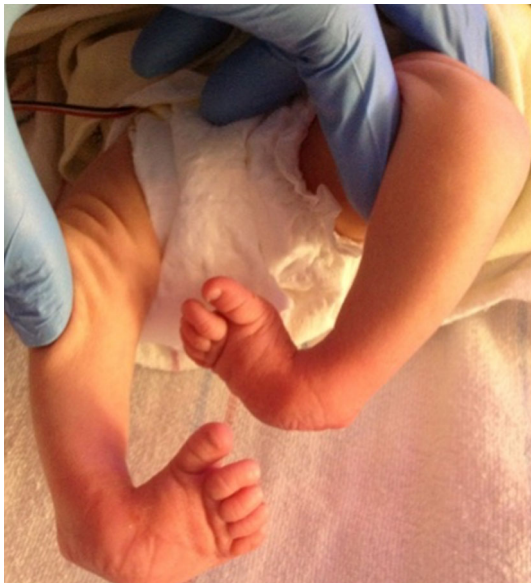

Fig. 1 Bilateral clubfoot in a newborn child

present study had idiopathic clubfoot and excluded patients with any syndromic stigmata (Fig. 1). Patients undergoing TAL for toe walking or reasons other than clubfoot were excluded. A TAL was performed if the foot could not be dorsiflexed to 5° prior to application of the final cast. Sterile prep and drape was utilized. A time out was done. No tourniquet was utilized. The foot was maximally dorsiflexed and the distal portion of the Achilles tendon was palpated under the skin. A 10-mm incision was made along the medial edge of the tendon 1 cm above the calcaneus (Fig. 2). The Achilles tendon was identified. A mosquito clamp was placed beneath the Achilles tendon from medial to lateral to isolate and tenotomize the tendon (Figs. 3 and 4). After tenotomy, an increase in dorsiflexion to greater than 5° was observed in all patients. Local anesthetic 2 ml of 0.25 % bupivacaine HCl with 1:200,000 epinephrine was injected. The skin was closed 4–0 Monocryl. A long leg cast was applied for 4 weeks (Fig. 5). One patient in the present study underwent a caudal block at the preference of the anesthesiologist. All other patients received general anesthesia and local anesthetic.

Results

Forty-one patients underwent 63 TALs via a mini-open technique in day surgery. Twelve were right-sided, seven were left-sided, and 22 were bilateral TAL. The average Pirani score was 5.8 prior to casting (range 2–6). Pirani scoring consists of six components, each scored 0, 0.5, or 1, depending on severity, for a maximal score of 6 (Table 1). The average number of casts applied prior to surgery was

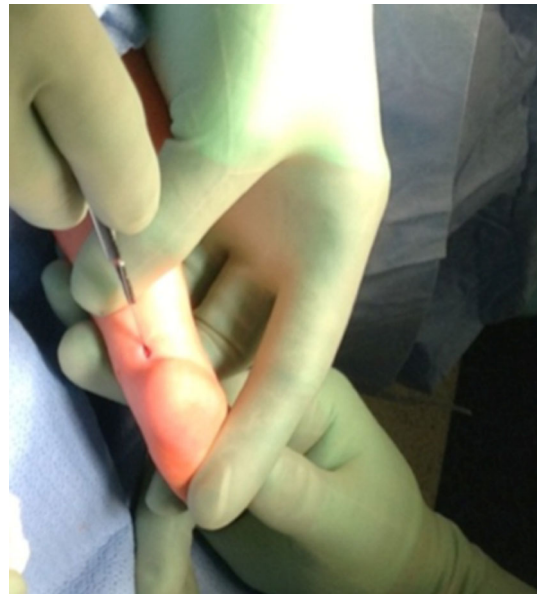

Fig. 2 Small incision of the mini-open Achilles tenotomy. Incision made over the medial edge of the Achilles tendon

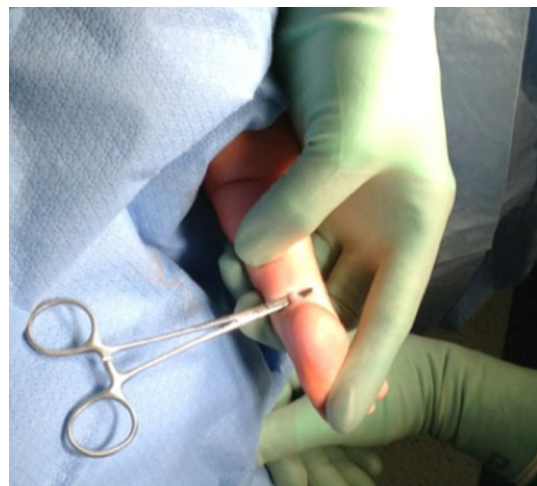

Fig. 3 A small hemostat used to deliver the tendon from the wound for direct visualization prior to tenotomy

5.8, with a range of 3–10 casts applied. The average age at the time of the TAL was 12.5 weeks, with a range of 5–48 weeks. The average weight at the time of surgery was 7.3 kg, with a range of 3.6–13 kg. The average time in the day surgery unit was 5.2 h, with a range from 3 to 16 h (Table 2). No child had a delay in discharge or stayed overnight in the hospital. All children were prescribed acetaminophen upon discharge. No post-discharge phone calls were received from the families. No patient demonstrated an anesthetic-related complication, such as death, aspiration, arrhythmia, laryngeal spasm, or bronchospasm. No nerve injuries or vascular injuries occurred. No child needed a repeated TAL due to an incomplete tenotomy.

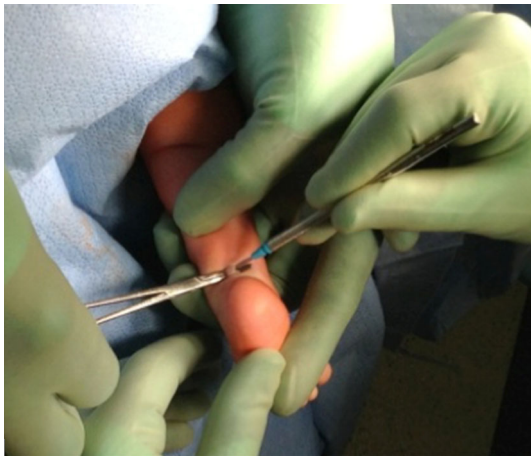

Fig. 4 Tenotomy then performed only after direct visualization obtained

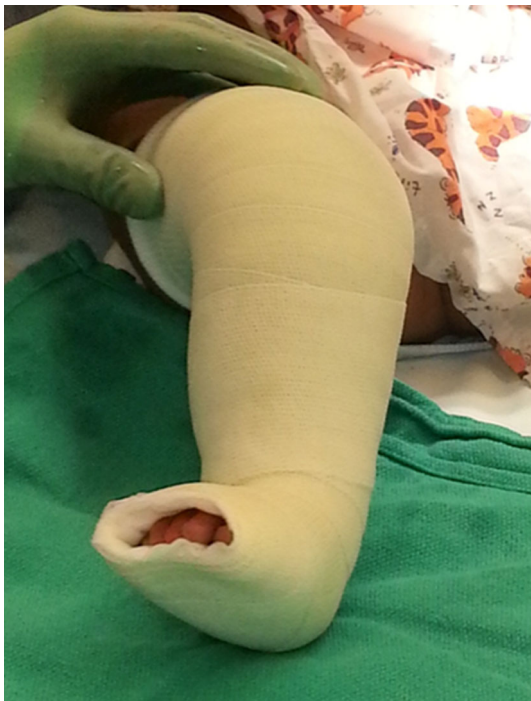

Fig. 5 A long leg cast is applied for 4 weeks

Discussion

The Ponseti technique involves weekly manipulations and serial casting to allow collagen relaxation and atraumatic remodeling of joint surfaces without fibrosis and scarring from surgical releases. The order of correction with serial casting progresses from addressing the midfoot cavus to forefoot adduction to hindfoot varus, then finally to hindfoot equinus [7]. If a residual equinus deformity is still present, a TAL is performed prior to the final cast application. The TAL is needed in about 85 % of cases [8].

Table 1 Pirani score criteria. Pirani scoring consists of these six components, each scored 0, 0.5, or 1, depending on severity. The minimum total score is 0 and the maximum total score is 6

Pirani scoring	
1	Posterior crease
2	Empty heel
3	Rigid equinus
4	Medial crease
5	Curvature of the lateral border
6	Position of talar head

Tendoachilles tenotomy in infants has been studied by ultrasound. The tendon reestablishes continuity between the stumps as soon as 3 weeks after surgery, with ability to transmit force to the heel [9–11]. Ultrasound was also used to measure calf diameters as a reflection of strength and showed no significant differences with the changes over time between affected and non-affected sides of children with unilateral clubfoot [12].

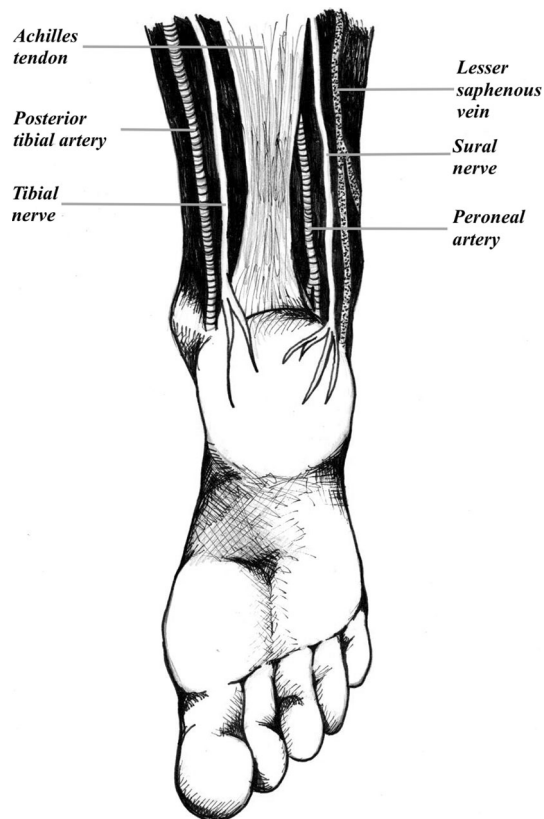
Complications from percutaneous TAL in the clinic include bleeding due to injury to the peroneal artery, posterior tibial artery, or lesser saphenous vein, injury to the tibial or sural nerves, and incomplete release (Fig. 6) [1–4]. In an effort to avoid these complications, the senior author now performs a mini-open TAL as part of the Ponseti technique in the treatment of clubfoot. To the author's knowledge, the mini-open technique has only been reported in the podiatric literature up to this point [13]. Anecdotal reports suggest a small open incision to directly visualize the tendon before tenotomy [3]. Dogan et al. corroborated their use of the mini-open technique with a rat study, demonstrating equivalent or better healing from a mini-open TAL compared with a percutaneous approach [14].

Ponseti and many clinicians have traditionally performed TAL in the clinic [8]. The benefits of performing the procedure in an outpatient office setting include decreased cost, no general anesthesia, and immediate treatment [15].

Other surgeons choose to perform the TAL in an OR setting [5, 16, 17]. The benefits include: improved safety, better control of the procedure for the surgeon, better ability to manage complications, and improved ability to safely guide a resident through the procedure. For example, in the present study, there were no adverse effects or complications from general anesthesia. Every patient was able to discharge to home the same day of the procedure. In addition, Iravani et al. demonstrated no adverse outcomes in 114 patients undergoing general anesthesia for TAL in clubfoot [5]. Bor et al. noted that too much use of local anesthetic can complicate the surgery by obscuring

Table 2 Case data totals/averages with associated ranges for gender, Pirani score, laterality of clubfoot, number of casts, age (weeks), time spent in operating room (min), and time spent in hospital (min)

	Gender	Pirani score	Laterality	Number of casts	Age (weeks)	Operating room time (min)	Hospital time (min)
Total or average	M: 32 F: 9	5.8	R: 12 L: 7 B: 22	5.8	12.5	66.6	311.3
Range	—	2–6	—	3–10	5–48	48–111	180–960

**Fig. 6** The anatomic structures at risk when performing a tenoachilles lengthening (TAL): peroneal and posterior tibial arteries; lesser saphenous vein; and tibial and sural nerves

landmarks which may be especially problematic when performing percutaneous techniques [17]. In the current series, local anesthetic is applied after the tenotomy to avoid the local anesthetic obscuring surface landmarks or the surgical dissection.

The presence of vascular anomalies in the leg of patients with clubfoot is well documented. For example, in some cases, the anterior tibial artery and/or the posterior tibial artery can be absent [3]. In such feet, the peroneal artery is the dominant artery to supply the feet. Changulani et al. reported on a case study where the posterior artery was lacerated and the tibial nerve was completely

transected during a percutaneous TAL. Injury to the peroneal artery in these patients may result in an avascular limb and a potential amputation [2]. Burghardt et al. also reported a case study on a child who developed a pseudoaneurysm after percutaneous TAL. Burghardt et al. noted that the patient had a posterior tibial artery-dependent foot. The child later required repeat tenotomy and, during the revision done by open tenotomy, the posterior tibial artery was noted to be closely applied to the Achilles tendon [1]. Dobbs et al. further highlighted this point, reporting on four patients with serious bleeding complications following percutaneous tendoachilles tenotomy due to injury to the peroneal artery in three of the cases and the lesser saphenous vein in one case [3]. In the current study, no case of vessel or nerve occurred when utilizing the mini open technique.

TAL in the OR is more costly than in the clinic [16]. Although the cost of performing the procedure in the outpatient clinic is less compared to in the OR, the cost of one complication, such as a preventable amputation in a newborn, would exceed the OR costs of performing TALs in the OR during one surgeon's career. Anesthesia in small children is very safe but there are always risks. DiMaggio et al. reported that early exposure to child anesthesia resulted in increased risk of being diagnosed with behavioral and developmental disorders [18]. Wilder et al. also showed an increased risk with two or more early exposures, but a single exposure to anesthesia did not increase this risk [19]. No parent in this current study refused general anesthesia for his or her child.

TAL techniques range from percutaneous needle tenotomy to percutaneous tenotomy with a blade to open tenotomy to multiple tenotomies [3, 20–22]. A percutaneous technique with a blade or a needle may increase the chance of complications [13]. The percutaneous needle technique was described by Minkowitz et al. on 12 patients [20]. Another percutaneous technique was reported by Sharma et al. utilizing a mosquito hemostat to act as a depth gauge, helping to control the blade depth and as a backstop to protect the nearby neurovascular structures. In Sharma et al.'s technique, the Achilles tendon was still never visualized [23]. In the current study, direct visualization of

the tendon via a mini-open technique minimizes risks and allows a complete tenotomy in all cases.

Conclusion

Mini-open tendoachilles lengthening (TAL) in the operating room (OR) is safe and effective in infants with clubfoot. No complications occurred and all patients were discharged on the day of surgery. Direct visualization of the Achilles tendon via a mini-open technique minimizes the risk of neurovascular injury and incomplete tenotomy.

Acknowledgments Thank you to Zachary Winthrop for his illustration (Fig. 6).

Compliance with ethical standards

All procedures performed in studies involving human participants were in accordance with the ethical standards of the institutional research committee and with the 1964 Helsinki declaration and its later amendments or comparable ethical standards. Informed consent was obtained from all individual participants included in the study.

Conflict of interest Rhett MacNeille, William Hennrikus, Brian Stapinski, and Garrett Leonard declare that they have no conflict of interest.

Funding No funding was required for this study.

Ethical approval For this type of study, formal consent is not required.

Open Access This article is distributed under the terms of the Creative Commons Attribution 4.0 International License (<http://creativecommons.org/licenses/by/4.0/>), which permits unrestricted use, distribution, and reproduction in any medium, provided you give appropriate credit to the original author(s) and the source, provide a link to the Creative Commons license, and indicate if changes were made.

References

- Burghardt RD, Herzenberg JE, Ranade A (2008) Pseudoaneurysm after Ponseti percutaneous Achilles tenotomy: a case report. *J Pediatr Orthop* 28:366–369
- Changulani M, Garg N, Bruce CE (2007) Neurovascular complications following percutaneous tendoachillis tenotomy for congenital idiopathic clubfoot. *Arch Orthop Trauma Surg* 127:429–430
- Dobbs MB, Gordon JE, Walton T, Schoenecker PL (2004) Bleeding complications following percutaneous tendoachilles tenotomy in the treatment of clubfoot deformity. *J Pediatr Orthop* 24:353–357
- Jowett CR, Morcuende JA, Ramachandran M (2011) Management of congenital talipes equinovarus using the Ponseti method: a systematic review. *J Bone Joint Surg Br* 93(9):1160–1164
- Iravani M, Chalabi J, Kim R, Ebramzadeh E, Zions LE (2013) Propofol sedation for infants with idiopathic clubfoot undergoing percutaneous tendoachilles tenotomy. *J Pediatr Orthop* 33(1):59–62
- Carroll NC (2012) Clubfoot in the twentieth century: where we were and where we may be going in the twenty-first century. *J Pediatr Orthop B* 21(1):1–6
- Radler C, Manner HM, Suda R, Burghardt R, Herzenberg JE, Ganger R, Grill F (2007) Radiographic evaluation of idiopathic clubfeet undergoing Ponseti treatment. *J Bone Joint Surg Am* 89(6):1177–1183
- Dobbs MB, Morcuende JA, Gurnett CA, Ponseti IV (2000) Treatment of idiopathic clubfoot: an historical review. *Iowa Orthop J* 20:59–64
- Maranho DA, Nogueira-Barbosa MH, Simão MN, Volpon JB (2009) Ultrasonographic evaluation of Achilles tendon repair after percutaneous sectioning for the correction of congenital clubfoot residual equinus. *J Pediatr Orthop* 29(7):804–810
- Agarwal A, Qureshi NA, Kumar P, Garg A, Gupta N (2012) Ultrasonographic evaluation of Achilles tendons in clubfoot before and after percutaneous tenotomy. *J Orthop Surg (Hong Kong)* 20(1):71–74
- Niki H, Nakajima H, Hirano T, Okada H, Beppu M (2013) Ultrasonographic observation of the healing process in the gap after a Ponseti-type Achilles tenotomy for idiopathic congenital clubfoot at two-year follow-up. *J Orthop Sci* 18(1):70–75
- Niki H, Nakajima H, Hirano T, Okada H, Beppu M (2013) Effect of Achilles tenotomy on congenital clubfoot-associated calf-muscle atrophy: an ultrasonographic study. *J Orthop Sci* 18(4):552–556
- Dogan A, Kalender AM, Seramet E, Uslu M, Sebik A (2008) Mini-open technique for the Achilles tenotomy in correction of idiopathic clubfoot. *J Am Podiatr Med Assoc* 98:414–417
- Dogan A, Uzumcugil O, Sarisozen B, Ozdemir B, Akman YE, Bozdag E, Sunbuloglu E, Bozkurt E (2009) A comparison of percutaneous and mini-open techniques of Achilles tenotomy: an experimental study in rats. *J Child Orthop* 3(6):485–491
- Lebel E, Karasik M, Bernstein-Weyel M, Mishukov Y, Peyser A (2012) Achilles tenotomy as an office procedure: safety and efficacy as part of the Ponseti serial casting protocol for clubfoot. *J Pediatr Orthop* 32:412–415
- Parada SA, Baird GO, Auffant RA, Tompkins BJ, Caskey PM (2009) Safety of percutaneous tendoachilles tenotomy performed under general anesthesia on infants with idiopathic clubfoot. *J Pediatr Orthop* 29:916–919
- Bor N, Katz Y, Vofsi O, Herzenberg JE, Zuckerberg AL (2007) Sedation protocols for Ponseti clubfoot Achilles tenotomy. *J Child Orthop* 1:333–335
- DiMaggio C, Sun LS, Li G (2011) Early childhood exposure to anesthesia and risk of developmental and behavioral disorders in a sibling birth cohort. *Anesth Analg* 113(5):1143–1151
- Wilder RT, Flick RP, Sprung J, Katusic SK, Barbaresi WJ, Mickelson C, Gleich SJ, Schroeder DR, Weaver AL, Warner DO (2009) Early exposure to anesthesia and learning disabilities in a population-based birth cohort. *Anesthesiology* 110(4):796–804
- Minkowitz B, Finkelstein BI, Bleicher M (2004) Percutaneous tendo-Achilles lengthening with a large-gauge needle: a modification of the Ponseti technique for correction of idiopathic clubfoot. *J Foot Ankle Surg* 43:263–265
- ElTayeby HM (2012) Multiple tenotomies after Ponseti method for management of severe rigid clubfoot. *J Foot Ankle Surg* 51(2):156–160
- Mahan ST, Spencer SA, Kasser JR (2014) Satisfactory patient-based outcomes after surgical treatment for idiopathic clubfoot: includes surgeon's individualized technique. *J Pediatr Orthop* 34(6):631–638
- Sharma S, Butt MF, Singh M, Sharma S (2013) The posterior to anterior controlled technique of percutaneous Achilles tenotomy in the correction of idiopathic clubfoot: a technical report. *J Pediatr Orthop B* 22(3):249–251