

## The BLUE-points: three standardized points used in the BLUE-protocol for ultrasound assessment of the lung in acute respiratory failure

Daniel A. Lichtenstein · Gilbert A. Mezière

Received: 29 July 2010 / Accepted: 18 February 2011 / Published online: 30 March 2011  
© Springer-Verlag 2011

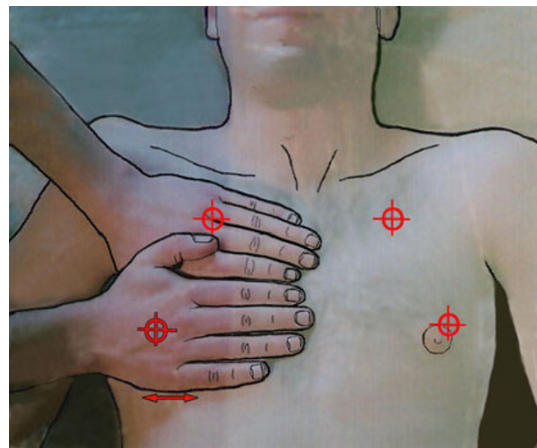
Sir,

The BLUE-protocol is designed for immediate diagnosis of acute respiratory failure, one of the most distressing settings for patients [1]. Physicians would appreciate standardized areas of investigation. The BLUE-points respond to this quest. Of the seven principles of lung ultrasound [2], principle 2, indicating that the disorders are distributed along an Earth–Sky axis, and principle 3, which recalls that the lung is the most voluminous organ, are used.

Beside use and absence of irradiation favor the use of ultrasound [3]. Studies have shown that most acute lung disorders benefit from standardized locations. Clinically relevant interstitial syndrome locates anteriorly [4]. Free pneumothoraces always locate anteriorly [5]. As free fluids follow gravity rules [6], all cases of free pleural fluid effusion, regardless its abundance locate at least posteriorly above the diaphragm [7]. Lung consolidation can locate everywhere depending on the cause and extension, yielding sensitivity lower than other disorders, 90% [8], yet its posterior location above the diaphragm in critically ill patients with pneumonia is usual [4].

We consider the hands of the patient (called BLUE-hands, roughly standard doctor's hands size in standard adults; physicians with large or small hands would make the adaptation once for all). The hands, applied as shown in Fig. 1, define the anterior chest wall. This is of great help in patients with major obesity, nipple ptosis, etc. This

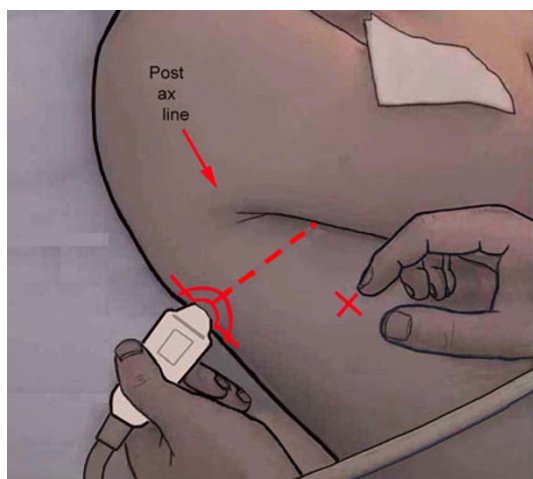
works with patients of any size, neonate included. The BLUE-hands allows to define five regions of interest. The upper and lower BLUE-points, the phrenic line, defined in Fig. 1, are anterior. The phrenic point is lateral, defined in Fig. 2. The PLAPS-point, defined in Fig. 2 from the lower BLUE-point, is posterior. The *Carmen maneuver* extends the location of the BLUE-points: by a slight back-and-forth movement of the probe held longitudinally to the left and the right, remaining at the same skin point and gently



**Fig. 1** The upper hand is applied with the little finger touching the lower border of the clavicle. The finger tips touch the midline. The lower hand is applied below the first one. The thumbs do not count. The upper BLUE-point is at the middle of the hand (root of the middle and ring fingers). The lower BLUE-point is in the middle of the palm of the lower hand. This definition allows avoiding the heart. The lower edge of the lower hand indicates the phrenic line, i.e., the end of the lung. The continuation of the phrenic line and its intersection with the middle axillary line define the phrenic point (of interest for assessing the diaphragm laterally). The geometry of the two joined hands from the oblique clavicle results in a horizontal phrenic line (from *Whole Body Ultrasonography in the Critically Ill*, Springer)

D. A. Lichtenstein (✉)  
Medical Intensive Care Unit, Hospital Ambroise-Paré,  
Boulogne (Paris-Ouest), France  
e-mail: dlicht@free.fr

G. A. Mezière  
Medical Intensive Care Unit, Centre Hospitalier, Mantes, France



**Fig. 2** The probe indicates the PLAPS-point, in the horizontal continuation with the lower BLUE-point (*dotted line*), as posterior as possible to the posterior axillary line with the patient remaining supine. The PLAPS-point is therefore located slightly above the diaphragm. The right index finger roughly indicates the phrenic point (target). PLAPS: posterolateral alveolar and/or pleural syndrome, a basic term used in the BLUE-protocol. Note important features regarding this probe: microconvex shape, 1 × 2 cm footprint, 8 cm length, good resolution from 1 to 17 cm depth, allowing both posterior analysis and fine resolution (from *Whole Body Ultrasonography in the Critically Ill*, Springer)

gliding over the underskin, one immediately scans 1 cm from either part of the BLUE-point, improving detection of B-lines or C-lines.

The upper BLUE-point immediately informs on pneumothorax (A'-profile) in semirecumbent (i.e., Stage 1', usually performed in dyspneic, nonventilated) patients. The lower BLUE-point immediately informs on pneumothorax in supine (i.e., stage 1, performed on mechanical ventilation) patients. The upper and lower BLUE-points immediately inform on pulmonary edema (B-profile) or immediately suggest pulmonary embolism (A-profile). The PLAPS-point allows immediate diagnosis of pneumonia, when combined with negative anterior findings among others [4]. Note that the BLUE-points are not appropriate for subtle approach of ARDS, nor for comprehensive search of small anterior (C-profile) or lateral consolidations, requiring more liberal scanning. The lung point, as

opposed to the BLUE-points, is located according to the pneumothorax extent [9].

In the BLUE-protocol, we advise a 5-MHz microconvex probe resulting in a small footprint, and a good resolution for both superficial and deep disorders (Fig. 2). This probe also allows satisfactory analysis of the vessels, heart, optic nerves, belly, i.e., whole body analysis, neonate excepted [2]. Those who do not benefit from this probe will need the good resolution of abdominal probes for the anterior analysis of the artifacts, the good superficial resolution of linear probes for details on lung sliding, and the good ergonomics of cardiac probes for PLAPS detection, taking maximal care for disinfecting each probe between changes, which prevents the BLUE-protocol to be performed within 3 min as advocated [4].

Standardizing the BLUE-points should favor widespread use of the BLUE-protocol, enabling this visual medicine to be applied to most patients [10].

## References

1. Irwin RS, Rippe JM (2008) Intensive care medicine, 6th edn. Lippincott Williams and Wilkins, Philadelphia, pp 491–496
2. Lichtenstein D (2010) Introduction to lung ultrasound. In: Lichtenstein D (ed) Whole body ultrasonography in the critically ill. Heidelberg, Springer, pp 117–127
3. Brenner DJ, Hall EJ (2007) Computed tomography—an increasing source of radiation exposure. *New Engl J Med* 357(22):2277–2284
4. Lichtenstein D, Mezière G (2008) Relevance of lung ultrasound in the diagnosis of acute respiratory failure. The BLUE-protocol. *Chest* 134:117–125
5. Lichtenstein D, Holzapfel L, Frija J (2000) Projection cutanée des pneumothorax et impact sur leur diagnostic échographique. *Réan Urg* 9(Suppl 2):138s
6. Guyton CA, Hall JE (1996) Textbook of medical physiology, 9th edn. W.B. Saunders, Philadelphia, pp 496–497
7. Lichtenstein D, Hulot JS, Rabiller A, Tostivint I, Mezière G (1999) Feasibility and safety of ultrasound-aided thoracentesis in mechanically ventilated patients. *Intensive Care Med* 25:955–958
8. Lichtenstein D, Lascols N, Mezière G, Gepner A (2004) Ultrasound diagnosis of alveolar consolidation in the critically ill. *Intensive Care Med* 30:276–281
9. Lichtenstein D, Mezière G, Biderman P, Gepner A (2000) The lung point: an ultrasound sign specific to pneumothorax. *Intensive Care Med* 26:1434–1440
10. van der Werf TS, Zijlstra JG (2004) Ultrasound of the lung: just imagine. *Intensive Care Med* 30:183–184