

WORKSHOP PRESENTATION**Open Access**

The clinical utility of contrast enhanced whole-heart coronary MRA with 32-channel coil at 3T scanner in the era of 64 and more-slice CT

M Wu^{1,2*}, Y Huang^{1,2}, F Wu^{1,2}, K Chiou^{3,2}, H Huang¹

From 16th Annual SCMR Scientific Sessions
San Francisco, CA, USA. 31 January - 3 February 2013

Background

Sixty-four and more-slice cardiac CT provides rapid and high quality coronary CT angiography for the majority of clinical needs of non-invasive evaluation of coronary artery. However, the recent advance of whole-heart coronary MRA has been able to provide high-quality of coronary MRA and also myocardial image in a reasonable scan time. The purpose of this study was to evaluate the clinical indication and the feasibility of coronary MRA with 32-channel coil at 3T scanner.

Methods

Acquisition of 3.0T coronary MRA data was done by using 32-channel torso coil (Skyra, Siemens AG Healthcare, Erlangen, Germany). An ECG-triggered, respiratory navigator-gated, inversion-recovery prepared, segmented gradient-echo sequence was used for image acquisition with an acceleration factor of 3 in the phase-encoding direction using generalized auto calibrating partially parallel acquisitions reconstruction. Slow infusion of 0.15 mmol/kg body weight of Gadobenate dimeglumine (MultiHance; Bracco Imaging SpA, Milan, Italy) at a rate of 0.2 mL/s was given. The image quality of coronary MRA was scored as 4, excellent; 3, good, confident for diagnosis; 2, fair, suboptimal for diagnosis; and 1, poor, not diagnostic. The clinical impact of the examination were classified as high, major revision; medium, minor revision or confirmation and low, non contribution to clinical diagnosis and management.

Results

Totally 76 patients (median of age = 22 years, 55 male) received the examination and 71 completed. The 5 failures were due to interrupted anesthesia (N=3), unstable vital signs (N=2). The indications of the 71 examination were (1). Kawasaki disease, N= 26 ; (2). anomalous coronary artery, with or without complex congenital heart disease, N = 8; (3). assessment of coronary artery disease in young patients with familiar hyperlipidemia, N = 9 ; (4). assessment of coronary artery stenosis in patients with heavy calcification, N = 11 and (5). complete evaluation of newly onset heart failure with low risk of coronary artery disease, N = 17. The scores of image quality were 18, 42, 8, 3 for scores of 4, 3, 2, and 1, respectively. The mean image time was 8.2 min. There were additional image findings included: 1. hyper-enhancement of myocardium, N = 23; 2. myocardial wall hypertrophy, N =17; 3. myocardial wall focal thinning, N = 14; 4. functional valvular disorders, N = 7. The clinical impacts of the examination were high in 14, medium in 40 and low in 17 patients.

Conclusions

Contrast enhanced whole-heart coronary MRA with 32-channel coil at 3T scanner has high clinical feasibility for appropriate clinical indications.

¹Radiology, Kaohsiung Veterans General Hospital, Kaohsiung, Taiwan
Full list of author information is available at the end of the article

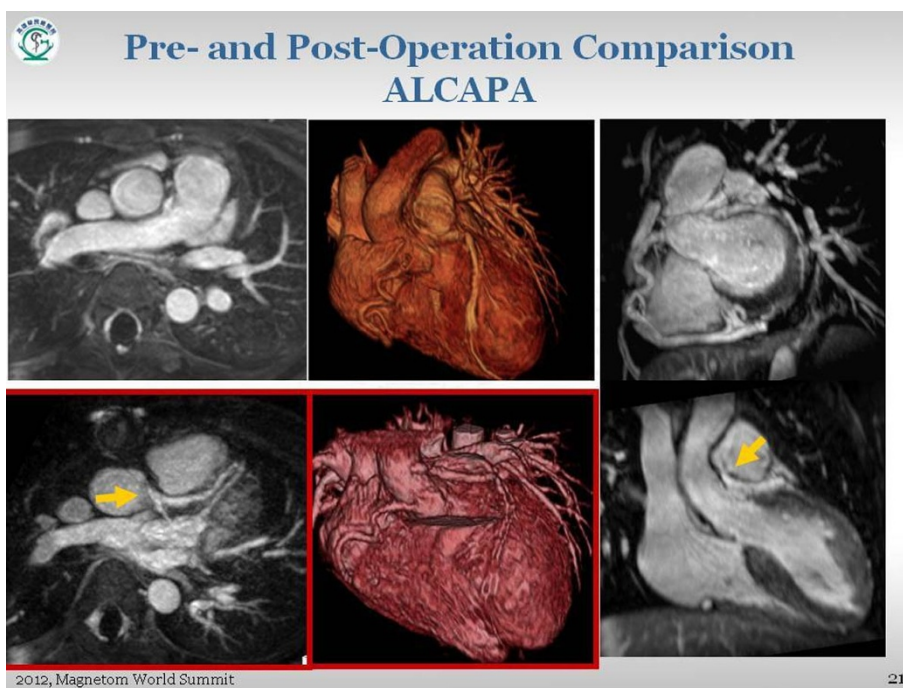


Figure 1 Pre-operation: Abnormal origin of left coronary artery from the inferior wall of main pulmonary artery, which has patent anastomosis with right coronary artery. Postoperation (lower-right): In-plantation of left coronary artery to the aorta.

Author details

¹Radiology, Kaohsiung Veterans General Hospital, Kaohsiung, Taiwan.
²Radiology, Faculty of Medicine, School of Medicine, National Yang Ming University, Taipei, Taiwan. ³Cardiology, Kaohsiung Veterans General Hospital, Kaohsiung, Taiwan.

Published: 30 January 2013

doi:10.1186/1532-429X-15-S1-W28

Cite this article as: Wu et al.: The clinical utility of contrast enhanced whole-heart coronary MRA with 32-channel coil at 3T scanner in the era of 64 and more-slice CT. *Journal of Cardiovascular Magnetic Resonance* 2013 **15**(Suppl 1):W28.

Submit your next manuscript to BioMed Central and take full advantage of:

- Convenient online submission
- Thorough peer review
- No space constraints or color figure charges
- Immediate publication on acceptance
- Inclusion in PubMed, CAS, Scopus and Google Scholar
- Research which is freely available for redistribution

Submit your manuscript at
www.biomedcentral.com/submit

 BioMed Central