

*Annals of Surgical Oncology* 14(4):1499–1506  
DOI: 10.1245/s10434-006-9323-2

# Isolated Limb Perfusion with Tumor Necrosis Factor Alpha and Melphalan for Locally Advanced Soft Tissue Sarcoma: Three Time Periods at Risk for Amputation

Robert J. van Ginkel, MD, PhD,<sup>1</sup> Katja M. J. Thijssens, MD,<sup>1</sup> Elisabeth Pras, MD, PhD,<sup>2</sup>  
Winette T. A. Van der Graaf, MD,<sup>3</sup> Albert J. H. Suurmeijer, MD, PhD,<sup>4</sup>  
and Harald J. Hoekstra, MD, PhD<sup>1</sup>

<sup>1</sup>Division of Surgical Oncology, Department of Surgery, University Medical Center Groningen and University of Groningen, PO Box 30.001, 9700 RB Groningen, The Netherlands

<sup>2</sup>Department of Radiotherapy, University Medical Center Groningen and University of Groningen, PO Box 30.001, 9700 RB Groningen, The Netherlands

<sup>3</sup>Department of Medical Oncology, University Medical Center Groningen and University of Groningen, PO Box 30.001, 9700 RB Groningen, The Netherlands

<sup>4</sup>Department Pathology, University Medical Center Groningen and University of Groningen, PO Box 30.001, 9700 RB Groningen, The Netherlands

---

**Background:** The aim of this study was to investigate the long-term limb salvage rate and overall survival after isolated limb perfusion (ILP) with tumor necrosis factor alpha and melphalan for locally advanced soft tissue sarcoma (STS).

**Methods:** From 1991 to 2003, 73 patients (36 men, 37 women, median age 54 [range 14–80] years) with biopsy-proven STS underwent 77 perfusions followed by delayed surgical resection, with or without adjuvant radiation. Limb salvage and overall survival curves were calculated by the Kaplan-Meier method.

**Results:** A total of 21 amputations (28%) were performed. Overall 1, 5, and 10 years' limb salvage was 80.1% ± 4.8%, 68.2% ± 6.5%, and 60.6% ± 9.2%, respectively. We found that the risk of amputation was linked to three time periods. The first was within a year after perfusion, mainly as a result of massive necrosis of the tumor and overlying skin, resulting in soft tissue deficit or recurrent disease (n = 17). The second was within 5 years, with two amputations performed for late local recurrence. The third occurred 10 years after perfusion, with two amputations performed for critical leg ischemia. Another two patients developed a pathological fracture of the femur due to radiation osteonecrosis. These four patients received adjuvant radiotherapy. Overall, 1, 5, and 10 years' survival was 82.9% ± 9.2%, 58.7% ± 13.1%, and 42.5% ± 18.2%, respectively.

**Conclusions:** ILP treatment with tumor necrosis factor alpha and melphalan followed by delayed surgical resection and adjuvant radiation treatment is an effective limb salvage treatment regimen for locally advanced STS. However, we observed late morbidity, with two amputations performed for critical leg ischemia and two pathological fractures of the femur in patients receiving adjuvant radiotherapy.

**Key Words:** Isolated limb perfusion—Sarcoma—Tumor necrosis factor alpha—Melphalan—Radiotherapy—Amputation—Late morbidity.

---

Received August 2, 2004; accepted March 10, 2006; published online: January 26, 2007.

Address correspondence and reprint requests to: Harald J. Hoekstra, MD, PhD; E-mail: h.j.hoekstra@chir.umcg.nl

Published by Springer Science+Business Media, Inc. © 2007 The Society of Surgical Oncology, Inc.

Limb salvage in patients with locally advanced extremity soft tissue sarcoma (STS) continues to be a challenge. Survival in these patients is determined by the development of distant metastases and is not

improved with the amputation of the affected limb.<sup>1,2</sup> Besides amputation, an extensive surgical procedure followed by radiotherapy is a treatment option.<sup>3</sup> Rosenberg et al.<sup>1</sup> showed the same disease-free and overall survival as amputation in the early 1980s with this treatment regimen. Preoperative therapies to improve limb salvage rates have been proposed. Suit et al.<sup>4</sup> reported in 1981 on the use of preoperative radiotherapy. Eilber et al.<sup>2,5</sup> combined preoperative (intra-arterial or systemic) chemotherapy and radiotherapy to improve resectability rates. In a randomized trial, O'Sullivan et al.<sup>6</sup> reported a greater risk of wound complications in the preoperative radiotherapy group compared with the postoperative radiotherapy group. The use of brachytherapy may also improve local control and avoid amputation.<sup>7</sup> The current treatment strategy of high-grade limb sarcomas is wide local resection, with the goal of achieving a R0 resection with a 2-cm margin. If the margin is < 2 cm or if a R1 resection (microscopically involved margin) is performed, adjuvant radiotherapy with 50–70 Gy is indicated to reduce the risk of local failure.<sup>3</sup> The question whether radiotherapy should be given before or after surgery is still unanswered.<sup>6</sup>

Another strategy for limb salvage in locally advanced extremity STS is to perform an isolated limb perfusion (ILP) with cytostatic agents. This procedure, which was originally developed for the treatment of melanoma of the limb in 1957, was also applied to the treatment of STS of the limb. In their first experience, Kremenz et al.<sup>8</sup> showed an early response rate of 83% with melphalan alone; however, complete regression of the tumor was rarely seen. Other perfusion agents in the treatment of limb STS were therefore investigated. Rossi et al.<sup>9</sup> claimed that doxorubicin was efficacious; another study<sup>10</sup> showed that doxorubicin alone was ineffective and that combined with melphalan, it was too toxic. Cisplatin also proved to be less effective than melphalan in the limb perfusion setting of sarcomas, and carboplatin was too neurotoxic.<sup>11–13</sup>

With the addition of tumor necrosis factor alpha (TNF- $\alpha$ ) to the perfusion circuit, Lienard et al.<sup>14</sup> made a step forward in the treatment of locally advanced extremity STS. A large European multicenter study proved the ILP concept in the limb salvage procedures for locally advanced STS with TNF- $\alpha$  and melphalan. The objective response rate was 75%, and a limb salvage rate of 82% was achieved with minimal treatment-related morbidity.<sup>15</sup> Since 1991, patients with locally advanced STS of the limbs have been treated at the University Medical

Center Groningen by ILP with TNF- $\alpha$  and melphalan with or without interferon gamma as perfusion agents, followed by delayed surgical excision and postoperative radiotherapy if a marginal resection or nonradical resection was performed. Recently we encountered long-term local morbidity, and therefore the aim of the present study was to analyze the limb salvage rate and survival in patients with locally advanced STS of the extremities that were treated in our center and to report the late effects of this treatment modality.

## PATIENTS AND METHODS

### Patient Characteristics

During 1991–2003, a total of 73 patients with STS of the extremity underwent 77 perfusions with a combination of TNF- $\alpha$  and melphalan, with (n = 19) or without (n = 58) interferon gamma. Thirty-six men and 37 women with a median age of 54 (range 14–80) years were treated. Tumors were considered unresectable because of size, their multicentricity in the limb, or fixation to the neurovascular bundle and/or bone, and therefore amputation was the only treatment option. Perfusion was performed at the iliac level in 32 cases (42%), at the popliteal level in 23 cases (30%), and at the femoral and axillary level in 11 cases each (14%). There were 60 primary (82%) and 13 recurrent (18%) sarcomas. Sixty-two sarcomas were located in the leg (85%) and 11 were located in the arm (15%). All patients were treated after informed consent was obtained according to institutional guidelines. Nineteen different histological types of STS were distinguished. The pathological grade of the tumor was scored following the criteria of Coindre et al.,<sup>17</sup> and the stage of the tumor was scored according to the American Joint Committee on Cancer (AJCC) criteria<sup>16</sup> (Table 1). Median tumor size was 16.2 (range 8.3–23) cm. In case of multifocal disease, the largest diameter was used.

### Perfusion Technique

The perfusion technique used at the University Medical Center Groningen is based on the technique developed by Creech et al.<sup>18</sup> and described elsewhere.<sup>19</sup> The major modifications during the last 30 years were the use of modern thermal blankets, improvement in leakage monitoring, and the introduction of a membrane oxygenator and heat

**TABLE 1.** Histological grade and stage of tumors<sup>a</sup>

Characteristic	n	%
Grade		
I	10	14
II	23	32
III	40	54
Stage		
I	10	14
II	1	1
III	50	69
IV	12	16

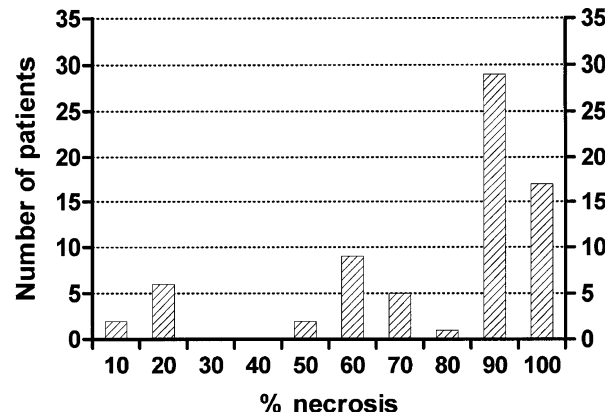
<sup>a</sup> Grade according to Coindre et al.,<sup>17</sup> and stage according to American Joint Committee on Cancer.<sup>16</sup>

exchanger to ensure optimal perfusion at 39–40°C. Because extensive washing with 6 L of saline is used, systemic inflammatory response syndrome (SIRS) is rarely seen.<sup>20</sup> After surgery, patients can be monitored on the recovery ward instead of the intensive care unit.

**Assessment of Tumor Response, Tumor Remnant, and Follow-up**

Responses were assessed by standardized World Health Organization criteria and on the basis of physical examination and/or imaging investigations (magnetic resonance imaging and computed tomographic scans).<sup>21</sup> Complete response was defined as the disappearance of all measurable disease in the limb for > 4 weeks, partial response as regression of the tumor size by > 50% of the largest diameter for > 4 weeks, and no change as regression of < 50% of the tumor in the limb or progression of < 25% for longer than 4 weeks. Resection of the tumor remnants was performed 2–15 weeks (median, 8 weeks) after perfusion. After resection, response was also assessed by pathological examination. The tumor remnants were measured in three dimensions and the percentage of necrosis estimated in relation to the complete tumor volume. Representative tumor sections were taken, encompassing macroscopically different tumor areas, including necrosis. As a general rule, one section per centimeter largest diameter with a minimum of three was taken. On the basis of an integration of gross and microscopic findings, a final estimate of the percentages of viable and necrotic or regressive tumor was made.

Excision margins were also evaluated on pathological examination and classified as radical when the resection margins were free of tumor cells (complete resection, R0), as R1 when resection margins were microscopically involved, or as R2 when resection



**FIG. 1.** Percentage of necrosis estimated at pathological examination of resected tumor remnant in relation to number of patients.

margins were macroscopically positive involved. Postoperative radiotherapy (60–70 Gy) was considered indicated in case of < 95% necrosis on pathological examination of the tumor or with marginal or microscopically positive resection margins. All patients were followed after perfusion treatment in a standardized protocol. Median follow-up was 27 (range 2–138) months.

**Statistical Analysis**

Survival and limb salvage curves were calculated according to the Kaplan-Meier method and log rank test.<sup>22</sup> Values of *P* < 0.05 were considered to be statistically significant. GraphPad Prism version 2.0 for Windows statistical software was used.

**RESULTS**

**Tumor Response**

A clinical complete response was observed after 19 ILPs (25%), a partial response after 53 ILPs (69%), and no change after 5 ILPs (6%); local progression was never observed. Resection of the remnant tumor was performed in 68 patients (93%). The pathological response is illustrated in Fig. 1. After 17 ILPs (23%), no viable tumor cells were found on pathological examination. In 29 ILPs (37%), ≥ 90% necrosis was found on pathological examination. When both groups were added together, a good response to ILP was found in 60% of the patients. In 17 ILPs (22%), an intermediate response was found on pathological examination (necrosis 50%–80%). After eight ILPs (10%), < 20% of necrosis or no necrosis was found on pathological examination. In five patients (7%),

**TABLE 2.** Amputations performed in 21 patients according to interval duration

Patient no.	Diagnosis	Age (y)	Interval (mo)	Resection	RT	Rationale for amputation	Current status
1	PUS	60	0	R0	No	Postperfusion necrosis <sup>38</sup>	NED 120 months
2	Angiosarcoma	74	1	R2	No	Local recurrence	DOD 11 months
3	Fibrosarcoma	76	1	R0	No	Postperfusion necrosis	NED 2 months
4	PUS	67	2	R0	No	Postperfusion necrosis	DOD 9 months
5	Epithelioid Sarcoma	21	2	R0	No	Postperfusion necrosis	DOD 54 months
6	Leiomyosarcoma	17	2	R0	No	Insufficient clinical response	DOD 7 months
7	Liposarcoma	60	2	R1	No	R1 resection, RT not possible	AWD 10 months
8	PNET	62	3	R0	No	Local recurrence	DOD 17 months
9	Synovial sarcoma	39	3	R0	No	Postperfusion necrosis	DOD 50 months
10	PUS	63	3	R1	No	Postperfusion necrosis	NED 72 months
11	Angiosarcoma	80	4	R1	No	Local recurrence	DOD 10 months
12	Synovial sarcoma	65	4	R1	No	R1 resection, RT not possible	NED 6 months
13	Epithelioid Sarcoma	22	6	R2	No	Local recurrence <sup>a</sup>	DOD 39 months
14	Hemangioma pericytoma	50	8	R0	Yes	Wound complications after ILP with radiotherapy <sup>a</sup>	AWD 65 months
15	PUS	71	12	R0	Yes	Wound complications after ILP with radiotherapy <sup>a</sup>	NED 14 months
16	PUS	61	15	R0	Yes	Arterial occlusion	AWD 17 months
17	Synoviosarcoma	42	18	R1	Yes	Local recurrence	NED 20 months
18	Liposarcoma	53	37	R0	Yes	Local recurrence	DOD 110 months
19	Liposarcoma	39	58	R0	No	Local recurrence	DOD 120 months
20	PNET	56	110	R0	Yes	Critical leg ischemia	NED 118 months
21	Chondrosarcoma	18	125	R0	Yes	Critical leg ischemia	NED 134 months

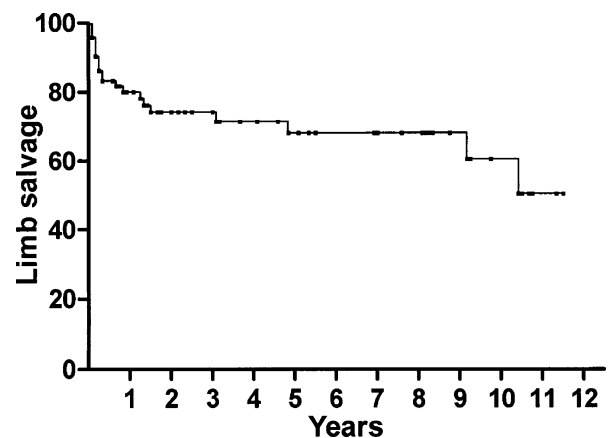
PUS, pleomorphic undifferentiated sarcoma; RT, radiotherapy; NED, no evidence of disease; AWD, alive with disease; DOD, death of disease; PNET, malignant peripheral nerve sheath tumor; R1 resection, microscopically involved resection margin; ILP, isolated limb perfusion.

<sup>a</sup> Patients treated for second ILP with tumor necrosis factor alpha and melphalan.

tumor response was not assessed because of progression of distant metastases in four patients and a local recurrence in one patient that necessitated a second perfusion, resulting in 90% necrosis of the tumor. No correlation could be demonstrated between grade and percentage of tumor necrosis after perfusion (Pearson's correlation). Postoperative radiotherapy (total dose 60–70 Gy, 25 × 2 Gy daily and 10–20 Gy boost) was given in 37 patients with microscopically involved or marginally free resection margins. Radiotherapy was initiated within 5–6 weeks after tumor resection. Radiation treatment was delivered through a multiple-field technique with computed tomographic treatment planning on a linear accelerator, 6–15 MV.

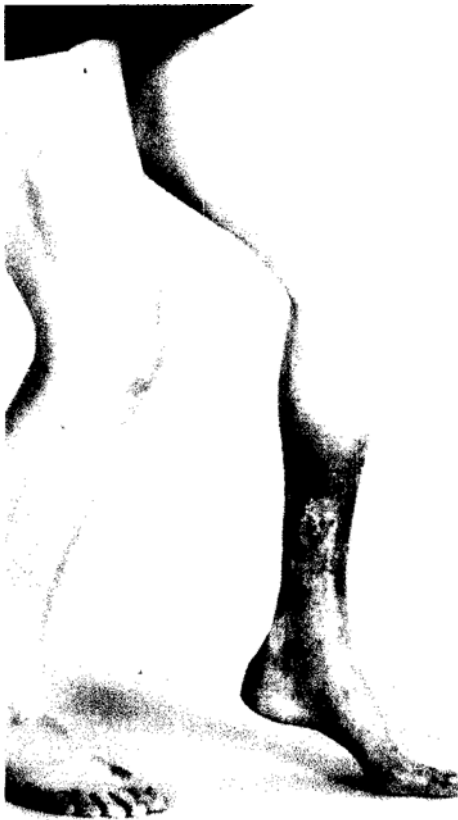### Amputations and Limb Salvage

A total of 21 amputations (28%) were performed. Table 2 presents the time interval between ILP and amputation and the rationale for amputation. Overall 1, 5, and 10 years' limb salvage was 80.1% ± 4.8%, 68.2% ± 6.5%, and 60.6% ± 9.2%, respectively (Fig. 2). When we analyzed the limb salvage curve, we found that the risk for amputation could be divided into three time episodes. The first period occurs within the first year or year and a half after



**FIG. 2.** Limb salvage curve in patients with locally advanced soft tissue sarcoma treated with tumor necrosis factor alpha, melphalan, and isolated limb perfusion.

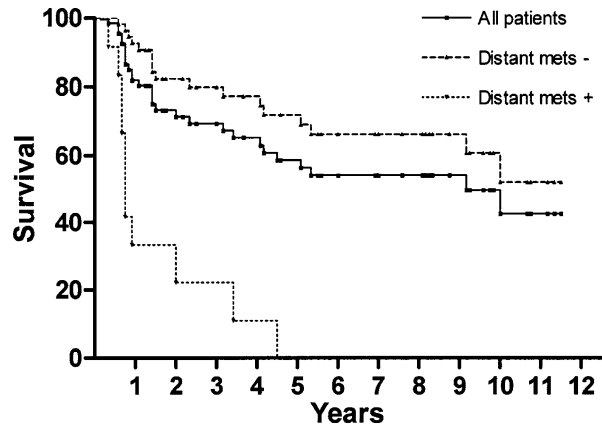
perfusion (n = 17 patients), with amputation performed to treat massive perfusion-induced necrosis of the tumor and overlying skin, which resulted in a soft tissue deficit (n = 6); tumor recurrence after perfusion (n = 5); wound complications after ILP followed by radiotherapy (n = 2); a microscopically involved resection margin with the rejection of the patient for adjuvant radiotherapy of the foot (n = 2); insufficient clinical response (one patient);



**FIG. 3.** Clinical appearance of lower leg of patient 21 (Table 3) before amputation for critical leg ischemia.

and arterial thrombosis with no vascular reconstruction possibilities 2 months after resection of a local recurrence in the groin (n = 1).

The second time period was within 5 years after ILP, with two amputations performed for late local recurrent disease (37 and 58 months after perfusion). The third episode occurred approximately 10 years after perfusion. Amputation was performed for critical leg ischemia with neuropathy due to treatment-induced atherosclerosis of the remaining tibial artery that was not suitable for arterial reconstruction (110 and 125 months after perfusion). An example of the clinical appearance of patient 21 is shown in Fig. 3. In this patient, a popliteal ILP was performed at the age of 18 years for a chondrosarcoma. After marginal resection, this patient received 66 Gy adjuvant radiotherapy. Ten years after ILP, an amputation was performed because of critical leg ischemia. No recurrent disease was found on pathological examination of the amputated specimen. Another two patients developed a pathological fracture of the femur due to radiation-induced osteonecrosis (78 and 129 months after perfusion). These four patients with



**FIG. 4.** Overall survival in patients with locally advanced soft tissue sarcoma treated with isolated limb perfusion (ILP), tumor necrosis factor alpha, and melphalan. Statistically significant difference was observed between patients with no distant metastases at time of ILP (mets -) compared with patients with metastases at time of ILP (mets +).

late post-ILP complications received high-dose post-perfusion radiotherapy (60–70 Gy).

**Systemic Metastases and Survival**

Twelve patients presented with distant metastases at time of ILP (16% stage IV AJCC); half of these patients had lung metastases, and the other half had lymph node metastases. Eleven of these patients died of disease after a median period of 9 (range 2–54) months; one patient is alive with no evidence of disease after 11 months. During follow-up, 25 patients (36%) developed distant metastases at a median interval of 9 (range 2–100) months. A statistically significant difference ( $P < .001$ ) was observed between patients with no distant metastases at the time of ILP compared with patients with metastases at the time of ILP (Fig. 4). Overall 1, 5, and 10 years' survival for all patients was  $82.9\% \pm 9.2\%$ ,  $58.7\% \pm 13.1\%$ , and  $42.5\% \pm 18.2\%$ , respectively (Fig. 4).

**DISCUSSION**

The results of a European multicenter trial performed in the 1990s led to the approval of the use of TNF- $\alpha$  for ILP in patients with locally advanced extremity sarcomas by the European Medicine Evaluation Agency.<sup>15</sup> ILP with TNF- $\alpha$  is currently available in more than 30 centers, and in 2002, a total of 350 so-called TNF- $\alpha$  perfusions were performed. As one of the first centers that participated in the



TNF- $\alpha$  ILP experience, and with more than a decade's experience, we recently encountered long-term treatment-related morbidity necessitating amputation of the perfused limb 10 years after treatment. For this reason, we analyzed our results of ILP with TNF- $\alpha$  and melphalan and describe our results in the present study.

We observed an overall response rate of 82%, which is in the range of the 63%–91% response rates reported in the literature.<sup>15,23,25</sup> Although a suggestion has been made for a relation between the grade of sarcoma and the response to TNF- $\alpha$  ILP, we could not demonstrate a correlation between grade and the percentage of necrosis after ILP with TNF- $\alpha$ . This is in concordance with the results of the Amsterdam group.<sup>23</sup> Various reports have shown that a limb salvage rate of 81%–86% can be achieved in patients with locally advanced limb sarcoma.<sup>15,23,25</sup> An independent review committee reconsidered the unresectability criteria of all patients enrolled onto the European study. Eighty percent of the patients in this study met the criteria for unresectability, and survival curves based on a match-control study with cases of the Scandinavian Soft Tissue Sarcoma Databank showed that TNF- $\alpha$  ILP had no negative effect on survival.<sup>26</sup>

We used the Kaplan-Meier method to calculate limb salvage because this method adjusts for censored observations, i.e., patients who were alive and well at the time of last contact or patients who died of distant metastases but who retained preserved limb function. By use of this method, we calculated a 1-year limb salvage rate of 80%. Amputations were performed mostly because of postperfusion-related complications or early local recurrence in the first year after ILP. A second curve in limb salvage was observed within 5 years after TNF- $\alpha$  ILP in two patients with late local recurrences. A third bend in the limb salvage curve was observed approximately 10 years after ILP. This was a new observation in two patients who had critical leg ischemia with ulceration and continuous pain. Besides ILP with TNF- $\alpha$  and melphalan, both patients received adjuvant radiotherapy (66 and 70 Gy) after marginal tumor resection.

What seems to be the cause of this late morbidity? Analysis of the functional and long-term morbidity in 97 patients with stage I melanoma treated with ILP with melphalan as the sole perfusion agent in our center showed after a median follow-up of 36 (range 12–76) months, no patients had critical leg ischemia.<sup>27</sup> The Rotterdam and Amsterdam perfusion group reported long-term morbidity consisting of

muscle atrophy or fibrosis in 11% of the patients after ILP with melphalan; however, cases of critical leg ischemia are not described.<sup>28</sup> The fact that in our series no muscle atrophy or fibrosis was found might be explained by the fact that we always perform a lateral fasciotomy after ILP to prevent a compartment syndrome. When we performed a literature search for late morbidity after ILP with TNF- $\alpha$  and melphalan, no studies could be retrieved.

The clinical importance of late morbidity after radiotherapy has evolved since Eifel et al.<sup>29</sup> retrospectively reviewed the medical records of 1784 FIGO stage IB patients receiving primary radiotherapy at the M. D. Anderson Cancer Center between 1960 and 1989. She showed that after 5 years, there was a small but continuous risk of experiencing major complications of radiotherapy (i.e., urinary, rectal, and small bowel complications) at up to 20 years of follow-up. Johansson et al.<sup>30</sup> described a high occurrence of severe neuropathy closely linked to the development of fibrosis around the nerve trunks after aggressive postoperative telecobalt therapy received in 1963–1965 in a group of 71 patients with breast cancer who were initially treated with modified radical mastectomy. Radiotherapy damage to the vascular system was demonstrated by Hopewell<sup>31</sup> in an experimental setting; arteries of hamster cheek pouch showed localized constrictions after irradiation. These constrictions were caused by clones of endothelial cells and may be the predominant factor influencing the degeneration of the capillary bed after radiotherapy.<sup>32</sup> Evidence of this occlusive effect of vessels by proliferating endothelial cells after radiation have also been reported by other investigators.<sup>33</sup>

Another argument to explain the observed late morbidity, at least in part, to radiotherapy is the fact that another two patients who received adjuvant radiotherapy after ILP with TNF- $\alpha$  and melphalan developed a pathological fracture of the femur (78 and 129 months after ILP with TNF- $\alpha$  and melphalan). Radiotherapy-induced osteonecrosis is a well-known phenomenon. Lin et al.<sup>34</sup> described 12 fractures of the femur after surgery and irradiation for STS of the thigh. Treatment of these fractures was difficult and demanding, with only four bony unions after a mean follow-up of 37 months. When we add up the evidence of developing fibrosis after ILP with melphalan and the development of fibrosis after radiotherapy, the combination of the two regimens could explain the observed late morbidity rate in the present series.

Overall survival for all patients showed a steadily decline, with a 10-year percentage of 42%. Even after

110 and 120 months, patients die of distant metastases. Sixteen percent of the patients had metastases at the time of ILP. A marked difference in survival was observed when comparing patients with pulmonary or lymph node metastases with patients lacking metastases at time of ILP. Five-year overall survival of 59% in this series is higher than the reported 5-year survival of 48% in the Amsterdam experience<sup>23</sup> and the reported 32% of Lejeune et al.<sup>24</sup> This is an unexpected observation because selection criteria for ILP with TNF- $\alpha$  between the institutes are comparable. High-grade tumors and tumors > 5 cm in diameter have a great tendency to metastasize. Patients with such tumors could theoretically benefit from neoadjuvant chemotherapy. A quantitative meta-analysis of data from 14 trials of doxorubicin-based adjuvant chemotherapy showed a benefit from systemic adjuvant chemotherapy of 6% for local relapse-free interval, but there was no overall survival benefit at 10 years.<sup>35</sup> Delaney et al.<sup>36</sup> developed a regimen of preoperative chemotherapy consisting of mesna, Adriamycin, ifosfamide, and dacarbazine (MAID) interspersed with radiotherapy, followed by resection and postoperative chemotherapy with or without radiotherapy to improve outcome in patients with high-grade extremity STS. Compared with a historical group of control patients, outcome in the MAID group was better. In an update of 64 patients, 5 required amputation because of disease, 3 had unresectable disease, and 1 patient refused surgery. Estimated 3-year survival and local-regional control were 75.1% and 79.3%, respectively. These results are comparable with the results of the present study.<sup>37</sup> However, systemic therapy is associated with systemic toxic effects, in contrast with the mild systemic side effects observed after ILP with TNF- $\alpha$  and melphalan.

Since 1992, we have not changed the indication for TNF- $\alpha$  perfusion. Patients who were candidates for amputation of the involved limb, as assessed by preoperative magnetic resonance imaging, were offered an ILP with TNF- $\alpha$  and melphalan, with the goal of preserving the limb with a locally advanced STS. After ILP patients received a delayed surgical resection, adjuvant radiotherapy was provided to patients with marginal or microscopically positive resection margins. This treatment resulted in a high limb salvage rate in patients with locally advanced STS, although late morbidity can occur, especially when adjuvant postoperative radiotherapy is applied. Therefore, continuous follow-up of these patients is warranted.

## REFERENCES

- Rosenberg SA, Tepper J, Glatstein E, et al. The treatment of soft-tissue sarcomas of the extremities: prospective randomized evaluations of (1) limb-sparing surgery plus radiation therapy compared with amputation and (2) the role of adjuvant chemotherapy. *Ann Surg* 1982; 196:305–15.
- Eilber FR, Morton DL, Eckardt J, Grant T, Weisenburger T. Limb salvage for skeletal and soft tissue sarcomas. Multidisciplinary preoperative therapy. *Cancer* 1984; 53:2579–84.
- Ham SJ, van der Graaf WT, Pras E, Molenaar WM, Van den Berg E, Hoekstra HJ. Soft tissue sarcoma of the extremities. A multimodality diagnostic and therapeutic approach. *Cancer Treat Rev* 1998; 24:373–91.
- Suit HD, Proppe KH, Mankin HJ, Wood WC. Preoperative radiation therapy for sarcoma of soft tissue. *Cancer* 1981; 47:2269–74.
- Eilber FR, Mirra JJ, Grant TT, Weisenburger T, Morton DL. Is amputation necessary for sarcomas? A seven-year experience with limb salvage. *Ann Surg* 1980; 192:431–8.
- O'Sullivan B, Davis AM, Turcotte R, et al. Preoperative versus postoperative radiotherapy in soft-tissue sarcoma of the limbs: a randomised trial. *Lancet* 2002; 359:2235–41.
- Shiu MH, Hilaris BS, Harrison LB, Brennan MF. Brachytherapy and function-saving resection of soft tissue sarcoma arising in the limb. *Int J Radiat Oncol Biol Phys* 1991; 21:1485–92.
- Krementz ET, Carter RD, Sutherland CM, Hutton I. Chemotherapy of sarcomas of the limbs by regional perfusion. *Ann Surg* 1977; 185:555–64.
- Rossi CR, Vecchiato A, Foletto M, et al. Phase II study on neoadjuvant hyperthermic-antiblastic perfusion with doxorubicin in patients with intermediate or high grade limb sarcomas. *Cancer* 1994; 73:2140–6.
- Klaase JM, Kroon BBR, Benckhuijsen C, et al. Results of regional isolation perfusion with cytostatics in patients with soft tissue tumors of the extremities. *Cancer* 1989; 64:616–21.
- Pommier RF, Moseley HS, Cohen J, Huang CS, Townsend R, Fletcher WS. Pharmacokinetics, toxicity, and short-term results of cisplatin hyperthermic isolated limb perfusion for soft-tissue sarcoma and melanoma of the extremities. *Am J Surg* 1988; 155:667–71.
- van Ginkel RJ, Schraffordt Koops H, de Vries EG, Molenaar WM, Uges DR, Hoekstra HJ. Hyperthermic isolated limb perfusion with cisplatin in four patients with sarcomas of soft tissue and bone. *Eur J Surg Oncol* 1996; 22:528–31.
- Daryanani D, de Vries EG, Guchelaar HJ, Van Weerden TW, Hoekstra HJ. Hyperthermic isolated regional perfusion of the limb with carboplatin. *Eur J Surg Oncol* 2000; 26:792–7.
- Lienard D, Ewalenko P, Delmotte JJ, Renard N, Lejeune FJ. High-dose recombinant tumor necrosis factor alpha in combination with interferon gamma and melphalan in isolation perfusion of the limbs for melanoma and sarcoma. *J Clin Oncol* 1992; 10:52–60.
- Eggermont AM, Schraffordt Koops H, Klausner JM, et al. Isolated limb perfusion with tumor necrosis factor and melphalan for limb salvage in 186 patients with locally advanced soft tissue extremity sarcomas. The cumulative multicenter European experience. *Ann Surg* 1996; 224:756–64.
- Greene FL, Page DL, Fleming ID, et al. *AJCC Cancer Staging Manual* 6th ed. New York: Springer-Verlag; 2002.
- Coindre JM, Trojani M, Contesso G, et al. Reproducibility of a histopathologic grading system for adult soft tissue sarcoma. *Cancer* 1986; 58:306–9.
- Creech O, Krementz ET, Ryan RF, Winblad JN. Chemotherapy of cancer: regional perfusion utilizing an extra-corporeal circuit. *Ann Surg* 1958; 148:616–32.
- van Ginkel RJ, Limburg PC, Piers DA, Koops HS, Hoekstra HJ. Value of continuous leakage monitoring with radioactive

- iodine-131-labeled human serum albumin during hyperthermic isolated limb perfusion with tumor necrosis factor-alpha and melphalan. *Ann Surg Oncol* 2002; 9:355-63.
20. Zwaveling JH, Maring JK, Clarke FL, et al. High plasma tumor necrosis factor (TNF)-alpha concentrations and a sepsis-like syndrome in patients undergoing hyperthermic isolated limb perfusion with recombinant TNF-alpha, interferon-gamma, and melphalan. *Crit Care Med* 1996; 24:765-70.
  21. World Health Organization Handbook for Reporting Results of Cancer Treatment Geneva, Switzerland: World Health Organization; 1979.
  22. Kaplan EL, Meier P. Nonparametric estimates from incomplete observations. *J Am Stat Assoc* 1958; 53:457-81.
  23. Noorda EM, Vrouenraets BC, Nieweg OE, van Coevorden F, van Slooten GW, Kroon BB. Isolated limb perfusion with tumor necrosis factor-alpha and melphalan for patients with unresectable soft tissue sarcoma of the extremities. *Cancer* 2003; 98:1483-90.
  24. Lejeune FJ, Pujol N, Lienard D, et al. Limb salvage by neoadjuvant isolated perfusion with TNFalpha and melphalan for non-resectable soft tissue sarcoma of the extremities. *Eur J Surg Oncol* 2000; 26:669-78.
  25. Gutman M, Inbar M, Lev Shlush D, et al. High dose tumor necrosis factor-alpha and melphalan administered via isolated limb perfusion for advanced limb soft tissue sarcoma results in a > 90% response rate and limb preservation. *Cancer* 1997; 79:1129-37.
  26. Eggermont AM, Schraffordt Koops H, Klausner JM, et al. Limb salvage by isolated limb perfusion (ILP) with tnf and melphalan in patients with locally advanced soft tissue sarcomas: outcome of 270 ILPs in 246 patients. *Proc Am Soc Clin Oncol* 1999.
  27. Olieman AF, Schraffordt Koops H, et al. Functional morbidity of hyperthermic isolated regional perfusion of the extremities. *Ann Surg Oncol* 1994; 1:382-8.
  28. Vrouenraets BC, Klaase JM, Kroon BBR, Van Geel BN. Long-term morbidity after regional isolated perfusion with melphalan for melanoma of the limbs: the influence of acute regional toxic reactions. *Arch Surg* 1995; 130:43-7.
  29. Eifel PJ, Levenback C, Wharton JT, Oswald MJ. Time course and incidence of late complications in patients treated with radiation therapy for FIGO stage IB carcinoma of the uterine cervix. *Int J Radiat Oncol Biol Phys* 1995; 32:1289-300.
  30. Johansson S, Svensson H, Denekamp J. Timescale of evolution of late radiation injury after postoperative radiotherapy of breast cancer patients. *Int J Radiat Oncol Biol Phys* 2000; 48:745-50.
  31. Hopewell JW. Early and late changes in the functional vascularity of the hamster cheek pouch after local x-irradiation. *Radiat Res* 1975; 63:157-64.
  32. Hopewell JW. The late vascular effects of radiation (letter). *Br J Radiol* 1974; 47:157-8.
  33. Fajardo LF, Stewart JR. Capillary injury preceding radiation-induced myocardial fibrosis. *Radiology* 1971; 101:429-33.
  34. Lin PP, Boland PJ, Healey JH. Treatment of femoral fractures after irradiation. *Clin Orthop* 1998; 352:168-78.
  35. Adjuvant chemotherapy for localised resectable soft-tissue sarcoma of adults: meta-analysis of individual data. Sarcoma Meta-analysis Collaboration. *Lancet* 1997; 350:1647-54.
  36. Delaney TF, Spiro IJ, Suit HD, et al. Neoadjuvant chemotherapy and radiotherapy for large extremity soft-tissue sarcomas. *Int J Radiat Oncol Biol Phys* 2003; 56:1117-27.
  37. Kraybill WG, Harris JH, Spiro I, et al. Radiation Therapy Oncology Group (RTOG) 9514: a phase II study of neoadjuvant chemotherapy (CT) and radiation therapy (RT) in the management of high risk (HR), high grade, soft tissue sarcomas (STS) of the extremities and body wall. *Proc Am Soc Clin Oncol* 2003; 22:815.
  38. van Ginkel RJ, Hoekstra HJ, Eggermont AMM, Pras E, Koops HS. Isolated limb perfusion of an irradiated foot with tumor necrosis factor, interferon, and melphalan. *Arch Surg* 1996; 131:672-4.