

## RESEARCH ARTICLE

## Open Access

# Bilateral spermatic cord en bloc ligation by laparoendoscopic single-site surgery: preliminary experience compared to conventional laparoscopy

Salvatore Micali<sup>1†</sup>, Ahmed Ghaith<sup>2†</sup>, Eugenio Martorana<sup>1\*†</sup>, Alessio Zordani<sup>1†</sup>, Angelo Territo<sup>1†</sup> and Giampaolo Bianchi<sup>1†</sup>

## Abstract

**Background:** Laparo Endoscopic Single-site Surgery (LESS) represents an evolution of minimally invasive surgery and aims to improve cosmetic outcome and reduce surgical trauma and complications associated with traditional laparoscopy. This study was performed to present our preliminary experience in bilateral spermatic cord ligation with the LESS technique and compare the results with the outcomes of conventional laparoscopic surgery.

**Methods:** Between June 2007 and May 2013, 24 patients were referred to our institute for bilateral varicocelectomy. The indications for this type of procedure were bilateral varicocele with impairment of semen parameters or chronic bilateral testicular pain. All procedures were performed via the same surgeon. The patients were divided into two groups according to the type of laparoscopic surgery. Group A included 10 patients underwent LESS technique while group B included the remaining 14 patients that underwent conventional laparoscopy.

**Results:** The comparison between the two techniques showed some important advantages for LESS: shorter operating time (45.4 min vs. 88.3 (P < .001), shorter hospital stay (16.6 hours vs. 51.4 hours) (P < .001), early return to the normal activity (2.3 days vs. 4.7 days) and better cosmetic outcomes. No conversions from LESS to conventional laparoscopy were necessary and blood loss was insignificant in all patients. All patients in the LESS group reported full satisfaction with the cosmetic outcome, whereas 85.7% of patients after conventional laparoscopy were fully satisfied with cosmesis.

**Conclusions:** Bilateral spermatic cord ligation with LESS is an alternative to conventional laparoscopy. The procedure was successfully performed in all patients. The trans-umbilical approach offers the advantage of a better cosmetic result, shorter hospital stay and less postoperative pain.

**Keywords:** Laparo Endoscopic Single-site Surgery (LESS), Transumbilical access, Bilateral spermatic cord ligation

## Background

The prevalence of varicocele is approximately 15% to 20% in the general male population and it increases to 40% to 70% in men with primary and secondary infertility, thus making varicocele the most common correctable male infertility factor [1]. Less frequently, varicocele may be a source of chronic testicular pain.

There are several theories regarding the mechanism by which varicocele could inhibit the fertility potential of affected men. The most commonly proposed theory is that excess heat, due to the varicocele, reduces spermatogenesis. Some have also speculated that the effect is via reflux of metabolites into the testes [2,3].

Various treatment modalities have been studied for patients with varicocele who have subfertility or scrotal pain, including percutaneous embolization, open (inguinal or high) varicocele ligation, subinguinal microsurgical varicocele ligation, and laparoscopic varicocele

\* Correspondence: [eugeniomartorana@libero.it](mailto:eugeniomartorana@libero.it)

†Equal contributors

<sup>1</sup>Department of Urology, University of Modena & Reggio Emilia, Via del Pozzo, 71, Modena 41124, Italy

Full list of author information is available at the end of the article

ligation. Each technique has advantages and disadvantages, and conflicting results have been achieved in different studies [4]. Advantages of laparoscopic varicocelectomy include: – increased magnification, facilitating more accurate identification of vessels [5,6]. Also, laparoscopic varicocelectomy allows for en bloc and bilateral ligation of the spermatic cord.

Efforts to further reduce the morbidity and improve the cosmetic outcome of laparoscopic surgery have led to the evolution of Laparo-Endoscopic Single-site Surgery (LESS) [7]. LESS has been developed in an attempt to reduce the morbidity and multiple scarring associated with laparoscopic surgery [8]. The feasibility of LESS varicocelectomy as a treatment modality has been described [9].

In this study we present our preliminary experience of bilateral en bloc spermatic cord ligation with LESS technique and compare the results with the outcomes of conventional laparoscopic surgery.

## Methods

### Patient demographics

Between June 2007 and May 2013, 24 patients were referred to Urology Department of Modena University for bilateral varicocelectomy. The indications for this type of procedure were bilateral varicocele with impairment of semen parameters or chronic bilateral testicular pain, based on physical examination, semen analysis and Doppler ultrasonography. Bilateral varicocelectomy in our institute is a part of routine/standard care whether open or laparoscopic. All patients gave written informed consent for the technique. The patients were divided into two groups according to the type of laparoscopic surgery and the data was collected retrospectively.

Group A included 10 patients that underwent bilateral LESS en bloc spermatic cord ligation. Their age ranged from 24 to 44 years old (mean age: 30.2 years). Two cases were bilateral grade 2, one case was grade 4 on the left and grade 2 on the right side, one case was grade 3 on the left and grade 2 on the right side, and six cases were bilateral grade 3. Two of these patients had recurrence after previous left open varicocelectomy. One patient had chronic testicular pain [Table 1]. Group A patients were informed that such elective conversion to standard laparoscopy was not a complication but rather surgical prudence because of the novelty of this procedure.

Group B included the remaining 14 patients that underwent bilateral varicocelectomy using conventional laparoscopy. The age ranged from 17 to 42 years old (mean age: 29.3 years), two cases were bilateral grade 3, four cases were bilateral grade 2, one case was bilateral grade 1, four cases were left grade 2 and right grade 1, two cases were left grade 3 and right grade 2 and one was left grade 4 and right 2. Three of these patients had

recurrence after previous left open varicocelectomy. Two patients had chronic testicular pain [Table 2].

Transabdominal sonography was done in all cases to exclude retroperitoneal masses and preoperative semen analysis was performed in all patients. Exclusion criteria included patients who underwent previous abdominal surgery. All patients provided informed consent.

All procedures were performed in the Urology Department of the University of Modena and Reggio Emilia, Italy. Laparoscopic and LESS varicocelectomies were performed by an individual urologist who was skilled in and experienced with laparoscopic surgery using a standardized protocol.

All data were collected retrospectively in excel file without any patient identifying information. Since each patient signed a general consent to the processing of personal data it was not necessary the institutional review board's approval for the data.

### Operative technique

After insufflation with carbon dioxide at 15 mmHg, the procedure started with 2 cm incision on the lower margin of the umbilicus (Figure 1). In the first five cases our transperitoneal access was created with the aid of 10 mm optical laparoscopic visual reusable trocar, Ternamian EndoTIP 10 mm (Karl Storz®, Tuttlingen, Germany) (Figure 2). This trocar enabled dissection of each tissue layer under direct vision, so that the surgeon has the visual control needed to avoid blood vessels. The next step was to substitute the optical trocar with a disposable multiport trocar (Covidien SILS™ Port, Mansfield, MA, USA) (Figure 3).

In the next five cases we performed an open technique to access the abdominal cavity and position the SILS port. Trans-umbilical access has two advantages: the use a pre-

**Table 1 LESS group patients' characteristics**

Patient	Name	Age	Varicocele grade	Previous varicocelectomy
1	MG	24	Grade 4 on the left, grade 2 on the right side	No
2	GD	29	Bilateral grade 2	No
3	MM	29	Bilateral grade 3	No
4	AM	30	Bilateral grade 2	No
5	PC	31	Bilateral grade 3	No
6	LU	25	Bilateral grade 3	Left varicocelectomy
7	MS	44	Bilateral grade 3 with chronic testicular pain	Left varicocelectomy
8	AG	32	Bilateral grade 3	No
9	EM	30	Bilateral grade 3	No
10	SM	28	Grade 3 on the left and grade 2 on the right	No

**Table 2 Conventional laparoscopy group patients' characteristics**

No.	Name	Age	Varicocele grade	Previous varicocelectomy
1	PL	20	Bilateral grade 2	No
2	PS	41	Left grade 4 Right grade 2	Left varicocelectomy
3	GM	22	Left grade 3 Right grade 2	No
4	YO	30	Left grade 2 Right grade 1	Left varicocelectomy
5	YS	18	Bilateral grade 2	No
6	AA	19	Left grade 3 Right grade 2	No
7	DS	17	Bilateral grade 2	No
8	TT	42	Bilateral grade 2	No
9	PS	30	Left grade 2 Right grade 1	No
10	RD	41	Left grade 2 Right grade 1	No
11	MA	20	Bilateral grade 3	No
12	RP	38	Left grade 2 Right grade 1	Left varicocelectomy
13	AM	39	Bilateral grade 1	No
14	BC	33	Bilateral grade 3	No

existing scar gives better cosmetic result, and trans-umbilical access allows for quick identification of the spermatic cords and vas deferens bilaterally by the same incision. The SILS port allows the insertion of a 5-mm flexible laparoscope EndoEye camera system (Olympus Medical, Orangeburg, NY, USA) that minimizes the

internal and external clashing of the instruments (Figure 4). Standard, reusable, 5 and 10 mm laparoscopic instruments were used to perform the procedure.

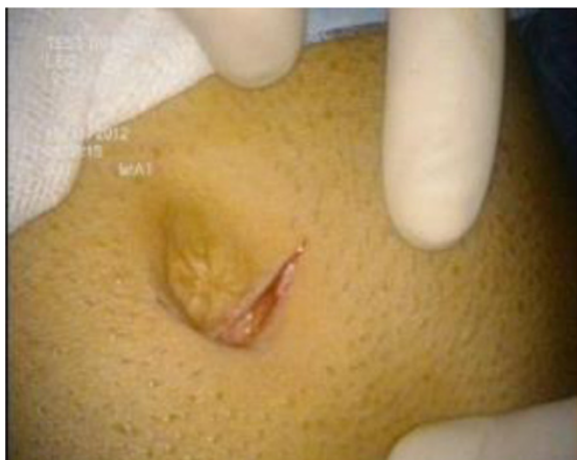A 3–4 cm “T” incision of the posterior parietal peritoneum was done lateral to the spermatic cord and proximal to the internal ring and vas deferens. The spermatic cord was isolated en bloc and four Hem-o-lok® (Teleflex Medical Research, Triangle Park, NC, USA) were placed for haemostasis. It is important to ensure vas deferens preservation with its artery to ensure blood supply to the ipsilateral testis. The same manoeuvre was then performed on the other side. At the end of the procedure the abdominal cavity is slowly deflated for haemostasis control.

#### Conventional laparoscopic varicocelectomy

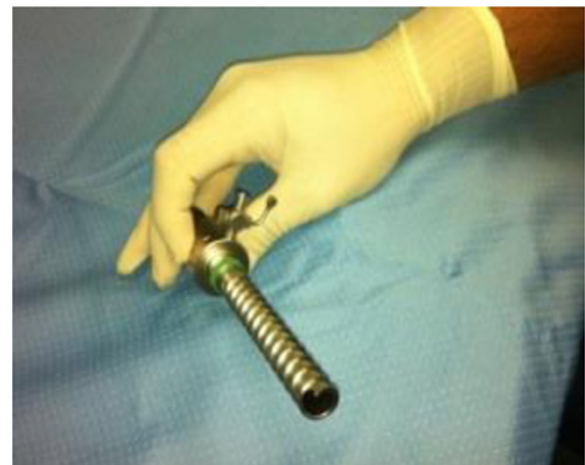The surgical steps were identical to those described for LESS technique. Under general anesthesia the patient is positioned supine and a Foley catheter is placed in the bladder. The abdomen is insufflated to 15 mm. Hg and a 12 mm transumbilical optical trocar was used for the 0-degree lens. A second 5 mm. port and an additional 10 mm. port were placed in the mid line of lower abdomen between umbilicus and symphysis pubis and used for dissection using standard, reusable, 5 and 10 mm laparoscopic instruments.

The overlying peritoneum is incised and the spermatic cord is isolated circumferentially proximal to the internal inguinal ring and the vas deferens.

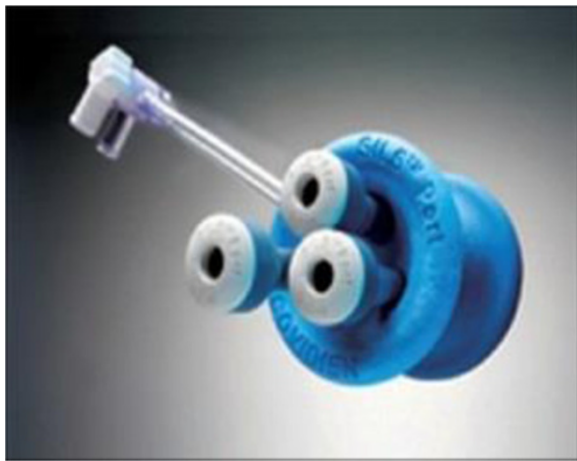Selective bilateral varicocelectomy was performed in 5 cases. Gonadal vein is identified and adjacent tissue with lymphatics is swept away, and the vein is ligated using titanium clips. The papaverine test is used for identification and preservation of the testicular artery. En bloc ligation of the spermatic cord and surrounding tissue was performed in the remaining 9 cases using Hem-o-lok®.



**Figure 1** Umbilical incision.



**Figure 2** Ternamian EndoTIP 10 mm optical trocar.



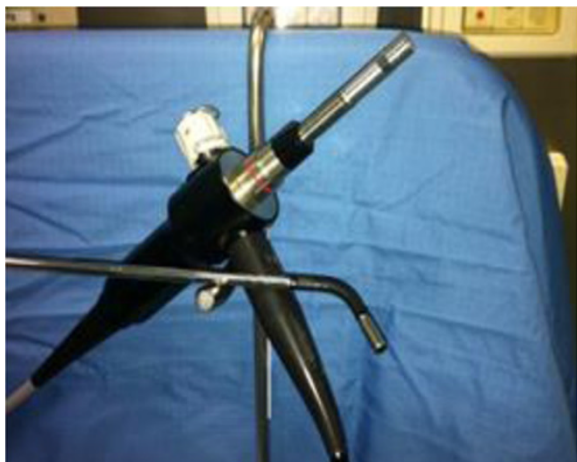**Figure 3** Covidien SILS™ port.

### Results

All procedures were performed successfully. Table 3 summarizes the results of both groups.

In LESS group operative time ranged from 31 to 75 - minutes (mean: 45.4 minutes), and the estimated blood loss was insignificant. The hospital stay ranged from 12 to 24 hours (mean: 16.6 hours). Time to return to work ranged from 2 to 3 days (mean: 2.3 days). None of the patients required narcotics or additional analgesia in the postoperative period. No intraoperative nor postoperative complications occurred.

In conventional laparoscopy group operative time ranged from 65 to 130 minutes (mean: 88.3 minutes), and the estimated blood loss was insignificant. The hospital stay ranged from 24 to 168 hours (mean: 51.4 hours). Time to return to work ranged from 4 to 7 days (mean: 4.7 days). Five patients required postoperative analgesia.



**Figure 4** EndoEye camera system.

Two patients had left orchitis and one of these developed an abdominal hematoma.

A scrotal echo-color Doppler was performed after 3, 6 and 12 months in all patients of both groups and showed no recurrence of varicocele, no testicular hypotrophy nor secondary hydrocele developed in any patients. A postoperative semen analysis was done 3, 6 and 12 months post-procedure to evaluate the sperm concentration, motility, and morphology; it showed an improvement of semen parameters in seven of LESS group patients versus nine patients of the other group. The patients with chronic testicular pain in both groups had improvement after 3 months. Six months after the procedure, the patients were completely pain free.

All patients in the LESS group reported full satisfaction with the cosmetic outcome (Figure 5), whereas 85.7% of patients after conventional laparoscopy were fully satisfied with cosmesis.

The comparison between the two techniques showed some important advantages for LESS: shorter operating time (45.4 min vs. 88.3 (P < .001), shorter hospital stay (16.6 hours vs. 51.4 hours) (P < .001), early return to the normal activity (2.3 days vs. 4.7 days) and better cosmetic outcomes. No conversions from LESS to conventional laparoscopy were necessary and blood loss was insignificant in all patients.

### Discussion

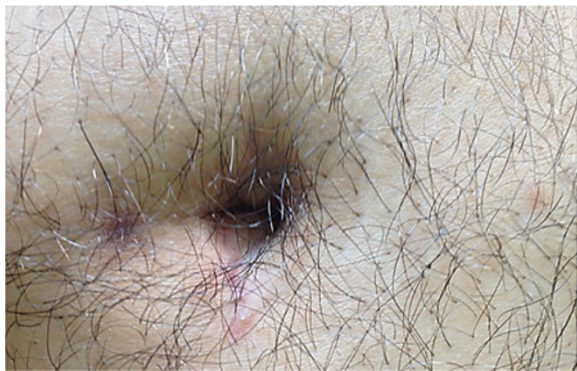
Varicocele is considered one of the most important causes of male infertility and prepubertal testicular hypotrophy. The most common indications for varicocelectomy are subfertility and chronic orchialgia [10,11]. Many clinical trials report a beneficial effect of varicocele repair on male reproduction with improvement in semen parameters, but some show the contrary [12].

The ideal method of varicocele treatment is a controversial issue. Several methods have been used, including open surgical ligation of the spermatic vein, retrograde or antegrade sclerotherapy, and laparoscopic

**Table 3** Results

	LESS varicoselectomy	Convention laparoscopic varicocelectomy
Number of patients	10	14
Mean operative time	45.4 minutes	88.3 minutes
Mean blood loss	< 30 ml	< 30 ml
Mean hospital stay	16.6 hours	51.4 hours
Postoperative analgesia	0	5 patients
Mean time return to work	2.3 days	4.7 days
Technique	Non selective	5 patients: selective 9 patients: non-selective
Complications	No	2 patients





**Figure 5** Postoperative umbilical scar.

and microsurgical varicocelectomy. Each technique has advantages and disadvantages, and conflicting results have been achieved in different studies [13].

The role of laparoscopic varicocelectomy is still controversial. According to our experience, the laparoscopic approach should be considered mostly in patients requiring bilateral varicocelectomy, since it appears to be a sensible alternative to 2 groin incisions. Also laparoscopic approach has short operative time and offers an easier postoperative course.

LESS has been developed in an attempt to further reduce the multiple ports morbidities and scarring associated with laparoscopic surgery [8]. In many studies, LESS varicocelectomy was reported to have acceptable feasibility, high patient satisfaction, and good postoperative outcomes [8,9,14-16]. Our study is in correspondence with these previous studies. It demonstrates that bilateral LESS varicocele ligation provides the best results comparison with those of the conventional laparoscopic technique.

The mean operative time was shorter in LESS group than in conventional laparoscopic group (45.4 minutes vs 88.3 minutes). The longer operative time in conventional laparoscopy group may be related to multiple numbers of access and performance of selective varicocelectomy in 5 of these patients. Dong Hyuk Kang et al., compared postoperative outcomes in patients treated with selective and non-selective LESS varicocele ligation. Mean operative time in non-selective group was similar to ours (48.6 minutes) while the mean operative time of selective group is shorter than that we found in conventional laparoscopy (60.7 minutes) [17]. This finding clarifies that the longer operative time in conventional laparoscopy may be related principally to multiple numbers of access.

The benefits of minimally invasive surgery are well recognized and include shorter length of stay, less analgesic requirement, faster convalescence, and better cosmetic outcomes. LESS is emerged to encounter these

advantages. Our study showed that hospital stay and return to work were shorter in LESS group (16.6 hours vs 51.4 hours and 2.3 days vs 4.7 days respectively).

We used an optical trocar to do transperitoneal access in the first five cases but, we found that it makes a false subcutaneous plain, as it has a smooth end and the subcutaneous fascia at the umbilicus is tough. This optical trocar technique prolonged operative time, and as a result we decided to directly perform open access to enter the abdominal cavity in the remaining five cases.

In our experience, using Covidien SILS™ Port gives many advantages. It is an excellent device that can be handled easily. It is composed of two parts, a sponge cork and three trocars. The sponge cork will seal the skin incision and the trocars prevent CO<sub>2</sub> leakage which is considered as an advantage over a gel port, which usually leaks. The optic with which we have obtained the best results is the 5-mm flexible laparoscope EndoEye camera system (Olympus Medical). This device provides flexibility and better working conditions [8]. In our experience we placed the instruments on different levels in the space with camera; with this expedient, the contact or clashing of instruments and the camera during LESS can be avoided.

Using transumbilical access, in LESS varicocelectomy, which is a pre-existing scar has potential better cosmetic outcomes and patient's satisfaction. Also, it allows for bilateral en bloc ligation of the spermatic cord through the same access.

All patients underwent LESS vaicocelectomy showed better cosmetic outcomes and were very satisfied while 85.7% of patients underwent conventional laparoscopy were very satisfied by cosmetic outcomes.

All patients who underwent LESS varicocelectomy in our study did not need postoperative analgesia while postoperative NSAIDs were used in 35.7% of patients underwent conventional laparoscopy. This corresponds with the results of Xue et al. who performed a prospective, randomized study comparing LESS with conventional laparoscopic varicocele ligation. They reported that the visual analog scale (VAS) pain score was significantly lower 6 and 24 hours after surgery in patients who underwent LESS [8].

Our principle is en bloc ligation of the spermatic cord proximal to the internal inguinal ring via LESS technique for treatment of patients with varicocele to preserve the distal gonadal artery flow via collaterals from the proximal deferential artery. The effect of artery preserving varicocele ligation is still controversial, as the testicles receive arterial supply mainly from the testicular artery, supplemented by the cremasteric and vasal arteries [18].

The division of the spermatic vessels for difficult orchiopey was suggested by Bevan in 1903. Later, Fowler

and Stephens described the anatomy that allowed division of the spermatic vessels to gain additional length and bring the testis to the scrotum while maintaining collateral blood supply [19,20]. Yamamoto et al. compared the two surgical methods and found no significant difference between testicular artery preservation and ligation varicocelectomy regarding semen quality, pregnancy rates, or testicular volume [21].

The retroperitoneal en bloc high ligation of a varicocele has the advantage of a lower incidence of recurrence due to ligation of the entire spermatic cord, including the artery and periarterial plexus of fine veins (venae comitantes), which may present as the source of recurrence [22].

The results of these studies correspond with our results. All patients included in both groups performed scrotal Doppler US at 3, 6, and 12 months and showed no recurrence of varicocele, no postoperative testicular atrophy nor secondary hydrocele.

In contrast, Zampieri et al. found that those with artery-sparing had better postoperative semen parameters than those who had undergone en bloc ligation that included the artery [23]. Raman and Goldstein also recommended preserving the testicular arteries for optimal testicular blood flow. However, prior series have revealed increased recurrence using the artery sparing method vs. taking the artery and veins [24,25].

The limitations of our study are the relatively small number of patients. Large randomized prospective trials are required.

## Conclusions

LESS is an effective technique for various urology indications. LESS en bloc bilateral spermatic cord ligation is safe, effective, and showed good results in terms of intraoperative outcomes, postoperative improvement in pain and semen parameters, and patient satisfaction, with no major complications. Minimal hospitalization requirement following LESS spermatic cord ligation is an additional timely advantage over conventional laparoscopic and open surgeries.

## Abbreviations

VAS: Visual analog scale; LESS: Laparo endoscopic single site surgery.

## Competing interest

All authors declare that they have no competing interest.

## Authors' contributions

EM and AG had full access to all the data in the study and take responsibility for the integrity of the data and the accuracy of the data analysis. SM, AG, and EM participated in study concept and design. AG and EM participated in acquisition of data. AG and EM participated in analysis and interpretation of data. AG, and EM participated in drafting of the manuscript. SM and GB participated in critical revision of the manuscript for important intellectual content. EM, and AG participated in statistical analysis. SM, EM, AZ, AT participated in administrative, technical, or material support. GB and SM participated in supervision of the manuscript. All authors read and approved the final manuscript.

## Author details

<sup>1</sup>Department of Urology, University of Modena & Reggio Emilia, Via del Pozzo, 71, Modena 41124, Italy. <sup>2</sup>Department of Urology, Tanta University, Tanta, Egypt.

Received: 3 October 2013 Accepted: 15 October 2014

Published: 23 October 2014

## References

1. Witt MA, Lipshultz LI: **Varicocele: a progressive or static lesion?** *Urology* 1993, **42**:541.
2. Naughton CK, Nangia AK, Agarwal A: **Pathophysiology of varicoceles in male infertility.** *Hum Reprod Update* 2001, **7**:473.
3. French DB, Desai NR, Agarwal A: **Varicocele repair: does it still have a role in infertility treatment?** *Curr Opin Obstet Gynecol* 2008, **20**:269.
4. Mohammed A, Chinegwundoh F: **Testicular varicocele: an overview.** *Urol Int* 2009, **82**:373.
5. Glassberg KI, Poon SA, Gjertson CK, DeCastro GJ, Misseri R: **Laparoscopic lymphatic sparing varicocelectomy in adolescents.** *J Urol* 2008, **180**:326–331.
6. Kocvara R, Dvoráček J, Sedláček J, Díte Z, Novák K: **Lymphatic sparing laparoscopic varicocelectomy: a microsurgical repair.** *J Urol* 2005, **173**:1751–1754.
7. Gill IS, Advincula AP, Aron M, Cadeddu J, Canes D, Curcillo PG 2nd, Desai MM, Evanko JC, Falcone T, Fazio V, Gettman M, Gumbs AA, Haber GP, Kaouk JH, Kim F, King SA, Ponsky J, Remzi F, Rivas H, Rosemurgy A, Ross S, Schauer P, Sotelo R, Speranza J, Sweeney J, Teixeira J: **Consensus statement of the consortium for laparoendoscopic single-site surgery.** *Surg Endosc* 2010, **24**:762–768.
8. Autorino R, Cadeddu JA, Desai MM, Gettman M, Gill IS, Kavoussi LR, Lima EL, Montorsi F, Richstone L, Stolzenburg JU, Kaouk JH: **Laparoendoscopic single-site and natural orifice transluminal endoscopic surgery in urology: a critical analysis of the literature.** *Eur Urol* 2011, **59**:26–45.
9. Kaouk JH, Palmer JS: **Single-port laparoscopic surgery. Initial experience in children for varicocelectomy.** *BJU Int* 2008, **102**:97–99.
10. Cadeddu JA, Bishoff JT, Chan DY, Moore RG, Kavoussi LR, Jarrett TW: **Laparoendoscopic testicular denervation for chronic orchalgia.** *J Urol* 1999, **162**:733–735.
11. Brooks JD, Moore RG, Kavoussi LR: **Laparoscopic management of testicular pain after embolotherapy of varicocele.** *J Endourol* 1994, **8**(5):361–363.
12. Schauer I, Madersbacher S, Jost R, Hübner WA, Martin I: **The impact of varicocelectomy on sperm parameters: a meta-analysis.** *J Urol* 2011, **187**:1540–1547.
13. Al-Said S, Al-Naimi A, Al-Ansari A, Younis N, Shamsodini A, A-sadiq K, Shokeir AA: **Varicocelectomy for male infertility: a comparative study of open, laparoscopic and microsurgical approaches.** *J Urol* 2008, **180**:266–270.
14. Kaouk JH, Autorino R, Kim FJ, Han DH, Lee SW, Yinghao S, Cadeddu JA, Derweesh IH, Richstone L, Cindolo L, Branco A, Greco F, Allaf M, Sotelo R, Liatsikos E, Stolzenburg JU, Rane A, White WM, Han WK, Haber GP, White MA, Molina WR, Jeong BC, Lee JY, Linhui W, Best S, Stroup SP, Rais-Bahrami S, Schips L, Fornara P, et al: **Laparoendoscopic single-site surgery in urology: worldwide multi-institutional analysis of 1076 cases.** *Eur Urol* 2011, **60**:998.
15. White WM, Haber GP, Goel RK, Crouzet S, Stein RJ, Kaouk JH: **Single-port urological surgery: single-center experience with the first 100 cases.** *Urology* 2009, **74**:801.
16. Lee SW, Lee JY, Kim KH, Ha US: **Laparoendoscopic single-site surgery versus conventional laparoscopic varicocele ligation in men with palpable varicocele: a randomized, clinical study.** *Surg Endosc* 2012, **26**:1056.
17. Kang DH, Lee JY, Chung JH, Jo JK, Lee SH, Ham WS, Cho KS, Kim TH, Lee SW: **Laparoendoscopic single site varicocele ligation: comparison of testicular artery and lymphatic preservation versus complete testicular vessel ligation.** *J Urol* 2013, **243**:249.
18. Mostafa T, Labib I, El-Khayat Y, El-Rahman El-Shahat A, Gadallah A: **Human testicular arterial supply: gross anatomy, corrosion cast, and radiologic study.** *Fertil Steril* 2008, **90**:2226.
19. Bevan AD: **The surgical treatment of undescended testis: a further contribution.** *JAMA* 1903, **41**:718.
20. Fowler R, Stephens FD: **The role of testicular vascular anatomy in the salvage of high undescended testis.** *Aust New Zeal J Surg* 1959, **29**:92.
21. Yamamoto M, Tsuji Y, Ohmura M, Hibi H, Miyake K: **Comparison of artery-ligating and artery-reserving varicocelectomy: effect on post-operative spermatogenesis.** *Andrologia* 1995, **27**:37.

22. Hopps CV, Goldstein M: **Varicocele. Unified theory of pathophysiology and treatment.** *AUA Update Series* 2004, **23**:12.
23. Zampieri N, Zuin V, Corroppo M, Chironi C, Cervellione RM, Camoglio FS: **Varicocele and adolescents: semen quality after 2 different laparoscopic procedures.** *J Androl* 2007, **28**:727.
24. Raman JD, Goldstein M: **Intraoperative characterization of arterial vasculature in spermatic cord.** *Urology* 2004, **64**:561.
25. Kass EJ, Marcol B: **Results of varicocele surgery in adolescents: a comparison of techniques.** *J Urol* 1992, **148**:694.

doi:10.1186/1471-2490-14-83

**Cite this article as:** Micali *et al.*: Bilateral spermatic cord en bloc ligation by laparoendoscopic single-site surgery: preliminary experience compared to conventional laparoscopy. *BMC Urology* 2014 **14**:83.

**Submit your next manuscript to BioMed Central  
and take full advantage of:**

- Convenient online submission
- Thorough peer review
- No space constraints or color figure charges
- Immediate publication on acceptance
- Inclusion in PubMed, CAS, Scopus and Google Scholar
- Research which is freely available for redistribution

Submit your manuscript at  
[www.biomedcentral.com/submit](http://www.biomedcentral.com/submit)

