

Poster presentation

Assesment of cardiac volumes in children with congenital heart disease using a 3D dual cardiac phase technique and a new segmentation tool

Tarique Hussain*¹, Hannah Bellsham-Revell¹, Sergio Uribe², Aaron Bell¹, Reza Razavi¹, Phillip Beerbaum¹, Isra Valverde¹, Tobias Schaeffter¹ and Gerald Greil¹

Address: ¹King's College London, London, UK and ²Pontificia Universidad Catolica de Chile, Santiago, Chile

* Corresponding author

from 13th Annual SCMR Scientific Sessions
Phoenix, AZ, USA. 21-24 January 2010

Published: 21 January 2010

Journal of Cardiovascular Magnetic Resonance 2010, **12**(Suppl 1):P2 doi:10.1186/1532-429X-12-S1-P2

This abstract is available from: <http://jcmr-online.com/content/12/S1/P2>

© 2010 Hussain et al; licensee BioMed Central Ltd.

Introduction

For children with complex congenital heart disease (CHD), the decision regarding univentricular or biventricular surgical repair may depend on accurate ventricular volume assessment. We have previously shown that three-dimensional (3d) whole-heart imaging acquired during end-systole and end-diastole (dual-phase) during one free-breathing MRI examination, when combined with semi-automatic analysis, may be more reproducible in calculating ventricular volumes than standard techniques (Uribe et al, 2008). We describe here, for the first time, use of 3d dual-phase imaging in children with complex CHD.

Purpose

To show 3d dual-phase imaging is feasible in children with complex CHD despite high heart rates.

Methods

The dual-phase sequence was used alongside standard 2d multi-slice cine in ten children with complex CHD (table 1). Analysis required a new semi-automatic segmentation tool which incorporates multiplanar reformatting and volume rendering to identify ventricular boundaries (ViewForum, Philips Healthcare, Figure 1). Two observers independently assessed end-diastolic and end-systolic ventricular volumes using both standard 2d cine with manual segmentation and new 3d dual-phase with semi-

automatic segmentation. If applicable, stroke volumes obtained were compared to phase contrast results. Bland-Altman was used to assess agreement and Pearson's coefficient for correlation.

Results

The mean age was 3 yrs (range 3 months-9 yrs) and heart rate range was 58-139 bpm. Volumetric analysis was feasible in all cases. Inter- and Intra-observer variability was similar for both methods. For 2d cine, acquired resolution was 1.8 mm × 1.8 mm; slice thickness 5 to 6 mm & temporal resolution 30 ms (20-40 phases). For 3d dual-phase, acquired resolution was 1.3 mm isotropic & temporal resolution 60 ms (2 phases). Bland-Altman (Figure 2A (systole), 2B (diastole)) showed excellent agreement between standard 2d cine and 3d dual-phase analyses (also, correlation 0.96(systole) and 0.93(diastole)). Similarly, Bland Altman for phase contrast stroke volume showed slightly better agreement with 3d dual-phase (Figure 2C) than with standard 2d cine (Figure 2D) (correlation 0.90 and 0.88 respectively).

Table 1: Patient diagnoses

Diagnosis	Which Ventricle Segmented	Number of Patients with given diagnosis
Repaired Pulmonary Atresia, VSD, Major Aorto-Pulmonary Collaterals with severely dilated RV	RV	2
Hypoplastic Left Heart Syndrome; Status Post Glenn Procedure	RV	1
Hypoplastic Left Heart Syndrome; Status Post Norwood Procedure	RV	1
Left Atrial Isomerism, Univentricular AV connection, Solitary RV, Aortic Atresia, Dextrocardia, Azygous continuation. Status Post Norwood	RV	1
Transposition of Great Arteries, VSD, Pulmonary Stenosis, Dextrocardia, Status Post Rastelli Procedure	RV	1
Situs Solitus, AV concordance, VA discordance, Dextrocardia, Unbalanced AVSD with Rudimentary Left Ventricle, Status Post Glenn	RV	1
Situs Solitus, AV concordance, Pulmonary Atresia with Aorta from RV, Unbalanced AVSD with Rudimentary Left Ventricle, Status Post Modified Blalock-Thomas-Taussig shunt	RV	1
Unrepaired Tetralogy of Fallot, with Major Aorto-Pulmonary Collaterals.	RV	1
Double Inlet Left Ventricle, Pulmonary Atresia, Status Post Glenn Procedure	LV	1

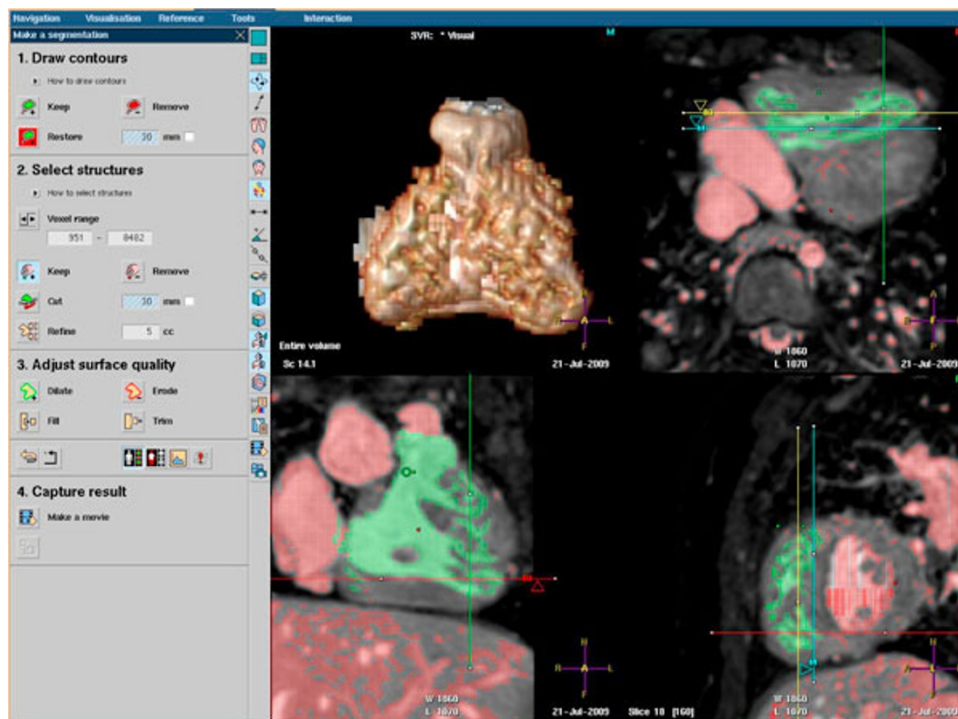


Figure 1

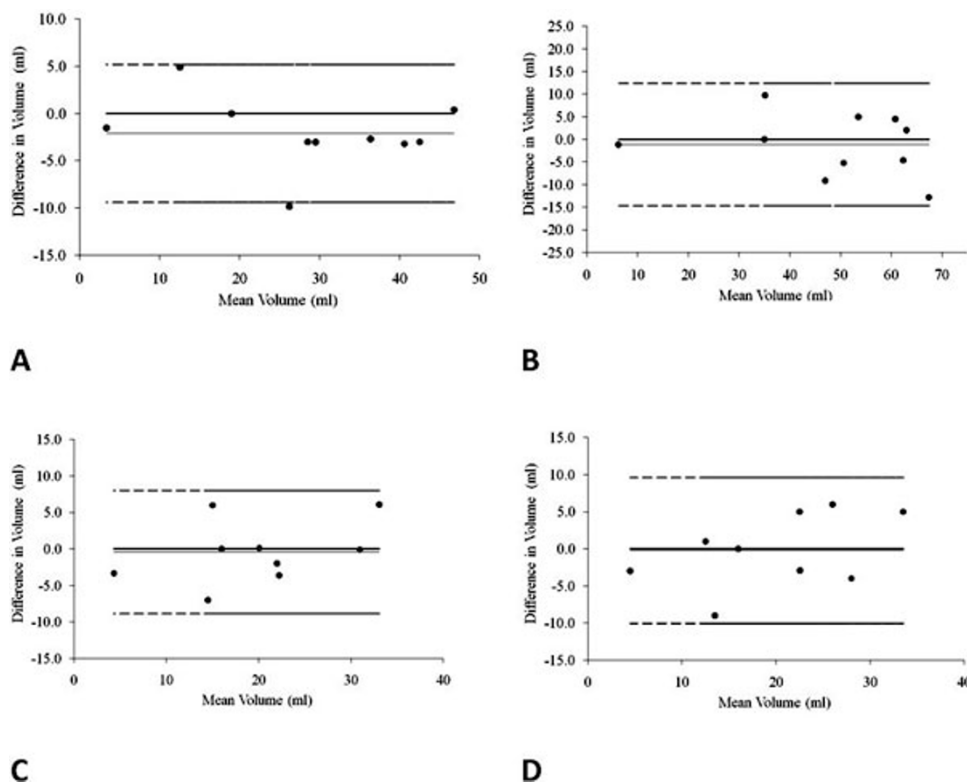


Figure 2

Conclusion

Standard ventricular analysis involves manual segmentation of cross-sectional cine images acquired over several breath-holds. This can have problems with slice misalignment. Furthermore, lack of isotropic resolution (by using thick slices which move during the cardiac cycle) makes definition of atrio-ventricular & ventriculo-arterial boundaries difficult. Therefore, acquisition and segmentation relies on operator experience. We believe that 3d dual-phase imaging with semi-automatic analysis overcomes these issues. This study demonstrates that 3d dual-phase imaging can successfully be performed even in very young children with complex CHD. Reliable and valid volumetric analysis was possible using the new semi-automatic segmentation technique.

Publish with **BioMed Central** and every scientist can read your work free of charge

"BioMed Central will be the most significant development for disseminating the results of biomedical research in our lifetime."

Sir Paul Nurse, Cancer Research UK

Your research papers will be:

- available free of charge to the entire biomedical community
- peer reviewed and published immediately upon acceptance
- cited in PubMed and archived on PubMed Central
- yours — you keep the copyright

Submit your manuscript here:
http://www.biomedcentral.com/info/publishing_adv.asp