




# REVISTA BRASILEIRA DE ANESTESIOLOGIA

Official Publication of the Brazilian Society of Anesthesiology  
[www.sba.com.br](http://www.sba.com.br)



## CLINICAL INFORMATION

# Intraventricular hemorrhage after dural fistula embolization

Joana Chaves Gonçalves Rodrigues de Carvalho<sup>a</sup>, Francisco Javier Tercero Machin<sup>b</sup>,  
Luis San Roman Manzanera<sup>c</sup>, Jordi Blasco Andaluz<sup>c</sup>, Sílvia Herrero Nogués<sup>d</sup>,  
Núria Peix Soriano<sup>d</sup>, Victor Obach Baurier<sup>e</sup>, Enrique Jesus Carrero Cardenal<sup>b,\*</sup>

<sup>a</sup> Anesthesiology Department, Unidade Local de Saúde de Matosinhos – Hospital Pedro Hispano, Matosinhos, Portugal

<sup>b</sup> Anesthesiology Department, Hospital Clínic, University of Barcelona, Barcelona, Spain

<sup>c</sup> Interventional Neuroradiology Department (CDI), Hospital Clínic, University of Barcelona, Barcelona, Spain

<sup>d</sup> Postanesthesia Care Unit, Hospital Clínic, University of Barcelona, Barcelona, Spain

<sup>e</sup> Neurology Department, Hospital Clínic, University of Barcelona, Barcelona, Spain

Received 1 June 2014; accepted 7 July 2014

### KEYWORDS

Intraventricular hemorrhage;  
Arteriovenous malformation;  
Dural fistula;  
Cerebral perfusion;  
Cerebral oximetry

### Abstract

**Background and objectives:** Dural arteriovenous fistulas are anomalous shunts between dural arterial and venous channels whose nidus is located between the dural leaflets. For those circumstances when invasive treatment is mandatory, endovascular techniques have grown to become the mainstay of practice, choice attributable to their reported safety and effectiveness. We describe the unique and rare case of a dural arteriovenous fistula treated by transarterial embolization and complicated by an intraventricular hemorrhage. We aim to emphasize some central aspects of the perioperative management of these patients in order to help improving the future approach of similar cases.

**Case report:** A 59-year-old woman with a previously diagnosed Cognard Type IV dural arteriovenous fistula presented for transarterial embolization, performed outside the operating room, under total intravenous anesthesia. The procedure underwent without complications and the intraoperative angiography revealed complete obliteration of the fistula. In the early postoperative period, the patient presented with clinical signs of raised intracranial pressure attributable to a later diagnosed intraventricular hemorrhage, which conditioned placement of a ventricular drain, admission to an intensive care unit, cerebral vasospasm and a prolonged hospital stay. Throughout the perioperative period, there were no changes in the cerebral brain oximetry. The patient was discharged without neurological sequelae.

\* Corresponding author.

E-mail: [ecarrero@clinic.ub.es](mailto:ecarrero@clinic.ub.es) (E.J. Carrero Cardenal).

## PALAVRAS-CHAVE

Hemorragia intraventricular;  
Malformação arteriovenosa;  
Fístula dural;  
Perfusão cerebral;  
Oximetria cerebral

**Conclusion:** Intraventricular hemorrhage may be a serious complication after the endovascular treatment of dural arteriovenous fistula. A close postoperative surveillance and monitoring allow an early diagnosis and treatment which increases the odds for an improved outcome.

© 2014 Sociedade Brasileira de Anestesiologia. Published by Elsevier Editora Ltda. All rights reserved.

## Hemorragia intraventricular após embolização de fístula dural

### Resumo

**Justificativa e objetivos:** Fístulas arteriovenosas durais (FAVD) são comunicações anômalas entre os canais venosos e arteriais da dura-máter cujo centro está localizado entre os folhetos da dura-máter. Para as circunstâncias nas quais o tratamento invasivo é obrigatório, as técnicas endovasculares se tornaram os pilares da prática, escolha atribuível a relatos de sua segurança e eficácia. Descrevemos o caso único e raro de uma FAVD tratada por embolização transarterial (ETA) e complicada por uma hemorragia intraventricular (HIV). Nosso objetivo foi destacar alguns aspectos centrais do manejo perioperatório desses pacientes para ajudar a melhorar uma futura abordagem de casos semelhantes.

**Relato de caso:** Paciente do sexo feminino, 59 anos de idade, com diagnóstico prévio de FAVD tipo IV (Cognard), apresentou-se para ETA, realizada fora da sala de cirurgia sob anestesia venosa total. O procedimento transcorreu sem complicações, e a angiografia intraoperatória revelou obliteração completa da fístula. No período pós-operatório imediato, a paciente apresentou sinais clínicos de aumento da pressão intracraniana (PIC) atribuíveis a uma HIV posteriormente diagnosticada, o que condicionou a colocação de um dreno ventricular, internação em Unidade de Terapia Intensiva (UTI), vasoespasma cerebral e internação hospitalar prolongada. Durante todo o período perioperatório, não houve alterações na oximetria cerebral. A paciente recebeu alta sem sequelas neurológicas.

**Conclusão:** HIV pode ser uma complicação grave após o tratamento endovascular de FAVD. A observação e monitoramento cuidadosos no pós-operatório permitem o diagnóstico precoce e o tratamento que aumenta as chances de um resultado melhor.

© 2014 Sociedade Brasileira de Anestesiologia. Publicado por Elsevier Editora Ltda. Todos os direitos reservados.

## Introduction

Ten to fifteen percent of all intracranial vascular malformations are dural fistulas (DVAf) which represent anomalous shunts among arterial branches and dural venous sinuses, meningeal or cortical veins.<sup>1-4</sup> Depending on their pattern of cortical drainage, some DAVF may present a high risk of hemorrhage, and therefore should be promptly sealed.<sup>3</sup> In the last 20 years, endovascular therapies have become the cornerstone of treatment for DVAf.<sup>3</sup> Nevertheless, they are not innocuous and patients should be closely and continuously monitored for the appearance of complications.

We report the case of a patient who developed an intraventricular hemorrhage (IVH) and acute hydrocephalus in the postoperative period of a DAVF embolization.

## Case report

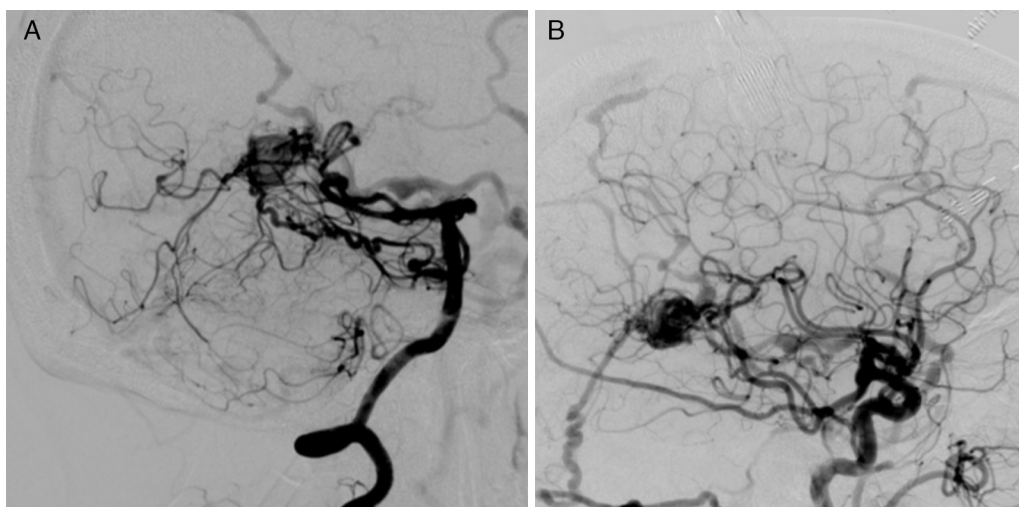
Female, 59 years old, 86 kg, BMI 32 kg m<sup>-2</sup>, ASA III, with a personal history of arterial hypertension, hypothyroidism and atrial fibrillation. In November 2013 she had been submitted to left atrial appendage closure after which she was

on double antiplatelet therapy with clopidogrel and aspirin for three months.

On March 2014 she was proposed for transarterial embolization (TAE) of a DAVF located at the torcula, classified as Cognard Type IV (Fig. 1), after a first endovascular procedure that did not achieve complete obliteration.

At the pre-anesthetic evaluation the patient did not present any focalizing neurological sign. She was currently medicated with digoxin, atenolol, enalapril and acetylsalicylic acid. Both the laboratory data and complementary exams were normal for age.

On the morning of the intervention the patient presented with a Glasgow Coma Score (GCS) of 15. After performance of a summary neurologic exam that once again showed no deficits she was premedicated with midazolam 1 mg intravenous (iv). Monitoring consisted of electrocardiogram (DII and V<sub>5</sub>), pulse oximetry, end tidal carbon dioxide, invasive blood pressure, central venous pressure, peripheral nerve stimulator, urinary output, Bispectral Index (BIS) (BIS<sup>TM</sup>, Brain Function Monitoring System, Covidien, Boulder, USA) and Near-infrared Spectroscopy (NIRS) (INVOS-4100, Cerebral Oximeter, Covidien, Mansfield, MA, USA). Basal NIRS values were 62 (right hemisphere) and 75 (left hemisphere).



**Figure 1** Torcular DAVF. Injection of the right vertebral artery (A) and right carotid artery (B) in a lateral view. The images show the arterial supply of the fistula arising from branches of the external carotid artery, occipital and middle meningeal arteries as well as from the posterior cerebral and superior cerebellar arteries. The patient showed venous sinus thrombosis as a probable cause for fistula development. The torcular DAVF, with its cortical venous drainage pattern, was graded as Cognard Type IV.

After preoxygenation, anesthesia was induced using a Targeted Controlled Infusion of propofol and remifentanyl and iv rocuronium ( $0.6 \text{ mg kg}^{-1}$  bolus followed by a perfusion). After insertion of a size 4 i-gel® laryngeal mask for airway control the patient was ventilated in volume-controlled mode adjusted for normocapnia, with a mixture of 50% oxygen in air and a positive end-expiratory pressure of  $5 \text{ cmH}_2\text{O}$ .

During anesthetic maintenance, perfusions were adjusted for the goals of BIS between 40–60 and train-of-four 0/4 with post-tetanic count +, as evaluated by the peripheral nerve stimulator. The concentrations at the effector site varied between  $1.5\text{--}2.0 \mu\text{g mL}^{-1}$  for propofol and  $2.0\text{--}2.5 \text{ ng mL}^{-1}$  for remifentanyl. Rocuronium was infused at a  $0.5 \text{ mg kg}^{-1} \text{ h}^{-1}$  rate.

The procedure consisted of complete DAVF TAE with ethylene-vinyl alcohol, formulated as Onyx®, and it underwent without ischemic or hemorrhagic incidents (Fig. 2). Through it all there were no other complications, the patient was hemodynamically stable and NIRS values did not vary more than 5% compared to basal.

Paracetamol 1 g and ondansetron 4 mg iv were administered for analgesia and postoperative nausea and vomiting prophylaxis, respectively. At the end of surgery neuromuscular blockade was reversed with sugammadex. When the patient was fully awake a new neurologic examination was executed and no new deficits were noted. She was then transferred to the Postanesthesia Care Unit (PACU) for overnight monitoring.

Shortly after admission the patient complained of pain on the femoral puncture site and was medicated with 2 mg of iv methadone. Two and a half hours later she developed a moderate hemicranial right headache accompanied with systemic hypertension (maximal systolic arterial pressure of 190 mmHg), two vomiting episodes and depressed level of consciousness (GCS = 13,  $\text{O}_3\text{V}_4\text{M}_6$ ). Repeated 5 mg iv urapidil boluses (30 mg total) were administered to control the

acute hypertension. NIRS values remained at 62–64 (right) and 72–76 (left).

An urgent computed tomography (CT) scan was performed showing an acute hydrocephalus, IVH and diffuse subarachnoid hemorrhage (Fig. 3A).

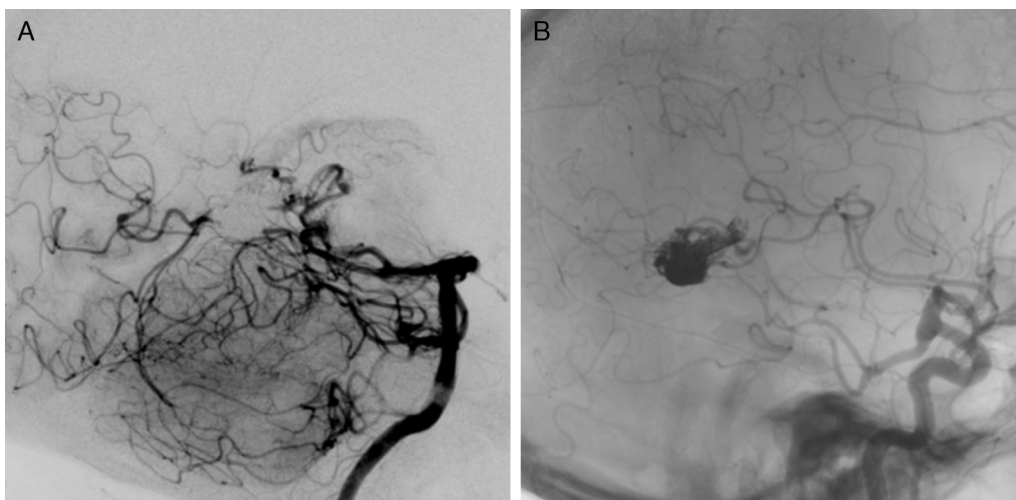
She was taken to the emergency operating room where a ventricular drainage system was placed (Fig. 3B) and later was admitted to the intensive care unit (ICU) sedated, intubated and ventilated. Extubation happened within the first 24 h postadmission and she was discharged to the general ward on the 3rd day.

On the following days a generalized and asymptomatic cerebral vasospasm was diagnosed by transcranial Doppler (TCD) but it slowly responded to therapy with the calcium-channel blocker agent nimodipine. The control CT scan showed IVH resolution but due to persistent dilation of the ventricular system the patient was scheduled for ventriculoperitoneal shunt insertion on the 22nd postoperative day. In the convalescence period from this second surgery, considering the patient's clinical and neurological stability as well as her arrhythmia history, antiplatelet therapy with aspirin was re-started. Since the recovery underwent without further incidents the patient was discharged home with no neurologic deficits one month after the endovascular embolization.

## Discussion

DAVF may represent a major source of neurological morbidity and mortality as a result of the occurrence of adverse clinical events like seizures, hemorrhage or steal phenomena.<sup>5</sup> The incidence of these complications is even higher for DAVF who have cortical venous drainage,<sup>6</sup> as in the case of our patient.

Over the past 20 years, DAVF surgery has become indicated only when endovascular therapies fail or are not



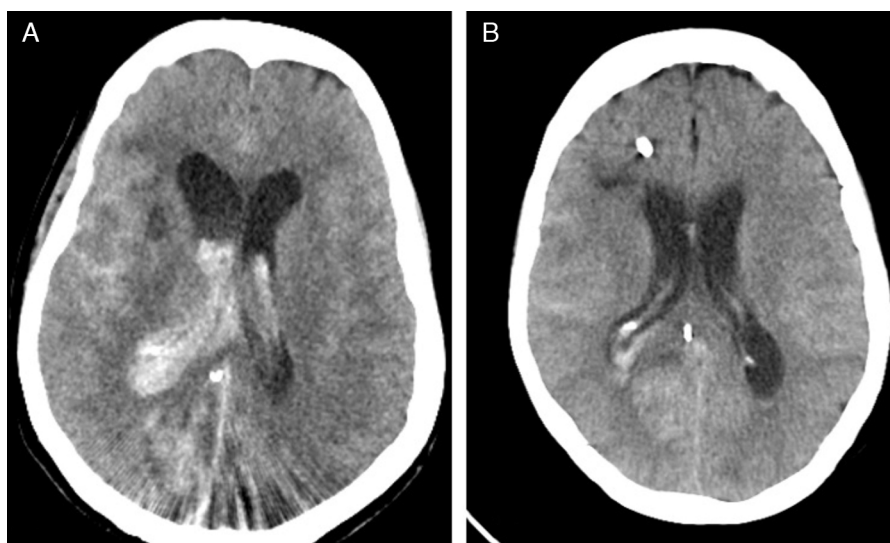
**Figure 2** Injections of the right vertebral artery (A) and right carotid (B) (lateral view), showing total fistula occlusion with the Onyx® cast.

practicable.<sup>3</sup> In reality DAVF embolization with Onyx®, a nonadhesive embolic agent composed by ethylene-vinyl alcohol dissolved in dimethyl-sulfoxide, has grown to become one of the major approaches to DAVF, which is intimately linked to its remarkable cure rates and low morbidity.<sup>3,5,6</sup> In fact, there are not many complications reported after these techniques. Maimon et al. describe a morbidity of 6% (1/17 patients) related to a transient trochlear nerve palsy and on a retrospective studied by Rangel-Castilla et al., the authors describe a complication rate of 9.7% (7 of 72 patients), of which only one corresponded to a intraparenchymal hemorrhage.<sup>5,6</sup>

After a systematic review of the international literature using the PubMed database, we were not able to find any article describing the occurrence of an IVH after DAVF embolization, which corroborates the relevance of this report.

Individuals medicated with the antiplatelet agent clopidogrel exhibit a wide variability in response that ranges from hypo-to-hyper responsiveness. When individuals are submitted to neurointerventional procedures, clopidogrel hyperresponsiveness seems to be associated with bleeding but the definitive clinical implications of these data are still under evaluation.<sup>7,8</sup> Although it is not known for how long this 'hyper' response can last, the fact that our patient had stopped the clopidogrel more than a month before the procedure leads us to believe that this was not the main factor behind the IVH, even though it could have played a role in its etiology.

Cerebral hyperperfusion syndrome (CHS), defined as an excessive increase in cerebral blood flow (CBF) into a previously hypoperfused area plus neurological symptoms, is a potentially life-threatening complication. It is caused by exhaustion of the cerebral autoregulation mechanisms



**Figure 3** Postprocedure computed tomography scan showing an intraventricular hemorrhage and hydrocephalus before (A) and after drainage (B).

(Normal Perfusion Pressure Breakthrough theory, NPPB)<sup>9</sup> and it can present with focal neurologic deficits, headache, confusion, seizures or intracerebral hemorrhage.<sup>10</sup> Although it has been widely reported after carotid endarterectomy (CEA)<sup>11,12</sup> and stenting,<sup>13</sup> it seems to be less common following interventions for arteriovenous malformations (AVMs).<sup>14</sup>

NIRS is a non-invasive and objective technology that continuously monitors regional oxygen saturation (rSO<sub>2</sub>). It is an early predictive marker for critical perfusion changes during endovascular neuroradiologic interventions.<sup>15</sup> Both Pennekamp et al. and Ogasawara et al. described the use of this technology as a mean to predict cerebral hyperperfusion, defined as a  $\geq 100\%$  increase in CBF from baseline value assessed with single-photon emission CT, after CEA.<sup>11,12</sup> Even though there are not clearly defined cut-off rSO<sub>2</sub> values for cerebral hyperperfusion, these authors showed that an increase as small as three to five percentage points with respect to basal values may detect cerebral hyperperfusion post-CEA with a high sensitivity and specificity (100% and 86.4%, respectively).<sup>11,12</sup> Both these parameters increase to 100% with cut-off points of 10% variation.<sup>12</sup> Whether the conclusions of these group studies can be extrapolated for neurointerventional procedures still needs to be established. Despite this lack of evidence, the stability of rSO<sub>2</sub> values made us consider phenomena other than CHS as the cause behind the patient's symptoms.

The urgent CT scan identified both the IVH and hydrocephalus and gave us a definitive diagnosis. The fact that the bleeding was restricted to the ventricular drainage system confirmed our arguments against the CHS. Young et al.<sup>16</sup> showed that increased CBF following cerebral AVM resection occurs throughout the entire brain, not just in regions that share the vascular supply with the malformation. In that case, rSO<sub>2</sub> values would have to have increased and that did not happen. NIRS technology does not reflect a global oxygen saturation.<sup>17</sup> If the probe is placed in the forehead, as in our patient, it is mainly monitoring both the frontal and parietal cerebral cortex and thus the territories irrigated by the anterior and middle cerebral arteries. This could explain why the rSO<sub>2</sub> did not increase after the IVH. Because the arterial branches supplying the DAVF arose from the posterior cerebral circulation, we cannot exclude that the NIRS monitor could be relatively "blind" to specific perfusion changes at these territories. On the other hand, the fact that the rSO<sub>2</sub> values did not decrease also suggests that the raised intracranial pressure (ICP), manifested as vomiting, headache and diminished level of consciousness, was compensated by the systemic arterial hypertension and did not lead to a lower cerebral perfusion pressure.

The development of vasospasm, as a response to the occurrence of IVH and SAH, is an indicative that the patient's cerebrovascular reactivity remained unaltered. This fact argues against the main principle underlying the NPPB theory of the CHS.<sup>9,18</sup>

After reviewing the case with the radiology team, it seems more likely that the hemorrhage was provoked by one of two causes: iatrogeny related to a microperforation while retrieving the microcatheter used for arterial cannulation or hyperpressure inside the DAVF after occlusion of its venous drainage, maybe secondary to an arterial branch that may have inadvertently persisted open.

As stated earlier, endovascular techniques have increased in popularity partly due to their high safety profile. Nevertheless, when anomalous events occur they may be severe and add morbidity, as we can infer from our patient's prolonged clinical course. This confirms that in the early postoperative period after AVM embolization individuals have an increased risk of neurological complications.

How can we further improve the neurologic outcome of these patients? In our opinion, this can be done by establishing the highest possible standards of care. Admission to a unit where a close follow-up can be carried on by a properly trained medical and nursing staff is crucial. Unlike uneventful unruptured aneurysm embolization,<sup>19</sup> complications after DAVF endovascular treatment may appear several hours postprocedure. For that reason and for assuring better surveillance of cerebral function, we believe that these patients should stay overnight in high dependency units, such as the PACU in our hospital.

A continuous and detailed clinical examination may swiftly detect a new neurologic deficit, a depressed level of consciousness or a change in the GCS, allowing a prompt diagnostic or therapeutic intervention that can ultimately result in an improved prognosis.<sup>20</sup> In some cases, neuromonitors like NIRS and TCD are able to detect cerebral disturbances even before symptoms become evident, identifying individuals at risk for ischemia<sup>21</sup> or cerebral hyperperfusion<sup>22</sup> after neurovascular techniques. In our case, the neurological symptoms were the key. NIRS helped us to guide the diagnosis and the TCD detected a late and asymptomatic vasospasm.

Not least important is monitoring the patient's vital signs, mainly arterial blood pressure. While we could not find data specifically focusing on DAVF, Basali et al. showed in their retrospective study that postoperative elevated arterial pressure is a correlate for intracerebral bleeding after craniotomy.<sup>23</sup> On the other hand, aggressive hypertension treatment decreases the risk of hyperperfusion and intracerebral hemorrhage following carotid artery stenting.<sup>13</sup> In our opinion this is also valid after DAVF embolization and so hypertension control was a common concern to all the elements involved in our case. Nevertheless, we think that the hypertension that our patient developed, more than a contributive factor to the hemorrhage, was a secondary manifestation of raised ICP.

After IVH it is common for patients to present with clinical findings of obstructive hydrocephalus, like depressed level of consciousness and vomiting, symptoms that our patient experienced. Even though there are reports of delayed and transient hydrocephalus that resolves spontaneously, when the clinical course is acute, like in our case, cerebrospinal fluid drainage should be promptly performed.<sup>24</sup>

When at the general ward of after hospital discharge it is important to keep a close surveillance of these individuals. This is true because non-occluded AVMs or fistulas with retrograde cortical drainage, like the one we here present, are at a high risk for early rebleeding. When this happens, consequences are more devastating than at a first episode.<sup>4</sup>

In summary, an IVH may be a serious complication after the endovascular treatment of a DAVF. A close postoperative surveillance and monitoring allow for an early diagnosis and treatment and thus a better outcome.

## Conflicts of interest

The authors declare no conflicts of interest.

## Acknowledgments

The authors thank Dr. Robert D. Ecker for providing the article "Hyperperfusion syndrome after stent/coiling of a ruptured carotid bifurcation aneurysm" (reference number 10).

## References

1. Ghobrial GM, Marchan E, Nair AK, et al. Dural arteriovenous fistulas: a review of the literature and a presentation of a single institution's experience. *World Neurosurg.* 2013;80:94–102.
2. Natarajan SK, Ghodke B, Kim LJ, et al. Multimodality treatment of intracranial dural arteriovenous fistulas in the onyx era: a single center experience. *World Neurosurg.* 2010;73:365–79.
3. Gandhi D, Chen J, Pearl M, et al. Intracranial dural arteriovenous fistulas: classification, imaging findings, and treatment. *Am J Neuroradiol.* 2012;33:1007–13.
4. Duffau H, Lopes M, Janosevic V, et al. Early rebleeding from intracranial dural arteriovenous fistulas: report of 20 cases and review of the literature. *J Neurosurg.* 1999;90:78–84.
5. Maimon S, Nossek E, Strauss I, et al. Transarterial treatment with onyx of intracranial dural arteriovenous fistula with cortical drainage in 17 patients. *Am J Neuroradiol.* 2011;32:2180–4.
6. Rangel-Castilla L, Barber SM, Klucznik R, et al. Mid and long term outcomes of dural arteriovenous fistula endovascular management with Onyx. Experience of a single tertiary center. *J Neurointerv Surg.* 2014;607–13.
7. Serebruany VL, Steinhubl SR, Berger PB, et al. Variability in platelet responsiveness to clopidogrel among 544 individuals. *J Am Coll Cardiol.* 2005;45:246–51.
8. Goh C, Churilov L, Mitchell P, et al. Clopidogrel hyper-response and bleeding risk in neurointerventional procedures. *Am J Neuroradiol.* 2013;34:721–6.
9. Spetzler RF, Wilson CB, Weinstein P, et al. Normal perfusion pressure breakthrough theory. *Clin Neurosurg.* 1978;25:651–72.
10. Ecker RD, Murray RD, Seder DB. Hyperperfusion syndrome after stent/coiling of a ruptured carotid bifurcation aneurysm. *Neurocrit Care.* 2013;18:54–8.
11. Pennekamp CWA, Immink RV, Ruijter HM, et al. Near-infrared spectroscopy can predict the onset of cerebral hyperperfusion syndrome after carotid endarterectomy. *Cerebrovasc Dis.* 2012;34:314–21.
12. Ogasawara K, Konno H, Yukawa H, et al. Transcranial regional cerebral oxygen saturation monitoring during carotid endarterectomy as a predictor of postoperative hyperperfusion. *Neurosurgery.* 2003;53:309–15.
13. Abou-Chebl A, Yadav JS, Reginelli JP, et al. Intracranial hemorrhage and hyperperfusion syndrome following carotid artery stenting: risk factors, prevention, and treatment. *J Am Coll Cardiol.* 2004;43:1596–601.
14. Picard L, Da Costa E, Anxionnat R, et al. Acute spontaneous hemorrhage after embolization of brain arteriovenous malformation with N-butyl cyanoacrylate. *J Neuroradiol.* 2001;28:147–65.
15. Rummel C, Zubler C, Schroth G, et al. Monitoring cerebral oxygenation during balloon occlusion with multichannel NIRS. *J Cereb Blood Flow Metab.* 2014;34:347–56.
16. Young WL, Kader A, Ornstein E, et al. Cerebral hyperemia after arteriovenous malformation resection is related to "breakthrough" complications but not to feeding artery pressure. The Columbia University Arteriovenous Malformation Study Project. *Neurosurgery.* 1996;38:1085–93.
17. Ghosh A, Elwell C, Smith M. Cerebral near-infrared spectroscopy in adults: a work in progress. *Anesth Analg.* 2012;115:1373–83.
18. Alexander MD, Connolly ES, Meyers PM. Revisiting normal perfusion pressure breakthrough in light of hemorrhage induced-vasospasm. *World J Radiol.* 2010;2:230–2.
19. Burrows AM, Rabinstein AA, Cloft HJ, et al. Are routine intensive care admissions needed after endovascular treatment of unruptured aneurysms? *Am J Neuroradiol.* 2013;34:2199–201.
20. Fabregas N, Bruder N. Recovery and neurological evaluation. *Best Pract Res Clin Anaesthesiol.* 2007;21:431–47.
21. Marshall SA, Nyquist P, Ziai WC. The role of transcranial Doppler ultrasonography in the diagnosis and management of vasospasm after aneurysmal subarachnoid hemorrhage. *Neurosurg Clin N Am.* 2010;21:291–303.
22. Pennekamp CW, Moll FL, De Borst GJ. Role of transcranial Doppler in cerebral hyperperfusion syndrome. *J Cardiovasc Surg (Torino).* 2012;53:765–71.
23. Basali A, Mascha EJ, Kalfas I. Relation between perioperative hypertension and intracranial hemorrhage after craniotomy. *Anesthesiology.* 2000;93:48–54.
24. Lulis EA, Vellimana AK, Ray WZ, et al. Transient obstructive hydrocephalus due to intraventricular hemorrhage: a case report and review of literature. *J Clin Neurol.* 2013;9:192–5.