

Oral presentation

Equilibrium contrast CMR for the measurement of diffuse myocardial fibrosisAndrew S Flett*¹, Martin Harward¹, Michael T Ashworth², Michael S Hansen², Andrew M Taylor², Shyam Kolvekar¹, John Yap¹, Perry Elliott¹, Christopher McGregor¹ and James C Moon¹Address: ¹The Heart Hospital, London, UK and ²Great Ormond Street Hospital, London, UK

* Corresponding author

from 13th Annual SCMR Scientific Sessions
Phoenix, AZ, USA. 21-24 January 2010

Published: 21 January 2010

Journal of Cardiovascular Magnetic Resonance 2010, **12**(Suppl 1):O16 doi:10.1186/1532-429X-12-S1-O16This abstract is available from: <http://jcmr-online.com/content/12/S1/O16>

© 2010 Flett et al; licensee BioMed Central Ltd.

Introduction

Diffuse myocardial fibrosis (DMF) is a final endpoint in most cardiac diseases. It is missed by the late gadolinium enhancement technique. Currently, the only method to quantify DMF is biopsy, which has risk and is prone to sampling error.

Purpose

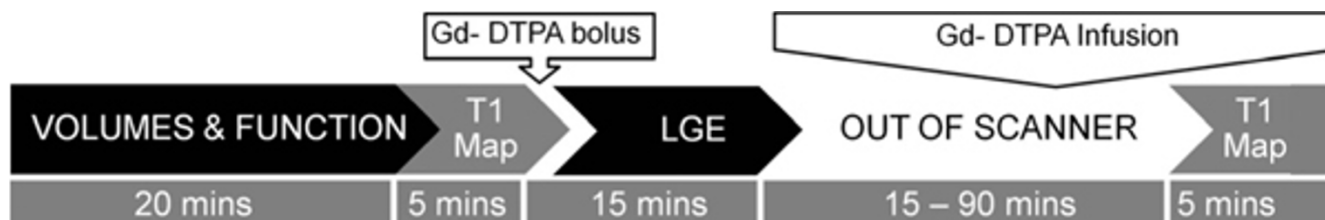
We have developed a new technique Equilibrium Contrast CMR (EQ-CMR) - the first clinically applicable, robust, noninvasive method to quantify DMF and show it to be accurate against the current gold-standard of surgical myocardial biopsy.

Methods

The three elements of EQ-CMR are: a bolus of extra-cellular Gd-DTPA contrast followed by continuous infusion to

achieve equilibrium; a blood sample to measure blood volume of distribution, $Vd_{(b)}$ (one minus haematocrit); and CMR to measure pre and post equilibrium T1 (with heart rate correction). $Vd_{(m)}$ is calculated, reflecting DMF.

Equilibrium acquisition was optimized in 16 individuals and achieved by a combination of loading bolus and slow continuous infusion. The T1 measurement technique and heart rate correction was validated in phantoms against T1 relaxometry and then against blood [Gd-DTPA]. Clinical validation was in patients undergoing AVR for AS or myectomy in HCM (n = 18 and 8 respectively). The surgical biopsies were analyzed using fully automated image analysis (macros in ImageJ) for picro-sirius red fibrosis quantification on histology. The scan protocol is outlined in Figure 1.

**Figure 1**

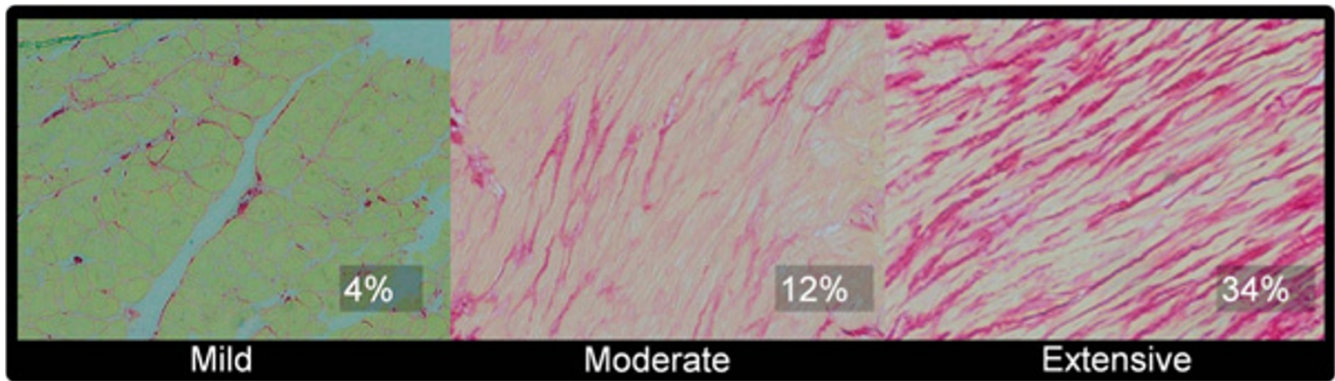


Figure 2

Results

Equilibrium was achieved in all patients within 40 minutes. The second scan took 5 mins ± 42 secs (9 breath-holds). The mean histological fibrosis was 20.5% ± 11% in AS and 17.1% ± 7.4 in HCM (Figure 2). The total Gd-DTPA dose was 0.14 ± 0.001 mmol/kg. EQ-CMR Vd_(m) correlated strongly with biopsy histological fibrosis: AS: r² = 0.86, p < 0.001; HCM: r² = 0.62, p < 0.02; combined r² = 0.80, p < 0.001 (Figure 3).

Conclusion

We have developed and validated a new technique, EQ-CMR to measure diffuse myocardial fibrosis. It is a simple, reliable and clinically.

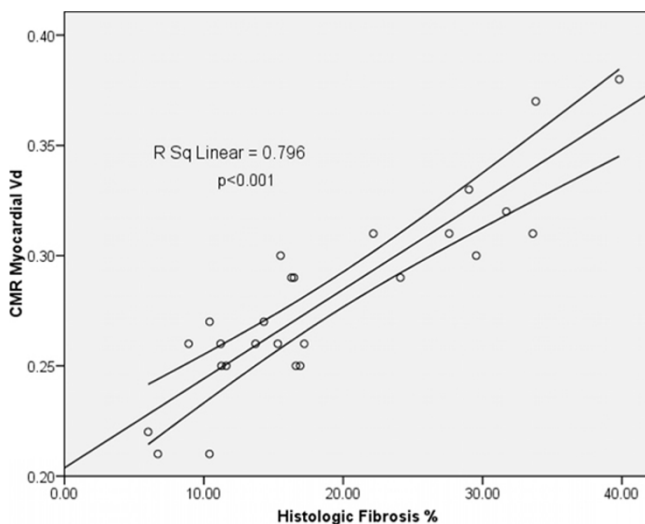


Figure 3

Publish with **BioMed Central** and every scientist can read your work free of charge

"BioMed Central will be the most significant development for disseminating the results of biomedical research in our lifetime."

Sir Paul Nurse, Cancer Research UK

Your research papers will be:

- available free of charge to the entire biomedical community
- peer reviewed and published immediately upon acceptance
- cited in PubMed and archived on PubMed Central
- yours — you keep the copyright

Submit your manuscript here:
http://www.biomedcentral.com/info/publishing_adv.asp