

Contents lists available at [ScienceDirect](http://ScienceDirect.com)

EBioMedicine

journal homepage: [www.ebiomedicine.com](http://www.ebiomedicine.com)

In Focus

## Surgical Approaches to the Lumbar Hidden Zone: Current Strategies and Future Directions



Clemens Reinshagen<sup>a,\*</sup>, Navid Redjal<sup>b</sup>, Marek Molcanyi<sup>c</sup>, Bernhard Rieger<sup>d</sup>

<sup>a</sup> Department of Radiology, Massachusetts General Hospital, Harvard Medical School, Boston, MA, USA

<sup>b</sup> Department of Neurosurgery, Massachusetts General Hospital, Harvard Medical School, Boston, MA, USA

<sup>c</sup> Institute of Neurophysiology, Medical Faculty, University of Cologne, Cologne, Germany

<sup>d</sup> Department of Neurosurgery, University of Dresden, Fetschersstraße 74, Dresden, Germany

The lateral lumbar spinal canal may be subdivided into the subarticular (lateral recess), the foraminal (pedicle) and the extraforaminal (far lateral) zone. Within these regions lies the “hidden zone”, an area known for its difficult surgical exposure (Fig. 1A) (Macnab, 1971). Common pathologies of this region include foraminal osseous stenosis (narrowing of the foramen through which the nerve root exits the spinal canal) as well as disc herniations. It has been estimated that roughly 10–20% of all disc herniations migrate in a cranio-lateral direction and may hence be located in the preforaminal and foraminal regions of the “hidden zone”. Due to the local anatomy, these lesions may affect both the traversing (level below) as well as the exiting (same level) nerve root. Patients typically present with neurological symptoms of (poly-)radiculopathy, including pain, weakness and numbness. Commonly, and in contrast to the above-mentioned zones, all types of disc herniations that affect the exiting nerve root at the same level are referred to as “far- or extreme-lateral”, including pre-, intra- and extra-foraminal herniations. Whilst a variety of effective techniques for approaching extraforaminal and purely intraforaminal lesions have been developed, there continues to be disagreement with regard to the optimal approach to lesions located in the pre- and intra-foraminal regions of the hidden zone.

In order to understand this discord, it is crucial to comprehend the difficulties and patient-specific concerns associated with the surgical exposure of this region. Anatomically, the medial hidden zone is an area bordered laterally by the pedicle, ventrally by the dorsal part of the vertebral body and covered dorsally by the pars interarticularis of the hemilamina (Fig. 1A). Open surgical exploration of this region via the traditional interlaminar route (Fig. 1B) is therefore only possible after at least partial removal of the ipsilateral hemilamina (extended laminotomy or even hemilaminectomy) and may additionally require partial or complete facetectomy (removal of the facet joint) (Schulz et al., 2014). Extended laminotomy as a means to approach the hidden zone has therefore lost popularity, since the associated removal of biomechanically important bony structures has been suggested to increase the risk of secondary segmental instability (Abumi et al., 1990) and may

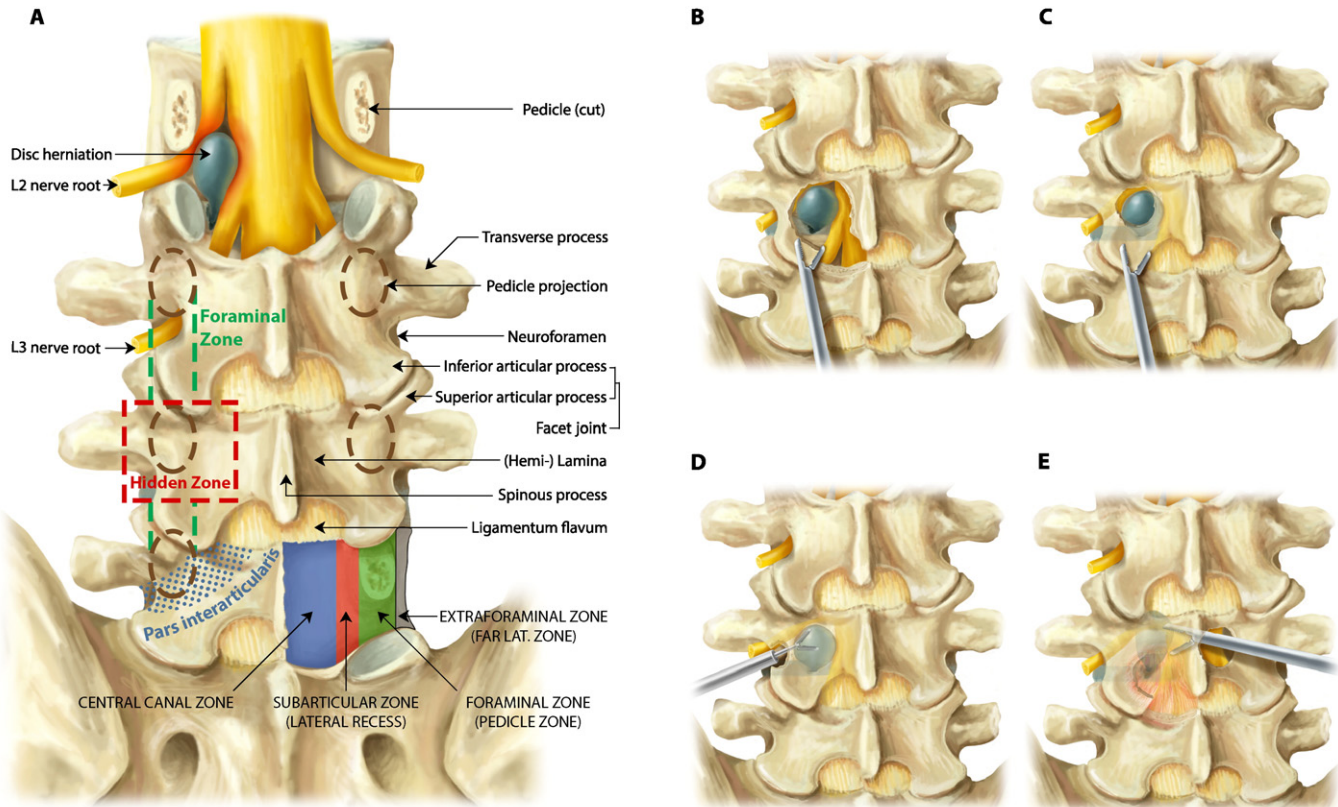
subsequently necessitate fusion surgery. Other, more lateral approaches have been suggested; however, these require specific anatomical knowledge, and offer inferior access to more medial spinal pathologies of the hidden zone.

In 1998, Di Lorenzo et al. (1998) proposed a less invasive direct procedure by utilizing a translaminar approach (TLA) through a fenestration of the pars interarticularis, thus circumventing facetectomy or hemilaminectomy in many cases (Fig. 1C). The increasing availability of high-definition imaging modalities (MRI, CT) has contributed to the growing popularity of the TLA, since identifying the exact location and extent of the spinal lesion is crucial for surgical planning to limit unnecessary biomechanical damage and prevent intraoperative conversion to conventional approaches. In recent years, several studies have demonstrated the feasibility, safety and efficacy of this technique to successfully treat disc herniations affecting the foraminal and preforaminal regions. Endoscopic approaches to the hidden zone have been suggested, including endoscopic transforaminal (Fig. 1D) or translaminar techniques (Schulz et al., 2014; Dezawa et al., 2012). However, whilst the endoscopic TLA might offer an incremental improvement with regard to trauma, transforaminal endoscopic procedures are not recommended for the more medial foraminal lesions of the hidden zone due to imposed spatial restrictions, especially in the lower lumbar levels. Consequently, endoscopic transforaminal approaches to these pathologies have been associated with increased operating times as well as higher complication and revision rates (Schulz et al., 2014; Lee et al., 2007).

Nevertheless, even though the TLA seems to be the method of choice to approach cranio-lateral disc herniations, some authors have argued that this technique also has its limitations. Due to segment-dependent changes of vertebral anatomy, Di Lorenzo's approach must be located very laterally in the more upper lumbar levels in order to reach the medial hidden zone. Disruption of the lateral hemilamina (pars interarticularis), however, has been linked to an increased risk of stress fracture and instability (Ivanov et al., 2007). This becomes more relevant as the relative risk of cranial disc sequestration increases significantly in higher lumbar levels and cranial sequestration is strongly correlated with increased age (Daghighi et al., 2014). Since older patients are also more likely to suffer from osteoporosis and degenerative spinal disorders such as facet joint hypertrophy, which may manifest segmental instability, less invasive medial approaches to the hidden zone are warranted.

★ The authors have no conflicts of interest, sources of financial support, or industry affiliations to disclose relevant to this article.

\* Corresponding author at: Department of Radiology, Massachusetts General Hospital, Building 149, Room 5404, Charlestown, MA 02129, USA.  
URL: [clemens.reinshagen@gmx.de](mailto:clemens.reinshagen@gmx.de) (C. Reinshagen).



**Fig. 1.** Lumbar anatomy and surgical approaches to the hidden zone. A) Overview of applied neurosurgical anatomy of the lumbar spine, depicting a representative cranio-lateral disc herniation affecting both the exiting L2 and the passing L3 nerve root. Besides the zones shown above, some authors further refer to the area that marks the entrance to the intraspinal part of the foraminal zone as the preforaminal region. B) Extended laminotomy: Technique that is based on conventional laminotomy, involving surgical flavectomy (removal of the ligamentum flavum that covers the intraspinal space) and (partial) hemilaminectomy. Extended laminotomy allows exposure of the intervertebral disc space, the nerve roots and the disc herniation in the hidden zone. However, excessive bone resection may lead to fracture of the cranial rest of the hemilamina and/or the medial facet joint thereby possibly paving the way to secondary segmental instability. C) Translaminar approach: A small fenestration located immediately over the site of the disc herniation enables direct removal of a cranio-lateral sequester, but limits surgical exposure of the intervertebral disc space. D) Endoscopic transforaminal approach: The cranio-lateral disc herniation is approached from outside the spinal canal through the neuroforamen. This approach may need additional widening of the neuroforamen (foraminoplasty) and has been associated with the risk of iatrogenic damage, as the endoscope must be placed in immediate proximity of the nerve root passing through the neuroforamen. E) Crossover translaminar approach: A small fenestration of the hemilamina, at the base of the spinous process, allows tangential access to the contralateral hidden zone. In patients who previously underwent conventional laminotomy, e.g. for a common postero-lateral disc herniation, this approach may prevent further bone resection (extended laminotomy) as well as operating directly through fibrous scar tissue. Besides its advantages in the recurrent setting, the cTLA naturally decompresses central stenosis and due to its angled trajectory allows excellent access and decompression of both the ipsi- and contralateral recess.

Recently, Reinshagen et al. (2015) suggested approaching cranio-lateral disc herniations via a crossover translaminar approach (cTLA), which utilizes a fenestration of the contralateral hemilamina at the base of the spinous process to reach the hidden zone (Fig. 1E). Besides avoiding disruption of the lateral half of the hemilamina, this facet-sparing technique might additionally offer advantages when treating recurrent patients who previously underwent extended laminotomy, as approaching the recurrent pathology from the contralateral side avoids additional ipsilateral bone resection. A minimally invasive technique, similar to that reported by Reinshagen et al., has been proposed by Alimi et al. (2014). Although not a translaminar approach, Alimi's technique also features a crossover route to the foraminal region and demonstrated good results for treating foraminal stenosis in a series of 32 patients.

The main limitation of both TLA and cTLA techniques is their restricted access to the intervertebral disc space, especially at lower lumbar levels. Although cranial disc herniations mostly appear as completely sequestered fragments, preoperative imaging and meticulous surgery planning is crucial in order to minimize reversion to conventional approaches. In the future, combining the TLA or cTLA with preoperative simulation software as well as intraoperative neuronavigation might prove helpful in further minimizing surgical tissue trauma when treating these challenging pathologies.

In conclusion, access to the hidden zone remains surgically challenging. However, with an increasing number of reliable techniques the

surgeon can now decide which procedure is the most appropriate for a patient's individual pathology. Furthermore, even though common sense implies that less bone disruption increases spinal stability, data on TLA and cTLA approaches still need to be supported by a large prospective randomized trial to assess the preservation of spinal stability and patient outcomes compared to conventional approaches.

#### Acknowledgements

All illustrations were created by Sebastian Zachar (artwork inquiries: [zachar.sebastian@gmail.com](mailto:zachar.sebastian@gmail.com)).

#### References

- Abumi, K., Panjabi, M.M., Kramer, K.M., Duranceau, J., Oxland, T., Crisco, J.J., 1990. Biomechanical evaluation of lumbar spinal stability after graded facetectomies. *Spine* 15 (11), 1142–1147.
- Alimi, M., Njoku, I., Cong, G.-T.T., Pyo, S.Y., Hofstetter, C.P., Grunert, P., et al., 2014. Minimally invasive foraminotomy through tubular retractors via a contralateral approach in patients with unilateral radiculopathy. *Neurosurgery* (10 Suppl 3), 436.
- Daghighi, M.H., Pouries, M., Maleki, M., Fouladi, D.F., Pezeshki, M.Z., Mazaheri Khameneh, R., et al., 2014. Migration patterns of herniated disc fragments: a study on 1,020 patients with extruded lumbar disc herniation. *Spine* J. 14 (9), 1970–1977.
- Dezawa, A., Mikami, H., Sairyo, K., 2012. Percutaneous endoscopic translaminar approach for herniated nucleus pulposus in the hidden zone of the lumbar spine. *J. Endovasc. Surg.* 5 (4), 200–203.

- Di Lorenzo, N., Porta, F., Onnis, G., Cannas, A., Arbau, G., Maleci, A., 1998. Pars interarticularis fenestration in the treatment of foraminal lumbar disc herniation: a further surgical approach. *Neurosurgery* 42 (1), 87–89 discussion 89-90.
- Ivanov, A.A., Faizan, A., Ebraheim, N.A., Yeasting, R., Goel, V.K., 2007. The effect of removing the lateral part of the pars interarticularis on stress distribution at the neural arch in lumbar foraminal microdecompression at L3–L4 and L4–L5: anatomic and finite element investigations. *Spine* 32 (22), 2462–2466.
- Lee, S., Kim, S.-K.K., Lee, S.-H.H., Kim, W.J., Choi, W.-C.C., Choi, G., et al., 2007. Percutaneous endoscopic lumbar discectomy for migrated disc herniation: classification of disc migration and surgical approaches. *Eur Spine J* 16 (3), 431–437.
- Macnab I. Negative disc exploration. an analysis of the causes of nerve-root involvement in sixty-eight patients. *J. Bone Joint Surg.* volume 1971; 53(5): 891–903.
- Reinshagen, C., Ruess, D., Molcanyi, M., Redjal, N., Walcott, B.P., Goldbrunner, R., et al., 2015. A novel translaminar crossover approach for pathologies in the lumbar hidden zone. *J. Clin. Neurosci* 22 (6), 1030–1035.
- Schulz, C., Kunz, U., Mauer, U.M., Mathieu, R., 2014. Early postoperative results after removal of cranially migrated lumbar disc prolapse: retrospective comparison of three different surgical strategies. *Adv. Orthop.* 2014, 702163.