



POSTER PRESENTATION

Open Access

Border sharpness of scar tissue after myocardial infarction as determined by self-navigated free-breathing isotropic 3D whole-heart inversion recovery magnetic resonance

Tobias Rutz^{1*}, Giulia Ginami^{2,4}, Davide Piccini^{2,3}, Jérôme Chaptinel^{2,4}, Simone Coppo^{2,4}, Gabriella Vincenti¹, Matthias Stuber^{2,4}, Juerg Schwitler¹

From 19th Annual SCMR Scientific Sessions
Los Angeles, CA, USA. 27-30 January 2016

Background

The border zone of myocardial scar after myocardial infarction (MI) plays an important role for arrhythmia formation. For this reason, high-resolution 3D information of scar tissue for planning of electrophysiological interventions after MI is highly desirable. This study evaluates sharpness of the borders (SB) of scar after MI by a self-navigated isotropic 3D free-breathing whole-heart magnetic resonance with inversion recovery (3DSN-IR) in comparison to a standard 2D inversion recovery sequence.

Methods

Patients after MI detected by 2D late gadolinium enhancement (2D LGE) on a standard 2D inversion recovery sequence (resolution 1.3 mm², 8 mm slice thickness) underwent 3DSN-IR on a 1.5T cardiac magnetic resonance scanner (MAGNETOM Aera, Siemens). Data acquisition was performed during the most quiescent systolic phase with a prototype 3D radial trajectory with self-navigation [1] after administration of 0.2 mmol/kg of Gadobutrol. A non-selective IR pulse was added prior to each acquired k-space segment to the segmented, ECG-triggered, fat-saturated radial SSFP imaging sequence with an isovolumetric resolution of 1.15 mm³. Inversion time was assessed with a 2D radial scout scan prior to 3DSN-IR. To determine SB, a customized software was used to calculate signal intensity

gradients between two regions [2]. SB in mm⁻¹ of borders “blood pool to scar”, “blood pool to non-infarcted myocardium” and “scar to non-infarcted myocardium” were compared between a 2D LGE short-axis slice with 8 mm slice thickness and two corresponding reconstructed 3DSN-IR short-axis slices, one with isovolumetric voxel size (1.15 mm³) and the second interpolated to 8 mm slice thickness, all at the same anatomical location.

Results

Thirteen patients (5 females, 58 ± 10 y, time between 2D LGE and 3D LGE 59 ± 64 days) were included. All scars visualized by 2D LGE could be identified by 3DSN-IR. SB was significantly better in 3DSN-IR compared to 2D LGE for the borders “blood pool to non-infarcted myocardium” and “scar to non-infarcted myocardium”. There was a trend to a better SB for 3DSN-IR images for the border “blood pool to scar” (see table and figure).

Conclusions

High resolution 3DSN-IR improves delineation of myocardial scar after MI as expressed by increased border sharpness in comparison to 2D LGE.

Authors' details

¹Division of Cardiology and Cardiac MR Center, University Hospital of Lausanne, Lausanne, Switzerland. ²Center for Biomedical Imaging (CIBM) & Center for Cardiovascular Magnetic Resonance Research (CVMR), University of Lausanne, Lausanne, Switzerland. ³Advanced Clinical Imaging Technology, Siemens Healthcare IM BM PI, Lausanne, Switzerland. ⁴Department of Radiology, University Hospital and University of Lausanne, Lausanne, Switzerland.

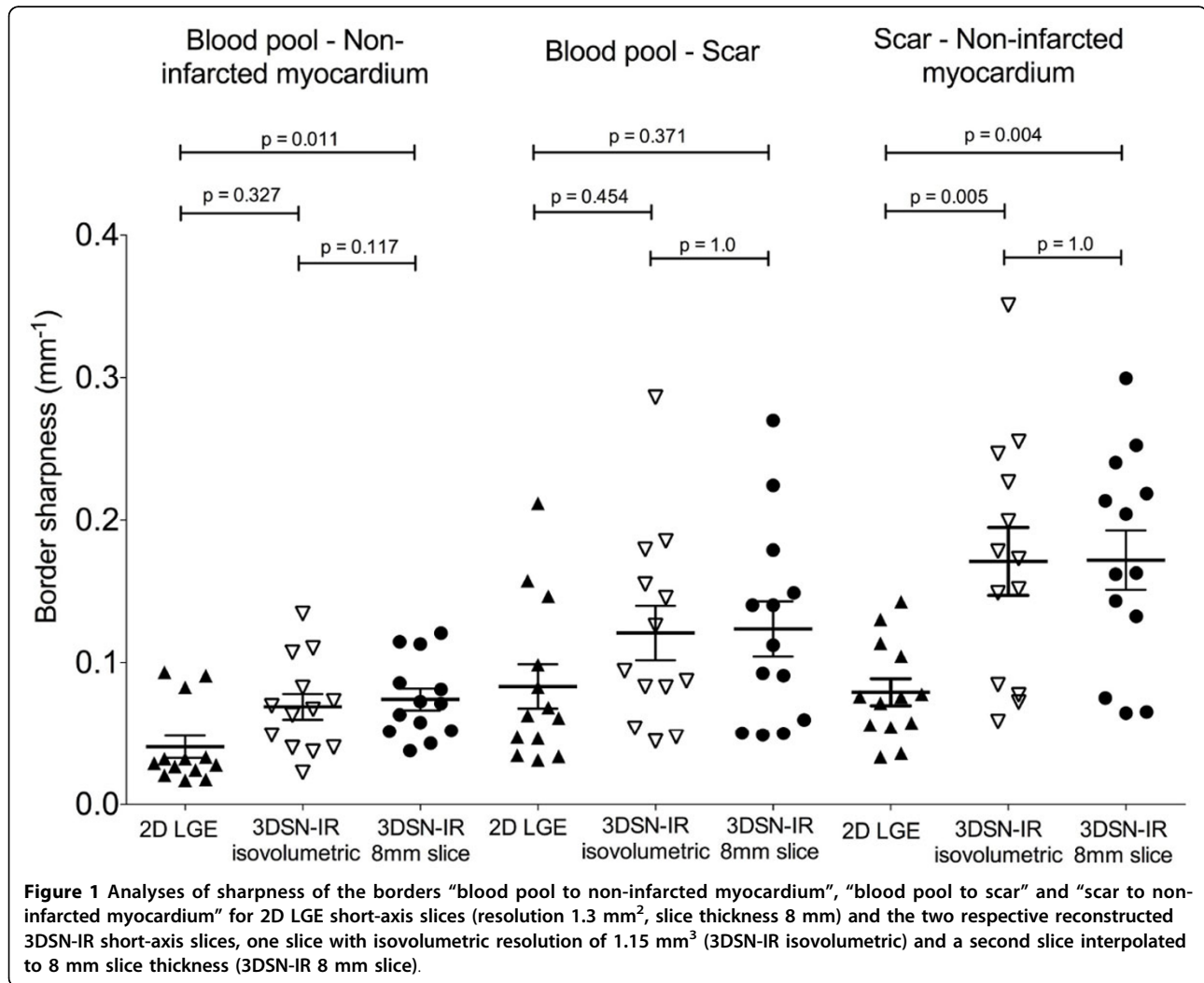
¹Division of Cardiology and Cardiac MR Center, University Hospital of Lausanne, Lausanne, Switzerland

Full list of author information is available at the end of the article

Table 1 Border sharpness of 2D LGE and 3DSN-IR images. Border sharpness of “blood pool to non-infarcted myocardium”, “blood pool to scar” and “non-infarcted myocardium to scar” in mm⁻¹. Data are mean ± standard deviation or range (interquartile) where appropriate.

	2D LGE	3DSN-IR isovolumetric voxel (1.15 mm)	3DSN-IR 8 mm slice thickness	p
Blood pool - non-infarcted myocardium	0.029 (0.022, 0.058)*	0.067 (0.04, 0.095)	0.071 (0.051, 0.10)	0.037
Blood pool - scar	0.083 ± 0.056	0.121 ± 0.070	0.124 ± 0.070	0.176
Scar - non-infarcted myocardium	0.079 ± 0.034†	0.171 ± 0.086	0.172 ± 0.074	<0.001

* p = 0.011 2D LGE to 3DSN-IR 8 mm slice thickness, † p < 0.006 2D LGE vs. 3DSN-IR isovolumetric voxel and 3DSN-IR 8 mm slice thickness



Published: 27 January 2016

References

1. Piccini D, et al: Respiratory self-navigation for whole-heart bright-blood coronary MRI: methods for robust isolation and automatic segmentation of the blood pool. *Magn Reson Med* 2012, **68**(29):P75-9.
2. Kording F, et al: Doppler ultrasound compared with electrocardiogram and pulse oximetry cardiac triggering: A pilot study. *Magn Reson Med* 2014.

doi:10.1186/1532-429X-18-S1-P74

Cite this article as: Rutz et al: Border sharpness of scar tissue after myocardial infarction as determined by self-navigated free-breathing isotropic 3D whole-heart inversion recovery magnetic resonance. *Journal of Cardiovascular Magnetic Resonance* 2016 **18**(Suppl 1):P74.