

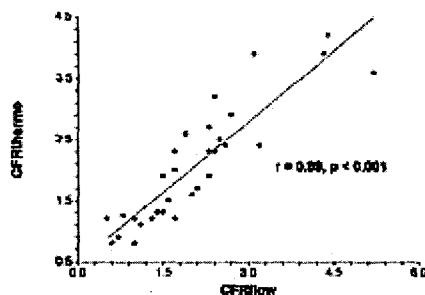
1151-174 Is Coronary Thermodilution as Accurate as Doppler Velocity for Measuring Coronary Flow Reserve?

William F. Fearon, Leora B. Balsam, H. M. Omar Farouque, Anthony D. Caffarelli, Robert C. Robbins, Peter J. Fitzgerald, Alan C. Yeung, Paul G. Yock, Stanford University, Stanford, CA

Background: Thermodilution coronary flow reserve (CFR_{thermo}) is a new technique for measuring coronary flow reserve (CFR) using a coronary pressure wire and based on the ability of the pressure transducer to also measure temperature changes. CFR_{thermo} defined as the mean transit time of room temperature saline injected down the LAD at rest divided by the mean transit time at maximal hyperemia.

Methods: In an open-chest pig model, CFR_{thermo} in the left anterior descending (LAD) artery was measured and compared to flow reserve from a Doppler wire (CFR_{doppler}), and an external flow probe placed around the LAD (CFR_{flow}). In 6 pigs, CFR was measured by all 3 means in the normal LAD and after creation of an epicardial LAD stenosis. In order to determine the added effect of microvascular disease, measurements of flow reserve were also performed after disruption of the coronary microcirculation using embolized microspheres. Intracoronary papaverine (20 mg) was used to induce hyperemia.

Results: In a total of 31 paired measurements, CFR_{thermo} correlated strongly with the reference standard CFR_{flow} ($r=0.89$, $p<0.001$). CFR_{doppler} correlated less well with CFR_{flow} ($r=0.77$, $p<0.001$). The correlation between CFR_{doppler} and CFR_{thermo} was the least strong ($r=0.72$, $p<0.001$).



Conclusion: Assessing CFR using a coronary thermodilution technique correlates better with absolute flow derived CFR than does CFR measured with a Doppler wire.

1151-175 First Experience With Noncavitational Ultrasound Enhancement of Selective Cellular Delivery of Liquid Perfluorocarbon Nanoparticles to Angiogenic Sites

Kathryn C. Crowder, Michael S. Hughes, Jon N. Marsh, Michael J. Scott, Lori Chinen, Thomas D. Harris, Gregory M. Lanza, Samuel A. Wickline, Washington University School of Medicine, St. Louis, MO, Bristol-Myers/Squibb, N. Billerica, MA

Background: Given that ultrasound (US) has been proposed as an adjunctive method to enhance delivery of drugs in conjunction with microbubble cavitation, we sought to delineate its use for noncavitational depot drug delivery with the use of targeted liquid perfluorocarbon nanoparticles (PN's). We have previously demonstrated the potential for PN's to deliver agents and kill cells selectively upon binding to specific cellular epitopes, and have confirmed the opportunity to image these targeted PN's simultaneously with US or MRI. We sought to specifically target cells expressing $\alpha_v\beta_3$, an integrin involved in angiogenesis in plaque growth and restenosis, and to enhance the delivery of PN's with clinical levels of US energy.

Methods: PN's were complexed with ligands targeted to $\alpha_v\beta_3$ and incubated with cells (MDA-435) that express $\alpha_v\beta_3$ in culture. Control PN's were produced that carried no ligand to $\alpha_v\beta_3$. A custom specimen holder permitted simultaneous visualization of cell interactions (Nikon Diaphot 300). Exposure to calibrated levels of US energy was imposed (MI:1.9; exposure time: 5 min; 2-3 MHz phased array transducer: Acuson 3Va2). Perfluorocarbon content (PFC) measured by gas chromatography was used as a tracer to confirm delivery of particles to cells.

Results: After PN binding to cells and application of US, a >2-fold increase in deposition of PFC to the cells was observed (2.67 ± 0.34 vs 1.12 ± 0.07 micrograms, with and without US respectively, $p<0.005$). For control PN's (nonbinding), US also increased PFC deposition, but the overall level was significantly less. We observed that PN's were not destroyed by US and that acoustic radiation forces (primary and secondary) may have participated in the enhanced delivery.

Conclusion: Enhancement of cellular interaction with targeted PN's is feasible by noncavitational mechanisms. Accordingly, US enhanced delivery of tracers or drugs to a wide variety of pathologic tissues may be useful for augmenting drug delivery after targeting, while limiting untoward effects on other tissues.

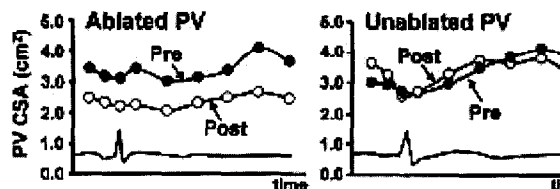
1151-176 Acute Pulmonary Vein Reaction to Radiofrequency Catheter Ablation for Atrial Fibrillation: Assessment Using Intracardiac Ultrasound

Hideaki Kanzaki, John Gorcsan, III, L. Elif Sade, Donald A. Severyn, David Schwartzman, University of Pittsburgh, Pittsburgh, PA

Background: Radiofrequency (RF) catheter ablation of pulmonary vein (PV) ostia is a novel therapy for atrial fibrillation. However, PV stenosis after the procedure has been a recent concern. To assess the acute effects of RF ablation, features of PVs were analyzed using left atrial intracardiac echo (ICE).

Methods and Results: Twenty-three patients (age 52 ± 8 years) were studied. A total of 129 PVs were assessed with AcuNav (Acuson) and 80 PVs with 9MHz (Boston Sci) ICE. After RF ablation, peak Doppler velocity at PV ostium increased from 52 ± 17 to 74 ± 24 cm/s and gradient increased from 1.2 ± 0.7 to 2.4 ± 1.4 mmHg, $*p < 0.01$. Ablation also resulted in an acute decrease in PV cross-sectional area (CSA) from 3.1 ± 1.8 to 1.9 ± 1.1 cm², increase in wall thickness from 0.7 ± 0.2 to 1.6 ± 0.7 mm and loss of its normal motility throughout the cardiac cycle: %change decreased from $27 \pm 14\%$ to $20 \pm 8\%$ (Fig), $*p < 0.01$. Unablated PVs remained unchanged.

Conclusion: RF ablation resulted in acute increases in PV flow velocity and wall thickness and decreases in CSA and motility, although no significant pulmonary stenosis was observed. ICE provides useful information about PV status in RF catheter ablation.

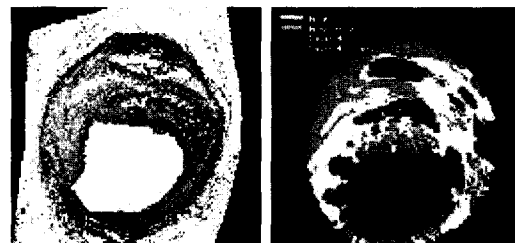


1151-177 Intravascular Ultrasound Plaque Characterization: Spectral Analysis and Tissue Maps

Anuja Nair, Daniella Calvetti, Barry D. Kuban, Paul Schoenhagen, Steven E. Nissen, E. Murat Tuzcu, D. Geoffrey Vince, The Cleveland Clinic Foundation, Cleveland, OH, Case Western Reserve University, Cleveland, OH

Background: Current diagnostic modalities do not allow reliable *in vivo* characterization of atherosclerotic plaques. Spectral analysis of backscattered IVUS data provides information on plaque composition beyond the standard gray-scale display. **Methods:** Data were collected *ex vivo* from 51 left anterior descending coronary arteries, with 30 MHz IVUS transducers in saline at physiologic pressure. Regions of interest (ROI), selected from histology, comprised 101 fibrous (F), 56 fibro-lipidic (FL), 50 calcified (C) and 70 calcified-necrotic (CN) regions. Spectra of IVUS data, identified for each ROI, were used to calculate spectral parameters. Various spectra were computed from mathematical models for data representing ROIs of decreasing sizes (480, 240, 120 Fm) to increase spatial accuracy of tissue maps. Statistical schemes were computed with the spectral parameters from 75% of the data. The remaining data were utilized to assess the accuracy of these schemes. Color-coded tissue maps were visualized for plaque composition.

Results: The spectrum that performed best, correctly identified 90.4% of F, 92.8% of FL, 90.9% of C, and 92.8% of CN in the training data set and 79.7%, 81.2%, 89.5%, 85.5% in the test data, respectively, with high specificities (90-100%). **Conclusion:** Coronary plaque composition can be predicted using IVUS radiofrequency data analysis. Autoregressive mathematical spectral classification schemes provided accurate tissue maps of plaque with increased spatial accuracy.



1151-197 Vulnerable Plaque Diagnosis by a Self-Contained Intravascular Magnetic Resonance Imaging Probe in Ex Vivo Human Insitu Coronary Arteries

Jacob Schneiderman, Robert L. Wilensky, Assaf Weisse, Eitzik Samouha, Lev Muchnik, Gil Alexandrowicz, Malca Chen-Zion, Mordechai T. Ilovich, Moshe Flugelman, Erez Golan, Renu Virmani, Armed Forces Institute of Pathology, Washington, DC

Background: To evaluate the efficacy of a novel intravascular MR probe in diagnosing vulnerable plaques (VPs) within *ex-vivo* insitu human coronary arteries.

Methods: A novel self-contained MRI probe has been developed, which requires no external MRI set-up for producing local high resolution images. The probe has been integrated into an intravascular catheter. Fourteen fresh postmortem hearts from patients suspected of coronary death underwent selective coronary angiography, yielding 7 hearts with coronary atherosclerosis. Eighteen intermediate proximal lesions (within 6cm from origin), each presenting stenosis in the range of 30%-60%, were designated for MR assessment and comparative histological validation. MR acquisition with the MR catheter was performed at preselected coronary lesions, with the MR probe gently applied to the luminal surface. The experimental set-up was designed to mimic coronary catheterization, thereby, intra-coronary pulsatile saline perfusion was maintained during acquisition. MR measurements were performed at 4 different angles along the circumference at each site (90 degrees apart). Each segment which underwent MR evaluation was also examined histologically by a trained pathologist unaware of the MR data, and the MR diagnosis was subsequently matched against histological diagnosis.

Results: Fifteen out of 18 lesions were accurately diagnosed as VP (3), or nonVP (12). There were two false positive diagnoses of VP, and one missed ruptured lesion, where lipid-rich necrotic material was replaced by laminating thrombus.

Conclusions: The self-contained intravascular MR probe has been demonstrated as an