

Available online at [www.sciencedirect.com](http://www.sciencedirect.com)

Journal of the Chinese Medical Association 74 (2011) 316–321

[www.jcma-online.com](http://www.jcma-online.com)

## Original Article

# Comparison of a minimally invasive technique with open tension band wiring for displaced transverse patellar fractures

Chao-Ching Chiang<sup>a,b,\*</sup>, Wei-Ming Chen<sup>a,b</sup>, Chien-Fu Jeff Lin<sup>c</sup>, Cheng-Fong Chen<sup>a,b</sup>,  
Ching-Kuei Huang<sup>a,b</sup>, Yun-Hsuan Tzeng<sup>d</sup>, Chien-Lin Liu<sup>a,b</sup>

<sup>a</sup>Department of Orthopaedics and Traumatology, Taipei Veterans General Hospital, Taipei, Taiwan, ROC

<sup>b</sup>Department of Surgery, National Yang-Ming University School of Medicine, Taipei, Taiwan, ROC

<sup>c</sup>Department of Statistics, National Taipei University, Taipei, Taiwan, ROC

<sup>d</sup>Department of Radiology, Cheng-Hsin General Hospital, Taipei, Taiwan, ROC

Received February 19, 2011; accepted February 23, 2011

## Abstract

**Background:** Open reduction and internal fixation with tension band wire is the standard treatment for displaced transverse patellar fractures. Recently, some minimally invasive techniques have been proposed as possible alternative methods. This retrospective study compared a newly reported percutaneous osteosynthesis with conventional open method for the treatment of displaced transverse patellar fractures.

**Methods:** The minimally invasive technique was performed by percutaneous osteosynthesis with modified Carpenter's (POMC) technique, using figure-eight wiring through two-paired cannulated screws under the control of arthroscopy and fluoroscopy. The conventional open surgery was performed with open modified anterior tension band (OMATB) technique. Totally 60 displaced transverse fractures were included in our study. Twenty were treated with percutaneous technique and 40 with open method. Outcome assessment included analysis of radiographic images, range of motion, Lysholm scores, complications, and reoperations.

**Results:** Mean follow-up was 37.3 months. Comparison of POMC and OMATB groups showed statistically significant results as follows: shorter surgical time,  $70.4 \pm 12.5$  minutes for POMC group; greater degrees of flexion,  $140.4 \pm 6.1$  for POMC group; better total range of motion,  $139.6 \pm 8.2$  for POMC group; higher Lysholm scores,  $93.6 \pm 3.1$  for POMC group. Frequencies of total complications and reoperations were significantly lower in POMC group.

**Conclusion:** POMC method was a reproducibly reliable method, offering better functional outcome, lower incidence of complications, and reoperations, as compared with standard OMATB group for transverse patellar fractures. Nevertheless, it is not recommended for severely comminuted fractures.

Copyright © 2011 Elsevier Taiwan LLC and the Chinese Medical Association. All rights reserved.

**Keywords:** Anterior tension band; Arthroscopy; Carpenter's technique; Displaced patellar fractures; Minimally invasive technique

## 1. Introduction

Open repair of displaced patellar fractures is still the most widely used technique and can offer satisfactory results.<sup>1</sup> However, complications associated with open treatment such as infection, delayed wound healing, broken wires, irritation,

\* Corresponding author. Dr. Chao-Ching Chiang, Department of Orthopaedics & Traumatology, Taipei Veterans General Hospital, 201, Section 2, Shih-Pai Road, Taipei 112, Taiwan, ROC.

E-mail address: [chiangcc@vghtpe.gov.tw](mailto:chiangcc@vghtpe.gov.tw) (C.-C. Chiang).

immigration of Kirschner wires, fixation failure, and revision were reported with different frequencies between 7% and 43%.<sup>2–6</sup> These complications were related with open approach, fixation device, or both.

Displaced transverse patellar fractures are easier for anatomic reduction by closed manipulation and potential candidates for percutaneous osteosynthesis. Less invasive technique with percutaneous fixation may reduce postoperative wound complications and the possibility of delayed operation. However, there is paucity of research in this field. There were a few articles describing techniques using closed methods for

patellar fractures.<sup>7–12</sup> However, they were not often indicated for significantly displaced transverse patellar fractures or these fixation methods were not considered to be as rigid as traditional tension band methods.

In a recent study, we reported a minimally invasive technique with figure-eight wiring through two parallel cannulated screws under arthroscopy and fluoroscopy assistances.<sup>13</sup> The objectives of this study are to compare the results of our percutaneous method with open modified anterior tension band (OMATB) for displaced transverse patellar fractures. This percutaneous reconstruction was a modification of Carpenter's technique.<sup>14</sup>

## 2. Methods

We retrospectively reviewed 107 patellar fractures treated with surgery at our institution between March 2004 and December 2005. The operative procedures were thoroughly explained to all patients preoperatively and performed with their consent. The criterion of inclusion was displaced, transverse patellar fractures, treated by either percutaneous osteosynthesis with modified Carpenter's (POMC) method or conventional OMATB technique. Exclusion criteria were open injury, multiple fractures, multiple trauma, comminuted fractures, periprosthetic patellar fractures, associated with pre-existed osteoarthritis of knee, clinical course greater than 48 hours, and loss to follow-up. No patellar fractures in POMC group and 3 in OMATB group were lost to follow-up.

All medical records of the study groups were reviewed comprehensively, including injury time, mechanism, soft tissue injury, associated trauma, operative time, and postoperative rehabilitation. Follow-up records including the functional recovery, complications, and the need for further surgery were reviewed in detail. Radiographic images were studied regarding initial fracture type, displacement, postoperative reduction, implant position, and healing process. Definitive assessment of functional outcome, including range of motion and Lysholm knee scoring rating system,<sup>15</sup> was evaluated at the last follow-up by an independent research staff who did not take part in the surgery of either group.

A total of 60 patients with 60 patellar fractures were included in our study. There were 20 patients in the POMC group and 40 patients in the OMATB group. All operations in the POMC group were performed by the same surgeon. For OMATB group, operations were performed or supervised by another two surgeons.

### 2.1. POMC technique

The operation was described in detail in our previous report.<sup>13</sup> The patient was prepared in supine position and a tourniquet was applied. First, the intra-articular hematoma was drained through standard inferolateral portal and superolateral portal of arthroscopy (Fig. 1A). Then reduction of fracture was attempted first at full extension. One pointed reduction forceps was applied at the far ends of the two fragments percutaneously. The reduction was checked with arthroscopy and fluoroscopy. If the joint congruity was not achieved, further

manipulation was performed. Each fragment was manipulated with an individual pointed reduction forceps until satisfactory congruity was achieved (Fig. 1B). The reduction was maintained with another pointed reduction forceps across the fragments and verified (Fig. 1C).

Two guide wires were inserted from the proximal end of the patella through two small stab incisions (Fig. 1D). These two parallel guide wires were separated by 1.5 cm–2 cm. The true length of screw was little shorter than the initial measured length. Then two partially-threaded 4.0-mm cannulated screws were inserted (Fig. 1E).

The first wire, 18 gauge (1.2 mm), was passed antegradely within the first cannulated screw. The end of wire came outside the distal stab incision. A cannula, such as a suction tip or 14-gauge catheter, was then passed subcutaneously from the proximal stab incision of the second screw to the distal stab incision of the first screw. Then the distal end of the first wire was guided in the cannula toward the proximal stab incision of the second screw. The similar procedure was repeated for the second wire directed to the proximal stab incision of the first screw. Then the proximal ends from each wire at each proximal stab incision were met and twisted simultaneously. The reduction and tension of fixation were checked to 90° of flexion under fluoroscopy. Generally, this technique was performed through 6–8 stab incisions.

### 2.2. OMATB technique

The method was performed using previously described standard procedure for open reduction and fixation with OMATB technique.<sup>1,16</sup>

### 2.3. Rehabilitation

For all patients in both groups, neither splint nor brace was used. Passive range of motion was started postoperatively as much pain as the patient could tolerate. Protected weight-bearing with two crutches was allowed at the first day following the surgery. Three days after the operation, patients were discharged. Active range of motion was instructed since 3 weeks postoperatively. Full weight-bearing without walking assistance was started after 8 weeks.

All patients were followed with the similar principles. Generally, biweekly in the first month, then monthly until 6 months and every 6 months thereafter.

### 2.4. Statistical methods

All 60 subjects were included in this analysis. Data were entered and analyzed with PC SAS (SAS Institute, Cary, NC, USA). Data were presented as mean ± standard deviation for continuous variables and number (percentage) for categorical variables. To compare two groups, two-sample *t* test was used for continuous variables and Fisher's exact test for categorical variables. The differences were presented as mean (95% confidence interval) for continuous variables and odds ratio

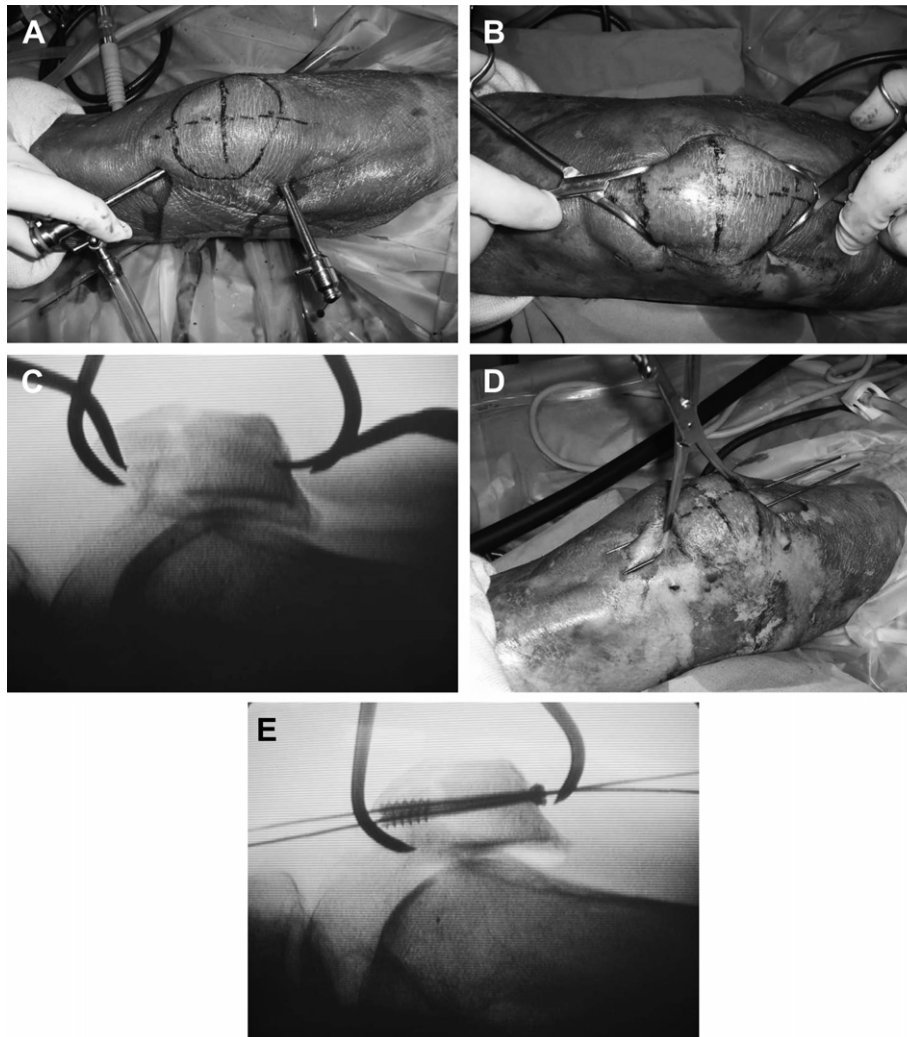


Fig. 1. A: Drainage of intra-articular hematoma through inferolateral- and superolateral-arthroscopic portals. B: Fragments were manipulated with two towel clamps percutaneously. C: After satisfactory reduction was achieved, application of reduction clamp across fragments. D: Two parallel guide wires were introduced antegrade, from superocentral to inferocentral and superomedial to inferomedial. E: Two partially-threaded 4.0-mm cannulated screws were inserted through the guide wires.

(95% confidence interval) for categorical variables. The significance level was set at 0.05 for all the tests in advance.

### 3. Results

#### 3.1. Demographics

Demographics of both groups were shown in Table 1. There were no statistically significant differences between these two groups, including preoperative displacement of fractures  $18.6 \pm 9.6$  mm in the POMC group versus  $18.0 \pm 12.2$  mm in the OMATB group. Surgical time was significantly shorter in the POMC group, with an average of  $70.4 \pm 12.5$  minutes.

#### 3.2. Surgical and functional outcome

The results are shown in Table 2. After a mean follow-up of  $38.3 \pm 6.8$  months, all fractures healed in the POMC group (Fig. 2). One nonunion happened in the OMATB group. There

was no difference in the union time between both groups. At the last follow-up, the POMC group had gained significantly better flexion and total range of motion, at an average of  $140.4 \pm 6.1^\circ$  and  $139.6 \pm 8.2^\circ$ , respectively. For Lysholm scores, the POMC group was at an average of  $93.6 \pm 3.1$ , statistically higher than the OMATB group.

#### 3.3. Complications and reoperations

All complications and reoperations in the follow-up period of both groups are shown in Table 3. Overall frequency of complications was 75% in the OMATB group and significantly higher than 15% in the POMC group. No postoperative infection or wound complication was observed in the POMC group (Fig. 3). Most common complication in both groups was irritation to hardware, with significantly higher frequency of 48% in the OMATB group. Forty-five percentage of the OMATB group showed migration of hardware, which was significantly higher than the POMC group.

Table 1  
Demographics of two groups<sup>a</sup>

	POMC (n = 20)	OMATB (n = 40)	Mean difference or odds ratio (95% CI)	p
Gender				
Female	11 (55%)	25 (62%)	1.52 (0.45, 5.02) <sup>c</sup>	0.585 <sup>d</sup>
Male	9 (45%)	15 (38%)		
Age (yr)	56.6 ± 14.7	60.2 ± 15.4	−3.59 (−11.61, 4.83) <sup>b</sup>	0.410 <sup>c</sup>
Side				
Left	11 (55%)	19 (47%)	1.22 (0.37, 4.00) <sup>c</sup>	0.791 <sup>d</sup>
Right	9 (45%)	21 (53%)		
Mechanism				
Fall	17 (85%)	33 (83%)	1.27 (0.25, 8.52) <sup>c</sup>	1.000 <sup>d</sup>
RTA	3 (15%)	7 (17%)		
AO/OTA type				
Transverse, middle (45-C1.1)	18 (90%)	35 (87%)	1.36 (0.20, 15.46) <sup>c</sup>	1.000 <sup>d</sup>
Transverse, distal (45-C1.3)	2 (10%)	5 (13%)		
Fracture displacement (mm)	18.6 ± 9.6	18.0 ± 12.2	0.60 (−5.1, 6.91) <sup>b</sup>	0.738 <sup>c</sup>
Operative time to injury (hr)	15.2 ± 7.9	17.0 ± 11.1	−1.79 (−7.01, 3.83) <sup>b</sup>	0.515 <sup>c</sup>

<sup>a</sup> Data are shown in number of patients (percentages) or means ± standard deviation.

<sup>b</sup> Mean difference (95% confidence interval) for continuous variable.

<sup>c</sup> Odds ratio (95% confidence interval) for categorical variables.

<sup>d</sup> Fisher's exact test.

<sup>e</sup> Two-sample *t* test.

AO/OTA = Arbeitsgemeinschaft für osteosynthesefragen/orthopaedic trauma association; OMATB = open modified anterior tension band technique; POMC = percutaneous osteosynthesis with modified Carpenter's technique; RTA = road traffic accident.

Reoperation rate was 15% for the POMC group, significantly lower than 58% in the OMATB group. The most common cause of reoperation in the two groups was removal of hardware as a result of irritation. Two patients (5%) of the OMATB group had recalcitrant keloid formation after initial open surgery and recurred after removal of implant with scar revision. These two patients underwent further scar revision by plastic surgeon, followed by a series of laser therapy and local steroid injections.

#### 4. Discussion

The results of our study showed that the POMC technique could provide satisfactory osteosynthesis, better functional outcome, and fewer complications and reoperations as compared with the OMATB technique.

Surgical time was shorter in the POMC group. Longer time is definitely necessary to close the surgical wound in the layers of OMATB group, which would make significant difference in

both groups. However, the difference could be attributed partly to the bias of operators. The OMATBs group were performed by attending surgeons or fellows/residents under supervision, which could prolong surgical time as a result of different levels of experience in both groups.

Functional outcome was statistically better for POMC group. But the difference was not substantial and might be insignificant clinically. Our interpretation is that the POMC group can offer equivalent or even better functional results than the OMATB group.

There are few reports describing percutaneous fixation of patellar fracture with the assistance of fluoroscopy or arthroscopy. Luna-Pizarro reported a method of percutaneous patellar osteosynthesis system for modified tension band wiring.<sup>8</sup> They designed a device with encouraging results as compared with open surgery. Tandogan used percutaneous cannulated screws for patellar fractures.<sup>10</sup> Their method was performed for patellar fracture with gap less than 8 mm. For larger displacement, they suggested open approach and

Table 2  
Comparison regarding surgical time, union time, follow-up and functional outcome<sup>a</sup>

	POMC (n = 20)	OMATB (n = 40)	Mean difference (95% CI)	p <sup>b</sup>
Surgical time (min)	70.4 ± 12.5	79.8 ± 15.7	−9.40 (−16.18, −0.62)	0.021
Union time (wk)	10.8 ± 1.3	10.3 ± 2.2	0.48 (−0.37, 1.73)	0.129
Follow-up (mo)	38.3 ± 6.8	36.6 ± 7.4	1.66 (−1.64, 5.96)	0.240
Extension (°)	−0.8 ± 3.8	−1.2 ± 3.7	0.43 (−1.48, 2.55)	0.605
Flexion (°)	140.4 ± 6.1	132.1 ± 8.5	8.34 (4.43, 12.84)	<0.001
ROM (°)	139.6 ± 8.2	130.7 ± 10.2	8.92 (4.20, 14.64)	<0.001
Lysholm scores	93.6 ± 3.1	88.8 ± 6.7	4.78 (2.01, 8.16)	<0.001

<sup>a</sup> Data are shown in means ± standard deviation.

<sup>b</sup> Two-sample *t* test.

OMATB = open modified anterior tension band technique; POMC = percutaneous osteosynthesis with modified Carpenter's technique.

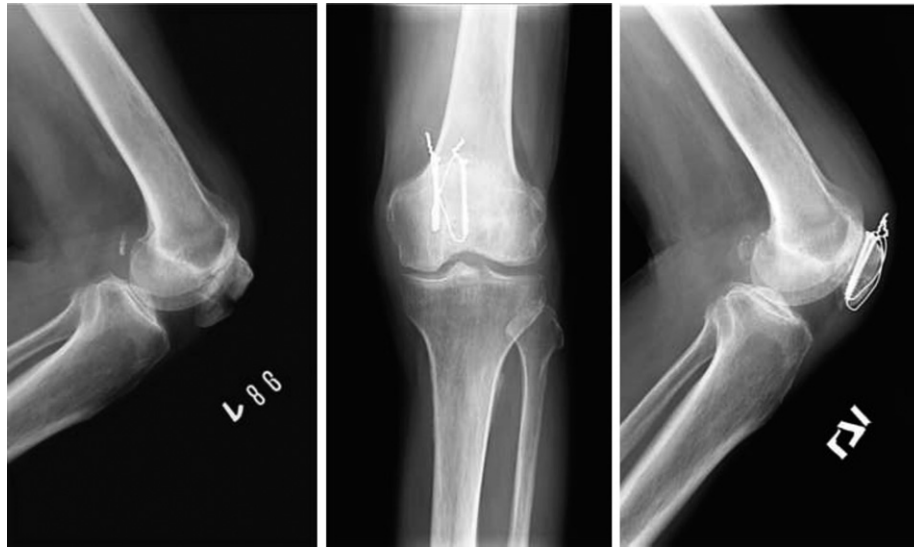

Fig. 2. Preoperative and postoperative 9-week radiographs of one case in the group of percutaneous osteosynthesis with modified Carpenter's technique.

concluded it was impossible to apply the figure-eight wire percutaneously. Yanmis described circular external fixator under arthroscopic control for comminuted patellar fractures.<sup>12</sup> All these articles proved minimally invasive approach could be achieved for transverse patellar fractures. However, the strength of fixation was still a concern.

Carpenter described the figure-eight wiring through parallel cannulated screws by open method for transverse patellar fractures.<sup>14</sup> The clinical results of this technique reported by Berg were comparable with those of modified tension band wiring.<sup>17</sup> Another biomechanical analysis by Carpenter

demonstrated figure-eight wiring through the paired cannulated screws provided the best mechanical strength as compared with screws alone or modified tension band technique.<sup>18</sup>

Our minimally invasive technique was a modification of Carpenter's method under the control of arthroscopy and fluoroscopy. The difference of our fixation construct to Carpenter's was that we used two separate wires instead of one

Table 3  
Comparison regarding complications and reoperations<sup>a</sup>

	POMC (n = 20)	OMATB (n = 40)	Odds ratio (95% CI)	p <sup>b</sup>
<b>Complications</b>				
Total	3 (15)	30 (75)	0.06 (0.01, 0.26)	<0.001
Infection	0	1 (3)		1.000
Malreduction	0	2 (5)		0.541
Loss of reduction	0	5 (13)		0.154
Nonunion	0	1 (3)		1.000
Migration	0	18 (45)		<0.001
Irritation	3 (15)	19 (48)		0.012
Broken wires	0	2 (5)		0.541
Keloid	0	2 (5)		0.541
Refractures	0	1 (3)		1.000
Patellar tendon tear	0	1 (3)		1.000
<b>Reoperations</b>				
Total	3 (15%)	23 (58)	0.17 (0.03, 0.68)	0.006
Debridement	0	1 (3)		1.000
Revision of fixation	0	2 (5)		0.541
Patellectomy	0	1 (3)		1.000
Removal	3 (15%)	22 (55)		0.013
Scar revision	0	2 (5)		0.541

<sup>a</sup> Data are shown in number of patients (percentages).

<sup>b</sup> Fisher's exact test.

OMATB = open modified anterior tension band technique;  
POMC = percutaneous osteosynthesis with modified Carpenter's technique.

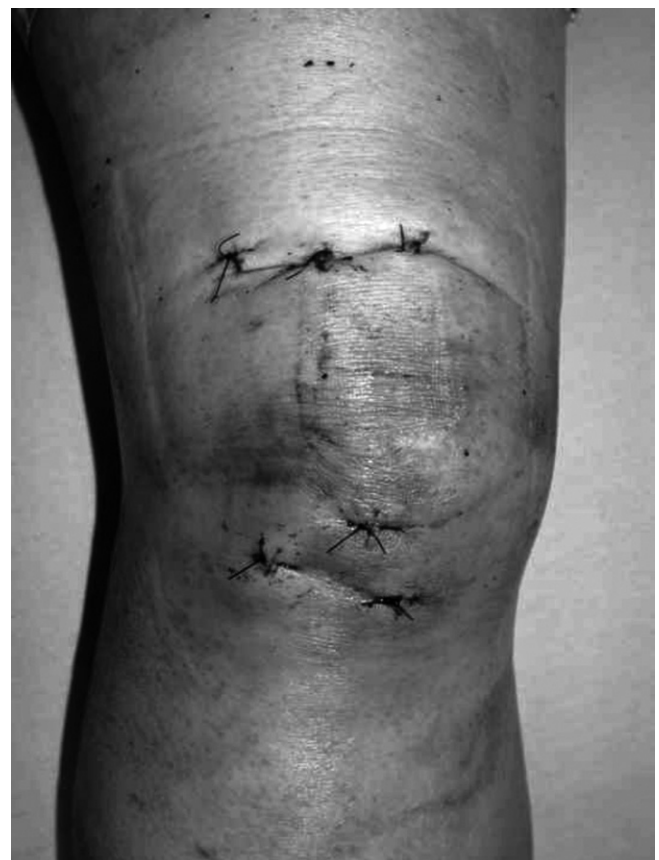

Fig. 3. Local soft tissue condition at a week after surgery in the percutaneous osteosynthesis with modified Carpenter's technique.

to pass through the parallel cannulated screws. The advantages of this change are easier passage of wire through each cannulated screw and wires being amenable to be twisted simultaneously to adequate strength when the procedure was performed percutaneously. Another modification was the use of arthroscopy and fluoroscopy for percutaneous approach. The possible advantages of arthroscopy in our study are clear verification of articular congruity and decompression of intra-articular hematoma for pain relief.

The major merit of our study is to confirm the percutaneous modification of a well-defined open method with more promising and encouraging surgical outcome than traditional open treatment. We proved that displaced transverse patellar fractures could be repaired with minimally invasive technique and rigid fixation. Both may possibly lead to better surgical outcome and fewer complications.

Some drawbacks still existed in our study. Variables between the both groups existed in approach, fixation method, and surgeon. Some complications and reoperations in the OMATB group were the results of fixation method, not the open approach itself, such as hardware irritation, migration of implant, and loss of reduction. However, the OMATB group could represent the standard reconstruction for displaced patellar fractures by orthopaedic surgeons. We thought it was reasonable to compare the results of a new method with those of the standard open method. Still, some limitations should be considered, our technique is indicated for displaced transverse patellar fractures but not recommended for more comminuted fractures with multiple displaced and stepped fragments. For these complicated fractures, precarious reduction by closed method is expected. Further research is required as to its role in more comminuted fractures.

## References

- Harris RM. Fractures of the patella. In: Bucholz RW, Heckman JD, editors. *Rockwood and Green's fractures in adults*. vol. 2, 5th ed. Philadelphia: Lippincott Williams & Wilkins; 2001. p. P1775–99.
- Perry CR, McCarthy JA, Kain CC, Pearson RL. Patellar fixation protected with a load-sharing cable: a mechanical and clinical study. *J Orthop Trauma* 1988;**2**:234–40.
- Us AK, Kinik H. Self locking tension band technique in transverse patellar fractures. *Int Orthop* 1996;**20**:357–8.
- Wu CC, Tai CL, Chen WJ. Patellar tension band wiring: a revised technique. *Arch Orthop Trauma Surg* 2001;**121**:12–6.
- Gosal HS, Singh P, Field RE. Clinical experience of patellar fracture fixation using metal wire or non-absorbable polyester: a study of 37 cases. *Injury* 2001;**32**:129–35.
- Hung LK, Chan KM, Chow YN, Leung PC. Fractured patella: operative treatment using the tension band principle. *Injury* 1985;**16**:343–7.
- Leung PC, Mak KH, Lee SY. Percutaneous tension band wiring: a new method of internal fixation for mildly displaced patellar fractures. *J Trauma* 1983;**23**:62–4.
- Luna-Pizarro D, Amato D, Arellano F, Hernandez A, Lopez-Rojas P. Comparison of a technique using a new percutaneous osteosynthesis device with conventional open surgery for displaced patella fractures in a randomized controlled trial. *J Orthop Trauma* 2006;**20**:529–35.
- Ma YZ, Zhang YF, Qu KF, Yeh YC. Treatment of fractures of the patella with percutaneous suture. *Clin Orthop* 1984;**191**:235–42.
- Tandogan RN, Demirors H, Tuncay CI, Cesur N, Hersekli M. Arthroscopic-assisted percutaneous screw fixation of select patellar fractures. *Arthroscopy* 2002;**18**:156–62.
- Turgut A, Gunal I, Acar S, Seber S, Gokturk E. Arthroscopic-assisted percutaneous stabilization of patellar fractures. *Clin Orthop* 2001;**389**:57–61.
- Yanmis I, Oguz E, Atesalp AS, Ozkan H, Kurklu M, Demiralp B, et al. Application of circular external fixator under arthroscopic control in comminuted patella fractures: technique and early results. *J Trauma* 2006;**60**:659–63.
- Chiang CC, Huang CK, Chen WM, Lin CF, Tzeng YH, Liu CL. Arthroscopically assisted percutaneous osteosynthesis of displaced transverse patellar fractures with figure-eight wiring through paired cannulated screws. *Arch Orthop Trauma Surg* 2011;**131**:949–54 [published online: 25 December 2010].
- Carpenter JE, Kasman R, Matthews LS. Fractures of the patella. In: Schafer M, editor. *Instructional course lectures*, vol. 43. Rosemont: American Academy of Orthopaedic Surgeons; 1994. p. P97–108.
- Tegner Y, Lysholm J. Rating systems in the evaluation of knee ligament injuries. *Clin Orthop* 1985;**198**:43–9.
- Szyszkowitz R. Patella and tibia. In: Muller ME, Allgower M, Schneider R, editors. *Manual of internal fixation*. 3rd ed. Berlin: Springer-Verlag; 1991. p. P564–7.
- Berg EE. Open reduction internal fixation of displaced transverse patella fractures with figure-eight wiring through parallel cannulated compression screws. *J Orthop Trauma* 1997;**11**:573–6.
- Carpenter JE, Kasman RA, Patel N, Lee ML, Goldstein SA. Biomechanical evaluation of current patella fracture fixation techniques. *J Orthop Trauma* 1997;**11**:351–6.