

Bioresorbable distraction device for the treatment of airway problems for infants with Robin sequence

Corstiaan Breugem · Emma Paes · Moshe Kon ·
Aebele B. Mink van der Molen

Received: 9 June 2011 / Accepted: 2 October 2011 / Published online: 19 October 2011

© The Author(s) 2011. This article is published with open access at Springerlink.com

Abstract Pierre Robin sequence is a well known craniofacial entity. There are numerous ways to treat the respiratory insufficiency, but sometimes surgical intervention is needed. Tracheotomy could be associated with morbidity, and distraction osteogenesis has been established as a stable method to obtain a safe airway. Distraction osteogenesis has traditionally been performed with an external device. In this manuscript we describe the feasibility of an internal bioresorbable device. Retrospective descriptive study was performed in a tertiary academic children's hospital. After multidisciplinary team consultation, 12 consecutive patients with Robin sequence were treated with this internal distraction device. The mean age at surgery was 32 days, and the average amount of mandibular distraction was 18 mm. All patients were extubated after an average of 7.5 days after the surgery. The average length of stay in the hospital was 17 days after surgery. There were no major surgical complications. A tracheotomy was prevented in all our patients, and complications were limited. Long-term studies are needed to evaluate the influence that internal distraction has on the growth of the mandible and teeth. The internal distraction system seems safe for infants with micrognathia and has certain benefits when compared to the external distractor.

Keywords Robin sequence · Robin syndrome · Distraction · Respiratory insufficiency · Cleft palate

Abbreviations

DO Distraction osteogenesis
ENT Ear nose and throat
CT Computed tomography

I soon noticed that many cases of congenital hypoplasia of the mandible occurred and that the organovegetative and psychic life of the infants was more disturbed when the hypoplasia was more pronounced. I have never seen babies live for more than sixteen or eighteen months who presented hypoplasia such that the lower maxilla was pushed more than 1 cm behind the upper.

(Pierre Robin 1934)

Introduction

In 1923 Pierre Robin described a constellation of findings that bears his name today [1]. The triad of findings included micrognathia, glossoptosis and respiratory obstruction; however, considerable confusion in the medical literature delineating Robin sequence has been demonstrated [2, 3]. Pediatricians often encounter the entity "Robin sequence"; however, there are still many unanswered questions surrounding this disorder. Robin sequence can still be associated with significant morbidity and even mortality [4]. Glossoptosis associated with airway compromise is most often the culprit instigating respiratory insufficiency

Each author listed above has participated in the concept and design, analysis and interpretation of data, and drafting or revising of this manuscript; each author has approved the manuscript as submitted.

C. Breugem (✉) · E. Paes · M. Kon · A. B. M. van der Molen
Cleft Palate Team, Department of Pediatric Plastic Surgery,
Wilhelmina Children's Hospital,
P.O. Box 85090, 3508 AB, Utrecht, The Netherlands
e-mail: c.c.breugem@umcutrecht.nl

C. Breugem
Meander Medical Centre,
P.O. Box 1502, 3800 BM, Amersfoort, The Netherlands

(Fig. 1). However, other causes can cause breathing problems, and these patients should be carefully investigated preferably by a multidisciplinary team [5]. Traditionally tracheotomy has been considered the definitive treatment in securing a stable airway when the airway was compromised. However, tracheotomy can be associated with significant morbidity and even mortality [6, 7].

Distraction of the mandible has become an accepted method to treat the micrognathia and subsequently the airway compromise [8–12]. Distraction osteogenesis (DO) is a technique in which bone is gradually lengthened after performing an osteotomy. After a short latency period, the bone segments are distracted. The bone segments are separated from each other at a slow, steady rate. Similar to fracture healing new bone will subsequently be formed between these segments. After the acquired bone length is achieved the consolidation period ensues in which the bone segments are held in their advanced positions. This is needed because the newly formed bone has to mature and consolidate. During DO the distraction proceeds at a slow, steady state ensuing not only bone lengthening but also concomitant soft tissue expansion. Subsequently will not only new bone be formed, but the muscles, blood vessels, nerves and mucosa will also be elongated. Ilizarov popularized distraction on the lower extremity in the 1940s [13], although Codvilla introduced distraction nearly 100 years ago [14]. Following in the footsteps of Ilizarov, mandibular distraction was first performed experimentally by Snyder [15]. The first clinical report of mandibular distraction in the English literature was reported by McCarthy et al. in 1992 [16]. Like Ilizarov did, mandibular distraction was performed with an external device. Since then, numerous reports have been published demonstrating the feasibility in relieving airway obstruction [8–12]. However, an external distraction system is cumbersome to take care of; it leaves external scars and always needs a second operation to remove the distraction device. In an

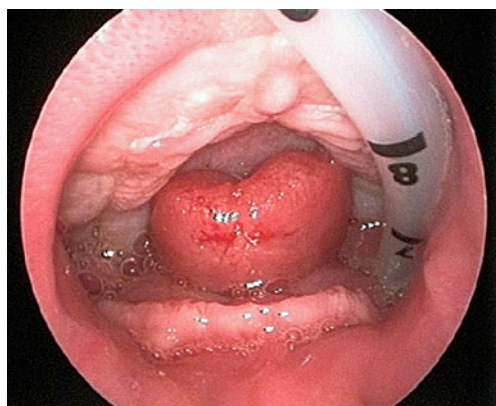


Fig. 1 Typical cases of glossoptosis. Patient has a cleft of the small palate (not visible on photo). Note retrusion of mandibula with regard to maxilla

attempt to alleviate these disadvantages, an internal and resorbable distraction device (located under the skin) was developed [17]. The goal of this manuscript is to review our results of performing mandibular distraction with a resorbable system in patients with Robin sequence and life-threatening airway compromise.

Methods

For this study we looked at the patients we treated early, i.e. in the first 3 months after births. Patients were considered for distraction only after a diagnosis of Robin sequence was made (glossoptosis, micrognathia and airway compromise). The medical ethical board approved this study. Patients were seen by a multidisciplinary team consisting of a pediatrician, ENT surgeon, geneticist, dietician and plastic surgeon. Non-invasive treatment options such as prone positioning and nasal continuous positive pressure are sufficient measures for most newborn babies with Robin sequence. Only patients that could not be treated conservatively and would traditionally be considered candidates for a tracheotomy were candidates for distraction osteogenesis. Before intervention patients were observed with continuous pulse oximetry and blood gas evaluation (pCO₂, HCO₃ etc). Saturation measured over 12 h in all patients was < 90% for >5% of the 12 h [10]. Polysomnography was only used if the aforementioned results were not comparable to the clinical picture. Patients received an endoscopy by the ENT surgeon prior to DO to exclude any other cause of airway obstruction (e.g. tracheomalacia, stenosis etc) besides the glossoptosis.

The first patient treated (Table 1) had already a tracheotomy, while the others were treated primarily for airway compromise. The aim in the first patient was to relieve him of his tracheostoma.

All patients were treated with the Lactosorb internal distractor distributed by W. Lorenz Surgical, a Biomet company. The precise placement has been described previously by Burstein [17]. Briefly, the surgical approach was a submandibular incision (2–2.5 cm) with dissection to the mandibular body and angle while preserving the mandibular branch of the facial nerve. The two dissolvable plates were placed after the vector of distraction was determined from a mandibular X-ray or a CT scan. An osteotomy was performed after the plates were fixated with soluble screws (Fig. 2). The distractor wire was subsequently placed subperiosteally and protruded the skin through an incision placed above the ear (Fig. 3). After the placement of the distractor, we waited for 36–48 h before the distraction was started. A postoperative X-ray was made. Distraction was performed at a rate of 1 mm twice daily (Figs. 4 and 5). After surgery all patients were

Table 1 Patient characteristics

Name	Date of birth (day.month.year)	Age at surgery (days)	Amount of distraction (mm)	Associated malformations (syndrome)	Outcome	Duration of hospital stay (days)
1. JH	09.19.2006	83	20	COL 11a2 gene mutation (anocular Stickler syndrome)	Admission with tracheacanalule. Minor local symptoms of infection at pin site. Removal 10 months post op.	18
2. NS	10.04.2007	15	18	COL 11a2 gene mutation (anocular Stickler syndrome)	Successful detubation on day 9 post op. Minor local symptoms of infection at one pin site	16
3. SS	10.03.2007	19	16	None	Successful detubation on day 8 post op.	11
4. LB	11.16.2007	17	20	No mutation on Col2A1 and Col11A1 genes. No definite exclusion of Stickler because of severe myopia	Successful detubation on day 11 post op. Technical failure of one distraction screw 5 weeks after surgery	18
5. LN	01.17.2008	13	18	None	Successful detubation on day 8 post op.	23
6. LK	03.30.2008	94	18	None	Successful detubation on day 5 post op.	14
7. RS	06.26.2008	27	20	Megaencephaly and retardation, no genetic mutation found	Successful detubation on day 8 post op.	27
8. LW	02.08.2010	45	22	None	Successful detubation on day 5 post op.	16
9. RS	06.19.2010	16	20	2.19 Mb deletion in 3q22.2q22.3. Further research is ongoing	Successful detubation on day 7 post op.	15
10. GH	11.03.2009	22	18	None	Successful detubation on day 6 post op.	20
11. JH	07.31.2008	11	18	None	Successful detubation on day 8 post op.	17
12. AE	04.23.2010	24	16	Suspicion of Stickler due to familiar myopia	Successful detubation on day 8 post op.	14

op. operation

treated in the pediatric intensive care unit, until the intubation tube could be removed. On average this was performed 5–7 days after the actual distraction was initiated, i.e. when 10–14 mm of bone lengthening was

achieved. Distraction was continued until the mandibular alveolus was in a normal position with regard to the maxillary alveolus or until the maximum technical length of distraction with this device (20–25 mm) was achieved (Fig. 6). After a consolidation phase of 4 weeks the distraction screw was removed in the outpatient clinic with patients receiving only paracetamol 30 min before removal

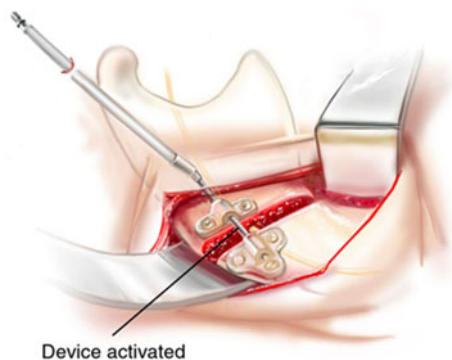


Fig. 2 Location of osteotomy

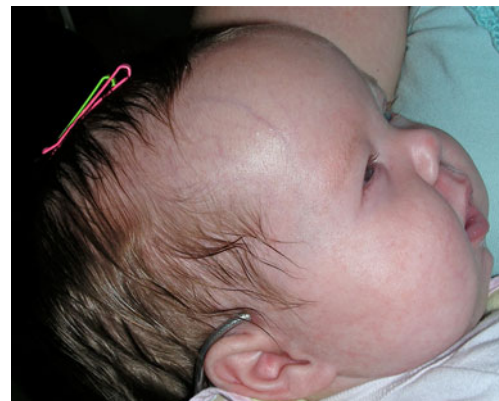

Fig. 3 Placement of internal device with distractor wire visible above ear. This could easily be concealed with a baby hat

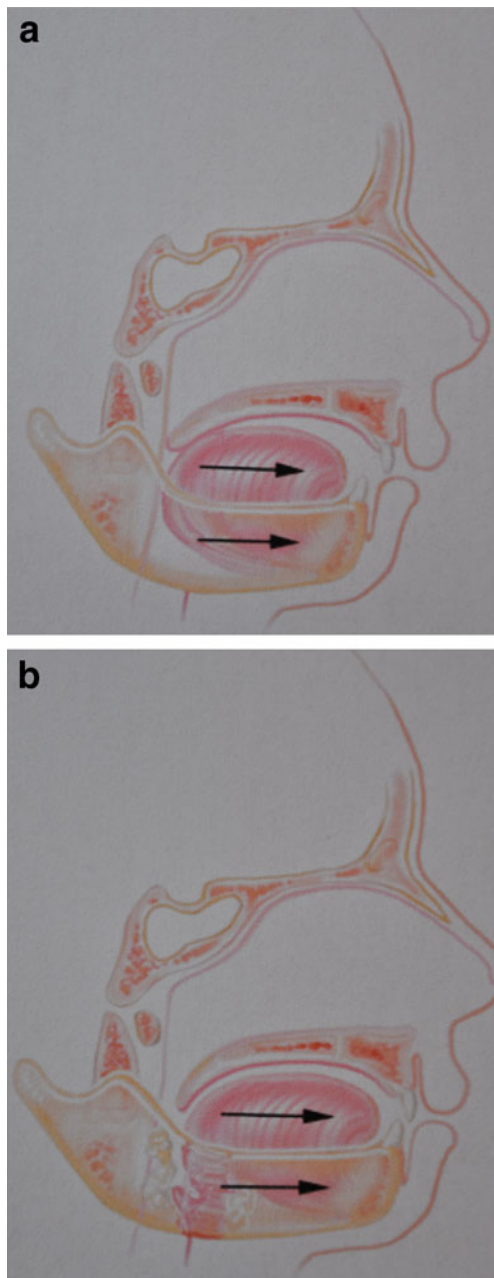


Fig. 4 After osteotomy the mandibular is gradually lengthened with the distraction. **a** Prior to distraction. This brings the tongue forward (**b**) and alleviates the respiratory obstruction

of the screw. An X-ray was performed before the distraction screw was removed to demonstrate bone consolidation.

Results

Twelve patients with Robin sequence were included (Table 1). All our patients had an associated cleft palate. Beside our first patient who already had a tracheostoma prior to distraction, a tracheotomy was prevented in all



Fig. 5 Comparison of resorbable plate size with 2-euro coin

other patients. The mean age at surgery was 32 days (range 11–94 days). The average amount of distraction performed was 18 mm. All patients were extubated after an average of 7.5 days. The average length of stay in the hospital was 17 days after surgery (range 11–27 days).

All patients were discharged without any nasal continuous positive pressure. Although feeding issues are not the aim of this manuscript, it should be noted that six of the patients went home without nasogastric feeding and another four patients had the nasogastric feeding discontinued before the distraction screw was removed. Our first patient treated with internal distraction could not be decannulated

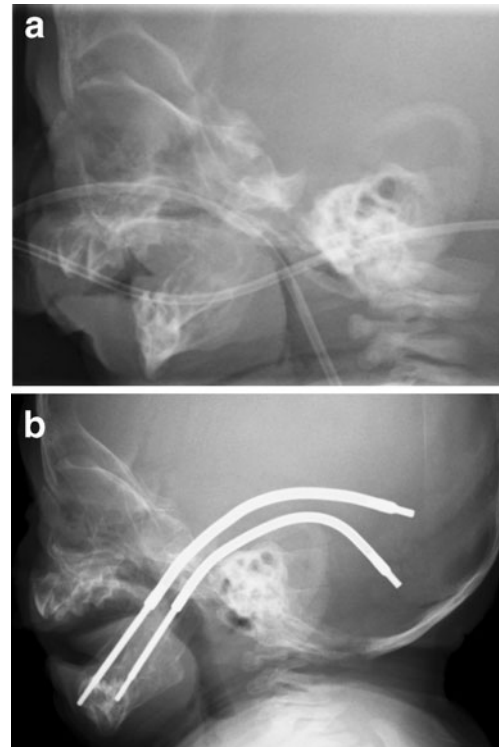


Fig. 6 Example of patient before (**a**) and after (**b**) surgery. Notice the extra space in the oropharynx after the distraction and that the nasogastric tube has been removed

after the distraction process that started at the age of 3 months. The X-ray showed only about 8–10-mm distraction, despite the expected 20-mm distraction. No surgical re-exploration was performed, but we expect that an incomplete osteotomy or possible mechanical default of the apparatus was the cause. The patient was eventually decannulated at 7 months of age, and it is unknown whether the distraction influenced this in a positive way. In another patient the distraction screw fell out after 95% of the consolidation phase was completed. The patient showed no symptoms, and the technical failure did not lead to any delay or problems. Patient No. 7 in Table 1 developed some redness in the skin around the distraction screw but with antibiotic ointment and oral antibiotics; this resolved without complications.

Discussion

This study demonstrates that the use of an internal bioresorbable distraction system for the treatment of airway compromise in Robin sequence seems a safe procedure with no serious short-term sequelae.

The treatment of patients with airway compromise and associated micrognathia and glossoptosis has been an ongoing research field for many physicians involved in pediatric care. There are numerous ways to address the airway obstruction in newborns ranging from prone positioning to nasopharyngeal airway placement and surgical intervention. Recently the “pre-epiglottic baton plate” (PEBP) has been described as another method to treat sleep apnea in infants with isolated Robin sequence [18]. The aim of our manuscript was not to compare the different treatment methods but to investigate an innovative method. We have previously demonstrated that there is widespread confusion regarding the description of this disorder [2, 3]. Moreover, by having different descriptions of Robin sequence, it is not possible to compare various treatment options. Robin sequence affects approximately 1:8000–8500 live births. Additionally it has been demonstrated that many different syndromes could be associated with Robin sequence [2, 3]. Some patients have multiple congenital malformations that do not fall within diagnostic criteria for a specific syndrome. It has been demonstrated that syndromic Robin sequence patients are associated with worse outcomes regarding the severity of feeding problems and airway occlusion [7]. For this study we used the definition described originally by Pierre Robin, consisting of micrognathia, glossoptosis and airway compromise. All our patients had an associated cleft palate. It is well known that most patients with Robin sequence can be treated with positional changes and nasal continuous positive pressure without surgical intervention [4]. However, it is also

recognized that a small subgroup needs some form of intervention to maintain an adequate airway [4, 10–12]. Tracheotomies for example can be associated with significant morbidity for the patient and places a huge social burden and responsibility on the family of the patient [6]. Average age at decannulation is 3.1 years, and the long-term sequelae of tracheal stenosis or tracheomalacia may be present in up to 50% to 75% of cases [6, 7, 12]. Other complications that could be associated with tracheotomy include sudden airway obstruction from mucous plugging or accidental decannulation. Additional concerns include airway infection, airway bleeding and possible inhibition of proper speech and swallowing development. Tongue–lip adhesion was introduced in 1946 and has long been an alternative to tracheotomies. Success rates have been determined between 50 and 80% although patient characteristics were not always clearly defined in the manuscripts [19, 20]. Complications associated with glossopey include a dehiscence of the adhesion and scarring of the salivary glands. Patients also need a second operation to undo the tongue–lip adhesion.

The feasibility of distraction osteogenesis in the treatment of airway problems was recently assessed by a comprehensive meta-analysis performed by Ow and Cheung [21]. This review retrieved 646 patients in which a bilateral distraction was performed to treat upper airway obstruction. Tracheotomy was prevented in 91.3% of neonates. However, distraction osteogenesis is still a relatively new technique and is performed with an external device in most cases [9–12, 16, 22, 23]. External distraction leaves scars on the side of the face and always needs a second operation to remove the pins [21]. The internal device is small (Fig. 6). Patients need only one operation as the material is dissolvable. The inconspicuous scar is located under the border of the mandible and above the ear. The external distraction has the added benefit that multiple vectors of distraction are possible, making it a more suitable distractor in patients with, for example, hemifacial microsomia and an absent condyle of the mandible (class II and III mandibular hypoplasia). However, the external distraction device is cumbersome and could definitely be inconvenient for parents and caretakers. For this reason patients are often admitted to the hospital for extended periods of time [12]. The distractor wire of the internal device above the ear is small, and this could easily be concealed under a baby hat. In this study patients had a distraction at an early age. This obviously was done to prevent a tracheostomy. However, at this age the mandible is also small and soft, and if screws are not adequately fixed they will break out. As the child gets older, the bone will become harder and more stable with subsequent easier fixation of the distractor.

A recent study has demonstrated that the long-term results of distraction osteogenesis are sustained [11, 12].

However, the entire process of distraction osteogenesis has multiple steps that each have potential complications and subsequently presents a unique challenge to the surgeon. Potential complications such as open bite deformities, tooth malformations or losses and possible nerve damage should be discussed before every intervention. A recent review has demonstrated that the external distraction device is often associated with the following complications: tooth injury (22.5%), hypertrophic scarring (15.6%), nerve injury (facial and inferior alveolar) (11.4%), infection (9.5%), inappropriate vector (8.8%), device failure (7.9%), fusion error (2.4%) and temporo-mandibular joint injury (0.7%) [22–24].

However, when we compare our study with the only other study population where the same internal resorbable device was used [8, 17], it seems that the internal device is associated with less morbidity than the external device. Although it should be mentioned that our study population is small, and long-term follow-up is needed to determine which device is superior.

In our study we had one patient where an “unsuccessful” distraction was achieved. Prior to distraction she had a tracheotomy, as was custom in our hospital at that stage. Objectively we achieved only 10 mm of distraction despite the expected 20 mm. However, we were able to decannulate her at 7 months of age. Since literature demonstrates that the average age of decannulation for children with Robin sequence is 3.1 years, it is possible that the distraction did shorten her tracheotomy time [25].

It is often stated that the mandible in Robin sequence always has a “catch-up” phase and that patients have a normal mandible in the long-term. However, it is demonstrated in the literature that micrognathia seldom recovers fully and that the previously reported “catch-up growth” often does not occur [26, 27].

Neonates with Robin sequence suffer from two main problems: airway obstruction and feeding difficulties. The main aim of this study was to determine the feasibility of this internal resorbable device to prevent tracheotomies; however, the impact distraction has on feeding was not studied and will be investigated in the future. Still we can address that the majority of our patients were dismissed without the need for a nasogastric tube and were able to be fed with a bottle and a Haberman teat feeder. Many other factors must be taken into consideration before deciding which intervention is best for the patient. In some patients with Robin sequence, mandibular distraction can permanently correct the obstructed airway, and subsequent inconvenience and costs associated with the maintenance of the tracheotomy can be avoided [8, 9, 11, 12]. It has also been demonstrated that some patients need multiple distractions and some patients will only benefit from a tracheotomy because of neurological impairment [28].

Conclusion

The internal distraction system seems safe for infants with micrognathia and has certain benefits when compared to the external distractor. A tracheotomy was prevented in all our patients, and complications were limited. Long-term studies are needed to evaluate the influence that internal distraction has on the growth of the mandible and teeth.

Conflict of interest The authors have no conflicts of interest to disclose.

Open Access This article is distributed under the terms of the Creative Commons Attribution Noncommercial License which permits any noncommercial use, distribution, and reproduction in any medium, provided the original author(s) and source are credited.

References

1. Robin P (1923) La chute de la base de la langue considérée comme une nouvelle cause de gans la respiration nasopharyngienne. *Bull Acad Natl Med (Paris)* 89:37–41
2. Breugem CC, Mink van der Molen AB (2009) What is “Pierre Robin sequence”. *J Plast Reconstr and Aesth Surg* 62:1555–1558
3. Breugem CC, Courtemanche DJ (2010) Robin sequence: clearing nosologic confusion. *Cleft Palate Craniofac J* 47(2):197–200
4. Caoutte-Laberge L, Bayet B, Larocque Y (1994) The Pierre Robin sequence: review of 125 cases and evolution of treatment modalities. *Plast Reconstr Surg* 93:934–942
5. Shprintzen RJ (1988) Pierre Robin, micrognathia and airway obstruction: the dependency of treatment on accurate diagnosis. *Int Anesth Clin* 26:64–71
6. Carron JD, Derkay CS, G1 S et al (2000) Pediatric tracheotomies: changing indications and outcomes. *Laryngoscope* 110:1099–1104
7. Jiang D, Morrison GA (2003) The influence of long-term tracheostomy on speech and language development in children. *Int J Pediatr Otorhinolaryngol* 67(Suppl 1):S217–220
8. Burstein FD (2008) Resorbable distraction of the mandible: technical evolution and clinical experience. *J Craniofac Surg* 19:637–643
9. Sidman JD, Sampson D, Templeton B (2001) Distraction osteogenesis of the mandible for airway obstruction in children. *Laryngoscope* 111:1137–1146
10. Schaefer RB, Stadler JA, Gosain AK (2004) To distract or not to distract: an algorithm for airway management in isolated Pierre Robin sequence. *Plast Reconstr Surg* 113:1113–1125
11. Tibesar RJ, Scott AR, McNamara C et al (2010) Distraction osteogenesis of the mandible for airway obstruction in children: long-term results. *Otol Head Neck Surg* 143:90–96
12. Denny A, Amm C (2005) New technique for correction of neonates with severe Pierre Robin sequence. *J Pediatr* 147(1):97–101
13. Ilizarov GA (1989) The tension-stress effect on the genesis and growth of tissues. *Clin Orthop Relat Res* 238:249–281
14. Codvilla A (1905) On the means of lengthening, in the lower limbs, the muscles and tissues which are shortened through deformity. *Am J Orthop Surg* 2:353–369

15. Snyder CC, Levine GA, Swanson HM (1973) Mandibular lengthening by gradual distraction. Preliminary report. *Plast Reconstr Surg* 51:506–508
16. McCarthy JG, Schreiber J, Karp NS et al (1992) Lengthening the human mandible by gradual distraction. *Plast Reconstr Surg* 89:108
17. Burstein FD, Williams JK (2005) Mandibular distraction osteogenesis in Pierre Robin sequence: application of a new internal single-stage resorbable device. *Plast Reconstr Surg* 115(1):61–67
18. Bacher M, Sautermeister J, Urschitz MS et al (2011) An oral appliance with velar extension for treatment of obstructive sleep apnea in infants with Pierre Robin sequence. *Cleft Palate Craniofac J* 48(3):331–336
19. Smith MC, Senders CW (2006) Prognosis of airway obstruction and feeding difficulty in Robin sequence. *Int J Pediatr Otorhinolaryngol* 70(2):319–324
20. Hoffman W (2003) Outcome of tongue–lip placcation in patients with severe Pierre Robin sequence. *J Craniofac Surg* 14(5):602–608
21. Bijnen CL, Don Griot PJ, Mulder WJ et al (2009) Tongue–lip adhesion in the treatment of Pierre Robin sequence. *J Craniofac Surg* 20(2):315–320
22. Ow AT, Cheung LK (2008) Meta-analysis of mandibular distraction osteogenesis: clinical applications and functional outcomes. *Plast Reconstr Surg* 121:54–69
23. Genecov DG, Barcelo CR, Steinberg C et al (2009) Clinical experience with the application of distraction osteogenesis for airway obstruction. *J Craniofac Surg* 20(2):1817–1821
24. Master DL, hanson PR, Gosain AK (2010) Complications of mandibular distraction osteogenesis. *J Craniofac Surg* 21(5):1565–1579
25. Denny A, Kalantarian B (2002) Mandibular distraction for neonates: a strategy to avoid tracheostomy. *Plast Reconstr Surg* 109:896–904
26. Daskalogiannakis J, Ross RB, Thompson BD (2001) The mandibular growth controversy in Pierre Robin sequence. *Am J Orthod Dentofacial Orthop* 120(3):280–285
27. Suri S, Ross RB, Thompson BD (2010) Craniofacial morphology and adolescent facial growth in Pierre Robin sequence. *Am J Orthod Dentofacial Orthop* 137(6):763–774
28. Izadi K, Yellon R, Mandell DL et al (2003) Correction of upper airway obstruction in the newborn with internal mandibular distraction osteogenesis. *J Craniofac Surg* 14(4):493–499