

ORIGINAL ARTICLE / *Cardiovascular imaging*

MRI monitoring of myocardial iron overload: Use of cardiac MRI combined with hepatic MRI in a cohort of multi-transfused patients with thalassaemia



A. Quatre^{a,*}, A. Jacquier^b, P. Petit^b, R. Giorgi^{c,d},
I. Thuret^e

^a Department of internal medicine, North Hospital, chemin des Bourrely, 13015 Marseille, France

^b Department of Radiology, La Timone Hospital, 27, boulevard Jean-Moulin, 13385 Marseille, France

^c Public Health and Medical Information, La Timone Hospital, 27, boulevard Jean-Moulin, 13385 Marseille, France

^d UMR912 SESSTIM, Inserm, IRD, Aix-Marseille University, Faculty of Medicine, 27, boulevard Jean-Moulin, 13385 Marseille, France

^e Thalassaemia Reference Centre, Department of Paediatric Haematological Oncology, La Timone Hospital, 27, boulevard Jean-Moulin, 13385 Marseille, France

KEYWORDS

Thalassaemia;
Iron overload;
Cardiac MRI;
T2*;
Hepatic MRI

Abstract

Purpose: We report the results of combining cardiac and hepatic MRI in the same examination to monitor 48 multi-transfused patients presenting iron overload secondary to their transfusions. This cardiac MRI technique uses acquisition sequences and calculation software that are readily available for 1.5 T systems, and it has been validated to screen for patients at risk of cardiac complications who present myocardial iron overload ($T2^* < 20$ milliseconds).

Patients and methods: A total of 176 combined MRI examinations were performed between May 2006 and January 2012 in 48 patients who had received transfusions due to thalassaemia. This monocentric retrospective study brings together all of the imaging examinations carried out.

Results: There was a positive correlation between the cardiac $T2^*$ values and left ventricular ejection fraction, which were measured in the same examination. At the first assessment 23/48 patients had a $T2^* < 20$ ms. These patients showed a significant improvement in cardiac $T2^*$ over time while their iron chelation therapy was being intensified.

Abbreviations: MRI, magnetic resonance imaging; LVEF, left ventricular ejection fraction; RT, relaxation time; ET, excitation time; ms, milliseconds.

* Corresponding author.

E-mail address: amandine.quatre@ap-hm.fr (A. Quatre).

Conclusion: This study validates the application of the cardiac MRI technique used to monitor cardiac iron overload in patients who have undergone multiple transfusions.

© 2014 Published by Elsevier Masson SAS on behalf of the Éditions françaises de radiologie.

Introduction

Thalassaemia major is a form of anaemia requiring monthly transfusions from early childhood, with each RBC introducing 200 mg of iron to the patient's system that they lack the natural mechanism to eliminate. In spite of iron chelation therapy, heart failure secondary to post-transfusion iron overload remains the leading cause of death in this illness [1–3].

The MRI techniques that are used to detect and quantify iron in the tissues allow the concentrations of hepatic and cardiac iron to be assessed. Pennell et al. described a reproducible method for quantifying myocardial iron concentration using T2* sequences [4]. A T2* value of below 20 milliseconds points to myocardial iron overload. If cardiac iron overload is detected, patients at risk of heart failure can be identified before they become symptomatic [5,6].

In France, for several years radiologists have been using a standardised and validated method to assess hepatic iron overload, to which a specific myocardial T2* sequence was added to allow an overall assessment of hepatic and myocardial iron overload in a single examination [7]. This technique has been validated to screen for patients who show a T2* value below 20 ms [8].

We report here an exhaustive experience of monitoring using this combined hepatic and cardiac MRI technique for patients treated in Marseille at the thalassaemia reference centre.

Patients and methods

This was a monocentric retrospective study of 48 multi-transfused patients with thalassaemia major ($n=41$) or thalassaemia intermedia ($n=7$) who underwent in total 179 cardiac MRI scans between May 2006 and January 2012, 176 of which were combined with hepatic MRI. This study was exhaustive because it included all of the imaging studies performed in patients with thalassaemia monitored at the specialist thalassaemia reference centre in Marseille over the relevant period.

There were 21 men and 27 women with a mean age of 24 ± 10.4 years at the time of their first cardiac MRI. All of the MRI scans were performed in the radiology department of La Timone Hospital in Marseille. At the time of their first cardiac MRI, 45 patients out of 48 were receiving iron chelation therapy. A result of $T2^* < 20$ ms routinely prompted consideration of intensifying the iron chelation therapy (increasing doses or introducing combination therapy).

The patients underwent combined cardiac MRI using a 1.5 Tesla system (1.5 T Whole-body MR scanner, Symphony TIM, Siemens with a dedicated 12-element coil and 1.5 T Achieva Philips with a dedicated 5-element coil). The

images were acquired with electrocardiogram synchronisation during breath hold and expiration with patients lying on their backs. Three successive sequences were carried out: T1-weighted spin-echo morphological sequences, cine sequences, and gradient-echo sequences to calculate T2*-weighting. To calculate left ventricular ejection fraction we used balanced gradient-echo cine sequences or Steady State Free Precession (SSFP): RT/ET = 3.2 ms/1.8 ms, 7 mm slice thickness, no spacing between slices, an angle of 50°, spatial resolution of $2.1 \times 1.6 \times 7$ mm, temporal resolution of 35 ms; then for post-treatment, specialist semi-automatic measuring software (Argus Viewer). We used the method described by the Lille team [7]. Three acquisitions were taken with slices 10 mm thick through the short axis of the heart using prospective ECG synchronisation, a resolution of 1.4×1.4 mm, a field of view of 350 mm, a bandwidth of 810 Hz, a spatial resolution of 256×256 , a flip angle of 20°, and the number of excitations per cycle was 10. We used the following parameters: RT/ET-ET: 386 ms/2.5 ms–5 ms, RT/ET-ET: 426 ms/2.5 ms–10 ms and RT/ET-ET: 377 ms/2.5 ms–20 ms (Siemens) and RT/ET-ET: 8 ms/2.5 ms–5 ms, RT/ET-ET: 13 ms/2.5 ms–10 ms and RT/ET-ET: 23 ms/2.5 ms–20 ms (Philips).

The signal of the images obtained was analysed at the defined region of interest (ROI) at the interventricular septum. The T2* value was calculated by measuring the relationship between these echoes using the following formula: $T2^* = (ET2 - ET1) / \text{Log}(S1/S2)$.

To calculate the liver iron concentration, we used the method described by Gandon et al. plus an additional sequence that allowed major hepatic iron overloads to be quantified [9,10]. The six following liver sequences were carried out:

- 1 RT: 120 ms; ET 21 ms; angle 20°;
- 2 RT: 120 ms; ET 14 ms; angle 20°;
- 3 RT: 120 ms; ET 9 ms; angle 20°;
- 4 RT: 120 ms; ET 4 ms; angle 20°;
- 5 RT: 120 ms; ET 4 ms; angle 90°;
- 6 RT: 48 ms; ET 1.8 ms; angle 60°.

Then a comparison was made between the liver ROI and the paravertebral muscles using the software available on the website of the University of Rennes [9].

For the statistical analysis the connections between the cardiac T2* data and both the left ventricular ejection fraction (LVEF) and the hepatic iron levels on MRI were studied using Spearman's correlation coefficient. The LVEF values by patient group, those who did or did not have myocardial iron overload, defined as $T2^* \geq 20$ ms, were compared using a non-parametric test (Mann-Whitney test). A mixed linear effect model was used to study the change in T2* values over time. A random intercept model was used to allow for individual variability. Two-tailed statistical tests were used and P -values ≤ 0.05 were considered to be significant. The

analysis was carried out using the software R, version 2.14.0 [10].

Results

In 48 patients managed at the centre, 179 cardiac MRI scans including an assessment of $T2^*$ were carried out, 176 of which were combined with an assessment of liver iron. Over a 68-month period, the 48 patients each had a mean of 3.7 cardiac MRI scans. The time between the first and the last imaging examination was on average 4 years and 5 months. LVEF was only calculated in 103 examinations (46 patients) and this was a random outcome, based on the availability and quality of the sequences taken.

Mean cardiac $T2^*$ at the first examination was 21.2 ± 10.1 ms and mean LVEF was $59.64 \pm 7.15\%$. Mean hepatic iron concentration was $280 \pm 114 \mu\text{mol/g}$ dry liver.

We found a positive correlation between the first LVEF and corresponding cardiac $T2^*$ in the 44 patients analysed using Spearman's correlation coefficient with a value of 0.40 (confidence interval [CI] 95%: 0.06; 0.63; $P < 0.01$, Fig. 1) which supports a link between an increased $T2^*$ value and an increased LVEF.

Furthermore, the left ventricular ejection fraction values in the sub-group of 20 patients who had a $T2^* < 20$ ms were significantly lower than those of the 24 patients with normal $T2^*$: 57.6% as against 62.4% ($P = 0.002$, Table 1).

Of the 48 patients, 23 had a cardiac $T2^* < 20$ ms at their first MRI. Iron chelation therapy was adjusted for 18 of these: combination therapy was introduced for ten patients, nine of which were regimens combining DEFERIPRONE and DEFEROXAMINE, while an increased dose of the chelating agent used as monotherapy was given to six patients, and for two patients, a change was made to the agent used as monotherapy. In five cases in which $T2^*$ was only slightly low (between 17.5 and 19.5 ms) there was no change to

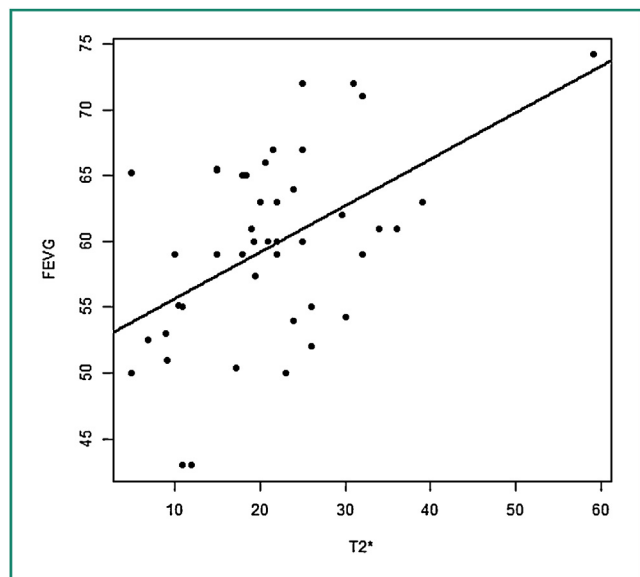


Figure 1. Correlation between the $T2^*$ value in ms and the left ventricular ejection fraction in % at inclusion in 44 patients. The correlation coefficient was assessed at 0.396 (0.06–0.627), $P < 0.01$.

Table 1 Comparison of the medians of LVEF in % depending on whether patients have a $T2^* < 20$ ms (20 patients) or a $T2^* \geq 20$ ms (24 patients).

$T2^*$ (ms)	Number of patients	LVEF (%)	<i>P</i>
< 20	20	57.6 (43.0–77.0)	0.002
≥ 20	24	62.4 (48.0–74.2)	

LVEF: left ventricular ejection fraction; ms: milliseconds.

treatment. Over the course of their monitoring, a further six patients presented $T2^* < 20$ ms: three patients had their treatment intensified through combination therapy, and the other three presented only very modest $T2^*$ decreases. No patients were lost to follow-up, deceased, or developed heart failure during the study period.

An analysis of the change in $T2^*$ values over time showed a significant improvement in $T2^*$ in the sub-group of patients whose $T2^*$ was < 20 ms at their first cardiac MRI based on a regression coefficient of 0.23 (CI 95%: 0.17; 0.28; $P < 0.0001$, Table 2). A significant reduction in liver iron concentration over time was demonstrated with a regression coefficient of -1.23 (CI 95%: -2.37 ; -0.10 ; $P < 0.0001$).

In line with what is normally reported in iron overloaded subjects receiving long-term iron chelation therapy, no correlation was seen between the iron levels in the heart and liver.

Discussion

Since 1999, a cardiac MRI technique developed by Pennell and Anderson's team at the Royal Brompton Hospital in London has been available that makes use of $T2^*$ to achieve a non-invasive method for quantifying myocardial iron overload. This technique has become the gold standard for detecting myocardial iron overload using specific sequences and post-treatment software [4]. This measure is also correlated to left ventricular ejection fraction [6,11–17]. It predicts development of heart failure in the short-term at the pre-symptomatic stage, which means that preventive iron chelation therapy can be adjusted [6,12], and it represents a major step forward in the management of post-transfusion iron overload.

In France, an MRI technique that combines cardiac sequences to calculate $T2^*$ and left ventricular ejection fraction with liver sequences in the same examination, allowing liver iron overload to be calculated, is widely used. To calculate iron excess, we use a number of gradient-echo sequences of the heart and liver and balanced gradient-echo cine sequences to measure left ventricular systolic function [7–10,18]. The method is straightforward, readily available, and standardised. It makes patient monitoring easier because it entails only a single examination to quantify both myocardial and liver iron, as well as assessing left ventricular ejection fraction. The cardiac $T2^*$ sequence has been validated to screen for iron overload because it identifies with good specificity and sensitivity patients presenting $T2^* < 20$ ms based on the standard technique used by

Table 2 Change in T2* values over time in 24 patients with a T2* < 20 ms and 24 patients with a T2* ≥ 20 ms.

T2* (ms)	Number of patients	Correlation coefficient	P
All patients	48	−0.01 (−0.08; 0.03)	0.71
≥ 20	25	−0.01 (−0.10; 0.07)	0.77
< 20	23	0.22 (0.17; 0.28)	< 0.0001

ms: milliseconds.

Anderson and Pennell et al. [5]. In this study, we also show a correlation between left ventricular ejection fraction and the cardiac T2* value.

An improvement over time in patients presenting myocardial iron overload after intensified iron chelation therapy has been reported in controlled studies [19,20]. In our study, an initial T2* value below 20 ms led to adjusted iron chelation therapy in 18 cases, with the five other patients presenting T2* values only very slightly below 20 ms. Alongside intensification of iron chelation therapy, the cardiac MRI results improved and no new case of heart failure arose. This improvement is only statistically significant for the sub-group of patients whose T2* < 20 ms, i.e. the group of interest, since only these patients are at risk of developing heart failure in the short-term. The French technique used to measure T2* can be used with various different software programs and systems; it has demonstrated excellent values for sensitivity, specificity, and positive and negative predictive values for the detection of T2* < 20 ms when compared to the standard technique. It enables not only screening but also monitoring of patients at risk of heart failure after their treatment has been adjusted.

This technique is not validated for monitoring patients with normal T2*: here we must note that greater error in measuring T2* values exceeding 20 ms in comparison to the standard technique has already been reported (standard deviation 10.45 ms) [8].

Finally, we observed a significant reduction in liver iron concentration over time for the entire cohort.

The limitations of our study were that it was at a single centre and it was retrospective as well as the variation in length of time between the MRI scans carried out. However, in showing the improvement over time of the cardiac MRI indices, the study validates the current practice of using the cardiac sequence of the combined MRI to adjust iron chelation therapy in patients with cardiac iron overload.

Conclusion

A cardiac MRI combined with liver exploration to assess iron overload offers, through its specific cardiac T2* sequence, effective monitoring for patients with thalassaemia who present post-transfusion cardiac iron overload.

Disclosure of interest

The authors declare that they have no conflicts of interest concerning this article.

References

- [1] Zurlo MG, De Stefano P, Borgna-Pignatti C, Di Palma A, Piga A, Melevendi C, et al. Survival and causes of death in thalassaemia major. *Lancet* 1989;2:27–30.
- [2] Olivieri NF, Nathan DG, MacMillan JH, Wayne AS, Llu PP, McGee A, et al. Survival in medically treated patients with homozygous betathalassaemia. *N Engl J Med* 1994;331:574–8.
- [3] Borgna-Pignatti C, Rugolotto S, De Stefano P, Zhao H, Cappellini MD, Del Vecchio GC, et al. Survival and complications in patients with thalassaemia major treated with transfusion and deferoxamine. *Haematologica* 2004;89:1187–93.
- [4] Kirk P, He T, Anderson LJ, Roughton M, Tanner MA, Lam WW, et al. International reproducibility of single breathhold T2* MR for cardiac and liver iron assessment among five thalassaemia centers. *J Magn Reson Imaging* 2010;32:315–9.
- [5] Anderson LJ, Holden S, Davies B, Prescott E, Charrier C, Bunce NH, et al. Cardiovascular T-star (T2*) magnetic resonance for the early diagnosis of myocardial iron overload. *Eur Heart J* 2001;22:2171–9.
- [6] Kirk P, Roughton M, Porter JB, Walker JM, Tanner MA, Patel J, et al. Cardiac T2* magnetic resonance for prediction of cardiac complications in thalassaemia major. *Circulation* 2009;120:1961–8.
- [7] <http://oernst.f5lvq.free.fr/liver/fer/fer.html#coeur>
- [8] Ernst O, Thuret I, Petit P, Ameer F, Loundou AD, De kervilier E, et al. Iron overload of hematological origin: validation of a screening procedure for cardiac overload by MRI in routine clinical practice. *Diagn Interv Imaging* 2013;94:601–8.
- [9] Ernst O, Rose C, Sergent G, L'Hermine C. Hepatic iron overload: quantification with MR imaging at 1.5 T. *AJR* 1999;172:1141–2.
- [10] R Core Team. R: a language and environment for statistical computing. Vienna, Austria: R Foundation for Statistical Computing; 2012 <http://www.R-project.org/>
- [11] Westwood MA, Anderson LJ, Maceira AM, Shah FT, Prescott E, Porter JB, et al. Normalized left ventricular volumes and function in thalassaemia major patients with normal myocardial iron. *J Magn Reson Imaging* 2007;25:1147–51.
- [12] Anderson LJ, Holden S, Davis B, Prescott E, Charrier CC, Bunce NH, et al. Cardiovascular T-star (T2*) magnetic resonance for the early diagnosis of myocardial iron overload. *Eur Heart J* 2001;22:2171–9.
- [13] Wood JC, Tyszkla JM, Carson S, Nelson MD, Coates TD. Myocardial iron loading in transfusion-dependent thalassaemia and sickle cell disease. *Blood* 2004;103:1934–6.
- [14] Mavrogeni S, Gotsis ED, Berdousi E, Ladis V, Verganelakis D, Toulas P, et al. Myocardial and hepatic T2* magnetic resonance evaluation in ex-thalassaemic patients after bone-marrow transplantation. *Int J Cardiovasc Imaging* 2007;1569–5794.
- [15] Chacko J, Pennell DJ, Tanner MA, Hamblin TJ, Wonke B, Levy T, et al. Myocardial iron loading by magnetic resonance imaging T2* in good prognostic myelodysplastic syndrome patients on long-term blood transfusions. *Br J Haematol* 2007;138:587–93.

- [16] Mavrogeni SI, Markussis V, Kaklamanis L, Tsiapras D, Paraskevidis I, Karavollas G, et al. A comparison of magnetic resonance imaging and cardiac biopsy in the evaluation of heart iron overload in patients with beta-thalassemia major. *Eur J Haematol* 2005;75:241–7.
- [17] Konen E, Ghoti H, Goitein O, Winder A, Kushnir T, Eshet Y, et al. No evidence for myocardial iron overload in multi-transfused patients with myelodysplastic syndrome using cardiac magnetic resonance T2* technique. *Am J Hematol* 2007;11:1013–6.
- [18] Ernst O, Sergent G, Bonvarlet P, Canva-Delcambre V, Paris JC, L'Hermine C. Hepatic iron overload: diagnosis and quantification with MR imaging. *AJR* 1997;168:1205–8.
- [19] Anderson LJ, Westwood MA, Holden S, Davis B, Prescott E, Wonke B, et al. Myocardial iron clearance during reversal of siderotic cardiomyopathy with intravenous desferrioxamine: a prospective study using T2* cardiovascular magnetic resonance. *Br J Haematol* 2004;127:348–55.
- [20] Tanner MA, Galanello R, Dessi C, Smith GC, Westwood MA, Agus A, et al. A randomized, placebo-controlled, double-blind trial of the effect of combined therapy with deferoxamine and deferiprone on myocardial iron in thalassemia major using cardiovascular magnetic resonance. *Circulation* 2007;115:1876–84.