



Case report

Delayed diagnosis of hemoptysis in the case of prior aortic coarctation repair: A case report of aortobronchial fistula

Vinay Kansal^a, Sudhir Nagpal^{b, c, *}^a University of Ottawa, Faculty of Medicine, Canada^b University of Ottawa, Division of Vascular Surgery, Canada^c Ottawa Hospital Research Institute, Canada

ARTICLE INFO

Article history:

Received 8 June 2015

Accepted 13 July 2015

Keywords:

Hemoptysis

Aortobronchial fistula

Pseudoaneurysm

Coarctation repair

Thoracic endovascular aneurysm repair

ABSTRACT

We report a case of a 46-year old man who presented with spontaneous bright red blood per mouth for several months. The patient had history of aortic coarctation repair at age 17. Endoscopy and nasopharyngoscopy revealed no source of bleeding. Computed tomography scan revealed the presence of thoracic aortic pseudoaneurysm with the formation of an aortobronchial fistula (ABF). This case illustrates the high index of suspicion for ABF in the case of hemoptysis or hematemesis with prior history of coarctation repair. Furthermore, we discuss the role of thoracic endovascular aneurysm repair (TEVAR) as the standard of repair over open surgery.

© 2015 The Authors. Published by Elsevier Ltd. This is an open access article under the CC BY-NC-ND license (<http://creativecommons.org/licenses/by-nc-nd/4.0/>).

1. Case presentation

The patient is a 46 year-old man who presented to our institution with bright red blood per mouth for several months. Initially it was felt the bleeding was from a GI source and upper endoscopy and nasopharyngoscopy were performed with no significant findings. These episodes occurred sporadically with periods of weeks without any bleeding. On several occasions, he lost consciousness and was transfused in hospital. He had no history of infection or fever.

The patient reported a past repair of congenital coarctation of the aorta by left thoracotomy at age 17. Surgical history also included mechanical aortic valve replacement at age 25 for a bicuspid valve requiring anticoagulation (Warfarin). Other significant medical history included cardio-embolic stroke with transient vision impairment, obesity and poorly controlled type 2 diabetes. Social history included social smoking in teenage years and minimal alcohol intake.

Further investigations included a non-enhanced computed tomography (CT) scan revealing a mass in the left lower lobe invading the descending aorta consistent with a lung neoplasm. Prior to a bronchoscopy, a vascular surgery consultation recommended an

enhanced CT, which revealed a pseudoaneurysm of the aorta surrounded by lung tissue consistent with findings of an aortobronchial fistula (ABF) (Fig. 1). This pseudoaneurysm was likely secondary to previous aortic coarctation repair. The bronchoscopy was deferred.

The patient was started on broad-spectrum antibiotics (IV Piptazo 3.375 g q 6 h) for 2 days prior to operative repair of this fistula. Endovascular treatment was chosen. The thoracic pseudoaneurysm was repaired using the Cook Zenith TX2 32-80 graft. The graft was positioned under direct fluoroscopy such that it covered the aorta above the pseudoaneurysm by 4 cm, and distally by 2 cm (Fig. 2). There were no intra-operative issues and the patient recovered well.

Post-operatively the patient was kept on IV Piptazo for 2 weeks. He was then switched to Amox-Claculin 875 mg po BID to prevent any infection due to communication between the lung parenchyma and the endovascular stent graft that was used to exclude the ABF. Furthermore, he is kept on Warfarin 6 mg daily anticoagulation for his mechanical heart valve. The patient will need lifelong surveillance to prevent recurrence, including regular CT scan follow-up to ensure no endoleak or migration of the endovascular prosthesis (Fig. 3).

2. Discussion

ABF is a rare but potentially life-threatening cause of hemoptysis if not adequately treated [1]. Most ABFs originate from a descending

* Corresponding author. The Ottawa Hospital Civic Campus, 1053 Carling Avenue, Room A280, Ottawa, ON, K1Y 4E9, Canada.

E-mail address: snagpal@toh.on.ca (S. Nagpal).

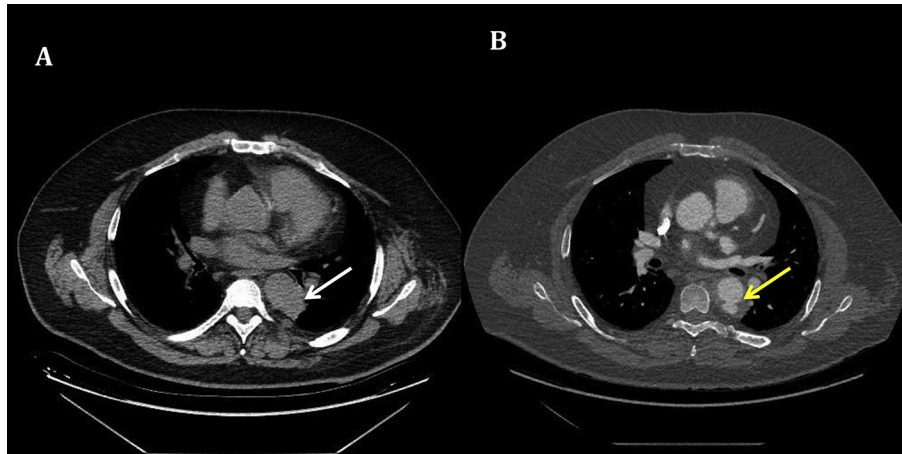


Fig. 1. Preoperative computed tomography (CT) images of the chest consistent with aortobronchial fistula (ABF). (A) Unenhanced CT showing mass initially thought to be a neoplasm (white arrow). (B) Enhanced CT showing ABF (yellow arrow).

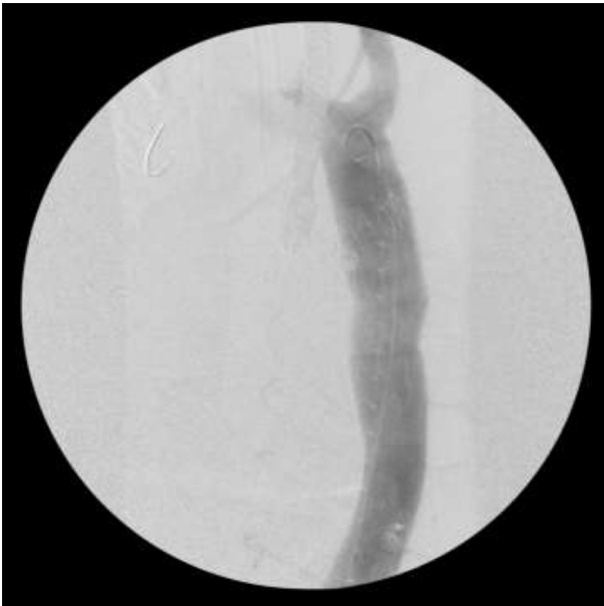


Fig. 2. Intra-operative angiogram during thoracic endovascular aneurysm repair (TEVAR) illustrating successful exclusion of the aortobronchial fistula.

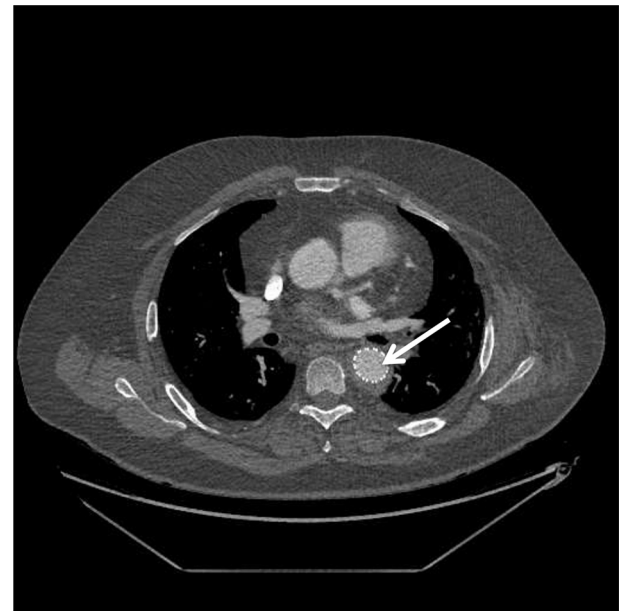

Fig. 3. CT image of the chest showing thoracic endovascular aneurysm repair successfully excluding the aortobronchial fistula. (White arrow – endovascular stent graft).

thoracic aorta aneurysm or pseudoaneurysm, which causes of an erosion of the lung parenchyma or tracheobronchial tree; this allows blood to travel from the aorta into the lung, manifesting as frank hemoptysis. The aneurysm can have numerous etiologies including tuberculosis, syphilis, fungal infections, trauma and atherosclerosis, mainly seen in elderly patients [6]. In younger patients, ABF is more frequently can be secondary to surgical repair of congenital heart defects, and aortic coarctation repair [1,6]). Several factors can lead to fistula. In the cases where surgical intervention involves the implantation of prosthesis, as is the case in aortic coarctation correction, the aneurysm or pseudoaneurysm can form in the proximal or distal suture lines of the prosthesis. Once formed, the continuous pressure of blood against the weakened vascular wall leads to damage of the aorta and subsequent lung parenchyma - usually of the left lung - resulting in the formation of a communication between the two structures. Furthermore, the foreign

material can become attached to the lung tissue and cause inflammation [2].

The case described here illustrates the high index of suspicion and appropriate investigations required for any bleeding that may be considered hemoptysis or hematemesis with a case of prior aortic coarctation repair. Hemoptysis is the most frequent clinical manifestation of ABF and can appear between 3 weeks and 25 years after surgery [4]. Episodes are usually recurrent and self-limited, as was the case with our patient. They tend to increase in severity, leading to massive hemoptysis. Temporary obstruction of the fistula by blood clots is thought to be the reason for this intermittency in hemoptysis presentation. Chest pain may also be present, occurring in 45% of cases of ABF [1], but did not occur in our patient.

Due to the non-specific nature of hemoptysis, diagnosis of ABF is often difficult. Chest x-rays tend to be either normal, or show

alveolar infiltrate due to bloody material, which reveals aneurysm in only 16% of cases [5]. CT is the most appropriate diagnostic tool. This imaging can reveal, in addition to the aneurysm itself, peri-aortic hematoma, mural thrombus and contrast extravasation to the lung parenchyma. When ABF is suspected, bronchoscopy must be used with caution, particularly when there is abundant hemoptysis; the scope may cause mobilization of thrombi in the fistula, which may lead to massive hemorrhage [2].

Surgical intervention is the treatment of choice in most patients and can be performed with relatively low risk of mortality. The main goals of surgical repair are maintenance of distal perfusion and repair of aortic and pulmonary defects. Classically, open surgical approach was considered the mainstay treatment, with either direct suture or patch closure of the aortic defect, anatomic reconstruction, debridement and drainage. However, this approach is reported to carry an operative mortality rate of 20% [5].

Thoracic endovascular aneurysm repair (TEVAR) is an advantageous alternative to open repair, as it allows prompt exclusion of thoracic aortic fistulas and control of hemorrhage while being minimally invasive. Larger case series of TEVAR for ABF are promising, reporting 100% operative survival and a mortality of 0%–25% at 3 years post-operatively [7,8]. This evidence changes the management algorithm for the ABF diagnosis and now TEVAR should be considered the standard of care.

Prosthetic graft infection is a significant concern following repair of ABF. During open surgical, antibiotic irrigation is employed intra-operatively, and in some cases the prosthetic graft is soaked in antibiotic solution prior to implantation [3]. Conversely, TEVAR alone does not allow debridement of the potentially contaminated thoracic cavity. That being said, the risk of infection after endograft deployment appears to be minimal. It has been suggested that this low infection rate can be attributed to the fact that there is little tissue associated with graft deployment, as opposed to open surgical repairs, thus the pseudoaneurysmal cavity is likely to become contaminated and subsequently infected. Furthermore, the excluded aneurysmal cavity may still remain

viable after endograft placement from small collateral blood vessels that were not disrupted during repair, thus preventing infection [8].

Our patient had recurrent episodes of hemoptysis for several months prior to a contrast-enhanced CT scan revealing the diagnosis. While the thoracic endograft did successfully exclude the pseudoaneurysm, the delayed diagnosis may increase the chance of endograft infection. Therefore, the current decision is to place the patient on oral antibiotic indefinitely to reduce or suppress the risk of graft infection. Current evaluation at 1 year post-operatively shows no sign of infection.

In summary, the possibility of aortic pseudoaneurysm and ABF should be considered in the differential diagnosis of hemoptysis in a patient with previous history of coarctation repair. TEVAR repair has been shown to be safe and well tolerated, thus should be considered the standard of care. Long-term surveillance and antibiotic prophylaxis of endograft infection should be considered.

References

- [1] A.A. Calderón, B.J. Chinarro, A.A. Fernández, O.I. Navarrete, A.R. Martos, M.J. Moragues, Recurrent hemoptysis secondary to an aortobronchial fistula (English Edition), *Arch. Bronconeumol.* 41 (6) (2005) 352–354.
- [2] A.F. Coelho Júnior, Antônio Amorim de Araújo Filho, Vasconcelos Leitão, João Paulo de, F. Cabral Júnior, Aortobronchopulmonary fistula in the postoperative period of aortic coarctation, *Arq. Bras. Cardiol.* 92 (4) (2009) e50–e52.
- [3] E. Eren, C. Keles, M.E. Toker, S. Ersahin, V. Erentug, M. Guler, et al., Surgical treatment of aortobronchial and aorto-esophageal fistulae due to thoracic aortic aneurysm, *Tex Heart Inst. J.* 32 (4) (2005) 522–528.
- [4] G.V. Knyshov, L.L. Sitar, M.D. Glagola, M.Y. Atamanyuk, Aortic aneurysms at the site of the repair of coarctation of the aorta: a review of 48 patients, *Ann. Thorac. Surg.* 61 (3) (1996) 935–939.
- [5] M. Hamilton, J. Holemans, J. Entwisle, Aortobronchopulmonary fistula after repair of aortic coarctation, *Clin. Radiol.* 59 (11) (2004) 1044–1047.
- [6] H. Posacioglu, A.Z. Apaydin, Pseudoaneurysm and aortobronchial fistula after aortic coarctation repair by patch aortoplasty, *Tex Heart Inst. J.* 31 (3) (2004) 319–321.
- [7] P.J. Riesenman, J.D. Brooks, M.A. Farber, Thoracic endovascular aortic repair of aortobronchial fistulas, *J. Vasc. Surg.* 50 (5) (2009) 992–998.
- [8] G.H. Wheatley, A. Nunez, O. Preventza, V.G. Ramaiah, J.A. Rodriguez-Lopez, J. Williams, et al., Have we gone too far? Endovascular stent-graft repair of aortobronchial fistulas, *J. Thorac. Cardiovasc Surg.* 133 (5) (2007) 1277–1285.