



## Case Report

# Ulnar nerve paralysis after forearm bone fracture<sup>☆</sup>



Carlos Roberto Schwartzmann<sup>a,b,\*</sup>, Paulo Henrique Ruschel<sup>b</sup>,  
Rodrigo Guimarães Huyer<sup>b</sup>

<sup>a</sup> Universidade Federal de Ciências Saúde de Porto Alegre, Porto Alegre, RS, Brazil

<sup>b</sup> Santa Casa de Porto Alegre, Serviço de Ortopedia e Traumatologia, Porto Alegre, RS, Brazil

### ARTICLE INFO

#### Article history:

Received 19 August 2015

Accepted 22 September 2015

Available online 12 July 2016

#### Keywords:

Ulnar nerve

Forearm injuries

Peripheral nerve injuries

#### Palavras-chave:

Nervo ulnar

Traumatismos do antebraço

Traumatismos dos nervos

periféricos

### ABSTRACT

Paralysis or nerve injury associated with fractures of forearm bones fracture is rare and is more common in exposed fractures with large soft-tissue injuries. Ulnar nerve paralysis is a rare condition associated with closed fractures of the forearm. In most cases, the cause of paralysis is nerve contusion, which evolves with neuropraxia. However, nerve lacerations and entrapment at the fracture site always need to be borne in mind. This becomes more important when neuropraxia appears or worsens after reduction of a closed fracture of the forearm has been completed. The importance of diagnosing this injury and differentiating its features lies in the fact that, depending on the type of lesion, different types of management will be chosen.

© 2016 Sociedade Brasileira de Ortopedia e Traumatologia. Published by Elsevier Editora Ltda. This is an open access article under the CC BY-NC-ND license (<http://creativecommons.org/licenses/by-nc-nd/4.0/>).

### Paralisia do nervo ulnar seguida de fratura dos ossos do antebraço

#### RESUMO

A paralisia ou lesão nervosa associada à fratura dos ossos do antebraço é rara, é mais comum nas fraturas expostas com grande lesão de partes moles. A paralisia do nervo ulnar é uma condição incomum associada a fraturas fechadas do antebraço. Na grande maioria dos casos, a causa da paralisia é a contusão do nervo, que evolui com neuropraxia. No entanto, devemos sempre estar atentos às lacerações do nervo e ao encarceramento do nervo no foco de fratura. Isso se torna mais importante quando ocorre o surgimento da neuropraxia ou pioria após a feitura da redução da fratura fechada do antebraço. A importância do diagnóstico da lesão e diferenciar suas características estão no fato de que, conforme o tipo de lesão, diferentes tipos de manejo serão escolhidos.

© 2016 Sociedade Brasileira de Ortopedia e Traumatologia. Publicado por Elsevier Editora Ltda. Este é um artigo Open Access sob uma licença CC BY-NC-ND (<http://creativecommons.org/licenses/by-nc-nd/4.0/>).

<sup>☆</sup> Study conducted at the Santa Casa de Porto Alegre, Serviço de Ortopedia e Traumatologia, Porto Alegre, RS, Brazil.

\* Corresponding author.

E-mail: [schwartzmann@santacasa.tche.br](mailto:schwartzmann@santacasa.tche.br) (C.R. Schwartzmann).

<http://dx.doi.org/10.1016/j.rboe.2015.09.017>

2255-4971/© 2016 Sociedade Brasileira de Ortopedia e Traumatologia. Published by Elsevier Editora Ltda. This is an open access article under the CC BY-NC-ND license (<http://creativecommons.org/licenses/by-nc-nd/4.0/>).

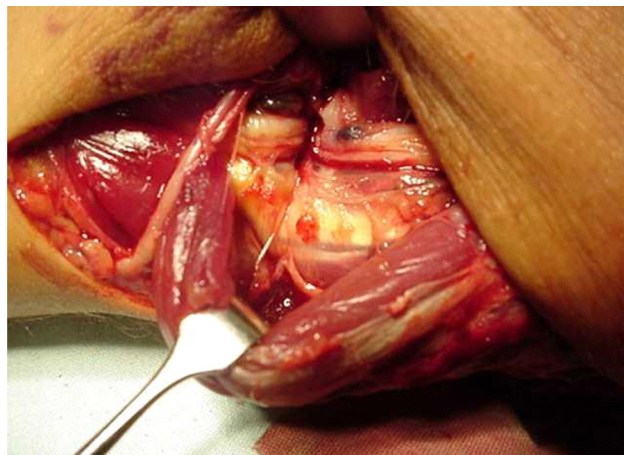
## Introduction

The authors present a case of fracture of both bones of the forearm associated with neuropraxia in the sensitive area of the ulnar nerve, which presented worsening of neurological symptoms after closed reduction of the fracture. Simple nerve injuries should be treated conservatively. Additional tests, such as magnetic resonance imaging (MRI), can be used to diagnose the status of the nerve in case of worsening of neuropraxia. Conversely, surgical exploration of the nerve and fracture fixation should be done in cases of emergency or worsening neuropraxia, especially after closed fracture reduction, associated with suspected nerve laceration or nerve entrapment at the fracture site. Paralysis of the ulnar nerve is an uncommon condition associated with closed fractures of the forearm.<sup>1-3</sup> In most cases, the cause of paralysis is the nerve injury. Nevertheless, orthopedists must always be watchful for lacerations and entrapment. This becomes more important in cases of onset or worsening of neuropraxia after a closed reduction of a forearm fracture. The importance of diagnosing this injury and differentiating its features lies in the fact that, depending on the type of lesion, different types of management will be chosen.<sup>4,5</sup>

## Case report

A male patient, 17, presented to the emergency room with complaint of forearm pain due to a skateboarding fall, functional limitation of the upper limb, and “tingling” of the fifth finger. Radiological examination indicated fracture of both radius and ulna. A closed reduction was performed, followed by immobilization of the fracture (Figs. 1 and 2).

Post-reduction control radiographs showed satisfactory results. However, the patient reported worsening of the tingling sensation in the fifth finger and worsening of sensitivity. Based on the symptoms, ulnar nerve laceration/injury after fracture reduction was suspected. Thus, surgical exploration

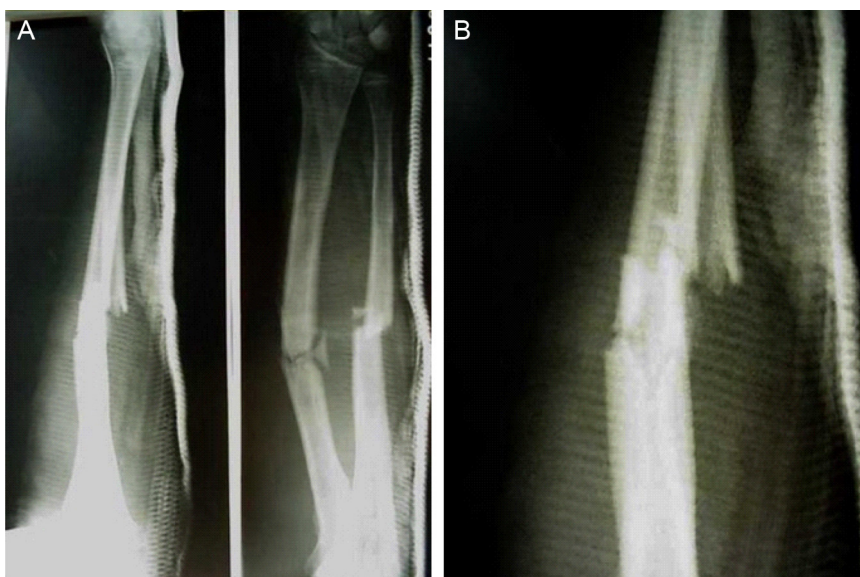


**Fig. 2 – Ulnar nerve entrapment.**

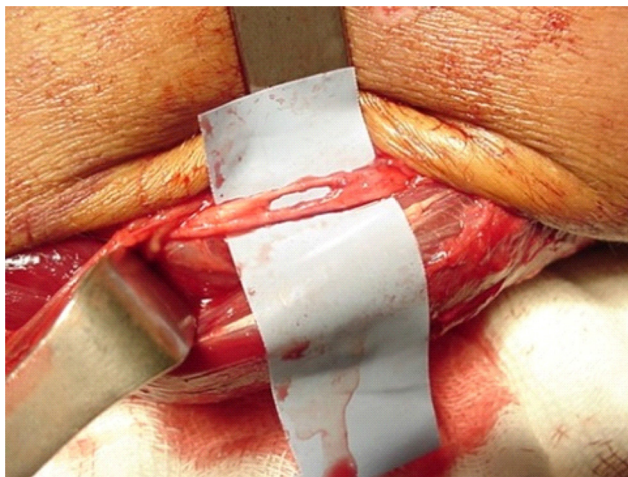
of the nerve was performed, with internal fixation of the forearm fracture. During surgery, after careful dissection, the ulnar nerve was found to be entrapped in the ulnar fracture (Figs. 3 and 4). After careful nerve release and microsurgical suture of the laceration with 8.0 nylon suture, both fractures were fixated with a DCP plate and 3.5-mm screws.

## Discussion

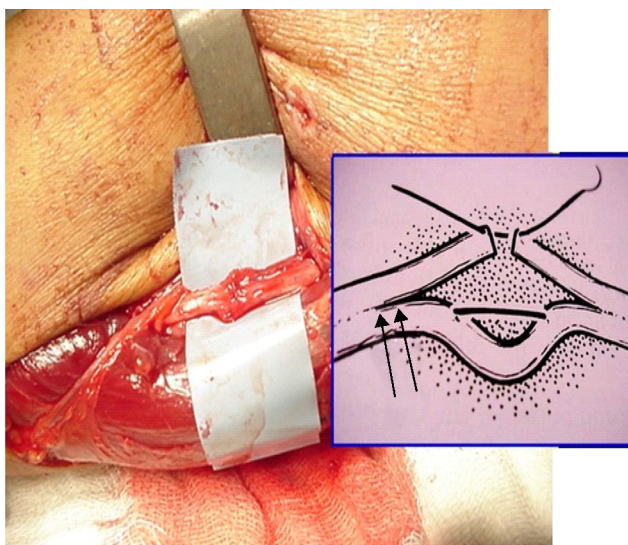
Ulnar nerve injury is a rare complication of closed fractures of the forearm. Few cases have been documented and published. Therapy ranges from conservative treatment and observation of the neuropraxia to nerve exploration, neurolysis, and/or microsurgical repair of injuries.<sup>1,3,5,6</sup> At first evaluation in the emergency room, physical examination and, in particular, careful neurological examination are paramount. It is important to consider compartment syndrome, its association with neurological symptoms, and the sequelae arising from its non-identification, such as Volkmann’s and Finochietto’s ischemic



**Fig. 1 – X-ray after closed reduction of forearm fracture.**



**Fig. 3 – Nerve injury after neurolysis.**



**Fig. 4 – Suture of the ulnar nerve.**

contractures. Specific signs observed after fracture reduction can lead to diagnosis of post-reduction neural entrapment, directing treatment and avoiding paralysis of the affected nerve.<sup>2,3,7</sup>

A nerve injury should always be suspected after worsening of neurological symptoms prior to fracture reduction.

Despite satisfactory reduction and the possibility of conservative treatment if nerve damage is not observed, the management changes; orthopedists should be aggressive and adopt a surgical approach with such patients.<sup>4,6,8</sup> Nerve exploration, neurolysis, microsurgical treatment of the injury if necessary, and internal fixation of the fracture are essential for a favorable outcome, and for complete return of the forearm and hand function after the injury.<sup>2,3</sup>

Ulnar nerve injuries associated with closed forearm fracture are uncommon. When they occur, they are usually associated with a contusion, and the treatment is conservative.<sup>1</sup> It is important to recognize and diagnose the etiology of the lesion. Nerve exploration and fracture fixation should be performed upon suspicion of nerve laceration or entrapment, in order to prevent nerve sequelae; additional tests are not required to indicate surgical procedure.<sup>3,7</sup>

### Conflicts of interest

The authors declare no conflicts of interest.

### REFERENCES

1. Torpey BM, Pess GM, Kircher MT, Faierman E, Absatz MG. Ulnar nerve laceration in a closed both bone forearm fracture. *J Orthop Trauma*. 1996;10(2):131-4.
2. Pai VS. Injury of the ulnar nerve associated with fracture of the ulna: a case report. *J Orthop Surg (Hong Kong)*. 1999;7(1):73-5.
3. Amit B, Ashish D, Vinit V, Raj S, Shivani B, Narender M, et al. Missed ulnar nerve injury and closed forearm fracture in a child. *Chin J Traumatol*. 2013;16(4):246-8.
4. Stahl S, Rozen N, Michaelson M. Ulnar nerve injury following midshaft forearm fractures in children. *J Hand Surg Br*. 1997;22(6):788-9.
5. Hirasawa H, Sakai A, Toba N, Kamiuttanai M, Nakamura T, Tanaka K. Bony entrapment of ulnar nerve after closed forearm fracture: a case report. *J Orthop Surg (Hong Kong)*. 2004;12(1):122-5.
6. Prosser AJ, Hooper G. Entrapment of the ulnar nerve in a greenstick fracture of the ulna. *J Hand Surg Br*. 1986;11(2):211-2.
7. Suganuma S, Tada K, Hayashi H, Segawa T, Tsuchiya H. Ulnar nerve palsy associated with closed midshaft forearm fractures. *Orthopedics*. 2012;35(11):e1680-3.
8. Neiman R, Maiocco B, Deeney VF. Ulnar nerve injury after closed forearm fractures in children. *J Pediatr Orthop*. 1998;18(5):683-5.