

Available online at [www.sciencedirect.com](http://www.sciencedirect.com)

ScienceDirect

Journal of the Chinese Medical Association 77 (2014) 163–165

[www.jcma-online.com](http://www.jcma-online.com)

## Case Report

## Use of sonography in assessing elbow medial collateral ligament injury after arm wrestling

Yuh-Shan Lee<sup>a</sup>, Yi-Hong Chou<sup>b,c,d</sup>, Hong-Jen Chiou<sup>b,c,d,\*</sup>, Yi-Chen Lai<sup>b,c,d</sup><sup>a</sup>Department of Rehabilitation, Keelung City Municipal Hospital, Keelung, Taiwan, ROC<sup>b</sup>Department of Radiology, Taipei Veterans General Hospital, Taipei, Taiwan, ROC<sup>c</sup>National Yang-Ming University School of Medicine, Taipei, Taiwan, ROC<sup>d</sup>National Defense Medical Center, Taipei, Taiwan, ROC

Received November 2, 2011; accepted June 4, 2012

## Abstract

Medial collateral ligament injury is an infrequent occurrence in arm wrestlers. We report here a male patient who injured his left elbow while arm wrestling. Ultrasonography showed a medial collateral ligament tear. We assessed both elbows using ultrasonography at his 3-year follow-up visit. Dynamic ultrasonography showed a decreased gap at the ulnotrochlear joint space in his left elbow. A medial collateral ligament tear in his right elbow was also evident using ultrasonography. This case report shows the advantages of ultrasonography, especially dynamic ultrasonography, in the evaluation of elbow injury. Ultrasonography provides more information than valgus stress radiography, arthrography, and magnetic resonance imaging in the assessment of medial collateral ligament injury. In addition, the contralateral side can readily be assessed for comparison during ultrasonography.

Copyright © 2013 Elsevier Taiwan LLC and the Chinese Medical Association. All rights reserved.

**Keywords:** arm wrestling; medial collateral ligament injury; sonography

## 1. Introduction

Baseball pitching is the most common cause of medial collateral ligament (MCL) injury, which is caused by repetitive stress during throwing. The condition occurs less frequently in other athletes such as javelin throwers, handball players, arm wrestlers, and tennis players.<sup>1–3</sup> We report here the case of an arm wrestler with an MCL injury diagnosed using dynamic ultrasonography (US).

## 2. Case report

A 58-year-old man injured his left elbow while arm wrestling. He heard a popping sound, which was followed by the

development of local redness, swelling, heat, and pain. The day after his injury, he presented at our orthopedic department and was referred for an ultrasound scan of his elbow. Ultrasonic examination was performed using L12-5 linear transducers of 5–12 MHz frequency (Philips-ATL IU22; Bothell, WA, USA) and 14L5 linear transducers of 5–14 MHz frequency (Siemens S2000; Mountain View, CA, USA). Ultrasonography at rest showed widening of the ulnotrochlear joint space (Fig. 1A). Dynamic US showed a defect in the left MCL with surrounding fat herniation into the joint space. During a valgus stress test with an abduction force of the left elbow, the joint space was increased to 6.3 mm. Some echogenic fat (heterogeneous hyperechogenicity) herniation into the left elbow joint was also noted with US (Fig. 1B).

Follow-up dynamic US with valgus stress to assess the elbow was carried out 3 years after the injury (Fig. 2A and B); some granulation tissue (heterogeneous hyperechogenicity in the previous MCL tear) was noted in the MCL region, but the laxity of the left elbow persisted. The left ulnotrochlear joint space was 4 mm in width. In contrast, the right elbow showed

Conflicts of interest: The authors declare that there are no conflicts of interest related to the subject matter or materials discussed in this article.

\* Corresponding author. Dr. Hong-Jen Chiou, Department of Radiology, Taipei Veterans General Hospital, 201, Section 2, Shih-Pai Road, Taipei 112, Taiwan, ROC.

E-mail address: [hjchiou@vghtpe.gov.tw](mailto:hjchiou@vghtpe.gov.tw) (H.-J. Chiou).

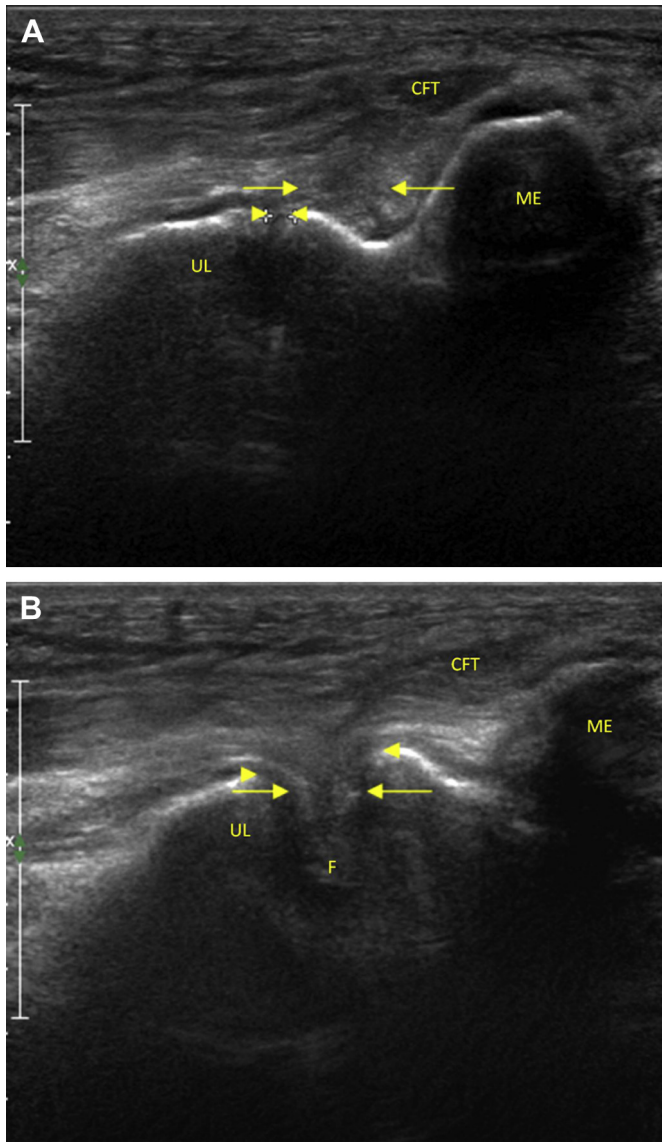


Fig. 1. Initial coronal ultrasound scan through the medial aspect of the elbow. (A) At rest, the elbow joint shows a small area of heterogeneous hypoechogenicity in the medial collateral ligament (arrows). The joint space was 2.3 mm (arrowheads). (B) Under valgus stress, the elbow joint shows some echogenic fat (heterogeneous hyperechogenicity) (arrows) herniated into the joint with widening of the joint space. The joint space was increased to 6.3 mm (between arrowheads). CFT = common flexor tendon; F = fat herniation; ME = medial epicondyle; UL = ulnar bone.

an ulnotrochlear joint space 2 mm in width, with joint space gapping of 2.8 mm. The right joint space increased under valgus stress to 4.8 mm in width, which was less than that of the left elbow. The joint space gapping was increased under valgus stress to a joint space of 5.5 mm and a tear of the MCL of the right elbow was also considered.

Our patient received conservative treatment, including local cooling or heating and rest, as suggested by other workers.<sup>4</sup> Our follow-up physical examination and US 3 years after the injury showed that the patient's muscle power and activities of daily life were very well preserved, returning to normal status following wound healing and training of the muscles

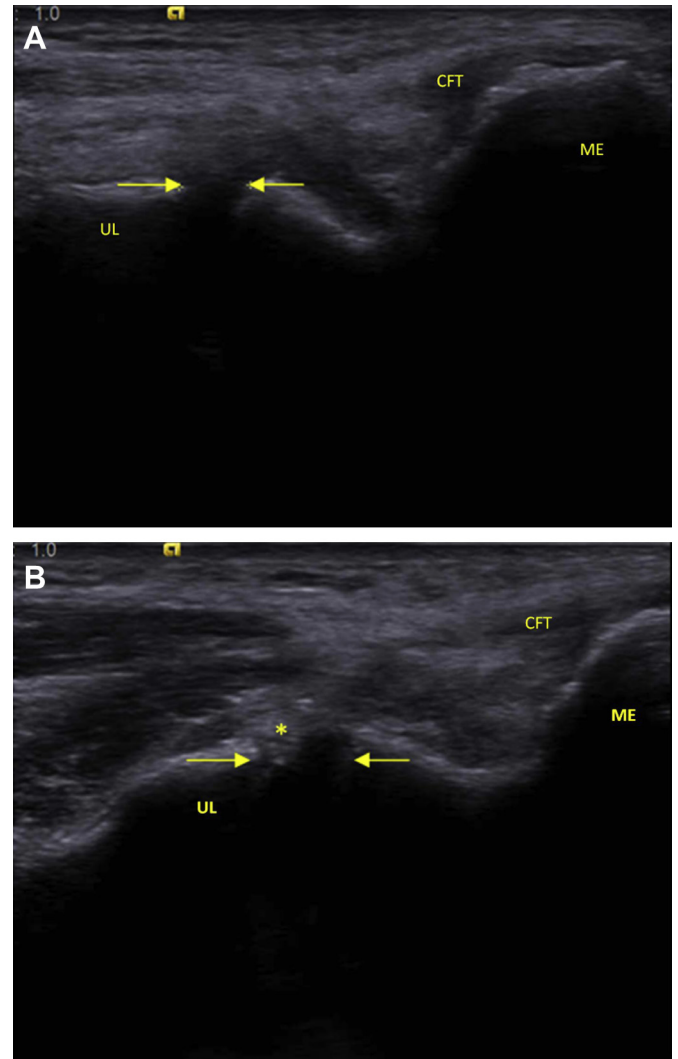


Fig. 2. Follow-up coronal ultrasound scan 3 years later, scanning through the medial aspect of the elbow. (A) At rest, the left elbow shows the left medial collateral ligament with a joint space of 4.0 mm (arrows). (B) Under valgus stress the left elbow shows widening of the elbow joint to a width of 5.5 mm (between arrows). Heterogeneous hyperechogenicity (granulation tissue) in the area of the previous medial collateral ligament tear (star). CFT = common flexor tendon; ME = medial epicondyle; UL = ulnar bone.

around the MCL for compensation. However, laxity of the elbow persisted. An MCL tear was still diagnosed, but healing had occurred with less joint space gapping after valgus stress.

### 3. Discussion

In human anatomy, the elbow is more supported by ligaments on the medial side than on the lateral side. It is therefore easier to experience valgus stress during many activities, which may result in MCL injury.<sup>5</sup>

The MCL is the major ligament involved in elbow joint stability. It has two functional components, namely, the anterior oblique and the posterior oblique ligaments; the former is the mainstay of elbow joint stability.<sup>5</sup> Based on the location

(the anterior oblique component inserting onto the medial coronoid process of ulnar bone and originating from the inferior aspect of the medial epicondyle of the humerus), our patient showed an injury of the anterior oblique component of the MCL, resulting in laxity of the left elbow. Symptoms of MCL injury include local redness, swelling, heat, and pain, with or without a popping sound when the injury occurs. Physical examination of our patient showed signs of inflammation, including local redness, swelling, heat, and pain, as well as laxity of the affected elbow.

Ultrasonography is a useful imaging modality to evaluate elbows with possible MCL injury, as it may show the torn component of the MCL. Moreover, dynamic US with valgus stress may uniquely demonstrate medial joint instability,<sup>6</sup> as observed in our patient. Dynamic US of the elbow can be used to assess medial elbow laxity by quantifying the medial elbow joint space under valgus stress.<sup>6–8</sup> Elbow valgus stress radiography has been used in the diagnosis of laxity of the medial elbow structures.<sup>9,10</sup> Rijke et al reported that stress radiography could detect ulnohumeral joint gapping under valgus stress (using a Telos GA-III stress device for the application of a valgus force of 15 daN to the lateral aspect of the elbow joint).<sup>9</sup> Ultrasonography, which is noninvasive, uses nonionizing radiation, is easily available, and is portable, is a good alternative modality for surveying laxity of the elbow. The width of the ulnotrochlear joint space can be determined by measuring the distance between the distal-medial corner of the trochlear portion and the proximal edge of the medial tubercular portion of the coronoid process. Our patient initially presented with an MCL tear in the left elbow and, at the 3-year follow-up ultrasound examination, an MCL tear in the right elbow was also suspected. Interestingly, resting US did not show signs of an MCL tear, whereas the tear was evident with a dynamic US study. Dynamic US is therefore indispensable in the evaluation of elbow injuries.

As a result of advanced technologies and state-of-the-art equipment, US can offer dynamically focused higher resolution real-time imaging of soft tissues, including skin, subcutaneous tissues, nerves, blood vessels, tendons, and ligaments. Advantages include its safety (nonionizing radiation), accessibility, speed, comfort, and cost-effectiveness. Another unique advantage of US is its use in dynamic applications. In addition, it is easy to assess the contralateral side for comparison using US.<sup>11</sup>

Because the anterior oblique component of the MCL in the elbow is the mainstay of joint stability, assessment of the anterior oblique component is particularly important in patients with a possible MCL injury. Both arthrography and US may be useful for the diagnosis of MCL injury, as both these techniques can be used to assess the deep capsular layer of the anterior bundle of the MCL.<sup>12</sup> However, arthrography is somewhat invasive, as it requires puncture and the injection of contrast into the joint space. High-resolution US, however, provides a fast and noninvasive assessment of the MCL.

The two best modalities for the assessment of soft tissues are magnetic resonance imaging (MRI) and US. Kijowski and De Smet<sup>13</sup> reported that the most obvious advantage of MRI is

its usefulness for the assessment of all tissues, including joints, bones, and soft tissues, in multiple planes during one examination. The disadvantages of MRI are its longer examination time and higher cost; furthermore, MRI is contraindicated in some patients, including those with implanted devices and claustrophobia. The advantages of US are its higher resolution of superficial structures such as tendons, vessels, and nerves and its dynamic application for the assessment of, for example, intermittent muscle or fascial herniation and intermittent tendon or nerve subluxation. Its main disadvantages are its inability to assess deep soft tissues and bones, as well as variable operator-dependent characteristics.

In conclusion, US is a highly useful imaging modality for the assessment of elbow MCL injury. Dynamic US can be used to assess certain conditions such as intermittent fascial or muscle herniation, and is an indispensable technique in the evaluation of elbow injury.

### Acknowledgments

The authors express their gratitude to Ms Chih-Ping Chiu, Ms Ting-Yu Pan, and Ms Shao-Ling Huang for their excellent clerical assistance.

### References

- Chen FS, Rokito AS, Jobe FW. Medial elbow problems in the overhead-throwing athlete. *J Am Acad Orthop Surg* 2001;**9**:99–113.
- Azar FM, Andrews JR, Wilk KE, Groh D. Operative treatment of ulnar collateral ligament injuries of the elbow in athletes. *Am J Sports Med* 2000;**28**:16–23.
- Hyman J, Breazeale NM, Altchek DW. Valgus instability of the elbow in athletes. *Clin Sports Med* 2001;**20**:25–45.
- Hariri S, Safran MR. Ulnar collateral ligament injury in the overhead athlete. *Clin Sports Med* 2010;**29**:619–44.
- Schwab GH, Bennett JB, Woods GW, Tullos HS. Biomechanics of elbow instability: the role of the medial collateral ligament. *Clin Orthop Relat Res* 1980;**146**:42–52.
- De Smet AA, Winter TC, Best TM, Bernhardt DT. Dynamic sonography with valgus stress to assess elbow ulnar collateral ligament injury in baseball pitchers. *Skeletal Radiol* 2002;**31**:671–6.
- Sasaki J, Takahara M, Ogino T, Kashiwa H, Ishigaki D, Kanauchi Y. Ultrasonographic assessment of the ulnar collateral ligament and medial elbow laxity in college baseball players. *J Bone Joint Surg Am* 2002;**84**:525–31.
- Nazarian LN, McShane JM, Ciccotti MG, O’Kane PL, Harwood ML. Dynamic US of the anterior band of the ulnar collateral ligament of the elbow in asymptomatic Major League Baseball pitchers. *Radiology* 2003;**227**:149–54.
- Rijke AM, Goitz HT, McCue FC, Andrews JR, Berr SS. Stress radiography of the medial elbow ligaments. *Radiology* 1994;**191**:213–6.
- Ellenbecker TS, Mattalino AJ, Elam EA, Caplinger RA. Medial elbow joint laxity in professional baseball pitchers: a bilateral comparison using stress radiography. *Am J Sports Med* 1998;**26**:420–4.
- Lee KS, Rosas HG, Craig JG. Musculoskeletal ultrasound: elbow imaging and procedures. *Semin Musculoskelet Radiol* 2010;**14**:449–60.
- Timmerman LA, Schwartz ML, Andrews JR. Preoperative evaluation of the ulnar collateral ligament by magnetic resonance imaging and computed tomography arthrography: evaluation in 25 baseball players with surgical confirmation. *Am J Sports Med* 1994;**22**:26–31.
- Kijowski R, De Smet AA. The role of ultrasound in the evaluation of sports medicine injuries of the upper extremity. *Clin Sports Med* 2006;**25**:569–90.