



ENDOSCOPIC SPOT

Tubular adenoma of the appendix: An unusual condition

Adenoma Tubular do Apêndice: um caso raro

Joana Machado*, António Castanheira, Paula Ministro, Ricardo Araújo, Eugénia Cancela, Américo Silva

Serviço de Gastrenterologia, Centro Hospitalar Tondela-Viseu EPE, Viseu, Portugal

Received 1 November 2012; accepted 4 December 2012

Available online 29 July 2013

The authors report a case of a 62-year-old woman who underwent colonoscopy in our department as a routine examination for colorectal cancer screening. Clinical history and physical examination were unremarkable. During cecal observation a polypoid structure with 15 mm protruded from the appendicular orifice. The polyp was pulled to the lumen and resected using a diathermic snare (Figs. 1 and 2). The remaining colon and rectum did not present any lesion. Histopathological examination was compatible with tubular adenoma (Fig. 3).

Appendicular benign polyps are a rare condition. The majority of them were found in appendectomy or necropsy specimens. The most frequent type is mucinous cystadenoma followed by villous adenoma.^{1,2}

A retrospective clinicopathologic analysis of 7970 appendectomies found 74 appendiceal tumors (incidence, 0.9%). Twelve (16%) of 74 tumors were benign, 7 mucinous cystadenomas and 5 villous adenomas.³

Another retrospective study that included 184 patients with appendiceal noncarcinoid epithelial tumors and tumor-like lesions found 43 adenomas but only one showed to be a tubular adenoma. It occurred in a 6-year-old boy who received a proctocolectomy for adenomatosis coli.⁴

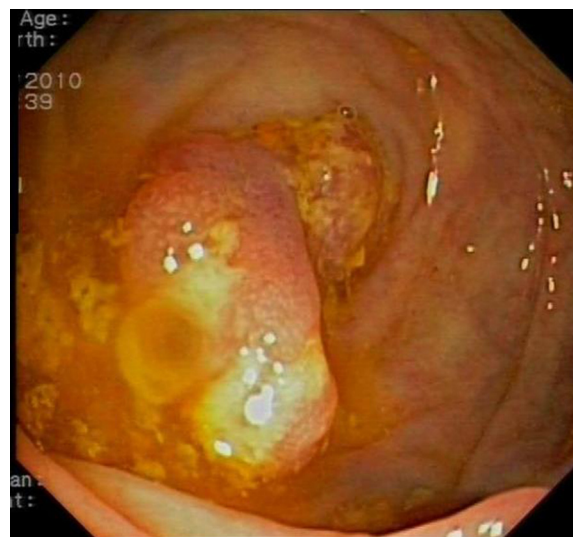


Figure 1 Polyp protruding from the appendicular orifice.

Tubular adenomas of the appendix have been reported in the literature as isolated case reports and represent a rare finding in appendectomy and necropsy series. As this is a very unusual condition, the optimal management of these patients is not defined.

* Corresponding author.

E-mail address: jvmachado@hotmail.com (J. Machado).

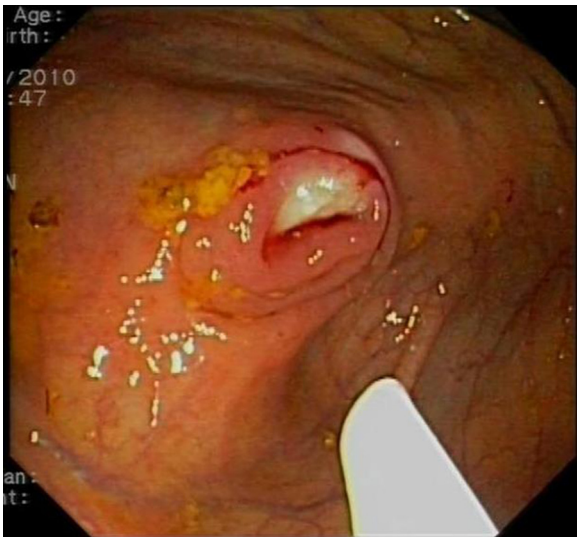

Figure 2 Appendicular orifice after resection of the polyp.

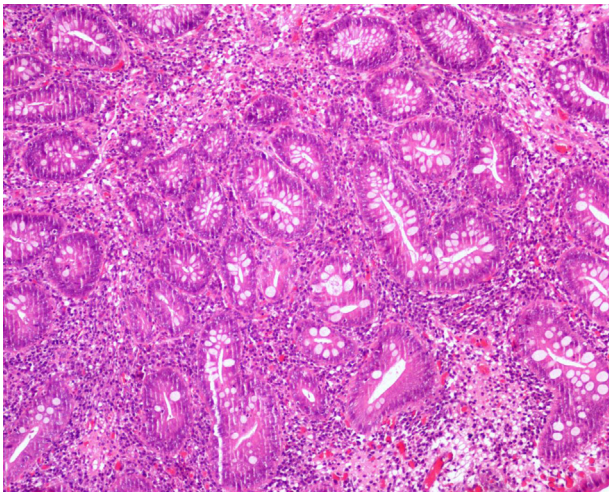


Figure 3 Tubular adenoma with low grade dysplasia (hematoxylin and eosin stain 400 \times).

The malignant potential of appendiceal adenoma is not well documented, but the lesion appears to have the same biologic behavior as the adenoma in other parts of the colon and rectum. Moreover, synchronous or metachronous neoplasms elsewhere in the large intestine have been reported.¹

Khan et al. hypothesized that patients with colorectal cancer might have a similar risk of synchronous and metachronous appendiceal tumors to that of the colon and rectum. They studied 169 patients who underwent surgery for colorectal cancer. The appendix was part

of the specimen in patients having right hemicolectomy and was removed separately in patients undergoing left hemicolectomy or rectal resection. Seven patients (4.1%) had epithelial appendiceal tumors. Since the appendiceal mucosa is inaccessible to postoperative surveillance after colorectal cancer resection, they propose routine addition of appendectomy in surgery for colorectal cancer to remove synchronous lesions and to eliminate the possibility of metachronous appendiceal neoplasia.⁵

After discussing the clinical situation with the patient, an elective appendectomy was performed and no residual lesion was found. Colonoscopy will be scheduled according to colorectal cancer surveillance program.

Ethical disclosures

Protection of human and animal subjects. The authors declare that no experiments were performed on humans or animals for this study.

Confidentiality of data. The authors declare that they have followed the protocols of their work center on the publication of patient data and that all the patients included in the study received sufficient information and gave their written informed consent to participate in the study.

Right to privacy and informed consent. The authors have obtained the written informed consent of the patients or subjects mentioned in the article. The corresponding author is in possession of this document.

Conflicts of interest

The authors have no conflicts of interest to declare.

References

1. Wolf M, Ahmed N. Epithelial neoplasm of the vermiform appendix (exclusive of carcinoid). *Cancer*. 1976;37:2511–22.
2. Williams G, du Bouly C, Roche W. Benign epithelial neoplasm of the appendix: classification and clinical associations. *Histopathology*. 1992;21:447–51.
3. Connor SJ, Hanna GB, Frizelle FA. Appendiceal tumors: retrospective clinicopathologic analysis of appendiceal tumors from 7,970 appendectomies. *Dis Colon Rectum*. 1998;41:75–80.
4. Carr NJ, McCarthy WF, Sobin LH. Epithelial noncarcinoid tumors and tumor-like lesions of the appendix. A clinicopathologic study of 184 patients with a multivariate analysis of prognostic factors. *Cancer*. 1995;75:757–68.
5. Khan MN, Moran BJ. Four percent of patients undergoing colorectal cancer surgery may have synchronous appendiceal neoplasia. *Dis Colon Rectum*. 2007;50:1856–9.