

Case Report

Steroid-induced central serous chorioretinopathy in a patient with non-arteritic anterior ischemic optic neuropathy



Zeynep Alkin; Ihsan Yilmaz*; Abdullah Ozkaya; Ahmet Taylan Yazici

Abstract

Non-arteritic anterior ischemic optic neuropathy is a result of an infarction of the small vessel at the anterior portion of the optic disc and causes acute, unilateral, painless visual loss. There is no generally accepted treatment method for this condition but some medical and surgical treatments are recommended. Earlier studies show that visual acuity recovery was better with corticosteroid medication compared to non-treated patients. However corticosteroids may cause side effects such as cataract, increased intraocular pressure and rarely central serous chorioretinopathy. This case report presents a patient with central serous chorioretinopathy secondary to corticosteroid medication.

Keywords: Ischemic optic neuropathy, Central serous chorioretinopathy, Corticosteroid

© 2015 The Authors. Production and hosting by Elsevier B.V. on behalf of Saudi Ophthalmological Society, King Saud University. This is an open access article under the CC BY-NC-ND license (<http://creativecommons.org/licenses/by-nc-nd/4.0/>). <http://dx.doi.org/10.1016/j.sjopt.2015.01.002>

Introduction

Corticosteroid medication for treatment of non-arteritic anterior ischemic optic neuropathy is controversial. It may cause a central serous chorioretinopathy (CSCR) and threaten the patients' visual acuity. As a treatment cutting of the corticosteroid medication should be advised. This case reports a 54-year-old male with CSCR secondary to corticosteroid medication which is used for treating patients' non-arteritic anterior ischemic optic neuropathy (NAION). The corticosteroid treatment induced central serous chorioretinopathy in patients' healthy eye and reduced visual acuity.^{1–4} The corticosteroid treatment was stopped. Two months after that visual acuity turned back to normal and central serous chorioretinopathy disappeared.

Case report

A 54-year-old male was referred to us with decreased visual acuity in his right eye (RE). The best-corrected visual

acuity (BCVA) was 0.05 in RE and 0.8 in left eye (LE). Ocular history was unremarkable. The patient had a systemic hypertension which was under control medically. Slit lamp examinations of anterior segment were normal in both eyes. Intraocular pressure (IOP) measurements were performed via Goldmann applanation tonometer and IOP was 14 mmHg in RE, 13 mmHg in LE. Relative afferent pupillary defect was present in RE. Dilated fundus examination revealed splinter hemorrhages and edema at the optic discs in RE. Fundus examination was normal in LE. Perimetry was performed via Humphrey 30–2 threshold test and there was a lower altitudinal visual field defect in RE. Fundus fluorescein angiography (FA) showed hyperfluorescence at the optic disc in RE and normal angiographic findings in LE (Fig. 1a and b). Optic disc appearance, visual fields, FA and optical coherence tomography of discs were suggestive of non-arteritic anterior ischemic optic neuropathy (NA-NAION) in RE. Patient was diagnosed with NA-AION and methylprednisolone was administered with a dose of 1 gr/day intravenously for 3 days. Then, steroid treatment continued with 1 mg/kg/day orally for a week.

Received 5 November 2014; received in revised form 10 December 2014; accepted 14 January 2015; available online 21 January 2015.

Beyoglu Eye Training and Research Hospital, Istanbul, Turkey

* Corresponding author at: Bereketzade Cami Sokak No: 2, Beyoglu, Istanbul, Turkey. Tel.: +90 532 345 59 72. e-mail address: ihsanyilmaz.dr@gmail.com (I. Yilmaz).



Peer review under responsibility of Saudi Ophthalmological Society, King Saud University



Production and hosting by Elsevier

Access this article online: www.saudiophthaljournal.com www.sciencedirect.com

Six days after initiating the corticosteroid treatment, the patient complained decreased visual acuity in his LE. BCVA was 0.05 in RE and 0.1 in LE. Relative afferent pupillary defect was still present in RE. Anterior segment and IOP measurements were normal in both eyes. Fundus examination showed decreased edema at the optic disc in RE. Additionally, there was an elevation in the macula in LE. Late-phase FA demonstrated granular hyperfluorescence just located nasally to the fovea surrounded by serous detachment in LE in addition to decreased hyperfluorescence at the optic disc in RE (Fig. 2a and b). Indocyanine green angiography (ICG) showed focal hyperfluorescence in mid-phase at the same location as in FA in LE (Fig. 2c). Spectral-domain optical coherence tomography revealed subretinal fluid in the macula in LE (Fig. 3). Central macular thickness (CMT) was 610 μm . The patient was diagnosed with acute CSC.

After the patient diagnosed steroid-induced CSCR, corticosteroid treatment was stopped abruptly. One month later, BCVA was 0.5 in LE. CMT was decreased to 414 μm in LE. Two months after the cessation of corticosteroid treatment, BCVA improved to 0.8 in LE and 0.1 in RE. There was no subretinal fluid and CMT was 279 μm in LE (Fig. 4).

Discussion

Central serous chorioretinopathy is characterized by serous detachment of the neurosensory retina due to defect in the retinal pigment epithelium.^{1,2} CSCR most commonly affects males between 20 and 50 years. Early studies showed that CSCR is related to psychological stress, endogenous hypercortisolism and use of corticosteroid medicines.³ It has been shown that corticosteroid treatment given through various routes such as oral, inhaled, epidural, intra-articular may cause CSCR.⁴ Exact mechanism for steroid induced CSCR has not been fully understood yet; however, it may result from inhibition of collagen synthase, increasing permeability of choroidal capillary, and dysfunction of ionic pump in the retina pigment epithelium.^{5,6}

Earlier studies showed that many CSCR may resolve spontaneously and just observational therapy was needed for 3–4 months.⁷ Some of CSCR cases may resolve with the successful treatment of underlying pathology or mechanism.⁸ Vayalambone et al. reported a 32-year-old Afro-Caribbean male patients with multi-focal CSCR secondary to latent tuberculosis. After the empiric antituberculous therapy, the patient had a significant visual improvement with resolution of the serous detachment.⁸ Similarly, in our patient after

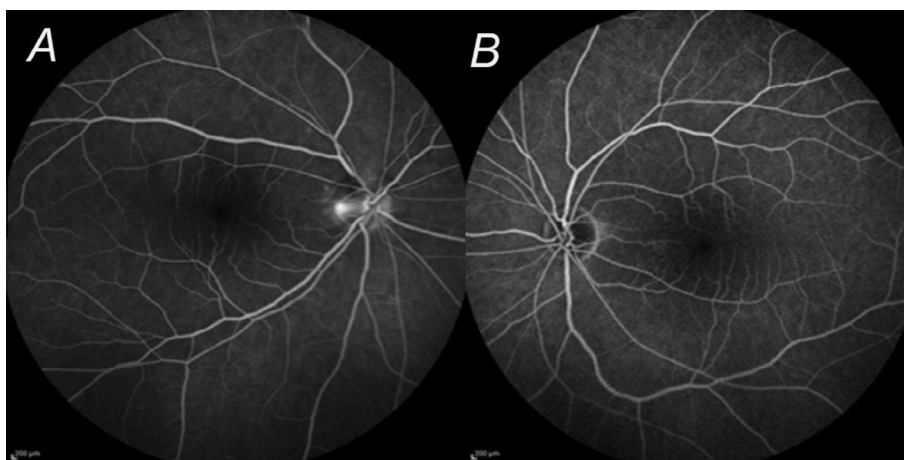


Figure 1. Fundus fluorescein angiogram of both eyes (a, b). A hyperfluorescence at the inferior half of the optic disc in RE (a) and normal angiogram in LE (b).

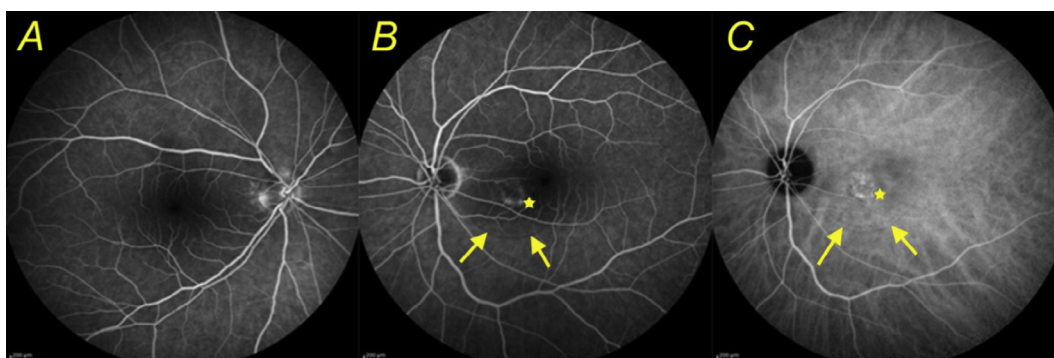


Figure 2. Fundus fluorescein angiography scans showed decreased hyperfluorescence at the inferior half of the optic disc in RE (a) and a central serous chorioretinopathy in LE (b). Arrow indicates the border of the pigment epithelial detachment and star indicates hyperfluorescence spots. Indocyanine green angiography scans showed focal hyperfluorescence coherent to fundus fluorescein angiography scan in LE (4c).

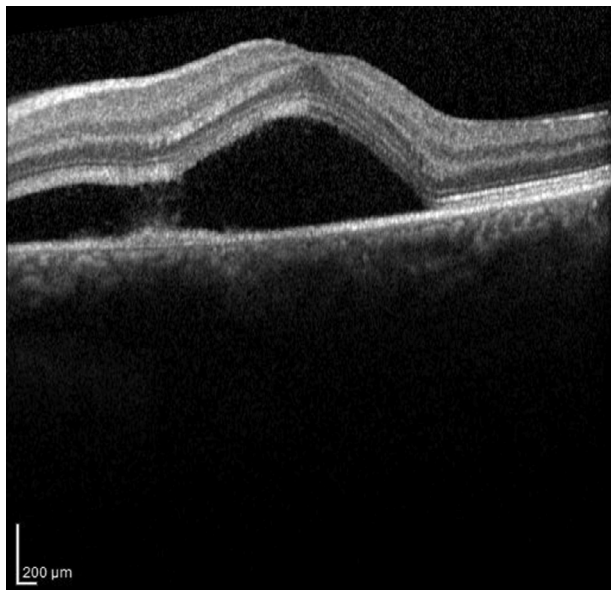


Figure 3. Spectral domain optical coherence tomography shows serous macular detachment as hyporeflective space between neurosensory retina and RPE in LE.

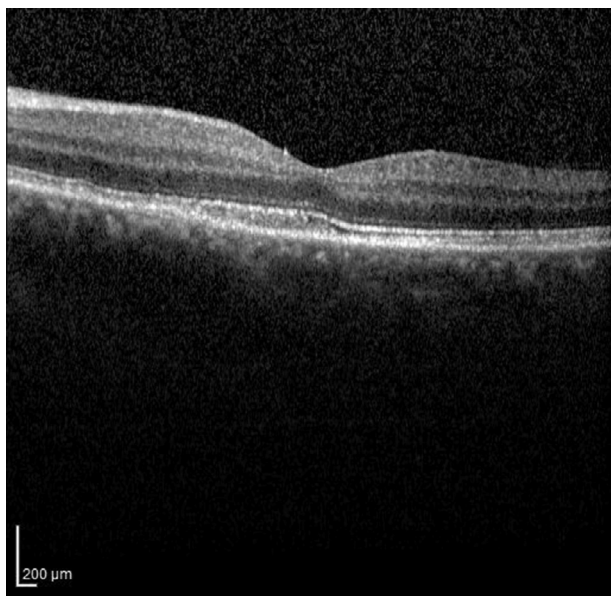

Figure 4. Spectral-domain optical coherence tomography scans two months after the corticosteroid treatment were stopped. The CSCR was resolved.

stopping underlying mechanism, which was a corticosteroid used, CSCR was resolved. After two months from stopping corticosteroid treatment visual acuity backed to 0.8 in LE, which was the same with patient's previous visual acuity.

There were similar results reported in the literature.^{9,10} Shah et al reported a 24 year-old male with CSCR secondary to prednisolone (60 mg/day) for treating left sided facial palsy.⁹ The dose of prednisolone was reduced to 40 mg and used for seven days then stopped.⁹ They reported that

visual disturbances abated gradually within one week after prednisolone was withdrawn.⁹ Loo et al. reported 3 patients with CSCR secondary to corticosteroid medication for different diseases.¹⁰ They reported that two of those cases resolved with tapering of corticosteroids and one case was treated by focal laser photocoagulation.¹⁰ There are still some CSCR cases may not improve on conventional observational approach. Photodynamic therapy may be used for these cases.¹¹ Shibata et al. used photodynamic therapy for treating two patients with CSCR and they reported that successful results were achieved.¹¹

There are new approaches for the treatment of NAION such as local steroid application.¹² As systemic steroid might trigger CSCR in the fellow healthy eye as presented, local (intravitreal) steroid application for the diseased eye would have been more appropriate.¹²

Conclusion

This case showed that systemic corticosteroid treatment may cause visual acuity loss due to CSCR and stopping the corticosteroid administration may be appropriate treatment.

Conflict of interest

The authors declared that there is no conflict of interest.

References

- Grixti A, Kumar V. Steroid induced central serous chorioretinopathy in giant cell arteritis. *Case Rep Ophthalmol Med* 2013;**2013**:924037.
- Fardin B, Weissgold DJ. Central serous chorioretinopathy after inhaled steroid use for post-mycoplasmal bronchospasm. *Br J Ophthalmol* 2002;**86**(9):1065–6.
- Tsai DC, Chen SJ, Huang CC, Chou P, Chung CM, Huang PH, et al. Epidemiology of idiopathic central serous chorioretinopathy in Taiwan, 2001–2006: a population-based study. *PLoS One* 2013;**8**(6): e66858.
- Balakrishnan S, Apsingi S, Manjure SB. Sudden loss of visual acuity following intra-articular steroid injection in to the knee joint: a case report. *Cases J* 2008;**1**:428.
- Cassel GH, Brown GC, Annesley WH. Central serous chorioretinopathy: a seasonal variation? *Br J Ophthalmol* 1984;**68**: 724–6.
- Siaudvytyte L, Diliene V, Miniauskiene G, Balciuniene VJ. Photodynamic therapy and central serous chorioretinopathy. *Med Hypothesis Discov Innov Ophthalmol* 2012;**1**(4):67–71.
- Ponce CM, Mohidat HM, Garcia CA. Central serous chorioretinopathy after blunt trauma. *BMJ Case Rep* 2012. <http://dx.doi.org/10.1136/bcr.01.2012.5626>.
- Vayalambrone D, Ivanova T, Misra A. Atypical central serous retinopathy in a patient with latent tuberculosis. *BMJ Case Rep* 2012. <http://dx.doi.org/10.1136/bcr.11.2011.5231>.
- Shah SP, Desai CK, Desai MK, Dikshit RK. Steroid-induced central serous retinopathy. *Indian J Pharmacol* 2011;**43**(5):607–8.
- Loo JL, Lee SY, Ang CL. Can long-term corticosteroids lead to blindness? A case series of central serous chorioretinopathy induced by corticosteroids. *Ann Acad Med Singapore* 2006;**35**:496–9.
- Shibata A, Ohkuma Y, Hayashi T, Tsuneoka H. Efficacy of reduced-fluence photodynamic therapy for serous retinal pigment epithelial detachment with choroidal hyperpermeability. *Clin Ophthalmol* 2013;**7**:2123–6.
- Alten F, Clemens CR, Heiduschka P, Eter N. Intravitreal dexamethasone implant Ozurdex for the treatment of nonarteritic anterior ischaemic optic neuropathy. *Doc Ophthalmol* 2014;**129**(3): 203–7.