

HOSTED BY



ELSEVIER

Available online at [www.sciencedirect.com](http://www.sciencedirect.com)

ScienceDirect

journal homepage: <http://ees.elsevier.com/ejbas/default.asp>

CrossMark

## Full Length Article

**Relation of cytokeratin 18-Apoptosense M30 to activity and fibrosis in chronic HCV patients****Walid Ahmed El-Sherbiny<sup>a,\*</sup>, Raghda El-Sayed Farag<sup>a</sup>,  
Azza Abd El-Baky El-Baiomy<sup>b</sup>, Rania Ahmed El-Erian<sup>a</sup>**<sup>a</sup> Mansoura Faculty of Medicine, Tropical Medicine Department, Egypt<sup>b</sup> Mansoura Faculty of Medicine, Clinical Pathology Department, Egypt

## ARTICLE INFO

## Article history:

Received 3 February 2015

Received in revised form

20 April 2015

Accepted 28 April 2015

Available online 20 May 2015

## Keywords:

HCV

Serum CK18-M30

Liver fibrosis

METAVIR score

## ABSTRACT

Hepatitis C virus (HCV) is a progressive disease that may result in Chronic active hepatitis, cirrhosis, and hepatocellular carcinoma. Cytokeratin(CK)18 is an intermediary filament protein, expressed in hepatocytes, which is proteolytically cleaved during liver damage. M30 epitope of cytokeratin18(CK18-M30) is involved at different levels in apoptotic pathways. The aim of this study to investigate the diagnostic accuracy of cytokeratin 18-apoptosin M30 fragments (CK18-M30) as non-invasive method of liver fibrosis assessment and their correlation to METAVIR score. Serum concentrations of CK18-M30 were measured by ELISA in One hundred and sixty eight chronic hepatitis C patients (112 males and 56 females). Results showed that serum concentrations of CK18 were significantly increased in a stepwise fashion from A0 to A3 and from F0 to F4. There was highly significant positive correlation between CK18 and fibrosis stages ( $r = 0.881$  &  $p < 0.001$ ) and activity grades ( $r = 0.881$  &  $p < 0.001$ ). Also, serum CK18 correlated positively with serum levels of transaminases ( $r = 0.355$  &  $p < 0.05$ ). CK18 was correlated positively with viral level ( $r = 0.3$  &  $p < 0.05$ ). It was concluded that Elevated serum CK18-M30, as an indicator of enhanced apoptosis of hepatocytes, was increased and correlated significantly with inflammation severity, stages of fibrosis, transaminases (ALT) levels and viral load in chronic HCV patients. These findings may place CK18-M30 as a non-invasive marker of liver fibrosis and disease activity.

Copyright 2015, Mansoura University. Production and hosting by Elsevier B.V. This is an open access article under the CC BY-NC-ND license (<http://creativecommons.org/licenses/by-nc-nd/4.0/>).

\* Corresponding author. El Galaa Street, El Mansoura, Mansoura, Dakahlia 12345, Egypt. Tel.: +20 01009092903.

E-mail addresses: [raghda.farag@yahoo.com](mailto:raghda.farag@yahoo.com) (R.E.-S. Farag), [azzabaiomy23@yahoo.com](mailto:azzabaiomy23@yahoo.com) (A.A.E.-B. El-Baiomy), [drrania494@yahoo.com](mailto:drrania494@yahoo.com) (R.A. El-Erian).

Peer review under responsibility of Mansoura University.

<http://dx.doi.org/10.1016/j.ejbas.2015.04.005>

2314-808X/ Copyright 2015, Mansoura University. Production and hosting by Elsevier B.V. This is an open access article under the CC BY-NC-ND license (<http://creativecommons.org/licenses/by-nc-nd/4.0/>).

## 1. Introduction

Hepatitis C virus (HCV) is a progressive disease that may result in chronic active hepatitis, cirrhosis and hepatocellular carcinoma. It is estimated nationally that over 200 million people are infected and about 80% progress into chronic form [20]. Egypt has the highest prevalence of hepatitis C virus (HCV) in the world, estimated nationally at 14.7% [15].

Cytokeratin (CK18) is major intermediate filament protein in liver cells. It is expressed in hepatocytes by both apoptosis and necrosis which are the triggering for the inflammatory condition, regeneration and liver fibrosis [1].

The apoptotic pathway is composed of two arms, intrinsic and extrinsic one. In the final common step of apoptosis, CK18 which is expressed by hepatocytes is cleaved resulting in exposure of its M30 fragment and because of the liver is highly perfused organ, it accumulates very rapidly in the circulation of patients with chronic liver disease including HCV infection [5,23].

Human Apoptosense M30 is an ELISA based monoclonal antibody [13]. This antibody specifically binds to the cleaved CK18 fragments but not to the uncleaved fragments providing a non invasive, simple and quantitative test for hepatocyte death [8,11].

Liver biopsy is the gold standard method for diagnosis, assessment of severity of liver injury as well as monitoring of therapy although, it has many complications [7]. So, the presence of non invasive, simple and low cost test is highly needed [9].

Serum Cytokeratin 18-Apoptosense M30 would define the apoptotic process [23] and by finding its correlation with the severity of inflammation, staging of fibrosis it would replace liver biopsy making it unnecessary in many instances providing serum biomarker for diagnosis of liver injury and treatment monitoring.

Aim of this study was to assess the levels of Caspase-cleaved fragments of CK-18 in the sera of patients with chronic HCV infection and evaluate its correlation with hepatocyte apoptosis and any correlations with stages of fibrosis and grades of inflammation.

## 2. Patients

The study involved 168 patients with chronic hepatitis C recruited from Tropical Medicine department, Mansoura University Hospitals during the period from January 2013 to January 2014 (112 male and 56 female) with age ranged between 23 and 56 years. An informed consent was obtained from all patients included in the study.

## 3. Methods

### 3.1. Routine laboratory investigations

The following investigations were done CBC, Liver function tests, Prothrombin time, INR, Blood sugar test, Renal function tests, Autoimmune profile and lipid profile.

### 3.2. Chronic HCV diagnosis

Diagnosis of chronic hepatitis C based on presence of anti-HCV antibodies, using third-generation assays (Axysm HCV EIA test system), quantitative HCV RNA by reverse transcriptase (Stratagene Mx3000P Real-Time PCR System with a detection limit of 15 IU/ml) and liver biopsy showing chronic hepatitis.

### 3.3. Abdominal ultrasound

Abdominal US was done to study size, pattern of liver, spleen, presence or absence of ascites and exclusion of hepatocellular carcinoma.

### 3.4. Ultrasound guided liver biopsy and histological assessment

All patients had ultrasound guided liver biopsy showing chronic hepatitis. For percutaneous approaches the patient lies supine. The borders of the liver are usually defined by percussion or visualised by ultrasound. In most instances the intercostal space in the mid-axillary line just cephalad to the costal margin is then infiltrated with local anaesthetic, and a small incision is made through the dermis. The biopsy needle is then advanced into the intercostal space. The patient then holds their breath in expiration. The subsequent procedure for taking the biopsy according to APASL recommendation for liver biopsy (2009). Liver histology was graded and staged according to METAVIR fibrosis scaling system that classifies fibrosis into five stages (F0–F4) and activity into four grades (A0–A3) [16].

### 3.5. Blood sampling

Blood samples were obtained from all subjects at the same setting of liver biopsy. Serum alanine aminotransferase (ALT), serum aspartate amino-transferase (AST) were determined by Hitachi 902 instrument and HBs Ag for HBV was also done.

### 3.6. Assessment of Cytokeratin-18 Apoptosense M30 levels

Serum human Apoptosense M30 was assessed by ELISA supplied by Glory Science co., Ltd (USA). A solid phase microwell coated by purified human Apoptosense M30 Antibody and horse reddish peroxidase (HRP) labelled with anti Apoptosense M30 was added forming Ab-(Ag –ab enzyme complex), washing the microwells and adding substrate tetramethyl benzidine (TMB) which is proportional to M30 concentration in the sample giving a blue colour which turned yellow after stopping reaction with sulphuric acid solution and the plate was read by spectrophotometry at a wave length 450 nm and results are interpolated from Apoptosense M30 standard curve [5].

### 3.7. Statistical analysis

Data was computed with the statistical package for the social science, windows 7 versions, USA (SPSS17 software). Variable

with normal distribution were expressed as mean  $\pm$  SD. In these variables, the T test was applied for group differences. Non parametric data were expressed as median. The Kalmogorove–Smirnov test was check normal distribution of data. For correlation analysis, spearman's correlation coefficients were calculated with two-tailed P value. Value of  $P < 0.05$  was considered significant [14].

#### 4. Results

Demographic data of the studied group according to stages of fibrosis are presented in (Table 1). As found there were 26 (15.5%) patients had fibrosis stage 0, 40 (23.8%) patients had fibrosis stage1, 40 (23.8%) patients had fibrosis stage 2, 36 (21.4%) patients had fibrosis stage 3 and 26 (15.5%) patients had fibrosis stage 4.

By studying correlation between CK18 and parameters including stages of fibrosis, grades of inflammation (activity), ALT levels and viral load as illustrated in (Table 2). There was highly significant positive correlation between CK-18 and fibrosis stages ( $r = 0.881$  &  $p \leq 0.001$ ). Also, a highly positive correlation was obtained between CK-18 and activity ( $r = 0.881$  &  $p \leq 0.001$ ). On the other hand, when comparing CK-18 and ALT levels a significant positive correlation was obtained ( $r = 0.355$  &  $p < 0.05$ ). Also, when comparing CK-18 with viral load, a significant positive correlation was obtained ( $r = 0.3$  &  $p < 0.05$ ).

A significant correlation between CK18 levels and stages of fibrosis illustrated in (Fig. 2). Also, A significant correlation between CK18 levels and grades of inflammation (activity) illustrated in (Fig. 3). And as illustrated in (Figs. 4 and 5), CK18-M30 correlated positively with serum levels of liver enzyme (ALT) and viral load respectively.

Comparison between patients according to stages of fibrosis and CK-18 levels was done using one way ANOVA test

and there was highly significant decreased CK-18 levels in stage F0 compared to stage F1 ( $p \leq 0.001$ ). Also, there was highly significant decreased CK-18 levels in stage F0 compared to stage F2 group ( $p \leq 0.001$ ). And, CK-18 in stage F0 was highly significant decreased as compared to stage F3 ( $p < 0.001$ ). Also, There was highly significant decreased in stage F0 CK-18 levels as compared to these levels of stage F4 ( $p \leq 0.001$ ) respectively (Table 3).

A highly significant decreased in stage F1 CK-18 levels as compared to these levels of stage F2 ( $p \leq 0.001$ ). And, CK-18 levels was highly significantly decreased in stage F1 as compared to stage F3 ( $p \leq 0.001$ ). Also, highly significant decreased in stage F1 CK-18 levels was found as compared to stage F4 ( $p \leq 0.001$ ). However, CK-18 levels in stage F2 was significantly decreased as compared to stage F3 and stage F4 ( $p \leq 0.001$  and  $p \leq 0.001$ ) respectively. CK-18 levels in stage F3 was highly significant decreased as compared to stage F4 ( $p \leq 0.001$ ) (Table 3) and the serum concentration of CK18- was significantly increased in a stepwise fashion from F0 to F4 as illustrated in (Fig. 1).

#### 5. Discussion

The study showed a significantly higher level of CK18 in the serum of patients with marked fibrosis compared to patients with lower levels of fibrosis. These results are in agreement with those of Akl et al., who reported that CK18 expression was found to be increased in chronic HCV cases with higher stages of fibrosis that were progressing into cirrhosis, especially at METAVIR stage F4 [2,3].

The serum CK18 levels were significantly increased in a stepwise fashion from A0 to A3 as this result indicated that serum CK18 levels correlated with grades of inflammation. These data support a central role for apoptosis in disease pathogenesis, and this finding was similar to the results reported by many studies [12,16,18,19].

Increased CK18 expression within hepatocytes was reported in higher grades of chronic inflammation compared to lower grades by Valva et al. and this indicates that the rate of hepatocyte apoptosis was correlated with the severity of inflammation and was increased in cases of severe hepatitis C [10,12,21].

This study found that serum CK18 levels were strongly correlated with ALT levels. However, chronic hepatitis C patients with normal ALT levels had lower levels of CK18 than those with elevated ALT levels.

This result may be important for patients with normal aminotransferase levels. Therefore, apoptotic CK18 in the serum of patients with chronic hepatitis C are associated with higher ALT level and histological liver damage. This agree with many studies that found elevated serum apoptotic CK18 levels in patients with chronic hepatitis with high ALT levels [18,22].

Our analysis of hepatitis C viraemia by quantitative PCR showed significant difference in viral load relative to serum CK18 levels. This finding was inconsistent with data from Asselah and Bieche who found that apoptosis did not correlate With HCV load [1,4].

**Table 1 – Demographic data according to stages of fibrosis of the studied groups.**

	No	Age \ years			Gender	
		Mean $\pm$ SD	Minimum	Maximum	Male	Female
F0	26	30.88 $\pm$ 5.29	23	40	18	8
F1	40	44.65 $\pm$ 6.39	34	56	30	10
F2	40	43.37 $\pm$ 3.27	39	49	28	12
F3	36	45.02 $\pm$ 1.82	42	48	18	18
F4	26	49.40 $\pm$ 0.99	48	51	18	8

**Table 2 – Correlation between CK-18 levels and other parameters.**

Correlation pair	Correlation coefficient (r)	P value
CK-18 & Fibrosis	0.881	$\leq 0.001$
K-18 & activity	0.844	$\leq 0.001$
CK-18 & viral level	0.300	$\leq 0.05$
CK-18 & Liver enzyme	0.355	$\leq 0.05$

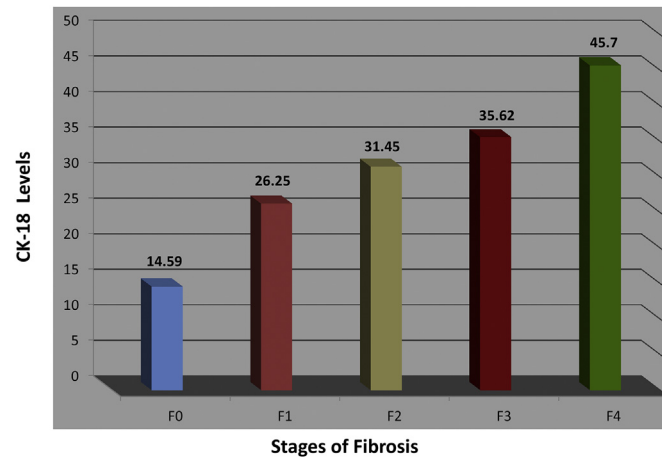


Fig. 1 – Comparison between patients according to stages of fibrosis and CK18 levels.

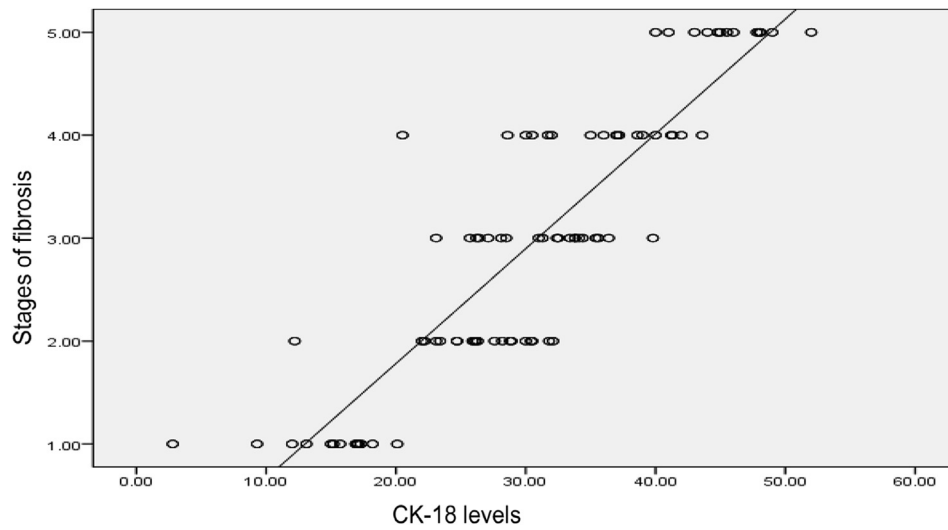


Fig. 2 – Correlation between CK18 levels and stages of fibrosis.

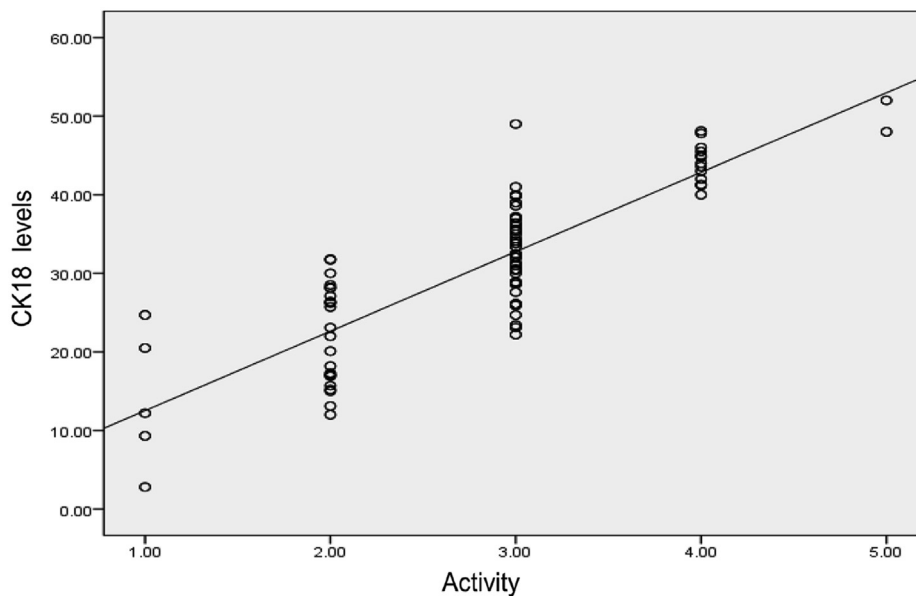


Fig. 3 – Correlation between CK18 levels and grades of inflammation (activity).

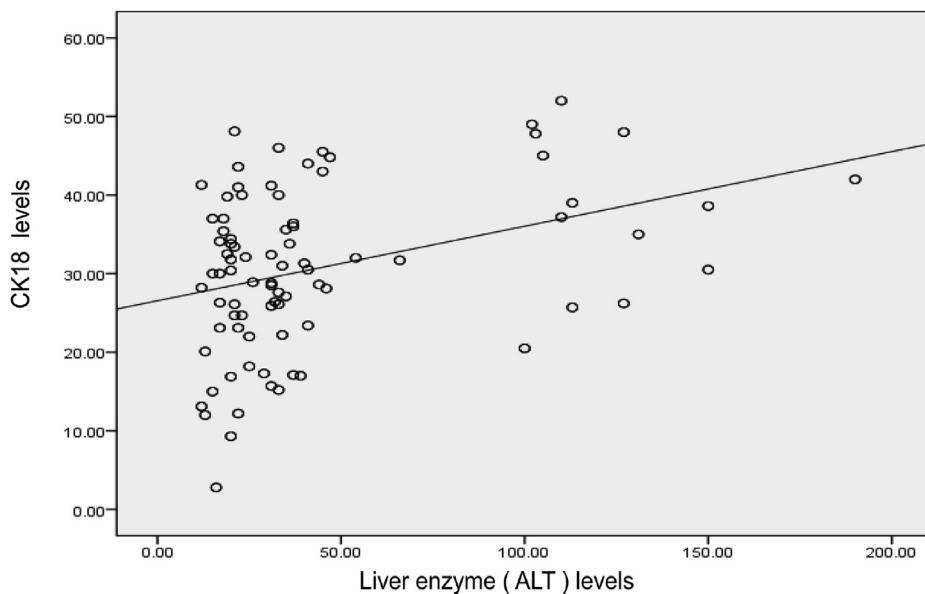


Fig. 4 – Correlation of CK18 levels and liver enzyme (ALT) levels.

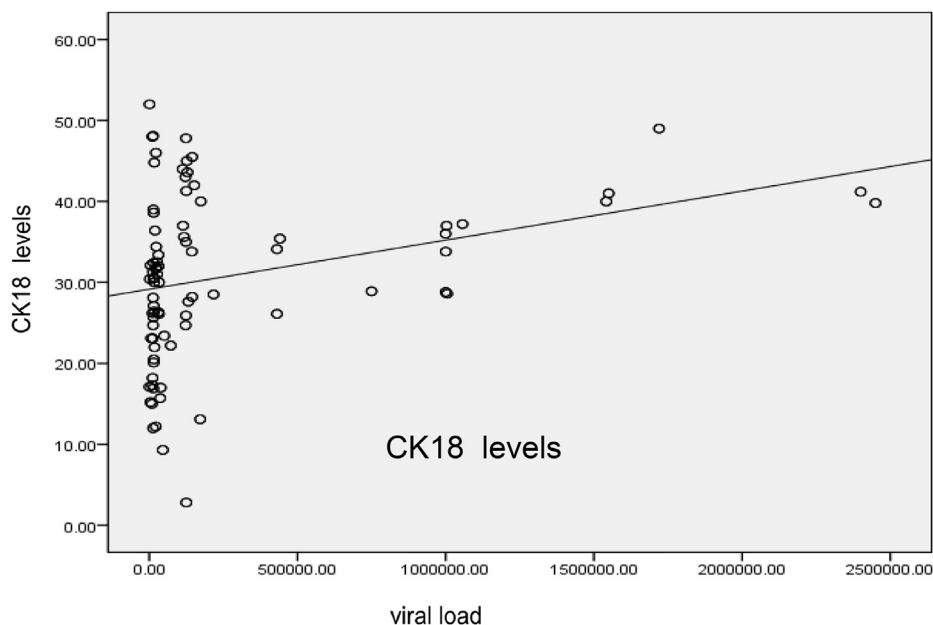


Fig. 5 – Correlation between CK18 levels and viral load.

Table 3 – Comparison between patients according to stages of fibrosis and CK-18 levels.

Fibrosis stage	CK18 range		Mean ± SD	p
	Minimum	Maximum		
F0 (26)	2.80	20.10	14.59 ± 4.52	≤0.001
F1(40)	12.20	32.10	26.25 ± 4.52	
F2(40)	23.10	39.80	31.45 ± 4.31	
F3(36)	20.50	43.60	35.62 ± 5.83	
F4(26)	40.00	52.00	45.70 ± 3.31	

## 6. Conclusion

Elevated serum CK18-M30, as an indicator of enhanced apoptosis of hepatocytes, was significantly increased and correlated significantly with inflammation severity, stages of fibrosis, transaminases levels and viral load in chronic HCV patients. These findings may place CK18-M30 as a non-invasive marker of liver fibrosis and disease activity.

## REFERENCES

- [1] Abdel-Haleem H, Zayed N, Abdel-Hafez H, Fouad A, Akl M, Hassan M. Evaluation of the diagnostic value of serum and tissue apoptotic cytokeratin-18 in patients with chronic hepatitis C. *Arab J Gastroenterol* 2013;14(2):68-72.
- [2] Akiko E, Wree A, Feldstein A. Biomarkers of liver cell death. *J Hepatol* 2014;60:1063-74.
- [3] Akl MM, Hammam O, El-Baz HG, Demerdash ZA, Sadek A, Mostafa I. Expression of intercellular molecule ICAM-1 and cytokeratin as potential markers of disease activity in the Egyptian pattern of chronic hepatitis C. *Med J Cairo Univ* 2002;70:45-53.
- [4] Asselah T, Bieche I, Paradis V, Bedossa P, Vidaud M, Marcellin P. Genetics, genomics and proteomics: implications for the diagnosis and the treatment of chronic hepatitis C. *Semin Liver Dis* 2007;27(1):13-27.
- [5] Bantel H, Lügering A, Heidemann J, Volkmann X, Poremba C, Strassburg CP. Detection of apoptotic caspase activation in sera from patients with chronic HCV infection is associated with fibrotic liver injury. *Hepatology* 2004;40(5):1078-87.
- [7] Bravo AA, Sheth SG, Chopra S. Liver biopsy. *N Engl J Med* 2001;344(7):495-500.
- [8] Canbay A, Feldstein A, Kronenberger B, Schulze-Osthoff K, Bantel H. Cytokeratin 18 as marker for non-invasive diagnosis and prognosis of acute and chronic liver diseases. *Z Gastroenterol* 2014;52(3):290-5.
- [9] Castera L. Noninvasive methods to assess liver disease in patients with hepatitis B or C. *Gastroenterology* 2012;142:1293-302.
- [10] Jang JY, Kim S, Cho EK, Jeong SW, Park EJ, Lee WC, et al. TRAIL enhances apoptosis of human hepatocellular carcinoma cells sensitized by hepatitis C virus infection: therapeutic implications. *PLoS One* 2014;9(6):e98171.
- [11] Hägg M, Bivén K, Ueno T, Rydlander L, Björklund P, Wiman KG. A novel high-through-put assay for screening of pro-apoptotic drugs. *Invest New Drugs* 2002;20(3):253-9.
- [12] Jazwinski AB, Thompson AJ, Clark PJ, Naggie S, Tillmann HL, Patel K. Elevated serum CK18 levels in chronic hepatitis C patients are associated with advanced fibrosis but not steatosis. *J Viral Hepat* 2012;19(4):278-82.
- [13] Leers M, Kölgen W, Björklund V, Bergman T, Tribbick G, Persson B. Immunocytochemical detection and mapping of a cytokeratin 18 neo-epitope exposed during early apoptosis. *J Pathol* 1999;187(5):567-72.
- [14] Levesque R. SPSS programming and data management. A guide for SPSS and SAS users. 4th ed. Chicago: SPSS Inc; 2007.
- [15] Mohamoud YA, Mumtaz GR, Riome S, Miller D, Abu-Raddad LJ. The epidemiology of hepatitis C virus in Egypt: a systematic review and data synthesis. *BMC Infect Dis* 2013;13:288.
- [16] McPartland JL, Guzail M, Kendall CH, Pringle JH. Apoptosis in chronic viral hepatitis parallels histological activity: an immunohistochemical investigation using anti-activated caspase-3 and M30 cytodetach antibody. *Int J Exp Pathol* 2005;86:19-24.
- [18] Parfieniuk-Kowerda A, Lapinski TW, Rogalska-Plonska M, Swiderska M, Panasiuk A, Jaroszewicz J, et al. Serum cytochrome c and m30-neoepitope of cytokeratin-18 in chronic hepatitis C. *Liver Int* 2014;34(4):544-50.
- [19] Seidel N, Volkmann X, Langer F, Flemming P, Manns MP, Schulze-Osthoff K, et al. The extent of liver steatosis in chronic hepatitis C virus infection is mirrored by caspase activity in serum. *Hepatology* 2005;42:772-8.
- [20] Valva P, Casciato P, Lezama C, Galoppo M, Gadano A, Galdame O. Serum apoptosis markers related to liver damage in chronic hepatitis C: sFas as a marker of advanced fibrosis in children and adults while M30 of severe steatosis only in children. *PLoS One* 2013;8(1):53519.
- [21] Valva P, De Mattea E, Galoppo MC, Gismondi MI, Preciado MV. Apoptosis markers related to pathogenesis of pediatric chronic hepatitis C virus infection: M30 mirrors the severity of steatosis. *J Med Virol* 2010;82:949-57.
- [22] Vos MB, Barve S, Joshi-Barve S, Carew JD, Whittington PF, McClain C. Cytokeratin- 18, a marker of cell death, is increased in children with suspected nonalcoholic fatty liver disease. *J Pediatr Gastro Enterol Nutr* 2008;47(4):481-5.
- [23] Yilmaz Y. Systematic review: caspase-cleaved fragments of cytokeratin -18 the promises and challenges of a biomarker for chronic liver disease. *Aliment Pharmacol Ther* 2009;30:1103-9.