



Official journal of the Pan African Urological Surgeons' Association
web page of the journal

www.ees.elsevier.com/afju
www.sciencedirect.com



Reconstructive Urology

Original Article

Tubularized incised plate urethroplasty repair in adult hypospadias patients. Are results similar to those reported in the pediatric age group? A prospective study



A. Bhat*, M. Bhat, R. Upadhaya, V. Kumar, R. Kumar, R. Mittal

Department of Urology, S.P. Medical College Bikaner, Rajasthan 334003, India

Received 5 November 2014; received in revised form 23 March 2015; accepted 1st April 2015

Available online 5 March 2016

KEYWORDS

TIPU;
Hypospadias;
Repair;
Results;
Adults;
Pediatric;
Variable;
Chordee;
Type of hypospadias;
Spongiosum urethral plate

Abstract

Objective: Most studies published in the literature report on the results of tubularized incised plate urethroplasty (TIPU) for hypospadias repair in children. Hence, the objective of this study was to evaluate the results of TIPU repair in adults.

Patients and methods: The records of 60 adult patients with primary hypospadias treated with TIPU between April 2009 and May 2012 were reviewed. All the procedures were done by the same surgeon under similar conditions and using the same kind of instruments and suture material. On clinical examination, the meatal location, as well as the presence/absence of chordee and penile torsion was assessed. The quality of the spongiosum and the width of the urethral plate were evaluated intraoperatively. The postoperative complications and results were recorded and the data were analyzed.

Results: The patients' age ranged from 16 to 27 years with a mean of 21 years. Out of the 60 cases, 43 (72%) had distal penile, 7 (11%) mid-penile and 10 (17%) proximal hypospadias. Penile torsion was present in 10 (17%) cases with 80% having a torsion $\leq 45^\circ$ and 20% having a torsion of $45\text{--}90^\circ$. Ventral chordee ranging from 30° to 90° was present in 14 (23%) cases. Chordee correction was possible by penile de-gloving in 4 (29%) patients (2 with distal and 2 with mid-penile hypospadias), by further mobilization of the urethral plate with the corpus spongiosum in 3 (21%) and by proximal urethral mobilization in another 6 (42%) patients with proximal hypospadias. One (7%) patient also required tunica albuginea plication. The urethral plate was wide in 22 (37%), average in 26 (43%) and narrow in 12 (20%) patients. Fifty percent of the patients with a narrow urethral plate developed complications, compared to 15% of the patients whose

* Corresponding author at: C-15 Sadul Ganj, Bikaner, Rajasthan 334003, India.

E-mail addresses: amilalbhat@rediffmail.com (A. Bhat), mahak199027@gmail.com (M. Bhat), surgeon.ups@gmail.com (R. Upadhaya), vinaysinghkgmc99@gmail.com (V. Kumar), drrajeevkr2k@gmail.com (R. Kumar), drruchimittalms@gmail.com (R. Mittal).

Peer review under responsibility of Pan African Urological Surgeons' Association.

<http://dx.doi.org/10.1016/j.afju.2015.04.007>

1110-5704/© 2016 Pan African Urological Surgeons' Association. Production and hosting by Elsevier B.V. All rights reserved.

urethral plate had an average width and none of the patients with a wide urethral plate. The spongiosum was well developed in 38 (63%) patients, while in 11 (18%) patients each the spongiosum was moderately and poorly developed. The complication rates were significantly higher (55%) in patients with a poorly developed spongiosum as compared to those with a well-developed spongiosum. The overall complication rate was 17% including fistula in 10% of the patients (2 patients with mid-penile and 4 patients with proximal hypospadias). Meatal stenosis was found in 4 patients with distal hypospadias (7%) who responded well to meatal dilatation. The fistula cases required surgical repair with a success rate of 100%. Mean hospitalization and follow-up were 9 days and 6–24 (median 37) months, respectively.

Conclusions: Complications encountered in the present study were urethral fistula and meatal stenosis with a higher incidence in patients with proximal hypospadias than reported in the literature. The important factors for the outcome of TIPU were the severity of hypospadias, the degree of curvature and the development of the spongiosum and urethral plate. Proximal hypospadias with a poor urethral plate and severe curvature in adults is not suitable for TIPU. In such cases, single-stage flap urethroplasty or two-stage buccal mucosal urethroplasty should be considered instead.

© 2016 Pan African Urological Surgeons' Association. Production and hosting by Elsevier B.V. All rights reserved.

Introduction

Tubularized incised plate urethroplasty (TIPU) is most commonly used for primary and re-do repair of distal, but also increasingly of proximal hypospadias in adults with good results [1,2]. Age is one of the important variables determining the outcome of surgical repair. The American Academy of Pediatrics recommends operating hypospadias at the age of 6–12 months [3]. In developed countries, children are taken to the hospital at a pediatric age suitable for surgery. However in developing countries, home births are still commonplace, mostly with the parents lacking awareness of congenital anomalies. Illiteracy and ignorance are among the most important reasons why patients with hypospadias present late to the hospital, mostly after the age of 2, and a significant number even in late childhood or as adults [4]. The few retrospective studies in the literature on the outcome of hypospadias repair in adults report a higher complication rate in older patients as compared to pediatric patients [5–7]. Adult hypospadias patients have been found to have erectile problems, a clearly increased susceptibility to infection, decreased vascularity, and wound healing problems, leading to further complications. There are no prospective studies on the outcome of TIPU in adults. Thus, the purpose of this study was to evaluate the results of TIPU repair in adults with reference to complications and the factors affecting the results.

Patients and methods

The records of 60 adult patients subjected to TIPU repair for hypospadias between April 2009 and May 2012 were reviewed. Only patients above the age of 16 with primary hypospadias who attended four follow-up visits after the intervention were included in the study. Care was also taken to select patients with the same socioeconomic background. Patients with secondary hypospadias and patients in whom a transection of the urethral plate had been done were excluded.

On clinical examination, the meatal location, as well as the presence/absence of chordee and penile torsion was assessed. The quality of the spongiosum and the width of the urethral plate were evaluated intraoperatively.

The quality of the spongiosum was classified as follows:

1. Poorly developed: Thin spongiosum with decreased vascularity. After tubularization, the diameter of the neourethra covered by the spongiosum was smaller than that of the proximal healthy urethra.
2. Moderately developed: Spongiosum with average thickness and vascularity. After tubularization, the diameter of the neourethra covered by the spongiosum was almost equal to that of the proximal healthy urethra.
3. Well developed: Robust, thick spongiosum with good vascularity. After tubularization, the diameter of the neourethra covered by the spongiosum was greater than that of the proximal healthy urethra [8,9].

We did not find any generally accepted objective criteria to define the normal width of the urethral plate. When the urethral plate could be tubularized easily without incision (on the largest catheter accepted by the normal proximal urethra), it was considered to be wide. When it required a superficial incision for this purpose, it was considered to be average, and when it required a deep incision of the plate, then it was considered to be narrow [8,9].

The degree of ventral curvature and torsion was also re-assessed intraoperatively before penile de-gloving. All patients included in the study were operated by the same surgeon under similar conditions and using the same kind of instruments and suture material.

Surgical technique

A V-shaped incision was chosen in cases without chordee or torsion requiring preputioplasty. In the remaining patients, an incision in inverted U-shape encircling the meatus up to the corona (preserving the urethral plate) was done and then continued circumferentially around the corona. Later on, the urethral plate and corpus spongiosum were mobilized in all cases. Penile de-gloving was done in cases with ventral curvature and/or penile torsion. The Gittes' test (intra-corporeal saline injection and simulated erection) was performed

STEPS FOR CHORDEE CORRECTION

- Step1- Penile skin de-gloving**
- Step2- Mobilization of divergent corpus spongiosum with urethral plate**
- Step3- Mobilization of urethral plate into glans**
- Step4- Mobilization of proximal urethra according to length required for correction**
- Step5- Single Stitch Dorsal plication**
- Step6- Ventral grafts**
- Step7- Division / resection of urethral plate**

Figure 1 Steps for chordee correction.

to assess chordee correction after penile de-gloving. Following creation of a plane of dissection just proximal to the meatus, the urethral plate with the corpus spongiosum was mobilized. Care was taken not to damage the corpus spongiosum or corpus cavernosum while dissecting the urethral plate. In case of a persisting curvature, proximal urethral mobilization was carried out up to the bulbar urethra. When the chordee still persisted, a single-stitch dorsal plication was done. Glanular chordee was corrected by mobilizing the urethral plate into the glans. The final chordee correction was checked using the Gittes test [4]. The same technique reported in previous studies [4,10] was used to correct torsion (Fig. 1). For tubularization of the urethral plate (with or without deep incision through the spongiosum) in the midline, 7/0 PDS sutures were used, irrespective of the patient's age. Spongioplasty and glanuloplasty were done using 6/0 Vicryl interrupted sutures to complete urethroplasty. An 8–10 Fr urethral catheter (depending on the patient's age) was left in situ. Preputioplasty was done in selected cases where the parents/patients demanded it, and care was taken to provide an adequate size of the prepuce. A pressure dressing was applied in all cases. The administration of anti-erotic estrogen (lynoestrol, 5 mg, one tablet three times a day) was started a week prior to surgery and continued for two weeks postoperatively, while alprazolam (.5 mg once at bedtime) was given postoperatively and continued for two weeks. Second-generation cephalosporins (ceftriazone 1 g) was applied intravenously just prior to surgery, and oral administration of cefexime 200 mg (one tablet twice daily) was continued for 2 weeks postoperatively. All patients also received anti-inflammatory drugs (brufen and paracetamol one tablet three times a day) for 7 days postoperatively.

The urethral catheter was removed on postoperative days 8–12.

The patients were seen for follow-up 1 month, 3 months, 6 months, 1½ years and 2 years after the operation. During their follow-up visits they were interviewed about the quality of their urine stream, the presence or absence of a fistula, urinary symptoms, erection and sexual function. Meatal calibration was done during the follow-up visit one month after the procedure. When the meatus was found to be narrow, this was recorded and meatal calibration was repeatedly done for up to 6 months. When meatal stenosis persisted beyond 6 months, it was recorded as non-responding to meatal dilatation. Post-operative complications and results including sexual function

were recorded. The data were analyzed using Student's *t*-test with $p < 0.05$ considered to be statistically significant.

Results

The patients' age ranged from 16 to 27 years with a mean of 21 years. Out of the 60 cases, 43 (72%) had distal penile, 7 (11%) mid-penile and 10 (17%) proximal hypospadias. The complication rate was significantly higher (43%) in patients with proximal hypospadias as compared to those with distal hypospadias (9.3%) (Fig. 2a).

Penile torsion was present in 10 (17%) cases with 80% having a mild torsion $\leq 45^\circ$ and 20% a moderate torsion of $45\text{--}90^\circ$. Nine (90%) of these ten cases had distal and one (10%) mid-penile hypospadias. The torsion was corrected by penile de-gloving in 80% and by mobilization of the urethral plate with the corpus spongiosum in 20% of the cases. The severity of penile torsion was not correlated with complications.

Ventral chordee ranging from 30° to 90° was present in 14 (23%) cases. Chordee correction was possible by penile de-gloving in 4 (29%) patients (2 with distal and 2 with mid-penile hypospadias), by further mobilization of the urethral plate with the corpus spongiosum in 3 (21%) patients with proximal hypospadias and by proximal urethral mobilization in another 6 (42%) patients with proximal hypospadias. One (7%) patient also required tunica albuginea plication. Ventral curvature affected the outcome of surgery. Patients with severe curvature, even those with distal hypospadias, developed complications (Fig. 2b).

The urethral plate was wide in 22 (37%), average in 26 (43%) and narrow in 12 (20%) patients. Fifty percent of the patients with a narrow urethral plate developed complications, compared to 15% of the patients whose urethral plate had an average width and none of the patients with a wide urethral plate (Fig. 2c).

The spongiosum was well developed in 38 (63%) patients, while 11 (18%) patients each had a moderate and poorly developed spongiosum. The complication rates were significantly higher (55%) in patients with a poorly developed spongiosum as compared to those with a well-developed spongiosum (Fig. 2d). Preputioplasty was done in 30 (50%) patients 8 (13%) of whom developed mild preputial edema which did not affect the repair and subsided spontaneously.

Fifty-eight patients (97%) were evaluated for their sexual function; 2 patients did not consent to this assessment. Of 38 (66%) patients having sexual contact (48% were married and 22% fathered children), 34 (59%) were able to ejaculate into their partner's vagina with adequate sexual performance and satisfaction of both partners. Four patients (7%) (1 proximal penile, 2 coronal, 1 penoscrotal) with small penises were not satisfied. However, all were able to maintain a good penile erection postoperatively.

Mean hospitalization was 8–10 days. Mean follow-up was 6–24 months with a median of 37 months.

The overall complication rate was 16.6% including fistula in 10% (2 patients with mid-penile and 4 with proximal hypospadias) [11]. Meatal stenosis was encountered in 6.6% (4 cases with distal hypospadias) [11]. Two of the patients with fistula due to proximal hypospadias also had strictures. Fistula closure was the procedure

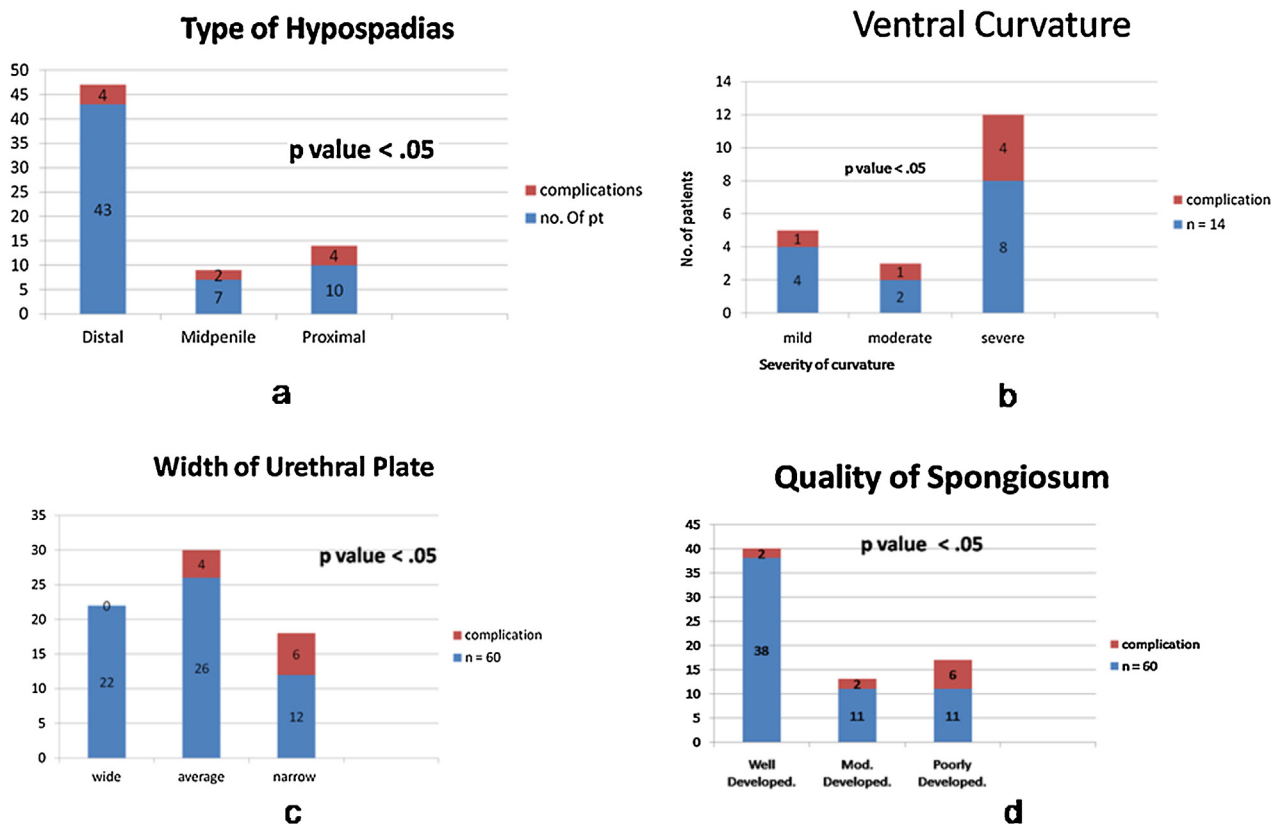


Figure 2 (a) Correlation between complications and the type of hypospadias. (b) Correlation between complications and ventral curvature. (c) Correlation between complications and the width of the urethral plate. (d) Correlation between complications and the development of the spongiosum.

of choice in patients with fistula alone. The fistulae with stricture were repaired with dorsal buccal graft urethroplasty in one and onlay flap urethroplasty in the other patient, with a success rate of 100% after re-do surgery. All cases of meatal stenosis responded to meatal dilation, however, three of them required monthly calibration for 4 months and one required repeated calibration for 6 months.

Discussion

Currently, the American Academy of Pediatrics recommends performing primary hypospadias repair at the age of 6–12 months based on a review of psychological, anesthetic and surgical factors [3]. However in developing countries, illiteracy and ignorance are among the most important reasons why patients with hypospadias present late to the hospital, mostly after the age of 2, and a significant number even in late childhood or as adults [4]. The mean age in this study was 21 years. This older age at presentation can be explained by the fact that parents in our environment are still ignorant about the importance of this painless and non-life threatening condition. When the young men become independent in their decision-making or plan to get married, they usually wish to have the defect repaired [12]. When comparing adult hypospadias patients with a young patient population at our institute, the complication rates were 17% vs. 4% (unpublished data), thus constituting a clinically significant difference. Several other authors also recorded higher complication rates in adult patients after hypospadias repair. Dodson et al. retrospectively reviewed 31 patients who underwent primary hypospadias repair after the age of 10 years. They reported fistula formation in 32%, stricture in 13%, hematoma in 6% and

failure of repair in 3% of the cases [13]. In another retrospective study of 42 adult patients, Hensle et al. reported a complication rate of 52% [5]. Nuininga et al. observed a 54% long-term complication rate in 126 patients who underwent primary hypospadias repair at a mean age of 7 years (range 1–14) [7]. Adult hypospadias patients have been reported to have problems of nocturnal and daytime erections more frequently than children. They have also shown a clearly increased susceptibility to infection, decreased vascularity, and wound healing disorders, leading to more complications [7]. On the other hand, there are authors who do not consider age to be an independent factor for adverse results [14].

In the present study, the severity of hypospadias correlated with the complication rate. 40% of the patients with proximal hypospadias developed complications, compared to 29% of the patients with mid-penile and 9% of the patients with distal hypospadias. The complication rates reported by Snodgrass vary from 19% to 60% (mean 22%) in patients with proximal hypospadias compared to 0–24% (mean 9%) in patients with distal hypospadias [3].

The fact that the complication rate in adults with proximal hypospadias reported by Bhat was 40% compared to 12% in younger patients shows that the severity of hypospadias combined with older age affects the results even more adversely [4].

Ventral penile curvature is also associated with higher complication rates [15]. In the present study, penile curvature was seen in 23% of the cases, 93% of which were corrected by mobilization of the urethral plate and urethra. An additional dorsal plication was only

necessary in 7%. The technique of mobilization of the urethral plate and proximal urethral mobilization has been used by other authors with variable results [3,4].

Our study included 14 patients with varying degrees of chordee. Of these, 1/4 (25%) patients with mild and 5/10 (70%) patients with moderate to severe chordee developed complications.

Penile torsion was present in 10 (17%) cases. Eight of them (seven distal, one mid penile) had a torsion $\leq 45^\circ$ and 2 (both distal) had a $45\text{--}90^\circ$ torque which, however, did not affect the results of repair.

Preputioplasty was performed in 50% of the patients, and none of them had a preputial narrowing after preputioplasty. Preputioplasty did not have any effect on the complication rate in our series, which shows that preputioplasty as such does not increase the complication rate when done in selected patients [6,15–19]. The decision on foreskin reconstruction depends on the patients' preference and may be considered for better cosmetic results, while the surgical aim of repairing congenital anomalies is the restoration of a normal or near normal anatomy.

Spongioplasty has been used by many authors, as a poor condition of the spongiosum is definitely correlated with complications [10,14]. In our series 6/10 (60%) patients with a poorly developed spongiosum developed complications. Assessing the development of a divergent spongiosum was a significant factor as the results were very poor in patients with a poorly developed spongiosum. We only performed spongioplasty as a water-proof layer without addition of a dorsal dartos, while other authors used the tunica vaginalis to reduce the complications in proximal hypospadias [20]. Since the results were poor in patients with a poorly developed spongiosum, we recommend using additional dorsal dartos or tunica vaginalis to prevent complications.

The assessment of the width, quality and depth of the urethral plate and their impact on the overall result of TIPU is still a matter of controversy. Some authors consider a plate < 8 mm as narrow [21,22]. As it seems illogical to us to assume a fixed width of the urethral plate for all patients, we took the caliber of the patient's native normal urethra as a reference. The width of the urethral plate also significantly affected our results: 50% of the patients with a narrow urethral plate, compared to 15% of the patients with an average urethral plate and none of the patients with a wide urethral plate, developed complications. The correlation of the width of the urethral plate with complications has also been reported by others [22–24]. Senkul et al. [25] managed their patients with primary TIP repair without any complications. Their results suggest that an intact urethral plate is associated with good results, even in adults.

The main complications encountered in the present study were urethral fistula (10%) and meatal stenosis (7%). Stricture and meatal stenosis increase the risk of fistula formation. Thus, creating a larger meatus by meatal calibration can decrease the risk of meatal stenosis as well as fistula. High complication rates in patients with proximal hypospadias (43%), a narrow urethral plate (50%) and a poorly developed spongiosum (55%) suggest that TIPU is not suitable in such cases. They should rather be managed with single-stage flap urethroplasty or two-stage buccal mucosal urethroplasty. The strength of our study is that it is a prospective study where all patients were of a similar socioeconomic background and were operated by a single surgeon using similar surgical techniques, instruments and

suture material. The follow-up period of 6 months to 2 years with a mean of 18 months is adequate. The results of our study are within an acceptable range as compared to other studies worldwide. The weakness of our study is the small number of cases. Therefore a larger database is required for more representative results.

Conclusions

The complication rate of adult hypospadias repair in this series was higher than that reported in the literature with urethral fistula and stricture formation being the most commonly encountered complications. The important factors determining the outcome of TIPU repair were the severity of hypospadias, the degree of curvature and the condition of the spongiosum and the urethral plate. These variables should be meticulously noted prior to hypospadias repair, as they may help the surgeon choose a repair procedure other than TIPU, if necessary, or give him the chance to refer the patient to a different center. The patients should be counseled beforehand about the likely outcome of surgery. TIPU is not suitable for adult patients with proximal hypospadias, a poor urethral plate and severe curvature. In such cases, single-stage flap urethroplasty or two-stage buccal mucosal urethroplasty should be considered instead.

Conflict of interest

None.

Ethical committee approval

Yes.

Source of funding

None.

References

- [1] Borer JG, Bauer SB, Peters CA, Diamond DA, Atala A, Cilento Jr BG, et al. Tubularized incised plate urethroplasty: expanded use in primary and repeat surgery for hypospadias. *J Urol* 2001;165:581–5.
- [2] Steckler RE, Zaontz MR. Stent-free Thiersch-Duplay hypospadias repair with the Snodgrass modification. *J Urol* 1997;158:1178–80.
- [3] Snodgrass WT. Hypospadias. In: Wein AJ, Kavoussi LR, Partin AW, Novick AC, Peters CA, editors. *Campbell-Walsh urology tenth edition*. Philadelphia: Elsevier Saunders; 2012. p. 3503.
- [4] Bhat A. Extended urethral mobilization in incised plate urethroplasty for severe hypospadias: a variation in technique to improve chordee correction. *J Urol* 2007;178:1031–5.
- [5] Hensle TW, Tennenbaum SY, Reiley EA, Pollard J. Hypospadias repair in adults: adventures and misadventures. *J Urol* 2001;165:77–9.
- [6] Marrocco G, Vallasciani S, Fiocca G, Calisti A. Hypospadias surgery: a 10-year review. *Pediatr Surg Int* 2004;20:200–3.
- [7] Nuininga JE, DE Gier RP, Verschuren R, Feitz WF. Long-term outcome of different types of 1-stage hypospadias repair. *J Urol* 2005;174:1544–8.
- [8] Bhat A, Sabharwal K, Bhat M, Saran R, Singla M, Kumar V. Outcome of tubularized incised plate urethroplasty with spongioplasty alone as additional tissue cover. A prospective study. *Indian J Urol* 2014;30:392–7.
- [9] Bhat A, Bhat M, Sabharwal K, Singla M, Saran R, Gokhroo S, et al. A prospective study to evaluate the role of different variables in results of TIPU for hypospadias. *Int J Res Urol* 2014. <http://dx.doi.org/10.5171/2014.547185>.

- [10] Bhat A, Bhat MP, Saxena G. Correction of penile torsion by mobilization of urethral plate and urethra. *J Pediatr Urol* 2009;5:451–7.
- [11] Dindo D, Demartines N, Clavien PA. Classification of surgical complications: a new proposal with evaluation in a cohort of 6336 patients and results of a survey. *Ann Surg* 2004;240:205–13.
- [12] Bhat A. General considerations in hypospadias surgery. *Indian J Urol* 2008;24:188–94.
- [13] Dodson JL, Baird AD, Baker LA, Docimo SG, Mathews RI. Outcomes of delayed hypospadias repair: implications for decision making. *J Urol* 2007;178:278–81.
- [14] Sarhan OM, El-Hefnawy AS, Hafez AT, Elsherbiny MT, Dawaba ME, Ghali AM. Factors affecting outcome of tubularized incised plate (TIP) urethroplasty: single-center experience with 500 cases. *J Pediatr Urol* 2009;5:378–82.
- [15] Eassa W, Jednak R, Capolicchio JP, Brzezinski A, El-Sherbiny M. Risk factors for re-operation following tubularized incised plate urethroplasty: a comprehensive analysis. *Urology* 2011;77:716–20.
- [16] Snodgrass W, Macedo A, Hoebcke P, Mouriquand PD. Hypospadias dilemmas: a round table. *J Pediatr Urol* 2011;7:145–57.
- [17] Leclair MD, Benyoucef N, Heloury Y. [Morbidity of foreskin reconstruction in distal hypospadias repair surgery]. *Prog Urol* 2008;18:475–9.
- [18] Keramidas DC, Soutis ME. Urethral advancement, glanduloplasty and preputioplasty in distal hypospadias. *Eur J Pediatr Surg* 1995;5:348–51.
- [19] Gray J, Boston VE. Glanular reconstruction and preputioplasty repair for distal hypospadias: a unique day-case method to avoid urethral stenting and preserve the prepuce. *Br J Urol Int* 2003;91:268–70.
- [20] Kajbafzadeh AM, Arshadi H, Payabvash S, Salmasi AH, Najjaran-Tousi V, Sahebpor AR. Proximal hypospadias with severe chordee: single stage repair using corporeal tunica vaginalis free graft. *J Urol* 2007;178:1036–42.
- [21] Nguyen MT, Snodgrass WT, Zaontz MR. Effect of urethral plate characteristics on tubularized incised plate urethroplasty. *J Urol* 2004;171:1260–2.
- [22] Holland AJ, Smith GH. Effect of the depth and width of the urethral plate on tubularized incised plate urethroplasty. *J Urol* 2000;164:489–91.
- [23] Sarhan O, Saad M, Helmy T, Hafez A. Effect of suturing technique and urethral plate characteristics on complication rate following hypospadias repair: a prospective randomized study. *J Urol* 2009;182:682–5.
- [24] Mosharafa AA, Agbo-Panzo D, Priso R, Aubry E, Besson R. Repair of hypospadias: the effect of urethral plate configuration on the outcome of Duplay-Snodgrass repair. *Prog Urol* 2009;19:507–10.
- [25] Senkul T, Karademir K, Işeri CN, Erden DO, Baykal K, Adayener CN. Hypospadias in adults. *Urology* 2002;60:1059–62.