



Contents lists available at ScienceDirect

## Gynecology and Minimally Invasive Therapy

journal homepage: [www.e-gmit.com](http://www.e-gmit.com)

## Case report

## Office hysteroscopic treatment of a vanishing external uterine orifice in a postmenopausal woman with an obstetrical history of 44 abortions

Maurizio Guida<sup>a</sup>, Lucio M.A. Cipullo<sup>a</sup>, Roberto Iovieno<sup>a</sup>, Anna Rita Palumbo<sup>a</sup>, Giovanni Pontrelli<sup>b</sup>, Gloria Calagna<sup>c</sup>, Attilio Di Spiezio Sardo<sup>d,\*</sup><sup>a</sup> Department of Gynecology and Obstetrics, University of Salerno, Salerno, Italy<sup>b</sup> Department of Gynecology and Obstetrics, Sacred Heart Hospital Don Calabria, Negrar, Verona, Italy<sup>c</sup> Department of Obstetrics and Gynecology, University Hospital "P. Giaccone", Palermo, Italy<sup>d</sup> Department of Neuroscience and Reproductive and Odontostomatological Sciences, University of Naples "Federico II", Naples, Italy

## ARTICLE INFO

## Article history:

Received 16 February 2015

Received in revised form

10 March 2015

Accepted 13 March 2015

Available online 30 April 2015

## Keywords:

cervical stenosis  
external uterine orifice  
hysteroscopy

## ABSTRACT

Cervical stenosis, defined as cervical scarring of variable degree, represents a significant anatomical impediment to hysteroscopic procedures. Acquired cervical stenoses are more common than congenital forms and they are mainly associated with aging, estrogen–progesterone drugs, cervical trauma or carcinoma. The overcoming of cervical stenosis at office hysteroscopy is challenging and it often fails requiring the scheduling of the patient for an in-patient treatment under general anesthesia. We report the office hysteroscopy treatment of a vanishing external uterine orifice in a postmenopausal woman with an ultrasonographic report of a heterogeneous and thick endometrium suggestive of endometrial pathology, focusing on the main surgical steps to perform an adequate management.

Copyright © 2015, The Asia-Pacific Association for Gynecologic Endoscopy and Minimally Invasive Therapy. Published by Elsevier Taiwan LLC. All rights reserved.

## Introduction

Several studies in the international literature report the success rate of office hysteroscopy as ranging from 90% to 95%.<sup>1,2</sup> Pain felt during the procedure, as well as the several anatomical impediments, which challenge the access to the cervical canal, represent the main limiting factors to the use of office hysteroscopy.<sup>1</sup>

Cervical stenosis, defined as cervical scarring of variable degree and comprising both subjective impression of tightening and the completely obliterated external (EUO) or internal uterine orifice (IUO), represents a significant anatomical impediment to hysteroscopic procedures.<sup>3</sup>

Cervical stenosis may be congenital or acquired. Congenital forms are rare and include cervical atresia and cervicovaginal

agenesis, while acquired cervical stenoses are more common and mainly associated with aging, estrogen–progesterone drugs, cervical trauma, or carcinoma. Nulliparity, endometrial and cervical curettage, and cervical surgery are also strongly associated with cervical stenosis.<sup>3–6</sup>

Reproductive age patients with incomplete cervical stenosis may initially be asymptomatic, as the cervical canal still allows partial drainage of menstrual blood, or may cause menstrual abnormalities, such as no periods (amenorrhea), painful periods (dysmenorrhea), abdominal distension, and episodes of light intermenstrual bleeding. Furthermore, it can also cause infertility because sperm cannot pass through the cervix to fertilize the egg. Postmenopausal cervical stenosis is commonly asymptomatic but, sometimes, a hematometra or pyometra may develop, causing pain or enlarging the uterus.

The overcoming of cervical stenosis at office hysteroscopy is challenging and it often fails, requiring the scheduling of the patient for an in-patient treatment under general anesthesia.

We report the office hysteroscopy treatment of a vanishing external uterine orifice in a 53-year-old postmenopausal woman with an obstetric history of 44 documented voluntary abortions.

Conflicts of interest: All the authors report no declarations of interest.

\* Corresponding author. Department of Neuroscience and Reproductive and Odontostomatological Sciences, University of Naples "Federico II", via Pansini 5, 80131 Naples, Italy.

E-mail address: [cdispie@tin.it](mailto:cdispie@tin.it) (A. Di Spiezio Sardo).

<http://dx.doi.org/10.1016/j.gmit.2015.04.005>

2213-3070/Copyright © 2015, The Asia-Pacific Association for Gynecologic Endoscopy and Minimally Invasive Therapy. Published by Elsevier Taiwan LLC. All rights reserved.

## Case report

A 53-years-old postmenopausal woman, with a history of three full-term pregnancies and 44 voluntary abortions between the 7<sup>th</sup> week and 12<sup>th</sup> week, came to our observation for the ultrasonographic report of a heterogeneous and thick endometrium (13 mm) suggestive of endometrial pathology.

The patient already had three failed diagnostic hysteroscopies (2 of those performed in an ambulatory setting and 1 in the operating room under general anesthesia), because of the impossibility of identifying and getting through the EUO. She was asymptomatic and only complained of episodically cramping pain. A repeat transvaginal sonography showed a retroverted uterus with a thick and irregular endometrium.

The patient was scheduled for an office hysteroscopy, which was performed with a rigid hysteroscope with an oval profile and a diameter of 4 mm (Office Continuous Flow Operative Hysteroscopy size 4; Karl Storz, Tuttlingen, Germany). A constant intrauterine pressure of almost 40 mmHg was obtained by setting the flow rate on 300–350 mL/min, a negative pressure suction of 150 mmHg and an irrigation pressure of 100 mmHg. Neither analgesic nor anesthetic preparations were administered to the patient. A vaginoscopic approach was used to access the uterine cavity, avoiding the need to introduce a speculum and a tenaculum. No cervical preparation was used before the procedure.

The vaginal phase immediately showed complete vanishing of the EUO. The scars of the previous failed attempts to dilate the EUO were detected in the apex of the vagina (Fig. 1A).

First, a 5F grasping forceps was used to test the consistency of the tissue. Then, a 5F bipolar electrode (Versapoint Twizzle electrode; Gynaecare, Ethicon Inc., Somerville, NJ, USA) has been used in a cold way (i.e., without electricity) as a sort of needle just to create a small hole in that area (Fig. 1B); as soon as a *black area* was created, confirming our hypothesis that it could be the distal part of the endocervical canal, the electrode was activated on the vaginal surface in order to perform four radial incisions (1–2 mm deep), at approximately the 3 o'clock, 6 o'clock, 9 o'clock, and 12 o'clock positions of the fibrous ring (Fig. 1C).

Then, 5F grasping forceps with teeth were inserted within the opening with the jaws first closed and then gently opened in order to stretch the fibrotic tissue (Figs. 1D and 1E). Finally, 5F sharp scissors were used to cut this fibrotic tissue at two or three points.

At the end, when the cervical stenosis was overpassed, the cervical canal and the uterine cavity were explored. A cystic endometrial polyp was detected and removed by means of a 5F bipolar electrode (Fig. 1F).

## Discussion

Cervical stenosis can be congenital or acquired and complete or partial. Since different definitions are used, the incidence observed by each author also varies, ranging from 0% to 25%.<sup>3,4</sup>

There are specific subgroups of patients, with an increased risk of cervical stenosis, which have a concomitant, absolute necessity to undergo cervical or uterine evaluation. These include postmenopausal women with increased endometrial thickness, previous cervical surgery (i.e., loop electrosurgical excision procedure, cold knife, and laser conization) that require follow-up (cytological sampling or endocervical evaluation by hysteroscopy and/or curettage) and infertile women with severe cervical stenosis impairing intrauterine insemination or embryo transfer.<sup>2,3,6</sup>

The management of cervical stenosis is generally challenging, and no clearly effective and reliable treatment is currently available. The most common treatments include cervical dilatation, stent insertion to maintain cervical patency, hysteroscopic canalization, and administration of medications to delay endometrial development.<sup>6,7</sup>

Cervical dilatation is commonly performed using Hegar dilators under antibiotic cover in order to reduce the risk of endometritis. However, recurrence after dilatation is common and may occur a few months after the procedure. This has led several authors to propose the insertion of stents, pessaries, and catheters to maintain a continuous expansive force on the cervix.<sup>7</sup> These devices have been reported to achieve good long-term outcomes, but may get dislocated or increase the risk of uterine infection.

Other authors have described the successful utilization of Interceed® (Ethicon – J&J, Somerville, NJ, USA), an absorbable adhesion barrier, in preventing recurrent stenosis.<sup>8</sup> Evidence for this method is scarce and limited to case reports, and it may be more effective when the recurrent stenosis is due to adhesions rather than a true narrowing.

Hysteroscopic canalization is a surgical procedure generally involving the use of a monopolar resectoscope with an angle-cutting loop to refashion stenotic portions of the cervical canal.<sup>9</sup> A spectrum

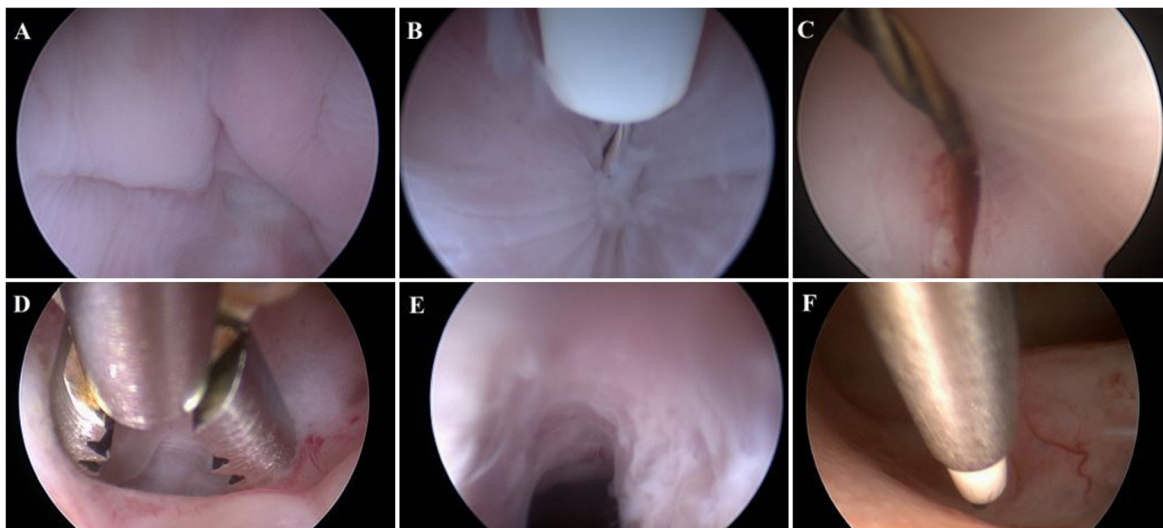


Fig. 1. Steps of surgical hysteroscopic synechiolysis.

of difficulties is related both to generic components of procedures such as patient positioning and need of local or general anesthesia, and to specific endoscopic surgery, such as perforation and injuries to surrounding structures and blood vessels or sequelae related to the use of monopolar uterine resectoscopes that involve thermal injury to the vulva and vagina.<sup>10</sup> Recent technological advances including the development of small-diameter rigid hysteroscopes with an oval profile, the use of normal saline as distension medium as well as the introduction of 5F operative instruments and bipolar electrodes have turned office hysteroscopy into a nearly painless, faster, and virtually complication-free technique.

The latter improvements have also made it possible to treat in the office-based setting a number of cervical and uterine pathologies, including cervical stenosis. In this respect, the oval profile of the hysteroscope together with the possibility of introducing operative instruments through the working channel allow most cervical stenoses to be easily overcome, involving either the EUO or the IUO.<sup>1,2,8</sup> An oval-profile hysteroscope conforms more strictly to the anatomy of the cervical canal, which is normally oval, with a main transverse axis and a diameter of approximately 4–5 mm. Therefore, a simple rotation of the scope on the endocamera by 90° is adequate to align the main longitudinal axis of the scope with the transverse axis of the IUO. In case of moderate stenosis, a 5F grasping forceps and sharp scissors, are generally enough to obtain the resection of fibrous tissue responsible for the stenosis, while a bipolar electrode is significantly more often used in case of stenosis of EUO alone or in combination with stenosis of IUO, as in the current patient. Indeed, stenoses involving the EUO are generally more severe than the others and, very often, it can be difficult even to identify a punctiform access to the uterine cavity. This precludes the initial use of mechanical instruments, allowing only the possibility to insert a needle-like bipolar electrode in order first to create a point of access in a *cold way* and then to cut the fibrotic ring in a safe way. The mildest energy of vapor cutting mode was used in our case (VC3 50W), because it provides the lowest energy flow into the tissue, thus reducing patient's pain and discomfort to the minimum.

As suggested during another hysteroscopic procedure, intra-operative ultrasound guidance could be associated to perform the procedure in a safe way, maintaining an adequate distance from the bowel or bladder, and to be sure of a complete intervention.

The main advantage of an office approach without any kind of anesthesia lies in the prompt identification of false passages.

Indeed, taking into account the absence of sensitive nerve terminals in the fibrous tissue, a sudden increase of patient's pain represents a warning sign that a false passage into the vagina or cervical myometrium has been created.

The safety of the procedure could be further increased by transabdominal sonographic surveillance after adequate bladder distension. This dual vision minimizes the risk of creating false passages and uterine perforations. In obese patients, use of transrectal ultrasound surveillance may be more advisable; however, this modality may be associated with poor patient compliance, and turn out to be anti-ergonomic when the need arises to tilt the hysteroscope, which may conflict with the advantage of dual control.

In conclusion, our case shows that it is possible to overcome even several stenoses in the office setting using some tricks with miniaturized instruments.

## References

1. Cicinelli E, Parisi C, Galantino P, Pinto V, Barba B, Schonauer S. Reliability, feasibility, and safety of mini-hysteroscopy with a vaginoscopic approach: experience with 6,000 cases. *Fertil Steril.* 2003;80:199–202.
2. Di Spiezio Sardo A, Taylor A, Tsirkas P, Mastrogamvrakis G, Sharma M, Magos A. Hysteroscopy: a technique for all? Analysis of 5,000 outpatient hysteroscopies. *Fertil Steril.* 2008;89:438–443.
3. Suh-Burgmann EJ, Whall-Strojwas D, Chang Y, Hundley D, Goodman A. Risk factors for cervical stenosis after loop electrocautery excision procedure. *Obstet Gynecol.* 2000;96:657–660.
4. Litta P, Bonora M, Pozzan C, et al. Carbon dioxide versus normal saline in outpatient hysteroscopy. *Hum Reprod.* 2003;18:2446–2449.
5. Dalton VK, Saunders NA, Harris LH, Williams JA, Lebovic DI. Intrauterine adhesions after manual vacuum aspiration for early pregnancy failure. *Fertil Steril.* 2006;85:1823.e1–1823.e3.
6. Pabuccu R, Ceyhan ST, Onalan G, Goktolga U, Ercan CM, Selam B. Successful treatment of cervical stenosis with hysteroscopic canalization before embryo transfer in patients undergoing IVF: A case series. *J Min Invasive Gynecol.* 2005;12:436–438.
7. Grund D, Köhler C, Krauel H, Schneider A. A new approach to preserve fertility by using a coated nitinol stent in a patient with recurrent cervical stenosis. *Fertil Steril.* 2007;87:1212.e13–1212.e16.
8. Palaia I, Perniola G, Arrivi C, et al. Persistent posttrachelectomy cervical stenosis treated with Petit-Le Four pessary in early cervical cancer patients: a report of two cases. *Fertil Steril.* 2007;88:1677.e5–1677.e7.
9. Lin BL, Higuchi TY, Yabuno A, et al. One-step hysteroscopic myomectomy using Lin dissecting loop and Lin myoma graspers. *Gynecol Minim Invasive Ther.* 2012;1:27–33.
10. Gudipudi D, Montemarano N, Del Priore G. Alternative approaches to cervical stenosis. *Fertil Steril.* 2007;88:763–764.