




Available online at
 ScienceDirect
www.sciencedirect.com

Elsevier Masson France
 EM|consulte
www.em-consulte.com/en

**Orthopaedics
& Traumatology**
 Surgery & Research

ORIGINAL ARTICLE

The concordance of MRI and arthroscopy in traumatic meniscal lesions in children

Y. Bouju^{a,*}, E. Carpentier^b, F. Bergerault^a, B. De Courtivron^a,
 C. Bonnard^a, P. Garaud^a

^a Pediatric Orthopedics Department, Clocheville Hospital, Tours University Hospital Center, 37044 Tours cedex, France

^b Pediatric Radiology Department, Clocheville Hospital, Tours University Hospital Center, 37044 Tours cedex, France

Accepted: 6 July 2011

KEYWORDS

Traumatic meniscal lesion;
 Children;
 MRI;
 Arthroscopy

Summary

Introduction: Traumatic meniscal lesions in children must be diagnosed quickly and efficiently as a priority in order to conserve the meniscus and safeguard the future of the knee. They are often isolated and difficult to identify clinically. In the diagnostic work up stage, an excessive resort to diagnostic arthroscopy has given way to increasing use of MRI by radiologists without pediatric specialization. The present study examined the agreement between MRI aspect and arthroscopic exploration in traumatic meniscal lesions in children.

Patients and methods: Sixty-nine knees in children aged 9 to 16 years having undergone MRI followed by arthroscopy for knee trauma between 1995 and 2008 were included in a retrospective design. Discoid meniscus was excluded. Files were reviewed by a single clinician and MRI scans by a radiologist specialized in pediatric pathology. Cases of epiphyseal fusion were excluded. All files were analyzable. Agreement with arthroscopic findings as reference was assessed for presence, location and type of meniscal lesion.

Results: Overall agreement with arthroscopy was respectively 78% and 82% on first and second MRI readings: 77% and 80% for the medial, and 78% and 84% for the lateral meniscus. On the first reading, there were 13 false positives for the medial and 5 for the lateral meniscus, versus 9 and 0 respectively on second reading. Overall sensitivity was 70% on first reading and 64% on second, and overall specificity 81% and 90%, respectively.

Discussion: The present results, in line with the literature, may appear encouraging, but hide considerable disparity between analysis of the medial and of the lateral meniscus: MRI overestimated medial and underestimated lateral meniscus lesions.

* Corresponding author. Tel.: +33 6 88 58 26 33.

E-mail addresses: yves.bouju@gmail.com (Y. Bouju), elodie.carpentier@univ-tours.fr (E. Carpentier), f.bergerault@chu-tours.fr (F. Bergerault), b.decourtivron@chu-tours.fr (B. De Courtivron), bonnard@med.univ-tours.fr (C. Bonnard), pa.garaud@gmail.com (P. Garaud).

Conclusion: MRI serves only as a support and does not provide sure diagnosis of meniscus lesion. Interpretation should take account of the clinical examination and the pediatric orthopedic specialist's experience.

Level of evidence: Level IV, retrospective study.

© 2011 Elsevier Masson SAS. All rights reserved.

Introduction

The meniscus plays a crucial role in stress reduction, load transmission and shock absorption. Childhood traumatic meniscal lesions are considered rare [1], but are increasingly frequent [2,3], presently representing 5% of meniscal lesions as a whole [4]. Early diagnosis conserves the meniscus and reduces the rate of suture failure.

Clinical diagnosis in children is difficult, as signs are non-specific and non-discriminating: joint pain, internal derangement of the knee [4] with cracking and/or locking. Clinical examination should be very rigorous to guide the physician, and is nowadays systematically associated to MRI [2].

The consensus is no longer to perform diagnostic arthroscopy in suspected meniscal lesion in adults [5]; this attitude was supported by Crawford et al. [6]. The diagnostic procedure for meniscal lesion in children was brought into line in 2006 [2].

In adults, MRI shows 92% sensitivity and 87% specificity [7] in diagnosing meniscal lesions. Few pediatric studies [8–11] have assessed the precision of MRI in this indication. Kocher et al. [11], in 2001, reported poor results, with 62% sensitivity and 90% specificity in patients under the age of 12 years.

White et al. [12] suggested that radiologist experience in MRI could be of positive impact in this rare pathology.

The present study assessed agreement between MRI and arthroscopy in the diagnosis of traumatic meniscal lesion in children and the interest of interpretation by a specialized radiologist.

Patients and methods

Patient

This was a continuous retrospective study, with the following inclusion criteria:

- patient managed in the department between April 1995 and September 2008 for suspected meniscal lesion;
- MRI examination for meniscal and/or ligamentary lesion. MRI was prescribed either by the patient's physician before the specialist consultation or by the pediatric orthopedic surgeon following the first consultation. The MR images were originally interpreted by hospital and/or private radiologists, a large majority of whom were not pediatric specialists but who did in principle have access to the clinical data;
- arthroscopy performed on the affected knee.

The exclusion criteria were:

- MRI not available for second reading;
- dysplastic or discoid meniscus (confirmed on arthroscopy);
- epiphyseal fusion seen on MRI.

Method

This was a retrospective file-based study, using a standardized clinical, MRI and arthroscopic review form.

Only the clinical data were provided to the radiologist for the second MRI reading. This introduced a bias in the study, these clinical data very likely being more exhaustive than those available to the radiologist at the initial MRI examination.

Lesions were classified according to Trillat's [13] descriptive anatomic classification, initially used for traumatic medial meniscus lesion in adults and later extended to lateral meniscus lesions [14] (Fig. 1): it describes longitudinal lesions with simple fissure, bucket-handle and flaps (radial and longitudinal lesion). Peripheral disinsertion is a longitudinal lesion extending beyond the meniscal wall.

This classification is completed by radial or transverse lesions, and by horizontal lesions (simple fissure, complex lesion).

There is no specific classification for pediatric meniscal lesions.

Fig. 1 shows the three most frequent types of meniscal lesion; the first two are in order of increasing severity.

Meniscal hypersignal was classified according to Crues and Stoller [15,16], as follows:

- grade I is single or multiple punctiform hypersignal not extending to joint surfaces (invisible to arthroscopy);
- grade II is linear intrameniscal hypersignal not extending to joint surfaces (invisible to arthroscopy);
- grade III is linear hypersignal extending to at least one of the two joint surfaces.

King et al. [9] studied the specificities of knee MRI in children, highlighting the high rate of false positive detection of meniscal lesions, due to the hypervascularized regions of the meniscus.

Takeda et al. [17] confirmed this problem in asymptomatic menisci and suggested a modification to Crues's classification [16] to overcome it, but which was not used in the present study.

All patients underwent arthroscopy, providing precise description of meniscal lesion anatomy.

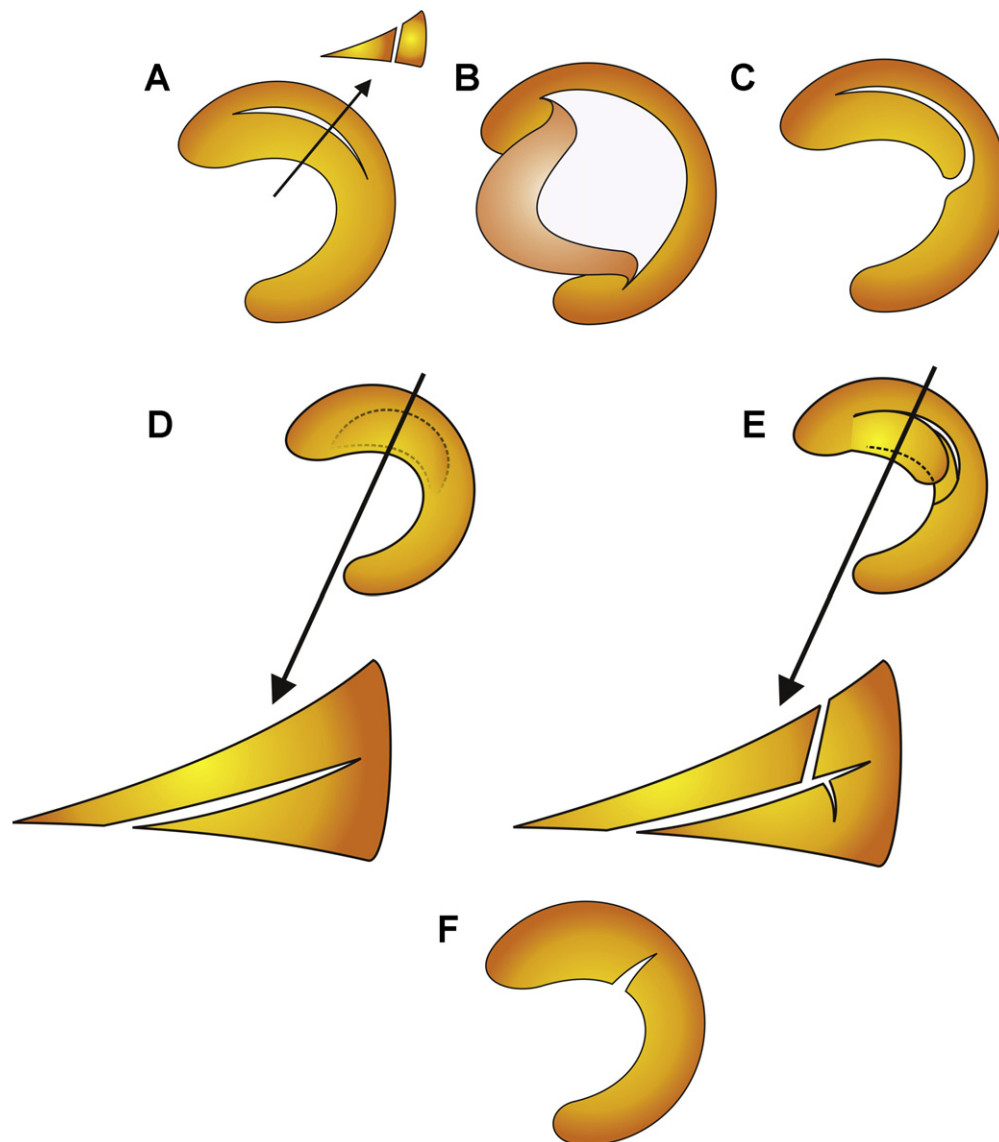


Figure 1 Drawings of the various meniscal lesions, made by Pr. P. Burdin for this report. A. Longitudinal lesions: simple fissure. B. Longitudinal lesions: bucket-handle. C. Longitudinal lesions: flap. D. Horizontal lesions: simple fissure. E. Horizontal lesions: complex lesion. F. Radial or transverse lesion.

All the MR images were reviewed by a single radiologist specialized in pediatrics, with access only to the clinical data.

Agreement between MRI and arthroscopy was assessed as the statistical precision of diagnosis in agreement with the reference examination (arthroscopy): i.e. the percentage of patients correctly diagnosed.

Agreement as to lesions between MRI (1st and 2nd readings) and arthroscopy was assessed on the following objective criteria:

- presence of an anatomically identifiable lesion, excluding grade I and II hypersignal;
- lesion location, following Cooper [18]: lateral or medial site and meniscal segment;
- morphologic lesion description on the morphologic classification.

Sensitivity (Se), specificity (Sp) and positive (PPV) and negative (NPV) predictive values were calculated for the series as a whole.

Results

Sixty-nine knees (69 children) were included: i.e. 138 menisci. Mean age at arthroscopy was 13.3 years (range, 9–16 years; median, 13.7 years); sex ratio showed male predominance (41/69); there were 36/69 right knees.

Presenting signs were non-specific, sometimes isolated or masked by anteromedial instability (31 cases). Pain was the principal complaint (52 patients). Twenty-nine patients had had one or more episodes of locking and 10 were disturbed by almost daily intra-articular cracking.

The mean interval between trauma and arthroscopy was 9.6 months. The mean interval between MRI and arthroscopy

Table 1 Meniscal lesions on arthroscopy.

Lesion type on arthroscopy	69 patients	
	Medial meniscus	Lateral meniscus
Simple longitudinal	1	9
Bucket-handle	4	4
Flap	0	2
Disinsertion	1	4
Simple horizontal	4	6
Complex	1	3
Radial	1	4
Total	12	32

was 1.9 months. Twenty-three lateral and 20 medial meniscal lesions were clinically suspected.

In eight patients, no diagnostic hypothesis could be formulated to explain the internal disorder of the knee.

Arthroscopy results

There were 44 lesions in all, mainly ($n=32$) to the lateral meniscus; in four patients, both menisci were affected (Table 1). Twenty-nine arthroscopies (42%) found no meniscal lesions; 21 found anterior cruciate ligament (ACL) tear with or without associated meniscal lesion; 17 found no lesion at all.

Lesion type was very variable: lateral meniscal lesions were mainly simple longitudinal and horizontal fissures. Four of the five radial lesions involved the lateral meniscus. Medial menisci mainly presented horizontal lesions and bucket-handle tears.

Seventy-five percent of lesions involved the posterior horn (medial or lateral), alone or in association with another segment.

MRI results

The 1st MRI reading suspected 20 medial meniscus lesions and 28 lateral (including three discoid) (Table 2). The 2nd reading suspected 16 medial meniscus lesions and 21 lateral (none discoid). Six grade II hypersignals were reported on 1st and 16 on 2nd reading.

Crossed reading

The study population was large enough to provide a considerable number of readings, especially for normal menisci (i.e. second healthy meniscus, also analyzed)—whence a large proportion of true negatives (Table 3). Forty-three percent of the 53 clinically suspected lesions failed to be confirmed on arthroscopy.

There was a large proportion of false positives for medial menisci on both readings, but few false negatives.

In lateral menisci, there were mainly false negatives on both readings. There were 5 false positives on the first reading and none on the second, performed by a specialized radiologist.

Figs. 2 and 3 show typical misinterpretations in pediatric cases.

Statistical analysis

Overall agreement between MRI and arthroscopy was assessed, including both medial and lateral meniscal lesions (Table 4). The level of agreement from the specialized pediatric radiologist was slightly better than on the 1st reading, as were specificity and PPV.

Results were also detailed per meniscus. In medial menisci, PPV was about 40% and NPV nearly 90%. In lateral menisci, PPV was 8% and 100% respectively on 1st and 2nd readings and NPV nearly 76% on both.

Discussion

Precise diagnosis is fundamental in children [2] to enable repair to be performed as soon as possible, and above all to

Table 2 Meniscal lesions on MRI, readings 1 and 2.

Lesion type on MRI	69 patients, 44 meniscal lesions			
	Medial meniscus (12)		Lateral meniscus (32)	
	1st reading	2nd reading	1st reading	2nd reading
Simple longitudinal	7	5	7	6
Bucket-handle	5	4	4	5
Flap	0	0	0	1
Disinsertion	1	0	0	0
Simple horizontal	4	7	5	2
Complex	3	0	9	5
Radial	0	0	0	2
Discoid	0	0	3	0
Total	20	16	28	21

Table 3 Comparison of the two MRI readings to arthroscopy.

MRI diagnosis	69 patients, 44 meniscal lesions			
	Medial meniscus (12)		Lateral meniscus (32)	
	1st reading	2nd reading	1st reading	2nd reading
True positive (TP)	9	7	22	21
False positive (FP)	13	9	5	0
True negative (TN)	44	48	32	37
False negative (FN)	3	5	10	11
Total	69	69	69	69

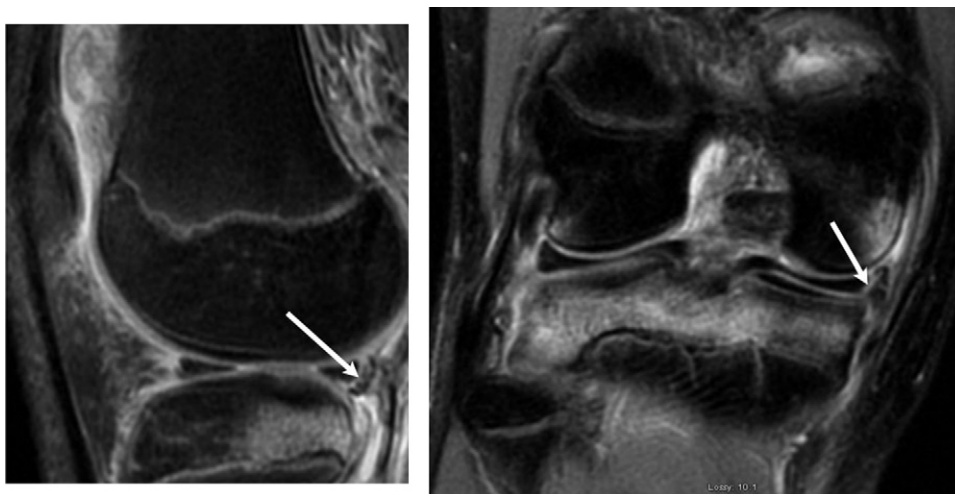
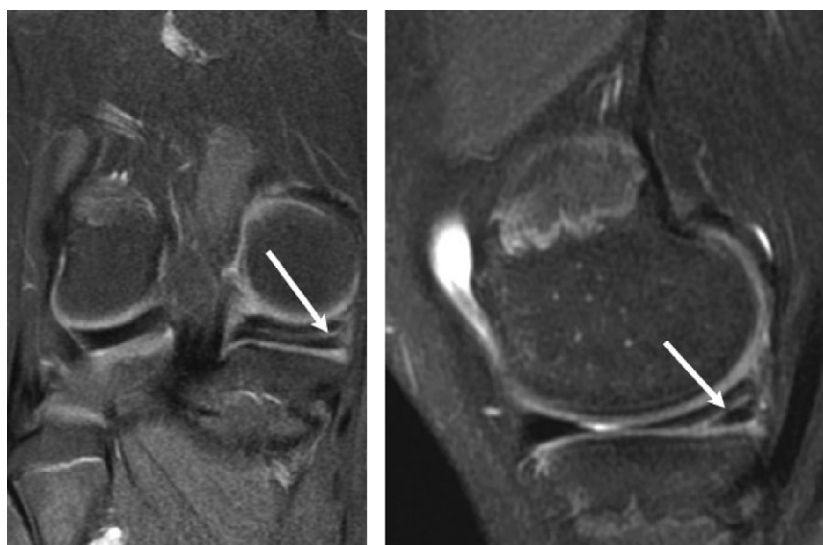
**Figure 2** Preoperative MRI of right knee in a 14-year-old boy, wrongly interpreted as normal whereas there was a longitudinal lesion of the posterior horn of the medial meniscus.**Figure 3** Preoperative MRI of right knee in a 14-year-old girl, wrongly interpreted as a lesion of the posterior horn of the medial meniscus (longitudinal on 1st reading, horizontal on 2nd).

Table 4 MRI/arthroscopy agreement on meniscal lesions.

	69 patients, 44 meniscal lesions					
	Overall (44 lesions)		Medial meniscus (12)		Lateral meniscus (32)	
	1st reading	2nd reading	1st reading	2nd reading	1st reading	2nd reading
Agreement	78%	82%	77%	80%	78%	84%
Sensitivity	70%	64%	75%	59%	69%	66%
Specificity	81%	90%	77%	84%	86%	100%
PPV	63%	76%	41%	44%	81%	100%
NPV	85%	84%	94%	91%	76%	77%

PPV: positive predictive value; NPV: negative predictive value.

avoid meniscectomy [3] with its catastrophic impact on the functional prognosis of the knee [19], following the universally accepted principle of meniscal sparing.

Before bone maturity in the knee, overall MRI-arthroscopy agreement in diagnosing traumatic meniscal lesions in children was 78% for non-specialized radiologists and 82% for the specialized pediatric radiologist. Overall sensitivity was respectively 70% and 64% and overall specificity 81% and 90%. The present 2nd reading results were strictly comparable to those of Kocher et al. [11] (sensitivity 61.7%, specificity 90.2%), in the most recent study in the field—which, however, dates from 2001.

Clinical examination alone is insufficient to guide the diagnostic procedure for meniscal lesion in children: with only 57% of suspected lesions confirmed on arthroscopy, further diagnostic support is required. Arthroscopy is very effective in diagnosing meniscal lesions [20], but is invasive and not without complications: we no longer perform it in first intention. There is no consensus as to systematic diagnostic arthroscopy in children. Stanitski [21,22] gives first place to clinical examination, stressing over-prescription of MRI by non-specialists and also the pressure on the physician from parents and society to prescribe a modern complementary examination; he does, however, consider MRI to have a role in the diagnostic procedure, and that it should be prescribed by the surgeon who will perform the operation.

MRI is non-invasive, pain free and requires no sedation for exploring traumatic meniscal lesions in children [2]. Kocher et al. [11], in 2001, reported 61.7% sensitivity and 90.2% specificity in bone-immature patients. These figures, like the present (64% sensitivity and 90% specificity) are slightly lower than those reported by Chang et al. [7] in adults (92% sensitivity and 87% specificity).

The present series (69 patients) was comparable to previous reports: McDermott et al. [8] had 51 patients, King et al. [9] 74, Zobel et al. [10] 104 and Kocher et al. [11] 139. There are several reasons for this large number:

- our department, having a pediatric ACL ligamentoplasty technique [23], treats a large number of children with knee trauma, who undergo both MRI and arthroscopy, which accounts for the rather large recruitment for a single center;
- childhood meniscal pathology would seem to be becoming more frequent [3], due to excessive sport [24], especially

pivot sports for older children, and to improved diagnostic procedures [2].

MRI exploration is not the same for the two menisci. In the medial meniscus, agreement with arthroscopy was 77% and 80% on 1st and 2nd reading, respectively—apparently a very encouraging result; there were, however, a large number of false positives (13 on 1st and 9 on 2nd reading). These findings confirm those of Zobel et al. [10]; it is noteworthy that the specialized 2nd reading improved the false-positive rate. Medial compartment analysis is thus not straightforward, with poor PPV on both readings (41 and 44%, respectively): MRI analysis is mistaken more than half the time when it detects a medial meniscal lesion. These false positives mainly concern the posterior horn, a hypervascularized region in children where intrameniscal vessels may persist [25]. The very good NPV, on the other hand, lends weight to a negative MRI scan, which will be correct in more than 90% of cases.

In the lateral meniscus, a specialized radiologist considerably improved interpretation, with 5 false positives on 1st reading and none on 2nd: i.e. an MR image read as positive by the specialist systematically corresponded to an anatomic lesion. The number of false negatives, in contrast, remained high on both readings: a posterior horn lesion may thus be masked by the popliteal tendon signal [15,16]. NPV is thus poorer in the lateral meniscus and a negative MRI should be viewed with skepticism if clinical suspicion is strong.

MRI results in children seem good overall, but in detail it depends on which meniscus, medial or lateral, is concerned. MRI serves as a diagnostic indicator and should not be considered as the absolute truth; the experience of the orthopedic surgeon [21,22,26] is primordial.

MRI involved limitations in lesion detection, but a specialized pediatric radiologist provided improvement, particularly in terms of false positives, which are the main drawback of MRI in childhood meniscal pathology. The present findings are in agreement with the conclusions drawn by White [12] as to the existence of learning curve for radiologists in interpreting meniscal lesions.

The present study involved several limitations:

- arthroscopy remains the reference tool for exploration of the knee, but may neglect certain lesions, notably in the posterior horns [20], as highlighted by Zobel et al. [10];

- the quality of MRI has markedly improved over 13 years [27], but as much cannot be said for interpretation. According to Grossman et al. [28], improved MRI quality (1.5 T vs 3 T) has not improved diagnostic precision in meniscal lesions;
- in 1995, the MRI specificities of the pediatric knee were not well or widely known if at all [9,10], and early interpretations may have borne the cost;
- the clinical data available to the specialized radiologist for the second MRI reading were very likely more complete than for the initial reading, which would somewhat bias the results.

Conclusion

The present study found 82% overall agreement of MRI with arthroscopy, 64% sensitivity and 90% specificity in the hands of a specialized radiologist, confirming previous reports in the field, with figures showing no progress over the last several years.

These findings argue for caution: MRI plays an essential role in the diagnostic procedure for traumatic meniscal lesion in children, but its findings are to be weighed against the interview and clinical results and against the pediatric orthopedic surgeon's experience.

Given the relative rarity of this pathology, the radiologist's experience is critical, especially to avoid the pitfalls of false positive readings. Radiologists still tend to diagnose to excess, and interpretation should be entrusted to a radiologist specialized in pediatrics.

At present, when a radiologist reports a medial meniscal lesion, one should be wary: in 60% of cases, it is an error. Lateral meniscal lesions, in contrast, are considerably under-diagnosed on MRI.

Disclosure of interest

The authors declare that they have no conflicts of interest concerning this article.

References

- [1] Bergstrom R, Gillquist J, Lysholm J, Hamberg P. Arthroscopy of the knee in children. *J Pediatr Orthop* 1984;4: 542–5.
- [2] Bonnard C, Chotel F. Symposium – Les lésions ligamentaires et méniscales du genou de l'enfant et de l'adolescent. *Rev Chir Orthop* 2007;93:95–139.
- [3] Stanitski CL, Harvell JC, Fu F. Observations on acute knee hemarthrosis in children and adolescents. *J Pediatr Orthop* 1993;13:506–10.
- [4] Willis RB. Meniscal injuries in children and adolescents. *Oper Tech Sports Med* 2006;14:197–202.
- [5] Prise en charge thérapeutique des lésions méniscales et des lésions du ligament croisé antérieur de l'adulte. Recommandation Haute Autorité de santé. HAS 2008. www.has-sante.fr.
- [6] Crawford R, Walley G, Bridgman S, Maffulli N. Magnetic resonance imaging versus arthroscopy in the diagnosis of knee pathology, concentrating on meniscal lesions and ACL tears: a systematic review. *Br Med Bull* 2007;84: 5–23.
- [7] Chang CY, Huang TF, Ma HL, Hung SC. Imaging evaluation of meniscal injury of the knee joint: a comparative MR imaging and arthroscopic study. *Clin Imaging* 2004;28:372–6.
- [8] McDermott MJ, Gillingham BL, Hennrikus WL. Correlation of MRI and arthroscopic diagnosis of knee pathology in children and adolescents. *J Pediatr Orthop* 1998;18:675–8.
- [9] King SJ, Carty HM, Brady O. Magnetic resonance imaging of knee injuries in children. *Pediatr Radiol* 1996;26:287–90.
- [10] Zobel MS, Borrello JA, Siegel MJ, Stewart NR. Pediatric knee MR imaging: pattern of injuries in the immature skeleton. *Radiology* 1994;190:397–401.
- [11] Kocher MS, DiCanzio J, Zurakowski D, Micheli LJ. Diagnostic performance of clinical examination and selective magnetic resonance imaging in the evaluation of intraarticular knee disorders in children and adolescents. *Am J Sports Med* 2001;29:292–6.
- [12] White LM, Schweitzer ME, Deely DM, Morrison WB. The effect of training and experience on the magnetic resonance imaging interpretation of meniscal tears. *Arthroscopy* 1997;13:224–8.
- [13] Trillat A. Chirurgie du genou. Journées lyonnaises de chirurgie du genou. Villeurbanne: Simep; 1973.
- [14] Hulet C, Burdin G, Locker B, Vielpeau C, Burbin P. Lésions méniscales traumatiques. In: *Arthroscopie*. 2^e éd. Paris: Elsevier; 2006. p. 79–90.
- [15] Stoller DW, Martin C, Crues JV, Kaplan L, Mink JH. Meniscal tears: pathologic correlation with MR imaging. *Radiology* 1987;163:731–5.
- [16] Crues, Mink J, Levy TL, Lotysch M, Stoller DW. Meniscal tears of the knee: accuracy of MR imaging. *Radiology* 1987;164:445–8.
- [17] Takeda Y, Ikata T, Yoshida S, Takai H, Kashiwaguchi S. MRI high-signal intensity in the menisci of asymptomatic children. *J Bone Joint Surg Br* 1998;80:463–7.
- [18] Cooper DE, Arnoczky SP, Warren RF. Arthroscopic meniscal repair. *Clin Sports Med* 1990;9:589–607.
- [19] Beaufilets P, Hardy P. Le ménisque latéral de l'adulte: suppl. au n° 5. *Rev Chir Orthop* 2006;92:169–94.
- [20] Sarpel Y, Ozkan C, Togrul E, Tan I, Gulsen M. Arthroscopy of the knee in pre-adolescent children. *Arch Orthop Trauma Surg* 2007;127:229–34.
- [21] Stanitski CL. Correlation of arthroscopic and clinical examinations with magnetic resonance imaging findings of injured knees in children and adolescents. *Am J Sports Med* 1998;26:2–6.
- [22] Stanitski CL. Use and abuse of knee MRI in assessment of pediatric knee intraarticular disorders. *J Pediatr Orthop* 2004;24:747–8.
- [23] Robert H, Bonnard C. The possibilities of using the patellar tendon in the treatment of anterior cruciate ligament tears in children. *Arthroscopy* 1999;15:73–6.
- [24] Peeters M. Le genou de l'enfant sportif. Chirurgie et orthopédie du genou. Monographie du groupe d'étude en orthopédie pédiatrique. Montpellier: Sauramps Médical; 1993. p. 249–61.
- [25] Cohen MD, Edwards MK. Magnetic resonance imaging of children. Philadelphia: Decker; 1990. p. 993.
- [26] Luhmann SJ, Schootman M, Gordon JE, Wright RW. Magnetic resonance imaging of the knee in children and adolescents. Its role in clinical decision-making. *J Bone Joint Surg* 2005;87:497–502.
- [27] Nemeš SF, Marlovits S, Trattnig S, Matzek W, Mayerhoefer ME, Krestan CR. High-resolution magnetic resonance imaging and conventional magnetic resonance imaging on a standard field-strength magnetic resonance system compared to arthroscopy in patients with suspected meniscal tears. *Acad Radiol* 2008;15:928–33.
- [28] Grossman JW, De Smet AA, Shinki K. Comparison of the accuracy rates of 3-T and 1.5-T MRI of the knee in the diagnosis of meniscal tear. *AJR Am J Roentgenol* 2009;193: 509–14.