

ORIGINAL RESEARCH

Quantification of Functional Mitral Regurgitation by Real-Time 3D Echocardiography

Comparison With 3D Velocity-Encoded Cardiac Magnetic Resonance

Nina Ajmone Marsan, MD,*§ Jos J. M. Westenberg, PhD,† Claudia Ypenburg, MD,* Victoria Delgado, MD,* Rutger J. van Bommel, MD,* Stijntje D. Roes, MD,‡ Gaetano Nucifora, MD,* Rob J. van der Geest, PhD,† Albert de Roos, MD, PhD,‡ Johan C. Reiber, PhD,† Martin J. Schalij, MD, PhD,* Jeroen J. Bax, MD, PhD*

Leiden, the Netherlands; and Pavia, Italy

OBJECTIVES The aim of this study was to evaluate feasibility and accuracy of real-time 3-dimensional (3D) echocardiography for quantification of mitral regurgitation (MR), in a head-to-head comparison with velocity-encoded cardiac magnetic resonance (VE-CMR).

BACKGROUND Accurate grading of MR severity is crucial for appropriate patient management but remains challenging. VE-CMR with 3D three-directional acquisition has been recently proposed as the reference method.

METHODS A total of 64 patients with functional MR were included. A VE-CMR acquisition was applied to quantify mitral regurgitant volume (Rvol). Color Doppler 3D echocardiography was applied for direct measurement, in “en face” view, of mitral effective regurgitant orifice area (EROA); Rvol was subsequently calculated as EROA multiplied by the velocity-time integral of the regurgitant jet on the continuous-wave Doppler. To assess the relative potential error of the conventional approach, color Doppler 2-dimensional (2D) echocardiography was performed: vena contracta width was measured in the 4-chamber view and EROA calculated as circular (EROA-4CH); EROA was also calculated as elliptical (EROA-elliptical), measuring vena contracta also in the 2-chamber view. From these 2D measurements of EROA, the Rvols were also calculated.

RESULTS The EROA measured by 3D echocardiography was significantly higher than EROA-4CH ($p < 0.001$) and EROA-elliptical ($p < 0.001$), with a significant bias between these measurements (0.10 cm^2 and 0.06 cm^2 , respectively). Rvol measured by 3D echocardiography showed excellent correlation with Rvol measured by CMR ($r = 0.94$), without a significant difference between these techniques (mean difference = -0.08 ml/beat). Conversely, 2D echocardiographic approach from the 4-chamber view significantly underestimated Rvol ($p = 0.006$) as compared with CMR (mean difference = 2.9 ml/beat). The 2D elliptical approach demonstrated a better agreement with CMR (mean difference = -1.6 ml/beat , $p = 0.04$).

CONCLUSIONS Quantification of EROA and Rvol of functional MR with 3D echocardiography is feasible and accurate as compared with VE-CMR; the currently recommended 2D echocardiographic approach significantly underestimates both EROA and Rvol. (J Am Coll Cardiol Img 2009;2:1245–52)

© 2009 by the American College of Cardiology Foundation

From the *Departments of Cardiology, †Division of Image Processing, and the ‡Department of Radiology, Leiden University Medical Center, Leiden, the Netherlands; and the §IRCCS Policlinico S. Matteo, Pavia, Italy. Drs. Ajmone Marsan and Delgado are financially supported by the Research Fellowship of the European Society of Cardiology. Dr. Schalij has received research grants from Biotronik, Medtronic, and Boston Scientific. Dr. Bax has received research grants from Medtronic, Boston Scientific, Bristol-Myers Squibb Medical Imaging, St. Jude Medical, Biotronik, Edwards Lifesciences, and GE Healthcare.

Manuscript received May 20, 2009; accepted July 9, 2009.

Functional mitral regurgitation (MR) is a common and serious complication in patients with global and/or regional left ventricular (LV) dilation and dysfunction and is associated with relatively high morbidity and mortality (1–4). Consequently, timely diagnosis and accurate grading of MR severity are crucial for appropriate patient management and timing of surgical intervention (2,5,6). However, quantitative assessment of MR remains challenging, and different echocardiographic modalities or semiquantitative angiographic grading have been proposed, but a true gold standard technique is still lacking (7,8). Evaluation of the effective regurgitant orifice area (EROA) and regurgitant volume (Rvol) is currently recom-

mended, applying 2-dimensional (2D) echocardiography with the proximal isovelocity surface area (PISA) or pulsed Doppler quantitative flow methods (8). However, both methods have several limitations due to indirect measurements based on imprecise hemodynamic assumptions and multiple computational steps (9–12).

In addition, an accepted direct assessment of EROA is the vena contracta width (VCW), as the narrowest cross section of the regurgitant jet (8,13,14). However, this method assumes the orifice as nearly circular, and the exact shape and size might not be accurately assessed due to the limited scan plane orientation of 2D echocardiography. Real-time 3-dimensional echocardiography (RT3DE) is now available to overcome this limitation, which is particularly relevant in patients with functional MR, in whom EROA geometry is usually complex and asymmetric (15,16). In fact, RT3DE provides unlimited image

plane orientation and, with color Doppler, allows for a direct EROA quantification (15,17,18).

Recently, velocity-encoded cardiac magnetic resonance (VE-CMR) has been proposed as a reference method for transvalvular flow quantification (19,20); in particular, the use of a 3-dimensional (3D) 3-directional acquisition has been shown to be able to optimize the conventional 2D 1-directional acquisition (21–24), providing independent MR flow quantification. Therefore, the aim of the current study was to explore in patients with functional MR, the feasibility and accuracy of direct measurement of EROA and quantification of Rvol with RT3DE, in a head-to-head comparison with VE-CMR.

To assess the relative potential error of 2D echocardiography for these measurements, 2D echocardiography was also performed in the same patient cohort.

METHODS

Study population and protocol. The study population consisted of 70 consecutive patients who were clinically referred for CMR and had functional mild-to-severe MR on color Doppler echocardiography. Functional MR was defined as leaflet tethering and incomplete leaflet coaptation in the presence of normal mitral valve anatomy and regional or global LV remodeling (25).

Patients with atrial fibrillation, irregular heart rhythm, or absolute contraindications (including cardiac devices) for CMR were excluded. The standard CMR protocol was applied to assess LV size and function. A 3D 3-directional VE-CMR acquisition was added to quantify MR. On the same day, patients also underwent 2D color Doppler echocardiography and RT3DE to quantify MR and for comparison with CMR measurements. All patients gave informed consent, and the protocol was approved by the institutional review board.

CMR. DATA ACQUISITION. Data acquisition was performed on a 1.5-T CMR scanner equipped with Powertrack 6000 gradients (ACS-NT15 Intera software release 11, Philips Medical Systems, Best, the Netherlands), with a 5-element cardiac coil placed on the chest for signal reception. The LV volumes were determined by planimetry from a series of short-axis acquisitions covering the complete LV from apex to base, following a standardized protocol described previously (26). The spatial resolution of the acquired images was $1.56 \times 1.56 \text{ mm}^2$.

For 3-directional VE-CMR, a true free-breathing 3D CMR acquisition was designed with velocity encoding in 3 orthogonal directions (field-of-view 370 mm, 3D volume scan with slab thickness 48 mm, reconstructed into 12 slices of 4 mm, echo time 3.3 ms, repetition time 14 ms, alpha 10° , acquisition voxel size $2.9 \times 3.8 \times 4.0 \text{ mm}^3$, reconstructed into $1.4 \times 1.4 \times 4.0 \text{ mm}^3$, number of signal averages 1, velocity encoding 150 cm/s in all 3 directions) and with 30 phases reconstructed during 1 average cardiac cycle from the retrospectively gated acquisition (temporal resolution between 25 and 40 ms, depending on the patient's heart rate). To reduce acquisition time, echo planar imaging was used with echoplanar imaging factor 5.

ABBREVIATIONS AND ACRONYMS

CMR = cardiac magnetic resonance

EROA = effective regurgitant orifice area

L/S = ratio of the longest and shortest diameter of effective regurgitant orifice area

LV = left ventricle/ventricular

MR = mitral regurgitation

PISA = proximal isovelocity surface area

RT3DE = real-time 3-dimensional echocardiography

Rvol = regurgitant volume

VCW = vena contracta width

VE-CMR = velocity-encoded cardiac magnetic resonance

2CH = 2-chamber view

4CH = 4-chamber view

Scan time was <5 min, depending on the subject's heart rate.

LV VOLUMES AND FUNCTION ANALYSIS. Quantification of LV end-systolic and end-diastolic volumes and ejection fraction was performed on the short-axis series with MASS analytical software (Medis, Leiden, the Netherlands) and manual contour segmentation of the epicardial and endocardial borders. In the presence of significant MR, LV ejection fraction does not represent the true systolic stroke volume. To correct for this effect, the "forward LV ejection fraction" was calculated as the ratio of the forward stroke volume (obtained from aortic flow measurements derived from VE-CMR) and LV end-diastolic volume (27).

MITRAL VALVE FLOW QUANTIFICATION. The 3D 3-directional VE-CMR acquisitions were analyzed with in-house-developed image processing software. The procedure was performed as previously described (24) and is schematically illustrated in Figure 1. In summary, from the CMR data, the 3 velocity vector components of blood flow at the level of the mitral valve plane needs to be reformatted, with the LV 4-chamber (4CH) and 2-chamber (2CH) views; this procedure required 5 to 10 min. The velocities measured perpendicularly to the reconstructed mitral valve plane need to be cor-

rected for the motion of the myocardium in basal/apical direction to obtain the true trans-valvular velocity of the blood flow (21). Therefore, the through-plane velocity of the mitral valve annulus was determined in the lateral wall and subtracted from the through-plane mitral valve flow velocities. The transvalvular volume flow was obtained by integrating the resulting velocities over the annulus area. The regurgitant volume (Rvol-CMR) was obtained by calculating the Riemann sum of backward flow during systole in the flow graph. This analysis required approximately 5 min, and its reproducibility was previously reported (24): intraobserver variation was <3%, whereas interobserver variation was <6%.

Echocardiography. STANDARD 2D ECHOCARDIOGRAPHY. Patients were imaged in the left lateral decubitus position with a commercially available system (iE33, Philips Medical Systems, N.A., Bothell, Washington) equipped with a 3.5-Mhz transducer. The VCW was measured as the narrowest portion of the MR color Doppler jet in a zoomed optimized apical 4CH view. In addition, VCW was also measured in the apical 2CH view to allow a more accurate calculation in case of asymmetric EROA. The systolic frame with the most relevant lesion size was selected for the measurement. Nyquist limits were always set between 30

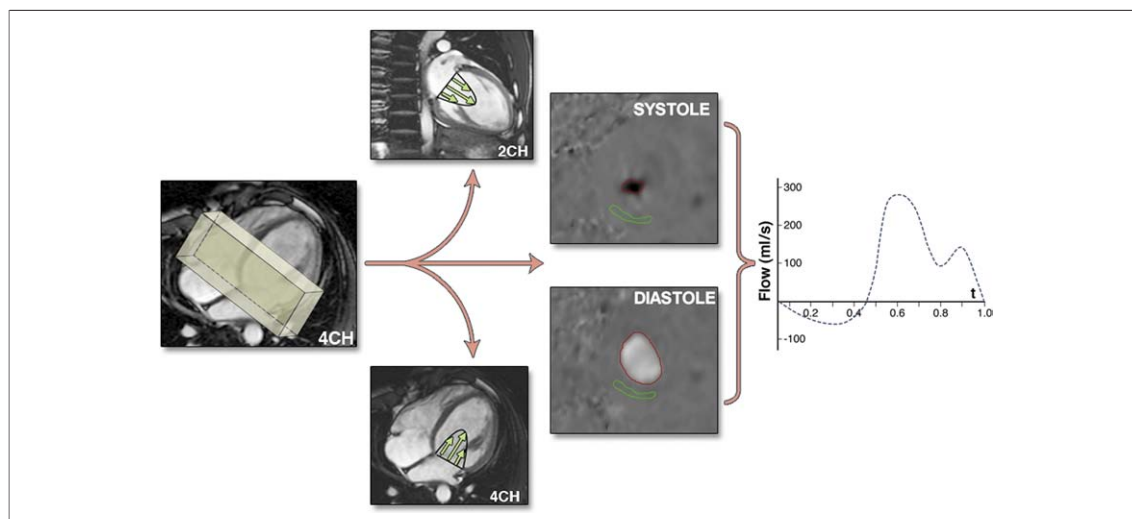


Figure 1. Reformat Procedure of Mitral Valve Flow From 3D 3-Directional VE-CMR Data

Schematic representation of reformat procedure of mitral valve flow from 3-dimensional (3D) 3-directional velocity-encoded cardiac magnetic resonance (VE-CMR) data. The acquisition is performed in a volume positioned at the basal level of the heart (left), covering the full excursion of the mitral valve during contraction and relaxation. From the 3D velocity vector field, the trans-mitral flow is retrospectively quantified by multi-planar reformatting of mitral valve in 2- (2CH) and 4-chamber (4CH) views (second panel). The through-plane velocity is constructed from the dot product with the normal vector (third panel). During systole, regurgitant flow can be identified and quantified. During diastole, mitral valve inflow is acquired. Through-plane motion correction is performed from the longitudinal velocity measured in the lateral wall (green lines). The regurgitant volume was obtained by calculating the Riemann sum of backward flow during systole in the flow graph (right panel).

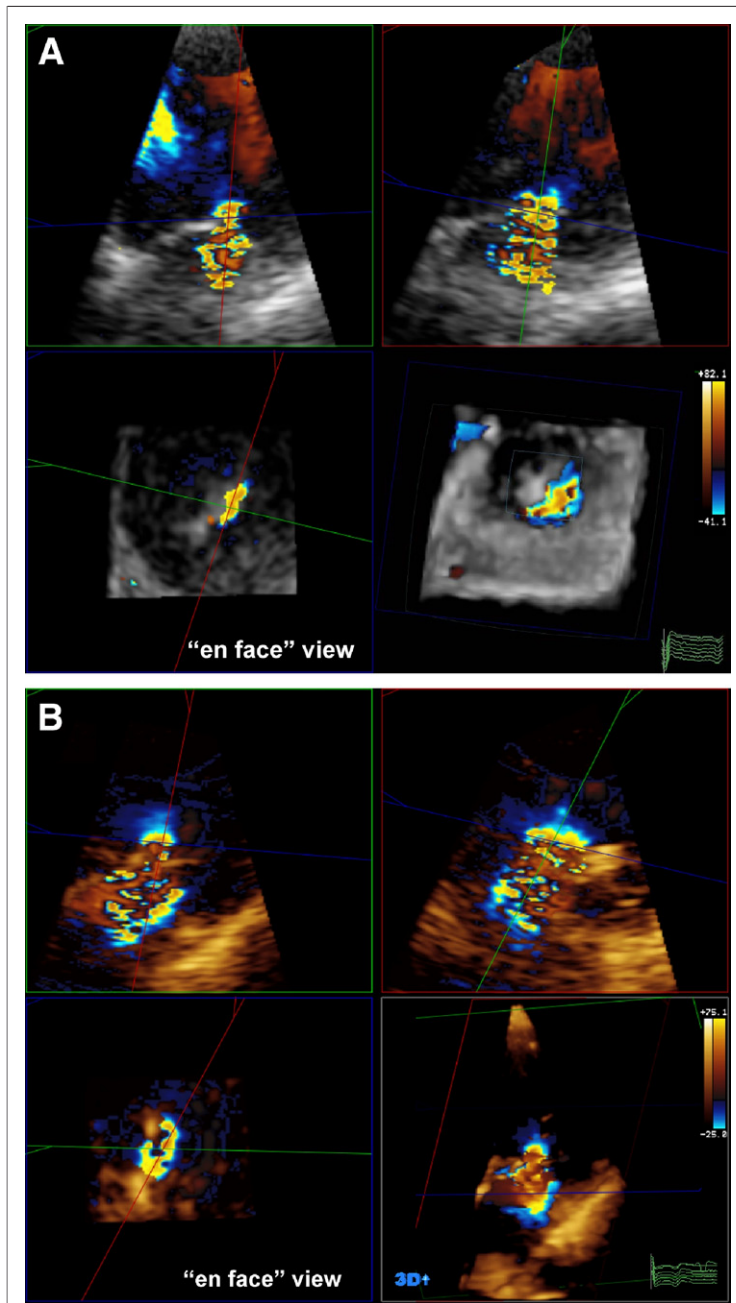


Figure 2. Real-Time 3D Echocardiographic Technique for Assessment of Vena Contracta Area (EROA-3D)

The 3-dimensional (3D) dataset is manually cropped by an image plane perpendicularly oriented to the jet direction up to the narrowest cross-sectional area of the jet. Effective regurgitant orifice area (EROA)-3D is measured by manual planimetry of the color Doppler signal tilting the image in an “en face” view. (A) Example of a patient with moderate functional mitral regurgitation (MR) and asymmetric EROA-3D (= 0.23 cm²) elongated along the leaflet coaptation line. (B) Example of a patient with severe functional MR and extremely irregular EROA-3D (= 0.48 cm²), for which geometric assumptions might not be applicable.

and 50 cm/s to avoid any over- or under-estimation, and a color gain was used that just eliminates random color speckles from nonmoving regions.

From the VCW measurements, estimates of EROA were obtained as circular (EROA-4CH = $[\pi \times (\text{VCW}-4\text{CH}/2)]^2$) as well as biplane elliptical (EROA-elliptical = $[\pi \times (\text{VCW}-4\text{CH}/2) \times (\text{VWC}-2\text{CH}/2)]$) (15). The Rvol can be estimated as EROA multiplied by the velocity time integral of the regurgitant jet on the continuous-wave Doppler.

RT3DE. The RT3DE was performed with the same ultrasound system and with an X3, fully sampled matrix transducer. Apical full-volume color Doppler datasets were obtained within 1 breath-hold, combining 7 small real-time subvolumes in a larger pyramidal volume (approximately 60° × 60°). Nyquist limits (aliasing velocity) and color gain were set as for 2D echocardiography. Analysis of the 3D images was performed offline (Q-Lab, version 6.0, Philips Medical Systems). To measure EROA (-3D), the 3D dataset was manually cropped by an image plane perpendicularly oriented to the jet direction as far as the narrowest cross-sectional area of the jet (15,18) (Fig. 2). The EROA-3D was measured by manual planimetry of the color Doppler signal, tilting the image in an “en face” view and selecting the systolic frame with the most relevant lesion size (Fig. 2). The Rvol (-3D) was derived as for 2D echocardiography. On the cropped images, the ratio of the longest and shortest diameter of EROA (L/S) was also calculated as an index of orifice shape (28). The image post-processing required 3 to 5 min.

Twenty patients were randomly identified to evaluate the inter- and intraobserver agreement for the EROA-3D. According to the Bland-Altman analysis, interobserver agreement was good: EROA-3D mean difference (\pm 2 SD) = 0.06 \pm 0.04 cm² (p = 0.43). The intraobserver agreement was also good with a mean difference (\pm 2 SD) of 0.04 \pm 0.04 cm² (p = 0.55).

Statistical analysis. Continuous data are presented as mean \pm SD (the range, when of interest). Categorical data are presented as absolute numbers or percentages. The *t* test and chi-square test were used for appropriate comparisons. For Rvol and EROA that were not normally distributed as evaluated by the Kolmogorov-Smirnov test, a log-transformation has been performed. Pearson’s correlation analysis was performed to evaluate the relation among VE-CMR, RT3DE, and 2D echocardiographic measurements of EROA and Rvol. Bland-Altman analysis was performed to evaluate the differences in Rvol and EROA assessed with CMR, RT3DE, and 2D echocardiography. The mean differences, trends, and limits of agreement are reported. A p value <0.05 was considered to be

statistically significant. A statistical software program SPSS version 16.0 (SPSS, Inc., Chicago, Illinois) was used for statistical analysis.

RESULTS

Six patients (8.5%) were excluded from further analysis because of inadequate RT3DE color Doppler images. Among the remaining 64 patients (44 men, 60 ± 11 years), 48 (75%) were referred because of ischemic cardiomyopathy with a previous myocardial infarction (31 patients with anterior myocardial infarction and 17 patients with inferoposterior myocardial infarction) and 16 (25%) patients were referred because of idiopathic dilated cardiomyopathy.

The CMR analysis revealed severe LV dilation (mean LV end-diastolic volume 273 ± 66 ml), with depressed LV systolic function (mean forward LV ejection fraction $29 \pm 10\%$). From the 3-directional VE-CMR analysis, the mean mitral Rvol was 12.9 ± 12.6 ml/beat, ranging from 2 to 63 ml/beat. No significant (more than mild) regurgitation of the other cardiac valves was detected by 3-directional VE-CMR.

RT3DE versus 2D echocardiography. The mean values and the ranges of the EROA measurements with 2D echocardiography and RT3DE are displayed in Table 1. The EROA-3D was significantly higher than EROA-4CH ($p < 0.001$) and EROA-elliptical ($p < 0.001$), and Bland-Altman analysis confirmed a significant systematic bias between these measurements (Table 2).

From the RT3DE analysis, EROA was considered significantly asymmetric when the L/S ratio was >1.5 (28). In patients with an asymmetric orifice shape ($n = 18, 28\%$), 4CH was significantly smaller as compared with patients with $L/S \leq 1.5$ ($p = 0.02$) (Table 1), indicating a regurgitant orifice elongated along the leaflet coaptation line with the 4CH view representing the narrowest and the 2CH view the widest VCW. The EROA-elliptical and EROA-3D were not significantly different, however, between patients with asymmetric or non-asymmetric EROA (Table 1).

RT3DE versus VE-CMR. The mean Rvol-3D was 12.8 ± 12.7 ml/beat, ranging from 2 to 67 ml/beat. The mean Rvol-4CH was 10.1 ± 11.9 ml/beat (from 1 to 51 ml/beat) and Rvol-elliptical was 11.3 ± 12.1 ml/beat (from 1 to 55 ml/beat).

The Rvol-3D showed an excellent correlation with Rvol-CMR ($r = 0.94$) (Fig. 3), and the Bland-Altman analysis revealed a nonsignificant

Table 1. Mean Values and Range of EROA

	Total Population (n = 64)	L/S >1.5 (n = 18)	L/S ≤1.5 (n = 46)
2D: EROA-4CH, cm ²			
Mean ± SD	0.11 ± 0.12*	0.06 ± 0.06†	0.14 ± 0.13
Range, min-max	0.008-0.64	0.008-0.27	0.008-0.64
2D: EROA-elliptical, cm ²			
Mean ± SD	0.14 ± 0.15†	0.15 ± 0.14	0.14 ± 0.16
Range, max-min	0.008-0.75	0.02-0.55	0.008-0.75
RT3DE: EROA-3D, cm ²			
Mean ± SD	0.22 ± 0.14	0.23 ± 0.14	0.20 ± 0.16
Range, max-min	0.04-0.78	0.07-0.41	0.04-0.78

Measured by 2 different 2-dimensional (2D) echocardiographic approaches (from the 4-chamber [4CH] view, and with the elliptical formula [elliptical]) and measured by real-time 3-dimensional echocardiography (RT3DE), in the total population and among patients with (ratio of the longest and shortest diameter of effective regurgitant orifice area [EROA]-3D [L/S] >1.5) and without (L/S ≤1.5) an asymmetrical regurgitant orifice. * $p < 0.001$ between 2D echocardiography and RT3DE. † $p < 0.05$ between patients with L/S >1.5 and with L/S ≤1.5.
 max = maximum; min = minimum.

bias between these techniques (Fig. 3): mean difference (RT3DE - CMR) = -0.08 ml/beat ($p = 0.87$), limits of agreement from -7.7 to 7.6 ml/beat (Table 2).

Conversely, the 2D echocardiographic approach from the 4CH view (Rvol-4CH) significantly underestimated Rvol ($p = 0.006$) as compared with CMR (Rvol-CMR) (Table 2). However, the 2D elliptical approach demonstrated a better agreement with CMR: mean difference (Rvol-elliptical - Rvol-CMR) = -1.6 ml/beat ($p = 0.04$), limits of agreement from -11.9 to 8.8 ml/beat (Table 2).

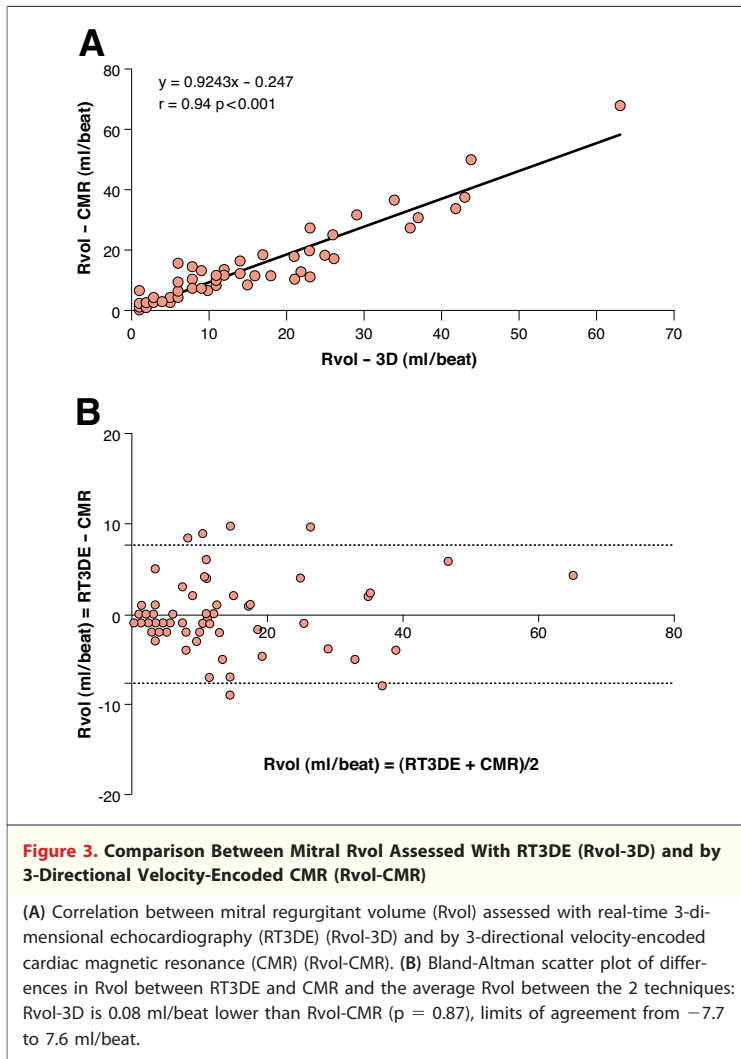
DISCUSSION

The main findings of the current study can be summarized as follows: 1) in patients with functional MR, direct assessment of EROA by RT3DE was feasible and reproducible; 2) 2D echocardiography systematically underestimated the EROA as compared with

Table 2. Summary of the Results of the Bland-Altman Analysis Applied for the EROA and Rvol Measurements

	RT3DE: EROA-3D, cm ²
2D echo: EROA-4CH, cm ²	$-0.10 (-0.26-0.08)^*$
2D echo: EROA-elliptical, cm ²	$-0.06 (-0.17-0.04)^*$
	CMR: Rvol, ml/beat
2D echo: Rvol-4CH, ml/beat	$-2.9 (-18.0-12.5)^†$
2D echo: Rvol-elliptical, ml/beat	$-1.6 (-11.9-8.8)^†$
RT3DE: Rvol-3D, ml/beat	$-0.08 (-7.7-7.6)$

Performed with 2D echocardiography (4CH view and elliptical approaches), RT3DE, and 3D 3-directional velocity-encoded cardiac magnetic resonance (CMR). The mean difference and the limits of agreements are reported. * $p < 0.001$. † $p < 0.05$.
 Rvol = regurgitant volume; other abbreviations as in Table 1.



RT3DE, and the difference between these 2 techniques was more accentuated in the presence of an asymmetric regurgitant orifice; and 3) a strong correlation was observed between RT3DE and CMR for the measurement of Rvol, with no significant bias between these 2 techniques; conversely, 2D echocardiography significantly underestimated Rvol as compared with CMR.

Quantification of MR. RT3DE VERSUS 2D ECHOCARDIOGRAPHY. Accurate grading of MR severity is an important but still controversial issue. Currently, conventional 2D echocardiography is the method of choice for the assessment of MR (8), although the limitations of this technique are well known. One of the most commonly used measures is the ratio between the regurgitant jet area and the left atrial area. However, this method is semiquantitative and rather subjective. In turn, quantitative approaches, such as PISA and pulsed Doppler quantitative flow methods, are limited

by hemodynamic and geometric assumptions that introduce inaccuracies and by complicated and time-consuming acquisitions and calculations (8–11). For estimation of MR severity, 2D echocardiographic measurement of VCW has also been proposed as a direct representation of the EROA (8,13,14). This approach assumes the EROA shape to be either circular or elliptical. However, these assumptions might not be applicable when mitral valve geometry is significantly altered (29) and the regurgitant orifice shows an irregular shape. Particularly in patients with functional MR, EROA is typically elongated along the semilunar-shaped leaflet coaptation line, which contributes to a significant underestimation of the regurgitant orifice when measured from the 4-chamber or parasternal long-axis views (15,16). In this group of patients, lower thresholds to define severe MR and to identify patients with poor prognosis have been proposed (EROA ≥ 0.2 cm² instead of 0.4 cm² and Rvol ≥ 30 ml/beat instead of ≥ 60 ml/beat) (2,3,30). This difference might be explained by the changes in LV and left atrium function and compliance (2,3), but the difference is probably also related to a significant underestimation of MR severity by conventional 2D echocardiographic methods in the presence of an asymmetric regurgitant orifice.

Color Doppler RT3DE, allowing for an unlimited plan orientation and in particular for an “en face” view of the mitral valve, provides a direct assessment of size and shape of regurgitant orifice, obviating the geometric assumptions applied by 2D echocardiography (15,17,18,28). Initial studies showed the incremental value of RT3DE measurements of EROA over 2D PISA and VCW. In particular, the studies by Iwakura *et al.* (28) and Kahlert *et al.* (15) emphasized the importance of a 3D approach in patients with functional MR, in whom 2D echocardiography significantly underestimated the size of the regurgitant orifice. Similarly, in the current study a significant difference in the measurement of EROA was observed between RT3DE and 2D echocardiography (-0.10 cm² for EROA-4CH, and -0.06 cm² for EROA-elliptical); also, 2D echocardiography underestimated EROA particularly in patients with an asymmetric regurgitant orifice ($L/S > 1.5$). Thus far, a true validation study of RT3DE measurement of EROA is lacking, because previous studies were limited to comparisons between different echocardiographic techniques or used semiquantitative angiographic grading as a reference (15,18,28). The present study is the first systematic comparison between RT3DE and VE-CMR, which has been recently proposed as the reference method for quantification of MR.

RT3DE VERSUS VE-CMR. VE-CMR is particularly suitable for determining trans-valvular blood flow, providing quantitative information on moving spins (31), and has been recently proposed as a reference method (19,20). However, conventional single-slice 1-directional VE-CMR showed some limitations (21), in particular because the acquisition plane cannot be adapted to the motion of the valve, and currently the most accurate approach is considered the 3D 3-directional VE-CMR with retrospective valve tracking. This technique is able to cover the complete velocity vector field of the blood flow and to correct for the through-plane myocardial motion in the apical-basal direction (22,23). Furthermore, it has been validated in vitro with flow phantoms and in vivo and showed excellent reproducibility (24).

In the current study, RT3DE measurement of Rvol was compared against 3D 3-directional VE-CMR. An excellent correlation between the 2 techniques was found without a significant bias. The residual nonsignificant difference between RT3DE and CMR might be explained by 2 sources of errors: the fixed position, and the eventual misalignment of the continuous-wave Doppler ultrasound beam to the flow direction. Furthermore, imaging the region of interest with RT3DE can be complicated by acoustic attenuation from cardiac and thoracic structures.

The currently recommended 2D approach, providing a less accurate measurement of the EROA and presenting the same limitations of the Doppler acquisitions, showed a significant underestimation of the Rvol when compared with 3D 3-directional VE-CMR. In particular, a mean bias between these 2 techniques of -2.9 ml/beat ($p < 0.05$, limits of agreement from -18.0 to 12.5 ml/beat) might easily

lead to a misdiagnosis of the severity of MR (mild instead of moderate or moderate instead of mild).

Clinical implications. The presence of functional MR has important prognostic value, and accurate assessment of its severity is crucial for risk stratification and clinical decision-making (1-6). In the present study, quantification of Rvol by RT3DE was demonstrated to be feasible and highly accurate compared with 3D 3-directional VE-CMR and, consequently, might be proposed as a better alternative to conventional 2D echocardiographic measurements. In addition, RT3DE will probably overcome the need for 2 different cutoff values to define severity of organic and functional MR, providing direct and accurate quantification of the EROA. Further multicenter studies are needed to confirm the present results, and follow-up data are necessary to explore the prognostic implications of these measures.

Of note, RT3DE technology is in continuous progress and will lead to further improvement in the image quality (allowing for a direct assessment of the regurgitant orifice without color Doppler) and in the temporal resolution (higher frame rate).

CONCLUSIONS

Quantification of the regurgitant orifice and volume of functional MR with RT3DE is feasible and accurate and demonstrated to be superior to the currently recommended 2D echocardiographic approach in a head-to-head comparison with 3D 3-directional VE-CMR.

Reprint requests and correspondence: Dr. Jeroen J. Bax, Department of Cardiology, Leiden University Medical Center, Albinusdreef 2, 2333 ZA Leiden, the Netherlands. *E-mail:* j.j.bax@lumc.nl.

REFERENCES

1. Bursi F, Enriquez-Sarano M, Nkomo VT, et al. Heart failure and death after myocardial infarction in the community: the emerging role of mitral regurgitation. *Circulation* 2005;111:295-301.
2. Grigioni F, Enriquez-Sarano M, Zehr KJ, Bailey KR, Tajik AJ. Ischemic mitral regurgitation: long-term outcome and prognostic implications with quantitative Doppler assessment. *Circulation* 2001;103:1759-64.
3. Grigioni F, Detaint D, Avierinos JF, Scott C, Tajik J, Enriquez-Sarano M. Contribution of ischemic mitral regurgitation to congestive heart failure after myocardial infarction. *J Am Coll Cardiol* 2005;45:260-7.
4. Jung B, Baron G, Butchart EG, et al. A prospective survey of patients with valvular heart disease in Europe: the Euro Heart Survey on Valvular Heart Disease. *Eur Heart J* 2003;24:1231-43.
5. Enriquez-Sarano M, Avierinos JF, Messika-Zeitoun D, et al. Quantitative determinants of the outcome of asymptomatic mitral regurgitation. *N Engl J Med* 2005;352:875-83.
6. Rosenhek R, Rader F, Klaar U, et al. Outcome of watchful waiting in asymptomatic severe mitral regurgitation. *Circulation* 2006;113:2238-44.
7. Enriquez-Sarano M, Seward JB, Bailey KR, Tajik AJ. Effective regurgitant orifice area: a noninvasive Doppler development of an old hemodynamic concept. *J Am Coll Cardiol* 1994;23:443-51.
8. Zoghbi WA, Enriquez-Sarano M, Foster E, et al. Recommendations for evaluation of the severity of native valvular regurgitation with two-dimensional and Doppler echocardiography. *J Am Soc Echocardiogr* 2003;16:777-802.
9. Enriquez-Sarano M, Miller FA Jr., Hayes SN, Bailey KR, Tajik AJ, Seward JB. Effective mitral regurgitant orifice area: clinical use and pitfalls of the proximal isovelocity surface area method. *J Am Coll Cardiol* 1995;25:703-9.

10. Schwammenthal E, Chen C, Benning F, Block M, Breithardt G, Levine RA. Dynamics of mitral regurgitant flow and orifice area. Physiologic application of the proximal flow convergence method: clinical data and experimental testing. *Circulation* 1994;90:307-22.
11. Utsunomiya T, Ogawa T, Doshi R, et al. Doppler color flow "proximal isovelocity surface area" method for estimating volume flow rate: effects of orifice shape and machine factors. *J Am Coll Cardiol* 1991;17:1103-11.
12. Zoghbi WA, Quinones MA. Determination of cardiac output by Doppler echocardiography: a critical appraisal. *Herz* 1986;11:258-68.
13. Hall SA, Brickner ME, Willett DL, Irani WN, Afridi I, Grayburn PA. Assessment of mitral regurgitation severity by Doppler color flow mapping of the vena contracta. *Circulation* 1997;95:636-42.
14. Mascherbauer J, Rosenhek R, Bittner B, et al. Doppler echocardiographic assessment of valvular regurgitation severity by measurement of the vena contracta: an in vitro validation study. *J Am Soc Echocardiogr* 2005;18:999-1006.
15. Kahlert P, Plicht B, Schenk IM, Janosi RA, Erbel R, Buck T. Direct assessment of size and shape of noncircular vena contracta area in functional versus organic mitral regurgitation using real-time three-dimensional echocardiography. *J Am Soc Echocardiogr* 2008;21:912-21.
16. Otsuji Y, Handschumacher MD, Schwammenthal E, et al. Insights from three-dimensional echocardiography into the mechanism of functional mitral regurgitation: direct in vivo demonstration of altered leaflet tethering geometry. *Circulation* 1997;96:1999-2008.
17. Irvine T, Li XN, Rusk R, Lennon D, Sahn DJ, Kenny A. Three dimensional colour Doppler echocardiography for the characterisation and quantification of cardiac flow events. *Heart* 2000;84 Suppl 2:II2-6.
18. Khanna D, Vengala S, Miller AP, et al. Quantification of mitral regurgitation by live three-dimensional transthoracic echocardiographic measurements of vena contracta area. *Echocardiography* 2004;21:737-43.
19. Buck T, Plicht B, Kahlert P, Schenk IM, Hunold P, Erbel R. Effect of dynamic flow rate and orifice area on mitral regurgitant stroke volume quantification using the proximal isovelocity surface area method. *J Am Coll Cardiol* 2008;52:767-78.
20. Stewart RA, Raffel OC, Kerr AJ, et al. Pilot study to assess the influence of beta-blockade on mitral regurgitant volume and left ventricular work in degenerative mitral valve disease. *Circulation* 2008;118:1041-6.
21. Kayser HW, Stoel BC, van der Wall EE, van der Geest RJ, de Roos A. MR velocity mapping of tricuspid flow: correction for through-plane motion. *J Magn Reson Imaging* 1997;7:669-73.
22. Westenberg JJ, Danilouchkine MG, Doornbos J, et al. Accurate and reproducible mitral valvular blood flow measurement with three-directional velocity-encoded magnetic resonance imaging. *J Cardiovasc Magn Reson* 2004;6:767-76.
23. Westenberg JJ, Doornbos J, Versteegh MI, et al. Accurate quantitation of regurgitant volume with CMR in patients selected for mitral valve repair. *Eur J Cardiothorac Surg* 2005;27:462-6.
24. Westenberg JJ, Roes SD, Ajmone Marsan N, et al. Mitral valve and tricuspid valve blood flow: accurate quantification with 3D velocity-encoded MR imaging with retrospective valve tracking. *Radiology* 2008;249:792-800.
25. Gillam LD. Is it time to update the definition of functional mitral regurgitation?: structural changes in the mitral leaflets with left ventricular dysfunction. *Circulation* 2008;118:797-9.
26. Westenberg JJ, van der Geest RJ, Lamb HJ, et al. MRI to evaluate left atrial and ventricular reverse remodeling after restrictive mitral annuloplasty in dilated cardiomyopathy. *Circulation* 2005;112: I437-42.
27. Westenberg JJ, Braun J, Van de Veire NR, et al. Magnetic resonance imaging assessment of reverse left ventricular remodeling late after restrictive mitral annuloplasty in early stages of dilated cardiomyopathy. *J Thorac Cardiovasc Surg* 2008;135:1247-52.
28. Iwakura K, Ito H, Kawano S, et al. Comparison of orifice area by transthoracic three-dimensional Doppler echocardiography versus proximal isovelocity surface area (PISA) method for assessment of mitral regurgitation. *Am J Cardiol* 2006;97:1630-7.
29. Kwan J, Qin JX, Popovic ZB, Agler DA, Thomas JD, Shiota T. Geometric changes of mitral annulus assessed by real-time 3-dimensional echocardiography: becoming enlarged and less nonplanar in the anteroposterior direction during systole in proportion to global left ventricular systolic function. *J Am Soc Echocardiogr* 2004;17: 1179-84.
30. Vahanian A, Baumgartner H, Bax J, et al. Guidelines on the management of valvular heart disease: The Task Force on the Management of Valvular Heart Disease of the European Society of Cardiology. *Eur Heart J* 2007;28:230-68.
31. Wigstrom L, Ebbens T, Fyrenius A, et al. Particle trace visualization of intracardiac flow using time-resolved 3D phase contrast CMR. *Magn Reson Med* 1999;41:793-9.

Key Words: cardiac magnetic resonance ■ functional mitral regurgitation ■ real-time 3-dimensional echocardiography.