

# Biliary complications following orthotopic liver transplantation: May contrast-enhanced MR Cholangiography provide additional information?

Piero Boraschi<sup>a,\*</sup>, Francescamaria Donati<sup>a</sup>, Roberto Gigoni<sup>a</sup>, Franco Filippini<sup>b</sup>

<sup>a</sup> 2nd Unit of Radiology, Department of Diagnostic Radiology, Vascular and Interventional Radiology, and Nuclear Medicine—Pisa University Hospital, Via Paradisa 2, 56124 Pisa, Italy

<sup>b</sup> Hepatobiliary Surgery and Liver Transplantation—Pisa University Hospital, Via Paradisa 2, 56124 Pisa, Italy

## ARTICLE INFO

### Article history:

Received 17 March 2016

Received in revised form 7 May 2016

Accepted 7 May 2016

Available online 6 June 2016

### Keywords:

Liver transplantation

Biliary complications

MR Cholangiography

Contrast-enhanced MR Cholangiography

Mangafodipir trisodium (Mn-DPDP)

## ABSTRACT

**Purpose:** To assess whether contrast-enhanced T1-weighted MR Cholangiography may provide additional information in the evaluation of biliary complications in orthotopic liver transplant recipients.

**Material and methods:** Eighty liver transplant patients with suspicion of biliary adverse events underwent MR imaging at 1.5 T scanner. After acquisition of axial T1-/T2-weighted images and conventional T2-weighted MR Cholangiography (image set 1), 3D gradient-echo T1-weighted fat-suppressed LAVA (Liver Acquisition with Volume Acceleration) sequences were obtained about 30 min after intravenous infusion of mangafodipir trisodium (Mn-DPDP, Teslascan®) (image set 2). The diagnostic value of mangafodipir trisodium-enhanced MR Cholangiography in the detection of biliary complications was tested by separate analysis results of image set 1 alone and image set 1 and 2 together. MRI results were correlated with direct cholangiography in 46 patients, surgery in 14 and/or clinical-radiological follow-up in the remaining 20 cases.

**Results:** The level of confidence in the assessment of biliary adverse events was significantly increased by the administration of mangafodipir trisodium ( $p < 0.05$ ). Particularly, contrast-enhanced T1-weighted LAVA sequences tended to out-perform conventional T2-weighted MR Cholangiography in the delineation of anastomotic and non-anastomotic biliary strictures and in the diagnosis of biliary leak.

**Conclusions:** Contrast-enhanced T1-weighted MR Cholangiography may improve the level of diagnostic confidence provided by conventional T2-weighted MR Cholangiography in the evaluation of biliary complications after orthotopic liver transplantation.

© 2016 The Author(s). Published by Elsevier Ltd. This is an open access article under the CC BY-NC-ND license (<http://creativecommons.org/licenses/by-nc-nd/4.0/>).

## 1. Introduction

Orthotopic liver transplantation (OLT) is actually considered the best treatment option for end-stage liver disease, as well as for acute hepatic failure [1]. Despite the continuous improvement in survival over the years [2], biliary complications are still common and represent important causes of mortality (between 2% and 7%), morbidity, and graft dysfunction after OLT. Adverse events such as biliary strictures, stones and leakages, can occur in a percentage ranging between 5.8% and 24.5% of adult liver transplant recipients and their prompt identification and appropriate management is essential for the survival of graft and patient [3,4].

\* Corresponding author.

E-mail addresses: [p.boraschi@do.med.unipi.it](mailto:p.boraschi@do.med.unipi.it), [p.boraschi@gmail.com](mailto:p.boraschi@gmail.com) (P. Boraschi).

<http://dx.doi.org/10.1016/j.ejro.2016.05.003>

2352-0477/© 2016 The Author(s). Published by Elsevier Ltd. This is an open access article under the CC BY-NC-ND license (<http://creativecommons.org/licenses/by-nc-nd/4.0/>).

Several authors [5–11] have reported that MR Cholangiography (MRC) has good results in identifying biliary complications following liver transplantation, suggesting that it may be a reliable non-invasive diagnostic method for imaging the biliary tract in these patients. Mangafodipir trisodium (Mn-DPDP, Teslascan®) is a contrast agent that consists of an organic ligand, fodipir (DPDP) and manganese (Mn) [12]. This hepato-biliary contrast medium is administered intravenously, taken up by the liver, and transported to bile, where it causes shortening of the T1 relaxation time as a result of paramagnetic effects of manganese ion [13]. Since it is excreted via the biliary tract in a percentage of about 20%, Mn-DPDP-enhanced T1-weighted MR cholangiograms may potentially increase reliability of MR examination or decrease the occurrence of a non-diagnostic or equivocal interpretation.

Our study was aimed to assess whether contrast-enhanced MR Cholangiography may provide additional information in the

evaluation of biliary complications in orthotopic liver transplant recipients.

## 2. Material and methods

### 2.1. Patients

A series of eighty consecutive patients (57 males and 23 females; age range: 19–67 years; mean age: 53 years) prospectively underwent MR examination between three and twenty-four months after liver transplant.

Liver transplantations were all full grafts from deceased donors. The indications for liver transplantation were represented by hepatocellular carcinoma (n=23), HCV-related hepatic cirrhosis (n=19), HBV-related hepatic cirrhosis (n=3), mixed HBV/HDV-related hepatic cirrhosis (n=7), alcoholic cirrhosis (n=9), fulminant hepatic failure (n=6), cryptogenic hepatic cirrhosis (n=6), Budd-Chiari syndrome (n=1), primary biliary cirrhosis (n=1), primary sclerosing cholangitis (n=1), Caroli's disease (n=1), cholangiocarcinoma (n=1), polycystic hepatic disease (n=1), hepatic alveolar echinococcosis (n=1).

The MR examinations were performed for altered liver function tests (elevated ALT, AST, gamma-glutamyl transpeptidase, alkaline phosphatase, bilirubin) associated or not to abnormalities at ultrasound (biliary dilation; biliary wall thickening; suspected lithiasis; liver parenchymal abnormalities).

In our series biliary reconstruction was performed with choledoch-choledochostomy in seventy-five patients (71 with and 4 without a T-tube stent) and with hepatico-jejunostomy in five subjects. A T-tube is usually placed through a choledochotomy in the recipient common bile duct and left in place for about three months in order to monitor bile and stent the anastomosis with its proximal limb; in our liver transplant center T-tube cholangiography is performed if necessary during this period and in all cases, before the removal of T-tube. Direct cholangiographic techniques, represented by endoscopic retrograde cholangiography (ERC) or percutaneous trans-hepatic cholangiography (PTC), were utilized in 46 patients within 7 days of the MR examination, and were considered the "gold standard" methods for biliary tree imaging. In 14 subjects requiring surgery, surgical findings associated with imaging and interventional procedures were used to validate MRI results. In the remaining 20 recipients in which no biliary abnormality was identified at MR examination, clinical follow-up was integrated with ultrasound and/or MR imaging for a period of at least twelve months (ultrasound every 3 months and MR exam every 6 months).

Institutional review board approval was obtained for this study and a written informed consent was signed by all the enrolled patients after the nature of the procedure had been fully explained.

### 2.2. MR imaging and MR Cholangiography

MR examinations were performed with a 1.5 T scanner (Signa HDx; GE Healthcare, Milwaukee, Wis) utilizing a twelve-channel phased-array body coil.

In order to improve the visualization of the duodenum, 300 ml of water was orally administered about 10 min before MR exam. Besides, immediately before starting MR imaging, scopolamine methyl-bromide (Buscopan® 20 mg/ml, Boehringer Ingelheim) was intramuscularly administered in order to avoid peristaltic artefacts.

The imaging protocol began with axial, breath-hold, with and without fat-suppression, spoiled gradient-echo (SPGR) T1-weighted images (repetition time, 110–130 ms; echo time, minimum full, with effective 2.1–2.3 ms; flip angle, 80°; section thickness, 5 mm; interslice gap, 0.5 mm; matrix size, 256 × 192

pixels; signal averaged, 1; acquisition time, 28–32 s), axial, respiratory-triggered, fat-suppressed, fast spin-echo (FSE) T2-weighted sequence (repetition time automatically adapted to the patient's breathing pattern, 6000–18000 ms; echo time, 95.5 ms; echo train length, 16; section thickness, 5 mm; interslice gap, 0.5 mm; signals averaged, 3–4; acquisition time, 3–4 min) and/or axial, breath-hold, single-shot fast spin-echo (SSFSE) T2-weighted sequence (repetition time, minimum; echo time, 80 ms; section thickness, 5 mm; interslice gap, 0.5 mm; signal averaged, 0.5–0.6; acquisition time, 18–24 s) in order to cover the liver and the biliary tract.

MR Cholangiography was performed utilizing a coronal respiratory-triggered, fat-suppressed, two-dimensional, heavily T2-weighted fast spin-echo sequence, the imaging parameters of which were: repetition time (automatically adapted to the patient's breathing pattern), 4500–9000 ms; echo time, 504 ms; echo train length, 16–32; section thickness, 2–2.5 mm with no interslice gap; field of view, 35–45 cm; matrix size, 224 × 192 pixels; 2–4 signals averaged. Anterior-posterior spatial pre-saturation was used for all of the images. The receive bandwidth was 62.5 kHz, and flow compensation and extended dynamic range options were also used. The images were acquired over a period of 2–4 min. Coronal breath-hold, thick-slab, single-shot fast spin-echo (SSFSE) T2-weighted sequences (effective echo time, 1102 ms; thickness, 10 and 40–50 mm; field of view, 35–45 cm; matrix size, 448 × 224 pixels; 0.5 signal acquired; acquisition time, 2–3 s for every image) were also acquired. The pre-contrast study represented our image set 1.

Our protocol then included a three-dimensional fat-suppressed breath-hold gradient-echo T1-weighted LAVA (Liver Acquisition with Volume Acceleration) sequence obtained 30 min after the end of the intravenous infusion of mangafodipir trisodium (Mn-DPDP, Teslascan®; GE Healthcare) in the coronal and axial planes. In all patients, Mn-DPDP was infused intravenously at a dosage of 0.5 ml/kg, with a flow-rate of 2–3 ml/min, over about 10–12 min. The parameters of this sequence were the following: 4.3–4.1/2.0–1.9, repetition time ms/echo time ms; 7.0, inversion time, ms; 15°, flip angle; 2.0–2.4 mm slab thickness/–1.0 to 1.2 mm spacing; 380–450 mm, field of view; 224 × 192, matrix size; 1, signals acquired and 15–18 s acquisition time. Post-contrast T1-weighted sequences were also obtained in a delayed phase, between 60 and 120 min after contrast agent administration in 22 out of 80 patients. The post-contrast study represented our image set 2.

### 2.3. Image analysis

Two experienced abdominal radiologists reviewed in conference the MR images and applied Maximum Intensity Projection (MIP), Volume Rendering (VolRend) and other multiplanar reformatting techniques to the data sets of coronal thin-slab fast spin-echo T2-weighted sequence and coronal contrast-enhanced T1-weighted LAVA sequence on an independent workstation connected to the MR scanner (Advantage Windows 4.4; GE Healthcare). The observers were blinded to patient identification and all clinical, laboratory, and previous imaging findings.

The MR exams were evaluated at the console in an ongoing manner (after the study was done) for the depiction of biliary anatomy and for the presence of biliary system complications such as intra- and extra-hepatic biliary ductal dilatation, strictures, stones, leakage and so on. MR studies were considered to be diagnostic by the two reviewers when they well exhibited the biliary anatomy including visualization of the surgical anastomosis. The maximum caliber of the pre- and post-anastomotic common bile duct was also measured at the console; the intra- and extra-hepatic bile ducts

**Table 1**  
Biliary complications in our series of 80 liver transplanted patients.

Findings	No. of patients
Anastomotic stricture	15
Non-anastomotic stricture including typical ITBL	28
Sphincter of Oddi dysfunction (SOD)	10
Biliary stones, sludge, and casts	22
Biliary leakage	6
Patients with regular or normal biliary tree anatomy	21

were considered to be dilated if their diameter exceeded 2 and 7 mm, respectively.

Subsequently, the diagnostic value of mangafodipir trisodium-enhanced MR Cholangiography to identify presence and site of biliary complications was tested by separate analysis results of image set 1 alone and image set 1 and 2 together. The level of diagnostic confidence of different image sets was graded using a 3-point-scale: not very confident (1); moderately confident (2); very confident (3).

Other two observers (a radiologist and a surgeon) analyzed in conference the ERC and the PTC images using the clinical, laboratory, endoscopic and imaging data during their review.

#### 2.4. Statistical analysis

The distribution of qualitative variables was expressed as the relative frequency of the various modalities under observation. The distribution of quantitative variables was expressed as the mean, minimum, maximum and number of observations.

MRI findings were correlated with direct cholangiography, surgery and/or clinical-radiological follow-up and defined as true positives when they correctly identified biliary complications confirmed by the final diagnosis reference standards; false positives when they were not confirmed by direct cholangiography, surgery and/or clinical-radiological follow-up; false negatives when complications detected by direct cholangiography, surgery and/or clinical-radiological follow-up were not observed by MR examination; true negatives when the absence of complications was confirmed by direct cholangiography, surgery and/or clinical-radiological follow-up.

Sensitivity, specificity, diagnostic accuracy, positive predictive value (PPV), and negative predictive value (NPV) of the reviewers for the detection of all types of biliary complications were calculated in order to evaluate the diagnostic yield of MR imaging. The level of diagnostic confidence of image set 1 alone versus image set 1 and 2 together (including Mn-DPDP-enhanced images) was compared using receiver operating characteristic (ROC) analysis. The diagnostic accuracy was estimated by calculating the area under the ROC curve.

A *p* value less than 0.05 was considered significant.

### 3. Results

MR studies were judged diagnostic by the two reviewers in all eighty patients.

Various biliary complications were identified in 59 out of the 80 liver recipients (74%) and are reported in Table 1. Twenty-one subjects showed regular or normal biliary tree anatomy, whereas in the remaining fifty-nine patients one or more of the following complications were observed: anastomotic strictures (*n* = 15), non-anastomotic strictures including typical “ischemic-type biliary lesions” (ITBL) (*n* = 28), sphincter of Oddi dysfunction (SOD) (*n* = 10), biliary stones, sludge, and casts (*n* = 22) and biliary leakage (*n* = 6).

In our series non-anastomotic strictures including typical ischemic-type biliary lesions were the most frequent adverse events; they prevalently involved the hepatic confluence and extra-

hepatic biliary system of the graft and were confirmed by gold standard methods in all 28 cases. Mn-DPDP allowed a better depiction and a more precise delineation of the extension of the restricted biliary segment, particularly at the level of hepatic bifurcation (Fig. 1). In a recipient a left hepatic duct stricture on MR imaging was not considered significant on ERC and was not endoscopically treated (1 false positive case).

On the other hand, in 14 out of 15 cases of anastomotic strictures, the site of biliary obstruction was correctly assessed by the reviewers and the dilated biliary system above the stenosis was completely visualized on MR images; there was a 100% correlation between MR Cholangiography and direct cholangiography findings or surgical reports (Fig. 2). In two of these patients no excretion of the hepato-biliary contrast agent was observed after two hours from administration and so contrast-enhanced T1-weighted MRC was not obtained. Direct cholangiography did not confirm an anastomotic stricture diagnosed on MRC images (1 false positive case); in this patient the discrepancy in the calibre of the donor and recipient common bile ducts (ratio 2:1) was interpreted as a stricture at the anastomotic site, but it was due to the anatomical conformation of pre- and post-anastomotic biliary tree. Another anastomotic stricture graded as mild on ERC was misdiagnosed as an artefact at MR Cholangiography (1 false negative).

The reviewers correctly identified all cases of biliary stones, sludge, and casts (*n* = 22) in the extra-hepatic biliary tract on MR images. Stones were typically recognized as low-signal-intensity areas surrounded by high-signal-intensity bile in the posterior portion of the ducts on axial images and were seen alone or associated with both anastomotic and non-anastomotic strictures (Fig. 3).

Moreover, on the combined set of MR images (set 1 and set 2 together) the reviewers diagnosed all six cases of biliary leakage; this was due to the fact that contrast-enhanced MRC was particularly helpful in identifying the site of the bile leak and directly visualized contrast material extravasation into the fluid collections (Fig. 4).

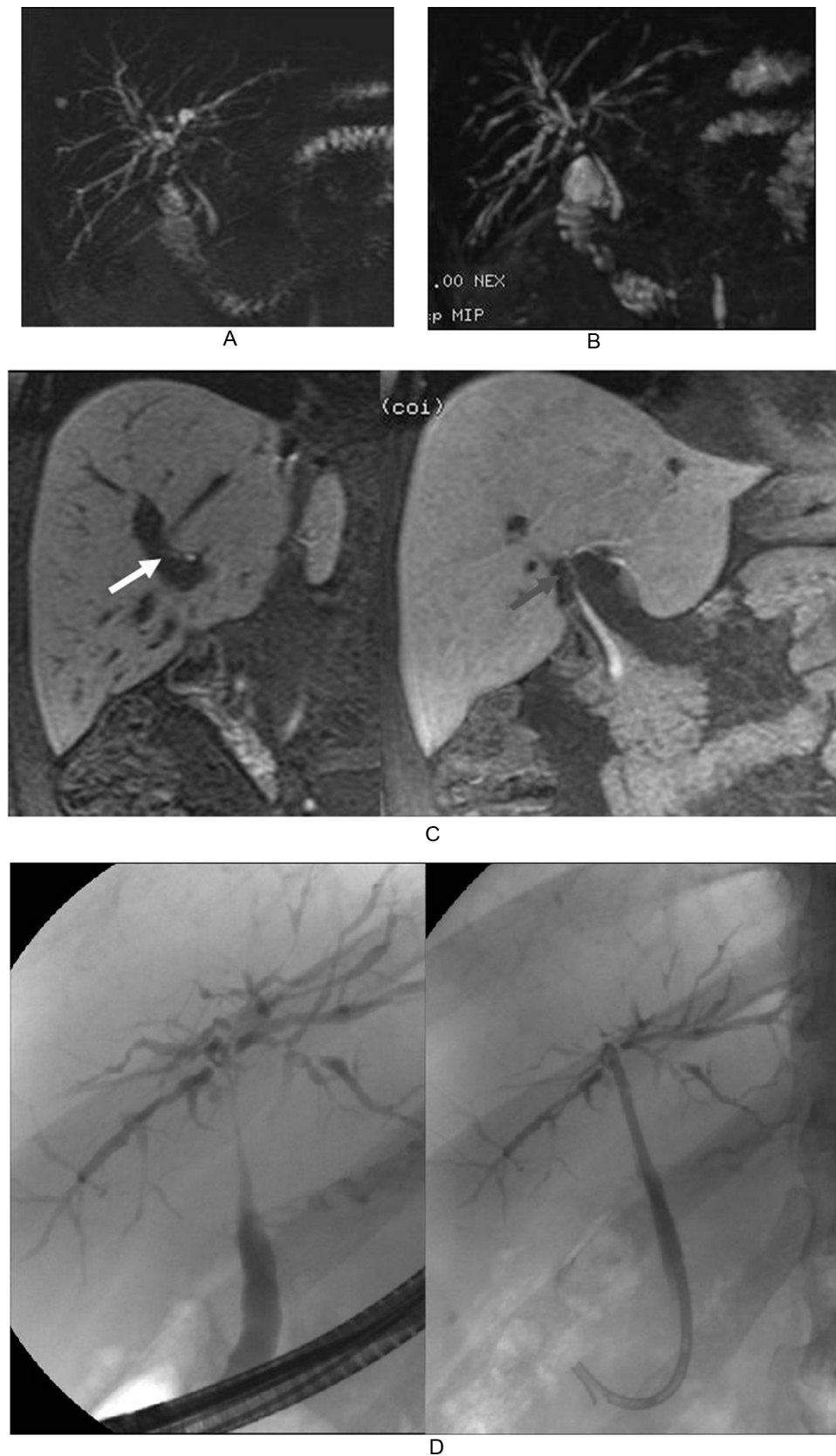
At last, in all the patients with sphincter of Oddi dysfunction we observed on MR images a significant dilatation of both recipient and donor common bile duct in the presence of narrowing of the terminal portion of recipient's common bile duct. In these cases, contrast-enhanced MR imaging also allowed to obtain functional information on the degree of biliary obstruction and increased the diagnostic confidence of un-enhanced MR images.

Overall, on the basis of observers' readings of combined image set 1 and image set 2 (pre-contrast study including T2-weighted MRC and contrast-enhanced MR Cholangiography), post-OLT evaluation of the biliary system with MR imaging resulted in 99 correct diagnoses (accuracy, 97%) and 3 (3%) incorrect diagnoses. Sensitivity, specificity, positive predictive value (PPV), and negative predictive value (NPV) of the reviewers' readings for the diagnosis of all types of biliary adverse events in liver recipients were 99%, 90%, 98% and 95%, respectively.

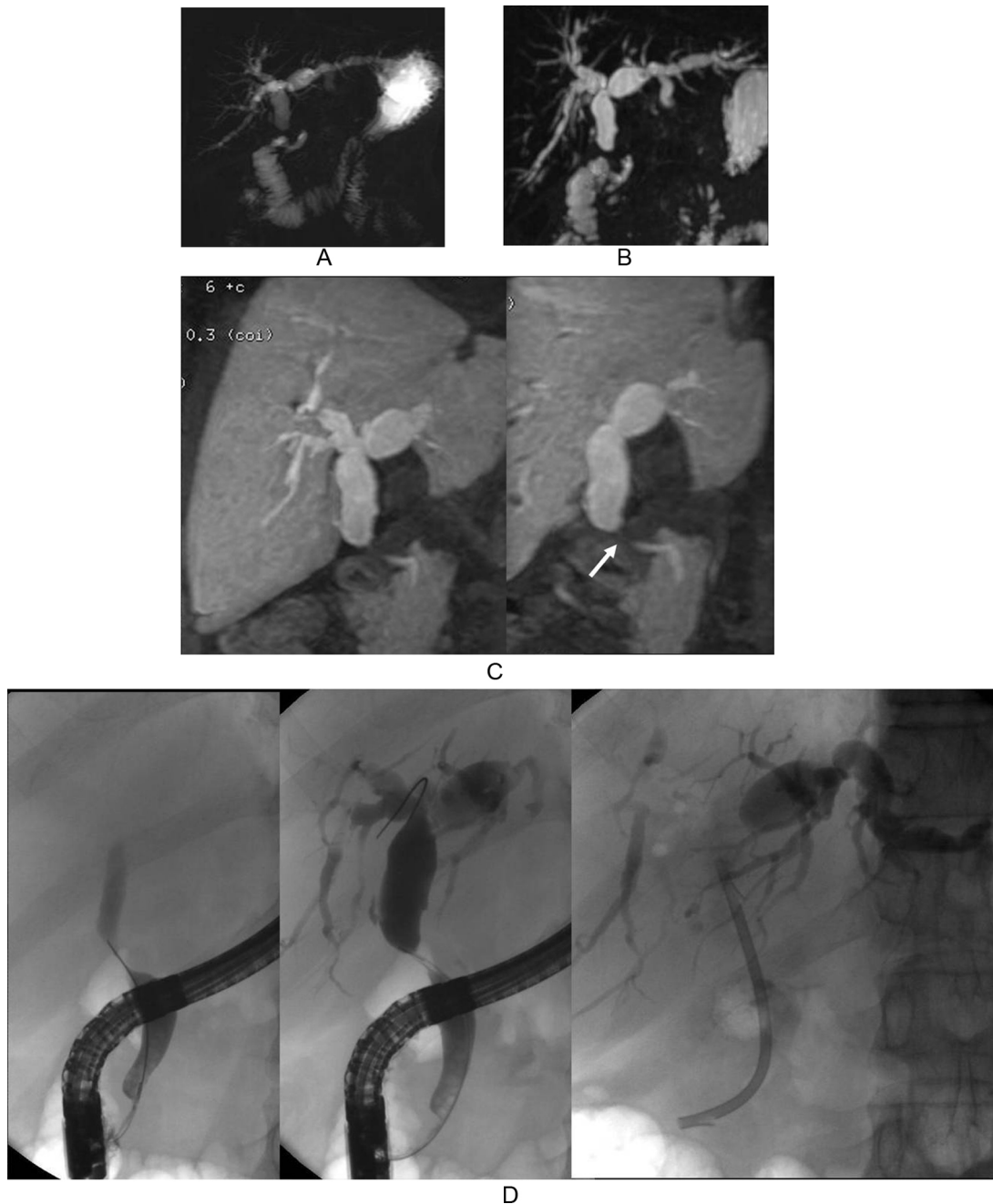
The level of confidence in the assessment of biliary adverse events was significantly increased by the administration of mangafodipir trisodium as demonstrated by ROC analysis of two different image sets (Fig. 5). The difference between areas under the ROC curve of two different images sets was 0.313 +/- 0.093, showing significance level (*p* = 0.001).

### 4. Discussion

Whenever a biliary complication is suspected in a liver transplant recipient, diagnostic work-up usually begins with laboratory tests and an abdominal Doppler ultrasound (US) that allows the simultaneous evaluation of liver parenchyma, biliary tree and hepatic vasculature. The positive predictive value of abdominal US



**Fig. 1.** (A–D) 52-year-old man with progressive jaundice. Conventional coronal thick-slab single-shot MRC (A) and MIP reconstructions from 3D-T2-weighted images (B) do not visualize the confluence of the hepatic ducts and the common hepatic duct of the graft; slight dilation of the intrahepatic biliary system is well evident. MIP reconstructions obtained from MnDPDP-enhanced 3D T1-weighted MRC (C) better delineate narrowed and irregular donor's extrahepatic biliary tract, in particular at the level of the right (white arrow) and the common (red arrow) hepatic ducts. Findings of typical ITBL were confirmed at ERC (D) and treated with a biliary stent. (For interpretation of the references to color in this figure legend, the reader is referred to the web version of this article.)

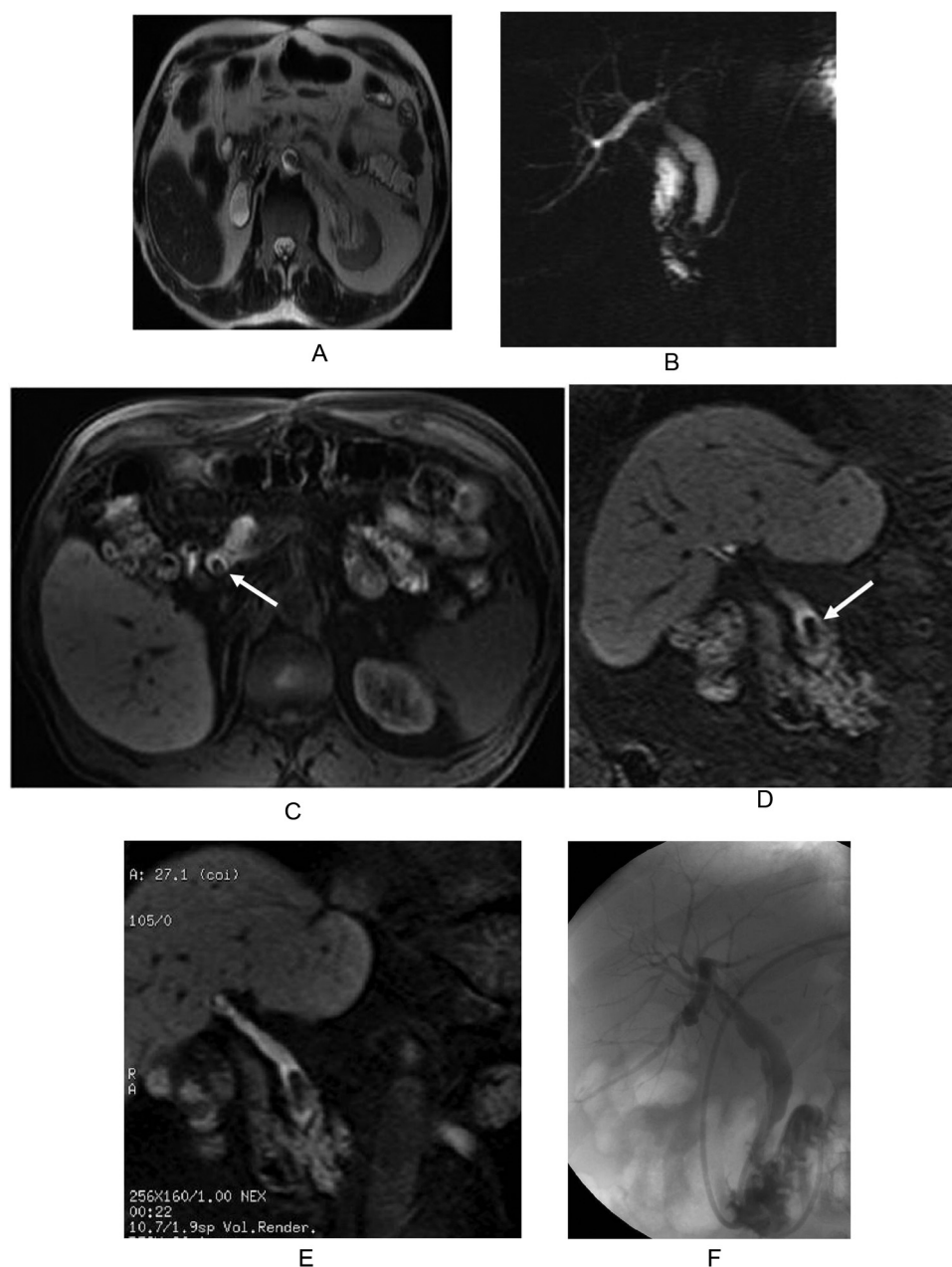


**Fig. 2.** (A–D) 44-year-old man with biochemical parameters of cholestasis. Conventional coronal thick-slab single-shot MRC (A) and MIP reconstructions from 3D T2-weighted images (B) show dilation of donor's biliary tree; long discontinuity is suggested at anastomotic site. MIP reconstructions obtained from Mn-DPDP-enhanced 3D T1-weighted MRC (C) well exhibit the length and degree of anastomotic stricture (white arrow). ERC (D), obtained in the same patient, confirms the presence of a biliary stricture at the anastomotic site; stricture was endoscopically treated and a biliary stent was placed.

is very high, especially in the presence of dilated bile ducts. In the absence of dilated bile ducts, the sensitivity of the ultrasound for detecting biliary obstruction ranges from 38% to 68% [14]. Although ultrasound is a non-invasive method of identifying adverse events in liver recipients, a normal US exam cannot exclude the presence of biliary strictures, widespread ductal abnormalities or bile leak [15,16]. Multi-detector computed tomography is usually performed in the period after transplant when US findings are equivocal or there is a strong clinical suspicion for an abnormality. This imaging technique is a reliable and non-invasive mean of visualizing hepatic artery, portal vein, hepatic veins, and inferior vena cava and evaluating non-vascular graft complications and extra-hepatic organs. As concerns as biliary adverse events, com-

puted tomography can be utilized to screen for biliary leakage or obstruction, but its role has not yet definitely clarified [17,18].

A more efficient evaluation of biliary adverse events can be obtained utilizing T-tube cholangiography or invasive techniques, such as endoscopic retrograde cholangiopancreatography (ERCP) or percutaneous trans-hepatic cholangiography (PTC). In recipients with a suspicion of biliary complications in the early period following liver transplant during which the T-tube is still in place, T-tube cholangiography is the examination of choice. On the other hand, when the T-tube is removed three months after OLT or in the case it is not used at all, direct visualization of the biliary tract is only possible when using invasive techniques, which are associated with various complications in 3.4% of PTC and 1–7% of ERCP. Nev-



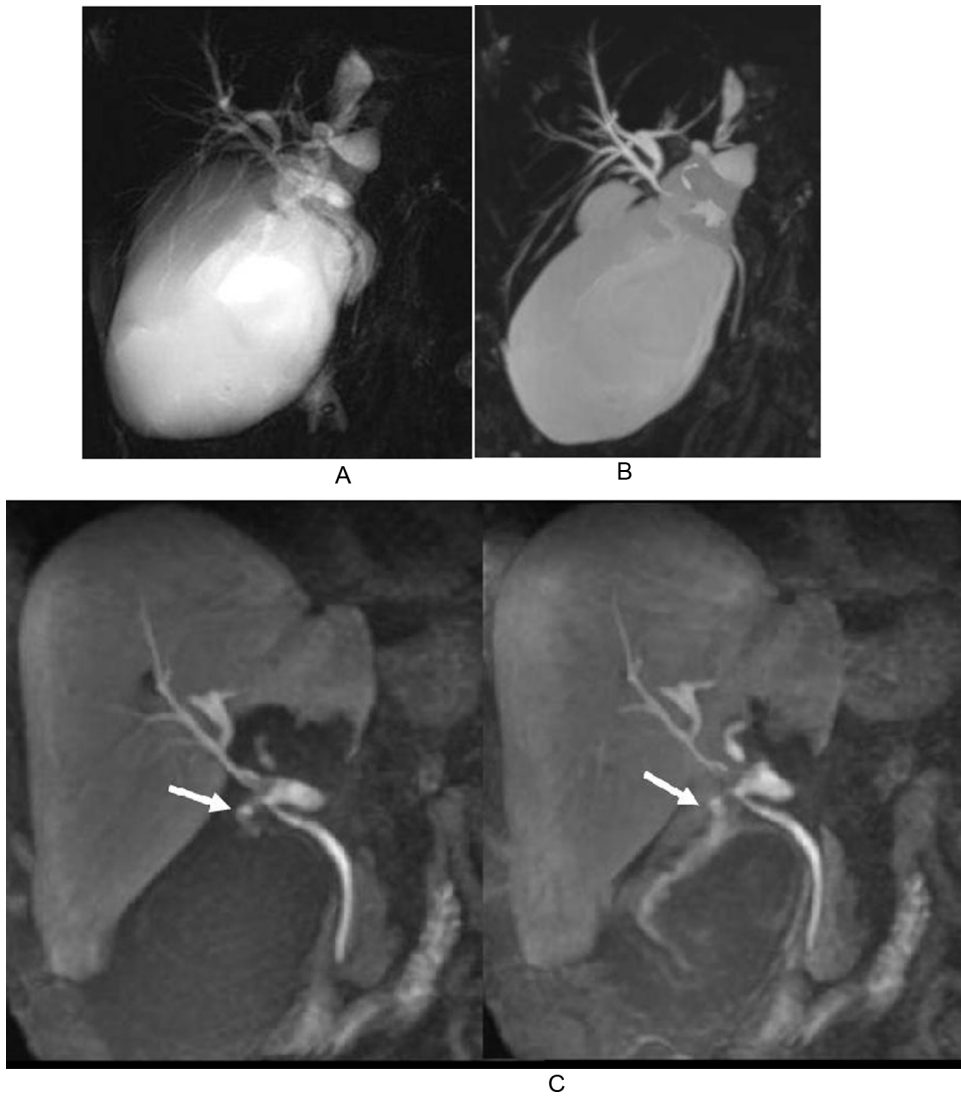**Fig. 3.** (A–F) 62-year-old patient with abnormal liver function tests. Axial T2-weighted image (A) and conventional coronal thick-slab single-shot MRC (B) well exhibit dilation of extrahepatic biliary tree and a signal void in the distal portion of the common bile duct. Axial (C) and coronal (D) Mn-DPDP-enhanced T1-weighted images depict stone as a low signal intensity filling defect in contrast-filled bile ducts (white arrow). 3D MIP reconstruction (E) also demonstrates narrowing of the terminal portion of recipient's common bile duct. Stone was endoscopically removed as confirmed at post-ERCP direct cholangiography (F).

ertheless, in patients with bilio-digestive anastomoses ERCP may be unsuccessful or extremely difficult since endoscopic approach of the biliary tract is generally precluded because technically challenging [19,20].

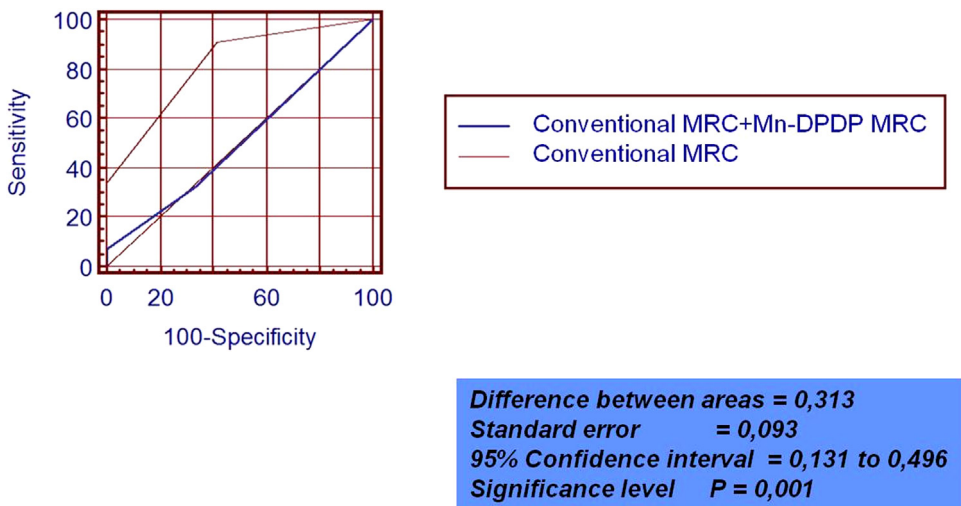
As a non-invasive alternative to direct cholangiography, MRC is actually very important for assessing biliary tree abnormalities after surgery [5]. In a recent meta-analysis Jorgensen et al. [21] concluded that MRCP may have an excellent diagnostic accuracy for post-OLT biliary obstruction, with a global sensitivity and specificity of 96% and 94%, respectively; on the basis of these results an appropriate use of MRCP could potentially prevent the unnecessary risks of invasive procedures in this clinical setting. Furthermore, in a still more recent meta-analysis Xu et al. [22] confirmed that MRCP is a highly accurate diagnostic technique for diagnosing biliary complications and strictures in patients who have undergone

OLT. However, the main disadvantages of conventional MRCP are that it lacks functional information and so, differentiation between obstructive and non-obstructive dilatation of the bile ducts is often extremely difficult [23,24]. Depiction of anatomy and lesion detection can be inadequate in a non-dilated biliary system; besides, free fluid and leak in the vicinity obscures the biliary anatomy due to overlapping [25,26]. Hence, there is often a need for a non-invasive imaging modality, which can provide reliable anatomic as well as functional information.

T1-weighted contrast-enhanced MR Cholangiography with intravenous administration of hepato-biliary contrast agents such as Mn-DPDP, Gd-BOPTA and Gd-EOB-DTPA [27] is a relatively recent MR technique that may provide both anatomic and functional information on the biliary system. These agents are taken up by functioning hepatocytes and excreted into the biliary system



**Fig. 4.** (A–C) 58-year-old woman with abdominal pain. Conventional coronal thick-slab single-shot MRC (A) and MIP reconstructions from 3D-T2-weighted images (B) show an huge sub-hepatic fluid collection partially obscuring the biliary tract. MIP reconstructions obtained from Mn-DPDP-enhanced 3D T1-weighted MRC (C) demonstrate the presence of a leakage at the anastomotic with contrast-enhanced bile filling of the sub-hepatic collection (white arrows).



**Fig. 5.** Graph shows ROC analysis of two image sets (conventional T2-weighted MRC image set versus all images set including Mn-DPDP-enhanced MRC) concerning the level of confidence in the diagnosis of biliary adverse events (p=0.001).

(3–5% for Gd-BOPTA, 20% for Mn-DPDP, and 50% for Gd-EOB-DTPA). Hepatic excretion of hepato-biliary contrast agents results in enhancement of biliary structures and it is likely to have a great impact on better visualization of biliary system [28]. In a preliminary experience on 13 patients with hepaticojejunostomy, Hottat et al. [24] concluded that contrast-enhanced T1-weighted MRC with intravenous administration of Mn-DPDP provides useful anatomic and functional information in patients suspected of having biliary obstruction on conventional T2-weighted MR Cholangiography. Various authors have recently underlined how hepatocyte-specific contrast-enhanced MR Cholangiography could offer additional information to referring clinicians and have reported the possible clinical applications in the evaluation of biliary pathology [29–32].

However, to the best of our knowledge, no study has been previously published on the possible added value of contrast-enhanced MR Cholangiography using Mn-DPDP in the evaluation of biliary adverse events following liver transplantation.

On the basis of our experience, MR studies including Mn-DPDP-enhanced sequences allowed complete visualization of the extra-hepatic biliary tree and provided functional information in our series of patients. In fact, times of contrast agent excretion seem to be in correlation with different degrees of biliary obstruction and related to the severity of the strictures. In the two patients with anastomotic strictures in which no excretion of Mn-DPDP was observed after two hours from contrast agent administration, the severity of the biliary strictures was confirmed on surgery.

Using conventional T2-weighted MRC and contrast-enhanced MR Cholangiography we correctly identified 42 out of 43 biliary anastomotic and non-anastomotic strictures with a false negative case and two false positive cases. The extension and degree of anastomotic and non-anastomotic strictures were better delineated when using Mn-DPDP-enhanced MR Cholangiography respect to conventional T2-weighted MRC. In our hospital, transplant surgeons actually select the more appropriate treatment (interventional or surgical) of the biliary strictures on the basis of the extent and grading of biliary involvement on MRC images.

Nevertheless, we correctly identified all six cases of biliary leakage due to the use of contrast-enhanced MRC with intravenous administration of Mn-DPDP. Although cross-sectional imaging can suspect the diagnosis of a biliary leakage in an appropriate clinical scenario, non-specific findings (e.g., fluid collection) are generally provided [29]. Invasive techniques such as PTC or, less frequently, ERCP are often utilized to confirm the diagnosis by demonstrating an active contrast extravasation from the biliary system. However, in our patients we were able to directly visualize contrast material extravasation into fluid collections on contrast-enhanced MRC and so we could also identify the anatomic site of the leak.

Although the ability of MR imaging to consistently identify calculi of a few millimeters in size has not yet fully demonstrated, numerous published studies have shown an excellent diagnostic accuracy of MR Cholangiography in the detection of common bile duct stones [33]. In our series of patients Mn-DPDP-enhanced MRC helped to exclude pathologic conditions and provided an increased diagnostic confidence in the differential diagnosis between endoluminal filling defects (such as biliary stones, sludge, and casts) and pneumobilia or flow artefacts. Furthermore, T1-weighted images improved the diagnostic confidence of conventional T2-weighted MRC for the detection of biliary cast syndrome in recipients with ITBL since biliary cast is hyperintense on T1-weighted images.

At least, in our series Mn-DPDP-enhanced MRC allowed an increased diagnostic confidence for the diagnosis of sphincter of Oddi dysfunction since it provided functional information on biliary flow dynamics. Delayed passage of bile through the ampulla of Vater might be caused by observing delayed passage or no passage of contrast medium in the ampulla of Vater on MR images usu-

ally obtained more than 1–2 h after Mn-DPDP injection. In addition, mangafodipir trisodium-enhanced MR Cholangiography may help to exclude the possibility of SOD by demonstrating normal passage of contrast material in the biliary tract on MR images obtained after a 30 min delay in patients clinically suspected to have sphincter of Oddi dysfunction.

On the basis of our data, the proposed combined approach using conventional T2-weighted MRC and mangafodipir trisodium-enhanced MR Cholangiography may predict biliary adverse events in at least 98%, and exclude them in 95% of cases. It can accurately demonstrate the site and extent of biliary strictures, which is very useful when planning possible interventional treatments. Besides, it can allow a more reliable diagnosis of very small biliary stones and particularly of biliary leakage, that is extremely difficult when only using conventional T2-weighted images; at last, it can provide functional information that are very promising in the grading the level and severity of biliary obstruction.

The drawbacks of contrast-enhanced MRC using mangafodipir trisodium are mainly represented by its additional costs, by the fact that it is a time-consuming technique and by limitations in delineating the biliary tract in patients with hepato-biliary dysfunction. Another potential limitation may be represented by the fact that mangafodipir trisodium (Teslascan) is currently no longer available commercially; however, in our opinion, the same results of our study can be theoretically obtained using other alternative contrast agents commercially available such as Gd-BOPTA and Gd-EOB-DTPA. Obviously, further prospective studies utilizing other hepato-biliary contrast media are needed to confirm the usefulness of this combined approach in the assessment of biliary complications after liver transplantation.

## 5. Conclusions

In summary, contrast-enhanced MR Cholangiography using mangafodipir trisodium may improve the level of diagnostic confidence provided by conventional T2-weighted MR Cholangiography for detecting biliary adverse events following orthotopic liver transplantation since it can provide both anatomical and functional information. For this reason, we actually recommend to utilize this diagnostic approach before planning every kind of therapeutic approach.

## Conflict of interest

All the authors declare that they have no conflict of interest.

## Authors contribution

All authors have made substantial contributions to all of the following: (1) the conception and design of the study, or acquisition of data, or analysis and interpretation of data, (2) drafting the article or revising it critically for important intellectual content, (3) final approval of the version to be submitted.

## References

- [1] B.J. Stange, M. Glanemann, N.C. Nuessler, U. Settmacher, T. Steinmüller, P. Neuhaus, Hepatic artery thrombosis after adult liver transplantation, *Liver Transpl.* 9 (2003) 612–620.
- [2] H.K. Hussain, H.V. Nghiem, Imaging of hepatic transplantation, *Clin. Liver Dis.* 6 (2002) 247–270.
- [3] R. Rerknimitr, S. Sherman, E.L. Fogel, C. Kalayci, L. Lumeng, N. Chalasani, et al., Biliary tract complications after orthotopic liver transplantation with choledochcholedochostomy anastomosis: endoscopic findings and results of therapy, *Gastrointest. Endosc.* 55 (2002) 224–231.
- [4] J. Piecuch, K. Witkowski, Biliary tract complications following 52 consecutive orthotopic liver transplants, *Ann. Transplant.* 6 (2001) 36–38.



- [5] C. Hoeffel, L. Azizi, M. Lewin, V. Laurent, C. Aubé, L. Arrivé, et al., Normal and pathologic features of the postoperative biliary tract at 3D MR cholangiopancreatography and MR imaging, *Radiographics* 26 (2006) 1603–1620.
- [6] A. Laghi, P. Pavone, C. Catalano, M. Rossi, V. Panebianco, D. Alfani, et al., MR cholangiography of late biliary complications after liver transplantation, *AJR Am. J. Roentgenol.* 172 (1999) 1541–1546.
- [7] A.S. Fulcher, M.A. Turner, Orthotopic liver transplantation: evaluation with MR cholangiography, *Radiology* 211 (1999) 715–722.
- [8] V. Meersschaut, K.J. Mortelé, R. Troisi, H. Van Vlierberghe, M. De Vos, L. Defreyne, et al., Value of MR cholangiography in the evaluation of postoperative biliary complications following orthotopic liver transplantation, *Eur. Radiol.* 10 (2000) 1576–1581.
- [9] P. Boraschi, G. Braccini, R. Gigoni, G. Sartoni, E. Neri, F. Filippini, et al., Detection of biliary complications after orthotopic liver transplantation with MR cholangiography, *Magn. Reson. Imaging* 19 (2001) 1097–1105.
- [10] R. Ott, H. Greess, U. Aichinger, F. Felner, C. Herold, S. Yedibela, et al., Clinical value of MRC in the follow-up of liver transplant patients with a choledochojejunostomy, *Abdom. Imaging* 27 (2002) 336–343.
- [11] P. Boraschi, F. Donati, R. Gigoni, L. Urbani, M. Femia, M.C. Cossu, et al., Ischemic-type biliary lesions in liver transplant recipients: evaluation with magnetic resonance cholangiography, *Transplant. Proc.* 36 (2004) 2744–2747.
- [12] C. Wang, Mangafodipir trisodium (MnDTPA)-enhanced magnetic resonance imaging of the liver and pancreas, *Acta Radiol. Suppl.* 415 (1998) 1–31.
- [13] G. Jung, W. Heindel, T. Krahe, H. Kugel, C. Walter, R. Fischbach, et al., Influence of the hepatobiliary contrast agent mangafodipir trisodium (MN-DTPA) on the imaging properties of abdominal organs, *Magn. Reson. Imaging* 16 (1998) 925–931.
- [14] S. Sharma, A. Gurakar, N. Jabbar, Biliary strictures following liver transplantation: past, present and preventive strategies, *Liver Transpl.* 14 (2008) 759–769.
- [15] G. Zemel, A.B. Zajko, M.L. Skolnick, K.M. Bron, W.L. Campbell, The role of sonography and transhepatic cholangiography in the diagnosis of biliary complications after liver transplantation, *AJR Am. J. Roentgenol.* 151 (1988) 943–946.
- [16] T. Kok, A. Van der Sluis, J.P. Klein, E.J. Van der Jagt, P.M. Peeters, M.J. Slooff, et al., Ultrasound and cholangiography for the diagnosis of biliary complications after orthotopic liver transplantation: a comparative study, *J. Clin. Ultrasound* 24 (1996) 103–115.
- [17] A.H. Caiado, R. Blasbalg, A.S. Marcelino, M. da Cunha Pinho, M.C. Chammas, C. da Costa Leite, et al., Complications of liver transplantation: multimodality imaging approach, *Radiographics* 27 (2007) 1401–1417.
- [18] A.K. Singh, A.C. Nachiappan, H.A. Verma, R.N. Uppot, M.A. Blake, S. Saini, et al., Postoperative imaging in liver transplantation: what radiologists should know, *Radiographics* 30 (2010) 339–351.
- [19] M.K. Bilbao, C.T. Dotter, T.G. Lee, R.M. Katon, Complications of endoscopic retrograde cholangiopancreatography (ERCP) A study of 10,000 cases, *Gastroenterology* 70 (1976) 314–320.
- [20] S.A. Cohen, J.H. Siegel, F.E. Kasmin, Complications of diagnostic and therapeutic ERCP, *Abdom. Imaging* 21 (1996) 385–394.
- [21] J.E. Jorgensen, A.K. Waljee, M.L. Volk, C.J. Sonnenday, G.H. Elta, M.M. Al-Hawary, et al., Is MRCP equivalent to ERCP for diagnosing biliary obstruction in orthotopic liver transplant recipients? A meta-analysis, *Gastrointest. Endosc.* 73 (2011) 955–962.
- [22] Y.B. Xu, Z.G. Min, H.X. Jiang, S.Y. Qin, B.L. Hu, Diagnostic value of magnetic resonance cholangiopancreatography for biliary complications in orthotopic liver transplantation: a meta-analysis, *Transplant. Proc.* 45 (2013) 2341–2346.
- [23] M.D. Bridges, G.R. May, D.M. Harnois, Diagnosing biliary complications of orthotopic liver transplantation with mangafodipir trisodium-enhanced MR cholangiography: comparison with conventional MR cholangiography, *AJR Am. J. Roentgenol.* 182 (2004) 1497–1504.
- [24] N. Hottat, C. Winant, T. Metens, N. Bourgeois, J. Devière, C. Matos, MR cholangiography with manganese dipyriddyloxyl diphosphate in the evaluation of biliary-enteric anastomoses: preliminary experience, *AJR Am. J. Roentgenol.* 184 (2005) 1556–1562.
- [25] D. Kandasamy, R. Sharma, A. Seith Bhalla, S.R. Gamanagatti, D.N. Srivastava, P. Sahni, et al., MR evaluation of biliary-enteric anastomotic stricture: does contrast-enhanced T1W MRC provide additional information, *Clin. Res. Hepatol. Gastroenterol.* 35 (2011) 563–571.
- [26] P. Boraschi, F. Donati, Biliary-enteric anastomoses: spectrum of findings on Gd-EOB-DTPA-enhanced MR cholangiography, *Abdom. Imaging* 38 (2013) 1351–1359.
- [27] H. Takao, H. Akai, T. Tajima, S. Kiryu, Y. Watanabe, H. Imamura, et al., MR imaging of the biliary tract with Gd-EOB-DTPA: effect of liver function on signal intensity, *Eur. J. Radiol.* 77 (2011) 325–329.
- [28] N.K. Lee, S. Kim, J.W. Lee, S.H. Lee, D.H. Kang, G.H. Kim, et al., Biliary MR imaging with Gd-EOB-DTPA and its clinical applications, *Radiographics* 29 (2009) 1707–1724.
- [29] L.M. Fayad, G.A. Holland, D. Bergin, N. Iqbal, L. Parker, P.G. Curcillo 2nd, et al., Functional magnetic resonance cholangiography (fMRC) of the gallbladder and biliary tree with contrast-enhanced magnetic resonance cholangiography, *J. Magn. Reson. Imaging* 18 (2003) 449–460.
- [30] D. Sheppard, L. Allan, P. Martin, T. McLeay, W. Milne, J.G. Houston, Contrast-enhanced magnetic resonance cholangiography using mangafodipir compared with standard T2W MRC sequences: a pictorial essay, *J. Magn. Reson. Imaging* 20 (2004) 256–263.
- [31] C. Burke, L. Alexander Grant, V. Goh, N. Griffin, The role of hepatocyte-specific contrast agents in hepatobiliary magnetic resonance imaging, *Semin. Ultrasound CT MR* 34 (2013) 44–53.
- [32] R.T. Gupta, Evaluation of the biliary tree and gallbladder with hepatocellular MR contrast agents, *Curr. Probl. Diagn. Radiol.* 42 (2013) 67–76.
- [33] E.J. Williams, J. Green, I. Beckingham, R. Parks, D. Martin, M. Lombard, British Society of Gastroenterology, Guidelines on the management of common bile duct stones (CBDS), *Gut* 57 (2008) 1004–1021.