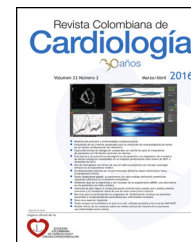



SOCIEDAD  
COLOMBIANA  
DE CARDIOLOGÍA Y  
CIRUGÍA CARDIOVASCULAR

# Revista Colombiana de Cardiología

[www.elsevier.es/revcolcar](http://www.elsevier.es/revcolcar)



## CARDIOLOGÍA DEL ADULTO – PRESENTACIÓN DE CASOS

# Caseous calcification of the mitral annulus: unmasking a master of disguise



Yale Tung-Chen\*, Miguel Ángel Roig-Osca

University and Polytechnic Hospital of La Fe. Department of Internal Medicine. Calle Fernando Abril Martorell N° 106, 46026, Valencia, Spain

Received 28 August 2015; accepted 29 March 2016

Available online 4 May 2016

### KEYWORDS

Echocardiography;  
Mitral valve;  
Calcium;  
Cardiovascular risk  
factors

### PALABRAS CLAVE

Ecocardiografía;  
Válvula mitral;  
Calcio;  
Factores de riesgo  
cardiovascular

**Abstract** Caseous calcification of the mitral annulus is an underdiagnosed disease, which can be associated with aging and cardiovascular risk factors: hypertension, diabetes, dyslipidemia or end-stage renal disease. This disease should be considered in the differential diagnosis in order to avoid unnecessary tests or even surgery.

© 2016 Sociedad Colombiana de Cardiología y Cirugía Cardiovascular. Published by Elsevier España, S.L.U. This is an open access article under the CC BY-NC-ND license (<http://creativecommons.org/licenses/by-nc-nd/4.0/>).

### Calcificación caseosa del anillo mitral: desenmascarando una enfermedad simuladora

**Resumen** La calcificación caseosa del anillo mitral es una enfermedad infradiagnosticada, que puede estar asociada al envejecimiento y a factores de riesgo cardiovascular como la hipertensión, la diabetes, la dislipidemia o la enfermedad renal terminal. Es preciso considerar esta enfermedad en el diagnóstico diferencial, de cara a evitar pruebas innecesarias e incluso cirugía.

© 2016 Sociedad Colombiana de Cardiología y Cirugía Cardiovascular. Publicado por Elsevier España, S.L.U. Este es un artículo Open Access bajo la licencia CC BY-NC-ND (<http://creativecommons.org/licenses/by-nc-nd/4.0/>).

## Introduction

Caseous calcification of the mitral annulus is an underdiagnosed disease, which can be associated with aging and

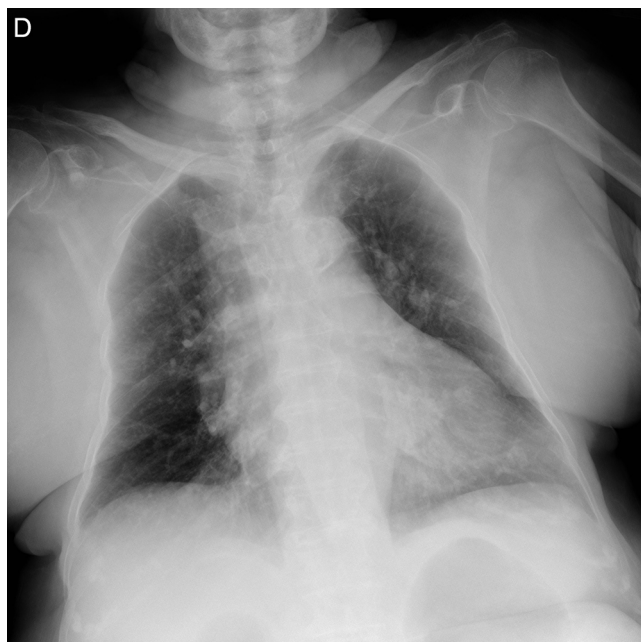
cardiovascular disease: hypertension, diabetes, dyslipidemia and end-stage renal disease.<sup>1–6</sup>

## Case report

We present a case of an 89 year-old woman, with previous history of hypertension, who was admitted to the emergency department due to asthenia and fever for

\* Corresponding author.

E-mail address: [yale.tung@comv.es](mailto:yale.tung@comv.es) (Y. Tung-Chen).



**Figure 1** Chest X-ray, showing a large, ovoid, dense structure overlying the cardiac silhouette.

1 week. The physical examination was only remarkable for the presence of systolic heart murmur at mitral location. A chest X-Ray revealed a large, ovoid, dense structure overlying the cardiac silhouette (Fig. 1). Transthoracic echocardiography was performed with a hand-held ultrasound device (Vscan™), on apical four-chamber view, a large (3.04 × 3.30 cm), round, echodense structure along the posterior mitral annulus, with central echolucency and mild acoustic shadow was noticed, associated with moderate regurgitation and stenosis (B-mode in video 2A, color Doppler in 2B), with conserved ventricular systolic function. Laboratory workup showed mildly elevated inflammatory markers, CRP 48 mg/dL [range: 0-5], white blood cell count 11000/μL [range: 3000-10000], renal function showed an elevation of creatinine 115 μmol/L [range: 49-92] and urinalysis revealed glucosuria, nitrate positive and 3-6 WBC/HPF [range: 0-3], which was compatible with urinary tract infection. Ceftriaxone was empirically started, and her clinical condition gradually improved. At that time, urine culture reported a heavy growth of multi-drug sensitive *Escherichia coli* strain.

The patient's caseous calcification was managed conservatively, and on routine follow-up, type 2 diabetes was diagnosed, achieving good glycemic control with metformin.

## Discussion

Caseous calcification of the mitral annulus is an underdiagnosed variant of mitral annular calcification due to its often-asymptomatic course.<sup>2</sup> As we see, can be incidentally detected on chest radiographs of the elderly, related with aging, hypertension, diabetes, dyslipemia and end-stage renal disease, can also be associated with cardiovascular disease (stroke, coronary disease and atrial fibrillation). Though, the explicit pathophysiology is not known.<sup>1</sup>

Nonetheless, when detected, a careful assessment of potential cardiovascular risk factors should be performed, and not misdiagnose it as pneumonia, pulmonary nodule, myocardial abscess, tumor or thrombus. The often-asymptomatic clinical course, in addition to the characteristic large, round, well-defined borders, echodense with central areas of echolucency, and typically posterior mitral leaflet site help distinguish it from these other diseases.<sup>4,5</sup>

Due to its benign and chronic course, conservative monitoring is the main recommendation in the long-term management of these patients, while surgery should be reserved only for cases with severe valvular dysfunction. For this purpose, hand-held transthoracic echocardiography, performed at bedside, is a very useful tool to avoid unnecessary investigations.<sup>6</sup>

## Ethics

All authors meet the criteria for authorship stated in the Uniform Requirements for Manuscripts Submitted to Biomedical Journals. All authors have contributed equally to this work. This work has not been supported by public grants or financial support. No sources of funding were used to assist in the preparation of this case report. Each author certifies that he has no commercial associations that might pose a conflict of interest in connection with the submitted article. We certify that the reporting of this case was conducted in conformity with ethical principles of our institution. Our figures have not been previously published and reproduced from another source.

## Ethical disclosures

**Protection of human and animal subjects.** The authors declare that no experiments were performed on humans or animals for this study.

**Confidentiality of data.** The authors declare that no patient data appear in this article.

**Right to privacy and informed consent.** The authors declare that no patient data appear in this article.

## Conflicts of Interest

The authors declare no conflicts of interest.

## Appendix A. Supplementary data

Supplementary data associated with this article can be found, in the online version, at [doi:10.1016/j.rccar.2016.03.019](https://doi.org/10.1016/j.rccar.2016.03.019).

## References

1. Arora H, Madan P, Simpson L, Stainback RF. Caseous calcification of the mitral annulus. *Tex Heart Inst J.* 2008;35:211.
2. Correale M, Deluca G, Ieva R, Biase MD. Spontaneous resolution of a caseous calcification of the mitral annulus. *Clinics*

- [Internet]. 2009 Nov [cited 2015 Oct 23];64(11). Available from: [http://www.scielo.br/scielo.php?script=sci\\_arttext&pid=S1807-59322009001100015&lng=en&nrm=iso&tlng=en](http://www.scielo.br/scielo.php?script=sci_arttext&pid=S1807-59322009001100015&lng=en&nrm=iso&tlng=en).
3. Furlan AJ, Craciun AR, Salcedo EE, Mellino M. Risk of stroke in patients with mitral annulus calcification. *Stroke*. 1984;15:801–3.
  4. García-Ibarrondo N, Lang RM. Caseous Calcification of the Mitral Annulus, a Rare Echocardiographic Finding. *Rev Esp Cardiol Engl Ed*. 2011 Sep;64:828–31.
  5. Martínez-de-Alegría A, Rubio-Álvarez J, Baleato-González S. Caseous Calcification of the Mitral Annulus: A Rare Cause of Intracardiac Mass. *Case Rep Radiol*. 2012;2012:1–3.
  6. Minardi G, Manzara C, Pulignano G, Pino PG, Pavaci H, Sordi M, et al. Caseous calcification of the mitral annulus with mitral regurgitation and impairment of functional capacity: a case report. *J Med Case Reports*. 2008;2:205.