


Chinese Taipei Society of
Ultrasound in Medicine

Available online at www.sciencedirect.com

ScienceDirect

journal homepage: www.jmu-online.com



IMAGING FOR RESIDENTS

A Male Adult with Medial Elbow Pain

Chen-Chang Chao ¹, Ke-Vin Chang ^{2*}

¹ Department of Medicine, National Taiwan University School of Medicine, and ² Department of Physical Medicine and Rehabilitation, National Taiwan University Hospital, Bei-Hu Branch, Taipei, Taiwan

Section 1—Quiz

A male adult developed right medial elbow pain after playing baseball with his son. The following ultrasound

images show the long axis views of the painful and contralateral medial elbow (Figure 1). What is your impression?

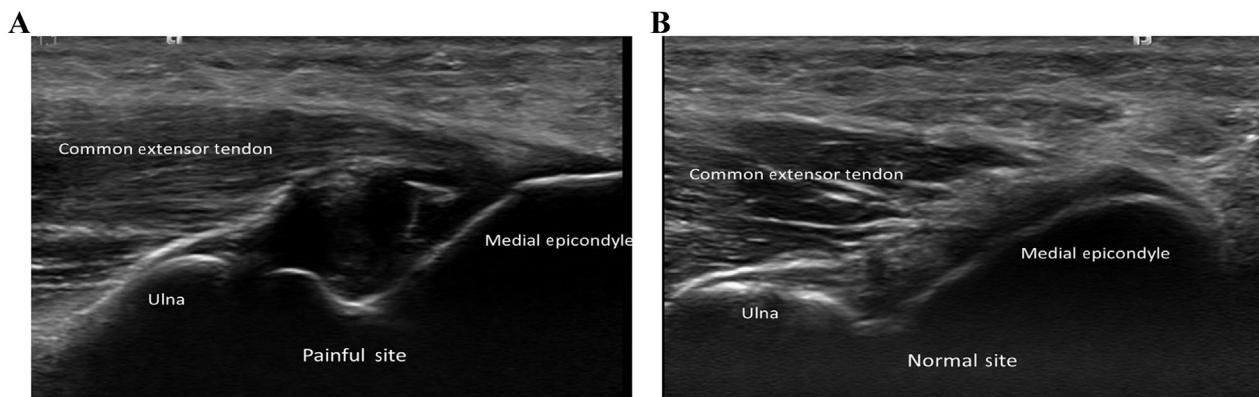


Figure 1 Ultrasound images showing the long axis views of the (A) painful and (B) contralateral medial elbow.

Conflicts of interest: All contributing authors declare no conflicts of interest.

* Correspondence to: Dr Ke-Vin Chang, Department of Physical Medicine and Rehabilitation, National Taiwan University Hospital, Bei-Hu Branch, No. 87, Neijiang St., Wanhua Dist., Taipei City 108, Taiwan.

E-mail address: pattap@pchome.com.tw (K.-V. Chang).