




Available online at
 ScienceDirect
www.sciencedirect.com

Elsevier Masson France

www.em-consulte.com

**Orthopaedics
& Traumatology**
 Surgery & Research

CLINICAL REPORT

Iliac crest bone graft harvesting complications: A case of liver herniation

T. Nodarian*, E. Sariali, F. Khiami, H. Pascal-Mousselard, Y. Catonné

Department of Orthopaedic Surgery and Traumatology, Pitié-Salpêtrière Teaching Hospital Center,
 47-83, boulevard de l'Hôpital, 75651 Paris cedex 13, France

Accepted: 16 March 2010

KEYWORDS

Liver herniation;
 Autogenous bone
 harvesting;
 Bone graft;
 Iliac crest

Summary The iliac crest is an easily accessible donor site offering a relatively large and safe supply of bone. There are however possible complications; residual pain frequently, and more rarely herniation. This latter's true incidence is unknown in a literature review, which found 15 articles. We report a case of liver herniation in a 64-year-old overweight lady after harvesting bone from her iliac crest. The clinical diagnosis was confirmed by CT scan. Despite an appropriate surgical repair, the hernia recurred. This serious complication of bone harvesting from the iliac crest, and possible other undesirable events described, prompted reconsideration of our harvesting techniques, and the use in our unit of bone substitutes or cell therapy to fill bone defects.

© 2010 Elsevier Masson SAS. All rights reserved.

Introduction

The iliac crest (posterior or anterior) is a frequently used bone-harvesting site in orthopedic surgery; it is considered to be the best site because of the quality and quantity of bone available. This site is used to harvest cancellous or corticocancellous bone for orthopedic surgeries such as open-wedge osteotomies, treatment of non-union, and arthrodeses. The iliac crest is a good and easily accessible donor site for cancellous bone, but has the disadvantage of considerable morbidity that has been widely reported

in the literature [1–6]. Persistent pain and discomfort at the donor site are the most often reported [1–4,6]. Fowler et al. [7] reported several types of possible complications: damage to the superior gluteal artery, fourth lumbar artery, iliolumbar artery, and deep circumflex iliac artery; damage to the femoral nerve and ilio-inguinal nerves; ureteral injuries; gastrointestinal hernias; ileus; haematomas; pelvic instability, and fractures. A literature review found 15 cases of hernia after harvesting bone from the iliac crest [8]. We report a case of liver herniation that occurred following harvesting of a corticocancellous bone graft from the right anterior iliac crest in a patient who had already undergone surgery for pseudarthrosis of the greater trochanter. To the best of our knowledge, this is the first case published in the literature.

* Corresponding author.

E-mail address: thnodarian@yahoo.fr (T. Nodarian).

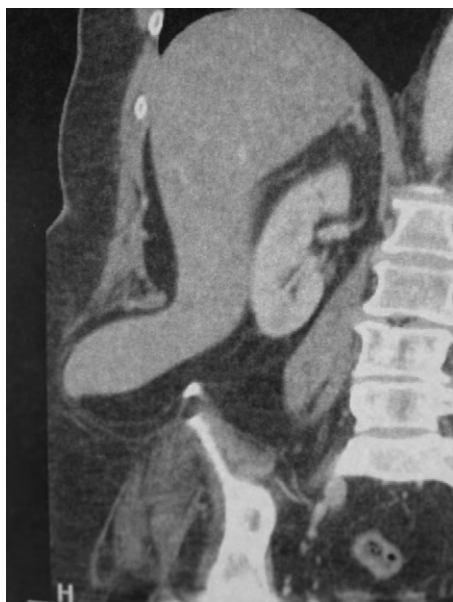

Figure 1 Abdominal CT scan (coronal section) showing herniation of the right lobe of the liver.

Observation

We report the case of a 64-year-old lady, weight 94 kg for a height of 160 cm (BMI = 36.7 kg/m²), who underwent surgery for pseudarthrosis of the greater trochanter in 2005, which occurred following total hip replacement in 2000. The patient was operated for primary osteoarthritis of the hip with total hip replacement using trochanteric osteotomy. Postoperatively, pain appeared. The assessment did not find any signs of loosening, but did find pseudarthrosis of the greater trochanter. Repeat surgery was performed in 2005 for treatment of the pseudarthrosis with a corticocancellous bone graft from the right iliac crest and osteosynthesis with a trochanteric hook. The graft had been harvested from the right anterior and middle iliac crest. The graft measured 5 cm; a tricortical graft from the anterior and middle iliac crest because of its size. Closure was performed using nonabsorbable sutures, without trans-osseous sutures. There was no abdominal wall rehabilitation. Weight bearing was resumed immediately. The immediate postoperative period was uncomplicated with in particular the absence of haematoma or infection at the donor site. Ten months after this repeat surgery, the patient presented spontaneous incisional hernia at the donor site, without obvious injury. A subhepatic swelling, reducible and not tender, was palpated on the physical examination. The patient complained about the swelling that was troublesome. She had no history of gastrointestinal surgery. An abdominal CT scan was thus requested to explore this swelling; the imaging studies showed herniation of the lower part of the right liver (Figs. 1 and 2). The liver function tests were normal. Considering the discomfort, she underwent surgery in 2007 for repair of the hernia and insertion of a non-absorbable preperitoneal patch. Complete breakdown of the various sutures was noted, and rupture of the abdominal wall muscles. The immediate postoperative period was uncomplicated; however recurrence occurred a year after

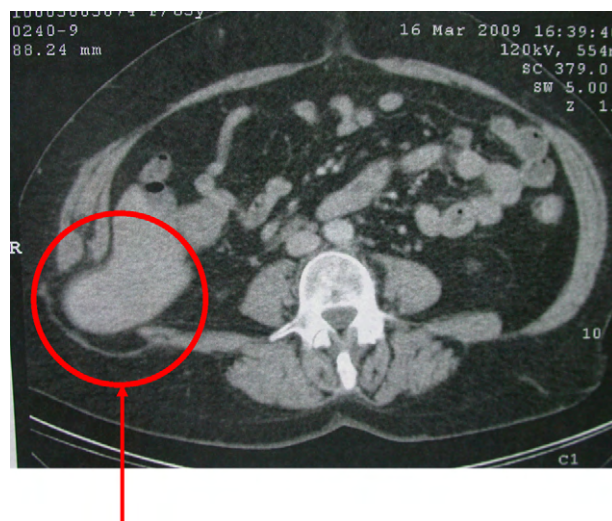

Figure 2 Abdominal CT scan (axial section) showing the liver hernia.

the hernia repair. For the time being, the patient refuses to repeat surgery.

Discussion

To the best of our knowledge, we report the first case of liver herniation as a complication of harvesting corticocancellous bone from the iliac crest. However, other types of hernia have already been reported. The frequency of incisional hernia, after bone harvesting from the iliac crest, is 5% according to Audela et al. [9]. This complication was reported as early as 1945 by Oldfield [10]. The most often it involves bowel loops [11], with the possibility of volvulus and strangulated hernias [12,13].

Time to onset of symptoms was 10 months. Depending on the authors, this can vary from 24 days [12] to 15 years after surgery [14]. This complication seems to be more frequent in women [9].

The physical examination is suspicious when there is a non-tender troublesome swelling at the scar. The diagnosis is confirmed with an abdominal CT scan that shows the hernia and its content [15,16]. This CT scan is required before surgery; diagnosis must be rapid to avoid complications of this hernia – strangulation and bowel necrosis. In the literature, when specifically investigating cases of liver herniation, only Rodríguez-Hermosa et al. [17] reported a case of liver hernia after cholecystectomy that occurred in a patient with morbid obesity (BMI = 57 kg/m²) whose laparoscopy was converted to a laparotomy. In that case, the clinical signs that resulted in the diagnosis of liver herniation in the immediate postoperative period were haemodynamic instability, paralytic ileus and abdominal pain. Repeat surgery was performed for organ reintegration and insertion of an extraperitoneal patch [17]. Unlike our observation, there was not only liver but also bowel herniation, which explained the far more severe symptoms. Isolated liver herniation does not seem to have clinical repercussions, apart from simple discomfort, in the absence of complications (necrosis, strangulation). The risk factors are obesity, increased intra-abdominal pressure, age greater

than 65, hypertension, emergency surgery, gastrointestinal cancers, and mechanical ventilation [18–21].

Treatment can be difficult. The cases of gastrointestinal hernia after bone harvesting from the iliac crest in the literature were operated and there were no new complications afterwards [8]. In the case we report, we noted recurrence in the year following repair, despite suitable surgical treatment, without a clear explanation.

The complication rate following autogenous bone grafts is probably underestimated in the literature. Depalma [5] observed persistent pain continuing 3 months afterwards in 15% of patients. Laurie [6] showed that the mean duration of acute pain was 6 weeks and that 10% of patients complained of pain over 2 years after surgery, mainly during strenuous physical exercise.

Taking all complications into account, this rate varies from 12% according to Watters and Levinthal [22] to 18% according to Boni [23] and can reach 20%. Boni [23] reported an 18% complication rate due to haematomas, local pain, and infection. Watters and Levinthal [22] reported 12% complications involving superficial or deep infection, meralgia paresthetica, pelvic fractures (in osteoporosis), deep hematomas, and urinary retention.

Fernyhough [24] noted that the most frequent complication was changes in sensations at the donor site, presenting as chronic pain and reduced sensitivity. In their study, 29% of patients complained of iliac crest pain over a year after surgery.

The intensity of the pain seemed to depend on the quantity of bone harvested [25]. There did not seem to be any relationship with the harvesting site (anterior or posterior), but tricortical grafts caused more severe pain. However, for Ahlmann et al. [26], who compared graft harvesting from the anterior or posterior iliac crest in terms of morbidity and pain, there was a difference. They reported a lower overall complication rate (2%) when the graft is harvested from the posterior crest compared with the anterior crest (23%); a significant difference. They also reported more severe pain for longer periods after harvesting from the anterior crest and recommended harvesting from the posterior crest as far as possible [26].

Scott [27] and Burstein et al. [2] have shown the effect of graft harvesting technique on morbidity. The standard technique, i.e., harvesting a tricortical graft, is accompanied by significantly higher morbidity in terms of analgesic consumption, incision length, duration of surgery, and hospital stay. In their study, patients operated using minimally invasive surgery presented fewer complications, resumed walking earlier, and had shorter hospital stays. The bone was harvested using a very short incision with a trephine fixed on a guide pin.

Kurz et al. [4] listed complications related to harvesting iliac crest bone grafts. Apart from pain at the donor site, they found nerve lesions causing meralgia paresthetica could reach 10% of cases, vascular lesions, particularly in posterior grafts, cosmetic sequelae, more frequent after tricortical grafts, and haematomas in 4 to 10% of cases. The risk of infection did not seem to be high, reaching less than 1% of cases. Limping involving the gluteus medius has been reported (up to 3% of cases) with posterior graft harvesting. Abdominal wall lesions and herniation of abdominal organs at the ilium can be seen after tricortical graft harvesting.

Avulsion of the anterior superior iliac spine [28] and fractures of the ala of the ilium are rare [29,30], but can require a second procedure for osteosynthesis. They are contributed to by osteoporosis.

This morbidity has serious consequences as shown by Hill [3]; the majority of patients who reported little or no satisfaction with their operation were those who presented complications at the donor site.

Considering these complications, we prefer to harvest bicortical bone grafts taken from the inner table to spare the outer table. We thus no longer harvest tricortical grafts. Even though there have not been any randomized studies comparing the two techniques, this is the least aggressive approach as it partly spares the insertions of the transverse abdominal muscles. Though exceptional, this complication is serious and requires consideration of the use of other techniques such as bone substitutes and cell therapy for bone reconstruction [31,32]. There are several options: either using the bone substitute as a true graft without harvesting corticocancellous bone or using the substitute to fill the bone defect created by graft harvesting. We have thus started to use bone substitute like a true graft; this enables us to spare the iliac crest entirely and to overcome all these potential complications.

Finally, in an attempt to explain this complication, the absence of trans-osseous sutures in some procedures could possibly be incriminated. We do not usually use trans-osseous sutures for closure. They could possibly have avoided this liver herniation in a patient with risk factors (obesity and harvesting of a quite large graft). This had weakened the abdominal wall and caused the liver herniation. On reviewing the CT scan images, the patient does not present any preexisting abnormalities; the hernia was obviously a consequence of graft harvesting.

Conclusions

Liver herniation after harvesting of an iliac crest bone graft is a rare complication requiring surgical treatment after CT scan assessment. Unfortunately, in our case the hernia recurred. Bone graft harvesting from the iliac crest can thus be followed by complications varying in severity and thus requiring consideration. The patient must be warned before performing the procedure. Whenever possible, harvesting from the posterior iliac crest should be preferred. We should tend towards the use of other techniques such as bone substitutes and cell therapy as true grafts or as substitutes to fill the bone defect left by graft harvesting.

Conflict of interest statement

None.

References

- [1] Banwart JC. Iliac crest bone graft harvest donor site morbidity. *Spine* 1995;20:1055–60.
- [2] Burstein FD, Simms C, Cohen SR, Work F, Paschal M. Iliac crest bone graft harvesting techniques: comparison. *Plast Reconstr Surg* 2000;105:34–9.

- [3] Hill NM. Donor site morbidity in the iliac crest bone graft. *Aust N Z J Surg* 1999;69:726–8.
- [4] Kurz LT, Grafin SR, Booth RE. Harvesting autogenous iliac bone grafts. *Spine* 1989;14(Suppl. 12):1324–31.
- [5] Depalma AF. Anterior interbody fusion for severe cervical disc degeneration. *Surg Gynecol Obstet* 1972;134:755–8.
- [6] Laurie SW. Donor site morbidity after harvesting rib and iliac bone. *Plast Reconstr Surg* 1984;73:933–8.
- [7] Fowler BL, Dall BE, Rowe DE. Complications associated with harvesting autogenous iliac bone grafts. *Am J Orthop* 1995;24(Suppl. 12):895–903.
- [8] Velchuru VR, Satish SG, Petri GJ, Sturzaker HG. Hernia through an iliac crest bone graft site. Report of a case and review of the literature. *Bull Hosp Joint Dis* 2006;63(Suppl. 3–4):166–8.
- [9] Audela J, Bianchi A, Tibau R, Rodriguez-Cano O. Hernia through iliac crest defects. *Int Orthop* 1995;19:367–9.
- [10] Oldfield MD. Iliac hernia after bone grafting. *Lancet* 1945;248:810–2.
- [11] Danikas D, Theodorou SJ, Stratoulis C, Constantinopoulos G, Ginalis EM. Hernia through an iliac crest bone-graft donor site. *Plast Reconstr Surg* 2003;110(Suppl. 6):161–3.
- [12] Challis JH, Lyttle JA, Stuart AE. Strangulated lumbar hernia and volvulus following removal of iliac crest bone graft. *Acta Orthop Scand* 1975;46(Suppl. 2):230–3.
- [13] Haj M, Griemberg B, Alkalay I, Stamler B. Large bowel herniation through a central fracture of iliac bone. *Isr J Med Sci* 1982;18:281–3.
- [14] Cowley PS, Anderson LD. Hernias through donor sites for the iliac bone grafts. *J Bone Joint Surg Am* 1983;65:1023–5.
- [15] Kaushik R, Attri AK. Incisional hernia from iliac bone grafting site: a report of two cases. *Hernia* 2003;7:227–8.
- [16] Kane VG, Silverstein GS. CT demonstration of hernia through an iliac crest defect. *J Comput Assist Tomogr* 1986;10:432–4.
- [17] Rodríguez-Hermosa JI, Ruiz-Feliú B, Roig-García J, Gironès-Vilà J, Planellas-Giné P, Ortuño-Muro P, et al. Hepatic evisceration after cholecystectomy in a superobese patient. *Obes Surg* 2008;18(12):1653–5.
- [18] Rodríguez-Hermosa JI, Codina-Cazador A, Ruiz B, Roig J, Gironès J, Pujadas M, et al. Risk factors for acute abdominal wall dehiscence after laparotomy in adults. *Cir Esp* 2005;77:280–6.
- [19] Carlson MA. Acute wound failure. *Surg Clin North Am* 1997;77:607–36.
- [20] Pavlidis TE, Galatianos IN, Papaziogas BT, Lazaridis CN, Atmatzidis KS, Makris JG, et al. Complete dehiscence of the abdominal wound and incriminating factors. *Eur J Surg* 2001;167:351–5.
- [21] Riou JP, Cohen JR, Johnson H. Factors influencing wound dehiscence. *Am J Surg* 1992;163:324–30.
- [22] Watters III WC, Levinthal R. Anterior cervical discectomy with and without fusion. Results, complications and long-term follow-up. *Spine* 1994;19:2343–7.
- [23] Boni M. Traitement chirurgical des cervicarthroses. Révision à distance (2–13 ans) chez les premiers cas opérés par voie antérieure. *Rev Chir Orthop Reparatrice Appar Mot* 1982;68(Suppl. 4):269–80.
- [24] Fernyhough JC. Chronic donor site pain complicating bone graft harvesting from the posterior iliac crest for spinal fusion. *Spine* 1992;17:1474–80.
- [25] Bloomquist DJ. The posterior ilium as a donor site for maxillofacial bone grafting. *J Maxillofac Surg* 1980;8:60–4.
- [26] Ahlmann E, Patzakis M, Roidis N, Shepherd L, Holtom P. Comparison of anterior and posterior iliac crest bone grafts in terms of harvest-site morbidity and functional outcomes. *J Bone Joint Surg Am* 2002;84-A(5):716–20.
- [27] Scott W. A method of procuring iliac bone by trephine curettage. *J Bone Joint Surg Am* 1949;31A:860.
- [28] Kuhn DA, Moreland MS. Complications following iliac crest bone grafting. *Clin Orthop Relat Res* 1986;209:224–6.
- [29] Friend KD, Koval KJ, Mirovsky Y, Remer SS, Bloom N, Neuwirth MG. Fracture of the iliac crest following bone grafting: case report and review of the literature. *Bull Hosp Jt Dis* 1995;54(1):49–51.
- [30] Porchet F, Jaques B. Unusual complications at iliac crest bone graft donor site: experience with two cases. *Neurosurgery* 1996;39(Suppl. 4):856–9.
- [31] Quarto R, Mastrogiacomo M, Cancedda R, Kutepov SM, Mukhachev V, Lavroukov A, et al. Repair of large bone defects with the use of autologous bone marrow stromal cells. *N Engl J Med* 2001;344(Suppl. 5):385–6.
- [32] Kitoh H, Kitakoji T, Tsuchiya H, Mitsuyama H, Nakamura H, Katoh M, et al. Transplantation of marrow-derived mesenchymal stem cells and platelet-rich plasma during distraction osteogenesis: a preliminary result of three cases. *Bone* 2004;35(Suppl. 4):892–8.