


Contents lists available at [ScienceDirect](http://ScienceDirect.com)

Gynecologic Oncology Reports

journal homepage: www.elsevier.com/locate/gore

Case Report

Endometrial carcinoma with ectopic human chorionic gonadotropin expression

Regina Lee^a, Roland Pattillo^{a,*}, Mark Bouzyk^b, Gabriela Oprea-Ilies^c, Roland Matthews^a^a Department of Obstetrics and Gynecology, Morehouse School of Medicine, Atlanta, GA, United States^b AKESOGen, Inc, Norcross, GA, United States^c Department of Pathology and Laboratory Medicine, Emory University School of Medicine, Atlanta, GA, United States

ARTICLE INFO

Article history:

Received 30 December 2014

Accepted 3 March 2015

Available online 11 March 2015

Keywords:

Human chorionic gonadotropin

Chemotherapy

Introduction

The roles of trophoblastic human chorionic gonadotropin (hCG) in pregnancy have long been known. Insufficient hCG expression has been linked with pregnancy failure either as a spontaneous abortion or as a biochemical pregnancies, as well as with ineffective placentation due to inadequate implantation manifesting as pregnancy induced hypertension (Cole, 2012). It has also been described that hCG β subunit is able to crosstalk with receptors of the cytokines in the cystine knot growth factor superfamily (Iles et al., 2010; Iles, 2007) due to crystalline structure homology with cystine disulfide bridges (Lapthorn et al., 1994). In particular, hCG is shown to block transforming growth factor β receptor mediated apoptosis (Iles, 2007; Butler et al., 2000) and to promote vascular endothelial growth factor receptor mediated angiogenesis (Herr et al., 2007; Reisinger et al., 2007). In addition, despite the molecular origin, hCG-H, hCG β and hCG β -H are all shown to behave similarly as promoters of cancer cell lines and their activities were similarly reduced by B152, antibody to hCG (Cole, 2012). It is thought that these are mechanisms by which a variety of non-gestational tumors that produce ectopic hCG β are able to develop characteristic aggressive course and treatment resistance (Iles et al., 2010). Despite the association with anaplastic tumor characterized by poor prognosis and rapid metastasis (Iles, 2007), there is no consensus or trials to answer if the tumors producing ectopic hCG should be treated differently.

Case presentation

A 64 year old African American Para 1001 woman with class II obesity (body mass index 37), well controlled diabetes mellitus and

hypertension, who underwent menopause at 53, presented with a rapidly growing mass protruding from the vagina with intermittent vaginal bleeding along with profuse malodorous vaginal discharge. Her family history was remarkable only for a sister with breast cancer in her late 30s and there was no known history of familial polyposis or Lynch syndrome. On the initial exam, there was a prolapsed fungated necrotic mass measuring 9 \times 5.5 cm and indistinct from her cervix. The uterus was 12 week size and there was no adnexal mass. The biopsy of the mass showed highly pleomorphic and poorly differentiated nests of epithelioid tumor cells. Her preoperative CA 125 was noted to be mildly elevated at 38.0 U/ml and CEA was normal at 0.5 ng/ml. She underwent total abdominal hysterectomy, bilateral salpingo-oophorectomy, and lymph node dissection. The uterus measured 14 \times 9 \times 6 cm and 202 g, containing a tumor measuring 6.5 \times 3.5 \times 2.5 cm (Fig. 1). The tumor was invading more than half of the myometrium and cervix as well as pelvic lymph nodes, making her stage IIIC1. The histology was classified as clear cell and papillary serous adenocarcinoma as well as simple hyperplasia in the endometrium (Fig. 2). The tumor stained positive for p53. On postoperative day 2, the patient was found to have dyspnea, tachypnea and desaturation. A CT PE protocol scan revealed multiple segmental emboli in the right lung and the patient was treated with anticoagulation.

At 6 weeks postoperatively, PET CT was obtained for evaluation of a 6 \times 6 cm pelvic mass, which was noted to have grown rapidly at the vaginal cuff. The mass showed heterogeneous FDG uptake to maximum SUV of 12.7, and there was interval worsening of bilateral lung nodularities with mild FDG uptake with index right upper lobe nodule 1.7 \times 1.1 cm with maximum SUV of 6.3 and index left upper lobe nodule 2.4 \times 1.8 cm with maximum SUV of 5.4. The biopsy specimen of this recurrence at the vaginal cuff was consistent with primary uterine cancer. The clear cell morphology of the hCG secreting stem cells present in the senior author's trophoblast cell line (Pattillo and Gey, 1968) prompted Dr. Pattillo to investigate whether this "clear cell" uterine cancer was producing hCG. The patient's serum hCG level was 7431 mIU/ml. Immunohistochemistry staining of tumor for hCG was requested and it was positive (Fig. 2). Subsequently, the tumor was submitted for further molecular testing. Whole genome microarray of the tumor showed multiple copy number variations (Fig. 3). These chromosomal abnormalities occurred over MSH2, MSH6, TP53 genes, as well as the duplication and overexpression of CGB genes encoding the β subunit of hCG on chromosome 19. At this time, the authors held a meeting with the patient and her family to discuss the findings and that although not standard of care, we would like to offer EMACO (etoposide, methotrexate,

* Corresponding author at: 720 Westview Drive SW, Atlanta, GA 30310, USA.

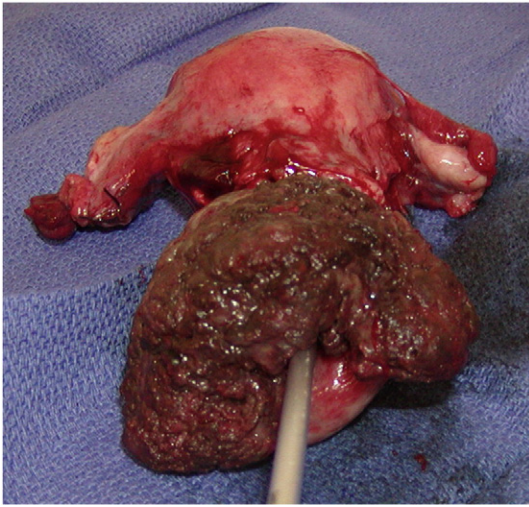


Fig. 1. Gross photograph of the uterus, tubes, ovaries. Anterior cervix replaced by the tumor. The probe is placed into the endocervical canal.

actinomycin D, cyclophosphamide and vincristine) therapy as her adjuvant course. Risks, side effects and alternative options were discussed and patient consented to the plan of care.

When patient presented for adjuvant chemotherapy, she was found to have asymptomatic systemic inflammatory response syndrome without a source of infection, which delayed initiation of first cycle. In 10 days, her hCG level had nearly doubled to 14,361 mIU/ml. During this delay, bleeding from her recurrent tumor rapidly dropped her hemoglobin. She was given transfusions and a total 30 Gy of pelvic radiation over 5 days to the vaginal cuff to reduce bleeding. Post radiation, hCG was noted at 11,915 mIU/ml. She had developed vancomycin nephrotoxicity by this time, and renally dosed EMACO

with omission of methotrexate was started. After the 1st cycle, her hCG was down to 2701 mIU/ml, but she was again admitted for 12 days with neutropenic fever with *Klebsiella pneumoniae* urinary tract infection, which delayed her 2nd cycle. Her 2nd cycle was given after pegfilgrastim, at renal dosage, again without methotrexate. Her hCG prior to 2nd cycle was down to 42 mIU/ml. After the 2nd cycle, she was again admitted with neutropenic fever with sepsis with disseminated *Cryptococcus laurentii* and remained hospitalized for 15 days, at which time, her hCG was down to 3 mIU/ml. The patient was hesitant about continuing EMACO secondary to multiple complications leading to hospital admissions. Repeat PET CT was obtained 6 months from the staging surgery, showing no recurrence in pelvis, interval resolution of FDG activity and interval decrease in sizes of pulmonary nodules. Her hCG was 1 mIU/ml. At this time, the patient agreed to close follow-up for recurrence surveillance but declined to receive further chemotherapy. The patient is now 20 months from the surgery and continues to remain free of disease as evidenced by physical exam, repeat PET CT and serum hCG.

Discussion

Dedifferentiation of advanced state of some malignancies enables acquisition of oncogenetic ectopic hCG β expression (Cole and Butler, 2012). The more dedifferentiated the tumor becomes, the more primitive cell replication becomes, and this may explain the effectiveness of chemotherapy regimen that targets the basic cell replication, such as EMACO (Pattillo, 1973). The hCG driven growth spurt is limited by the expression of β subunit encoded on chromosome 19. The α subunit on chromosome 6 is shared in all gonadotropins, and is expressed in excess in comparison to beta subunit whose expression is limited by transcription (Tarrade et al., 2001). EMACO chemotherapy includes actinomycin D, a potent inhibitor of transcription and a probable major component of EMACO affecting the transcription of hCG β . This process may result in cell kill of the clear cell component of this patient's

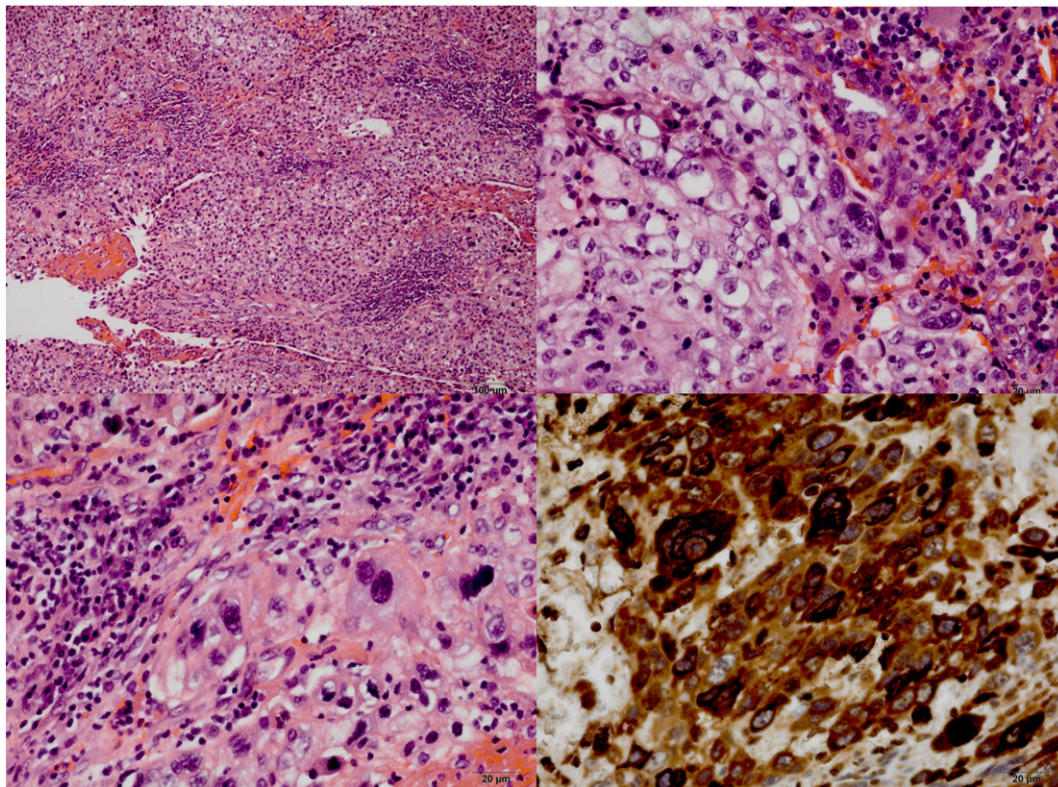


Fig. 2. Photomicrographs showing sheets of tumor cells with necrosis and acute inflammatory exudates in a bloody background. Tumor cells show variable amounts of cytoplasm, with occasional clearing and well defined cell borders. The nuclei are high grade with occasional bi- or multi-nucleation. Positive immunohistochemistry with hCG.

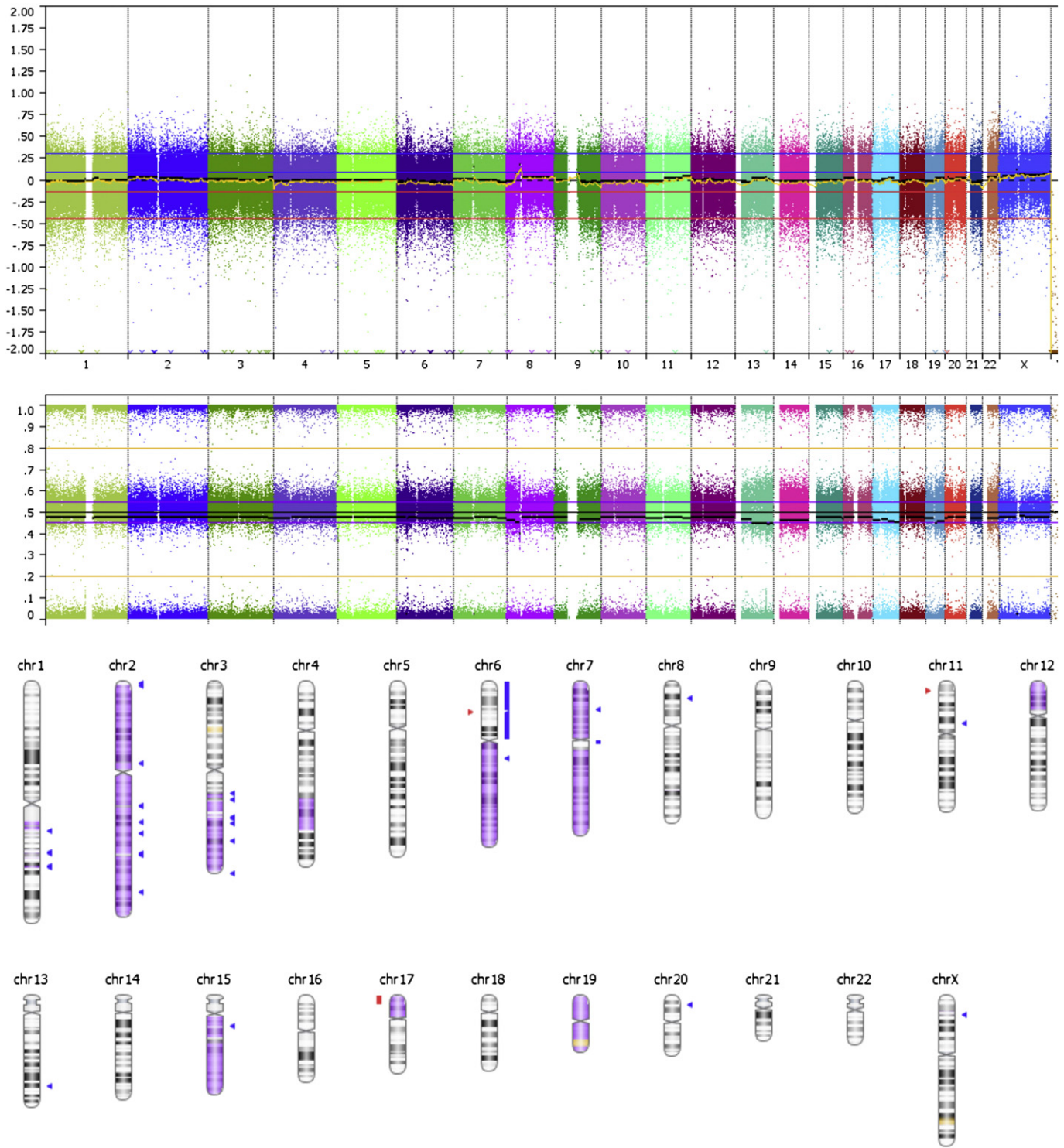


Fig. 3. Overview of the whole genome microarray of the tumor showing multiple copy number variations. Blue = duplication, red = deletion, purple = allelic imbalance.

tumor, dropping her hCG level, thus the autocrine or self-stimulation by the hCG would be eliminated.

Despite the case series demonstrating ectopic hCG expression in a substantial proportion of tumors (Iles, 2007) and the correlation of ectopic hCG expression and poor prognosis, there is a paucity of clinical trials addressing treatment of hCG expressing tumors. For our patient, EMACO proved its efficacy in treating her cancer.

Although the present report is an anecdotal experience, the EMACO chemotherapy outcome suggests that prospective studies of undifferentiated cancers bearing “clear cell morphology”, regardless of organ of origin, should be examined for hCG expression and clinical trials of EMACO regimen initiated. Such discussions and implementations are encouraged by this case report and are being institutionally pursued. Consequence of such a paradigm shift in cancer treatment may lead to

better outcomes, based not on the organ in which the cancer occurs, but rather on the genomic proteomic alterations unveiled by molecular testing.

Consent

Written informed consent for this report was obtained from the patient for publication of this case report, accompanying imaging and tumor testing. Morehouse School of Medicine institutional review board approved the written consent for tumor testing. A copy of written consent is available for review by the Editor-in-Chief of this journal on request.

Conflict of interest

The authors have no conflicts of interest to declare.

Acknowledgment

Authors would like to thank Natalia Kozyk, PhD, for her work on microarray testing, Frederick Bright, MD, for the intraoperative photograph and the medical oncology team under Myra Rose, MD for chemotherapy care of the patient.

References

Butler, S.A., Ikram, M.S., Mathieu, S., Iles, R.K., 2000. The increase in bladder carcinoma cell population induced by the free beta subunit of hCG is a result of an anti-apoptosis effect and not cell proliferation. *Br. J. Cancer* 82, 1553–1556.

- Cole, L.A., 2012. hCG, the wonder of today's science. *Reprod. Biol. Endocrinol.* 10, 1–18.
- Cole, L.A., Butler, S., 2012. Hyperglycosylated hCG, hCG β and hyperglycosylated hCG β : interchangeable cancer promoters. *Mol. Cell. Endocrinol.* 349, 232–238.
- Herr, F., Baal, N., Reisinger, K., Lorenz, A., McKinnon, T., Preissner, K.T., Zygmunt, M., 2007. HCG in the regulation of placental angiogenesis. Results of an in vitro study. *Placenta (Suppl. A)*, S85–S93.
- Iles, R.K., 2007. Ectopic hCG β expression by epithelial cancer: malignant behaviour, metastasis and inhibition of tumor cell apoptosis. *Mol. Cell. Endocrinol.* 260–262, 264–270.
- Iles, R.K., Delves, P.J., Butler, S.A., 2010. Does hCG or hCG β play a role in cancer cell biology? *Mol. Cell. Endocrinol.* 320, 62–70.
- Lapthorn, A.J., Harris, D.C., Littlejohn, A., Lustbader, J.W., Canfield, R.E., Machin, K.J., Morgan, F.K., Issacs, N.W., 1994. Crystal structure of human chorionic gonadotrophin. *Nature* 369, 455–461.
- Pattillo, R., 1973. Trophoblastic cancers: chorionic gonadotropin hormone production, antigenic expression, and trophoblast redifferentiation in multiple forms of malignancy. *Pathol. Annu.* 241–268.
- Pattillo, R.A., Gey, G.O., 1968. The establishment of a cell line of human hormone-synthesizing trophoblast cells in vitro. *Cancer Res.* 28, 1231–1236.
- Reisinger, K., Baal, N., McKinnon, T., Münstedt, K., Zygmunt, M., 2007. The gonadotropins: tissue-specific angiogenic factors? *Mol. Cell. Endocrinol.* 269, 65–80.
- Tarrade, A., Schoonjans, K., Guibourdenche, J., Bidart, J.M., Vidaud, M., Auwerx, J., Rochette-Egly, C., Evain-Brion, D., 2001. PPAR γ /RXR α heterodimers are involved in human CG β synthesis and human trophoblast differentiation. *Endocrinologie* 142, 4504–4514.