



REVIEW / *Breast imaging*

## Pathologies of the male breast

M. Charlot<sup>a,\*</sup>, O. Béatrix<sup>b</sup>, F. Chateau<sup>a</sup>,  
J. Dubuisson<sup>b</sup>, F. Golfier<sup>b</sup>, P.J. Valette<sup>a</sup>, F. Réty<sup>a</sup>

<sup>a</sup> *Medical Imaging Department, Lyon South General Hospital, 165, chemin du Grand-Revoyet, 69310 Pierre-Bénite, France*

<sup>b</sup> *Gynaecological Oncology Department, Lyon South General Hospital, 165, chemin du Grand-Revoyet, 69310 Pierre-Bénite, France*

### KEYWORDS

Breast;  
Man;  
Cancer;  
Gynaecomastia

**Abstract** The majority of breast lesions in men are benign. Gynaecomastia is a very common condition in which hormonal changes cause male breasts to enlarge. Three radiological patterns of gynaecomastia have been described: nodular, dendritic, and diffuse glandular pattern. The main differential diagnosis is lipomastia, which is when adipose tissue deposits are found in the subcutaneous tissue. Male breast cancer is rare. The main risk factors are pathologies that cause hormonal imbalances, a history of chest irradiation, and a family history of breast cancer (particularly in families carrying a mutation of the gene *BRCA2*). Mammography usually shows a mass with no calcifications. Sonography is useful to investigate local disease spread, and for detecting any enlarged axillary lymph nodes. MRI is not currently indicated to investigate male breast cancer. Very often, the clinical examination alone is enough to distinguish benign lesions from malignant lesions. Imaging must not be automatically carried out, but rather it should be used when the diagnosis is clinically uncertain or when patients present risk factors for breast cancer, as well as for guiding biopsies and for assessing disease spread.

© 2012 Éditions françaises de radiologie. Published by Elsevier Masson SAS. All rights reserved.

### Introduction

The majority of breast lesions in men are benign, since gynaecomastia is by far the most common aetiology. Breast cancers are rare in men, accounting for approximately 1% of cases [1,2]. Other breast pathologies are related to the cutaneous and subcutaneous tissue (lipoma, fat necrosis, lipomastia, abscess, epidermal inclusion cyst, etc.) [3].

The most common reasons for a man to seek a consultation are increased breast size, appearance of a nodule, or pain.

*Abbreviations:* ACR, American College of Radiology; MRI, Magnetic Resonance Imaging; *BRCA1*, BReast CAncer 1; *BRCA2*, BReast CAncer 2.

\* Corresponding author.

*E-mail address:* mathilde.charlot@chu-lyon.fr (M. Charlot).

## Imaging techniques

If a mammogram is required, the imaging techniques are the same as those used in women. A bilateral mammogram view (usually oblique) may be enough, or investigations may need to be completed by further views, localised and magnification images with focal compression, and sonography (Fig. 1). It is also possible to obtain geometric magnification images from the outset in order to achieve improved spatial resolution, since the entirety of the breast volume will be analysed, taking its smaller size into account, but the disadvantage is that increased doses of irradiation are needed.

## Gynaecomastia

### Background

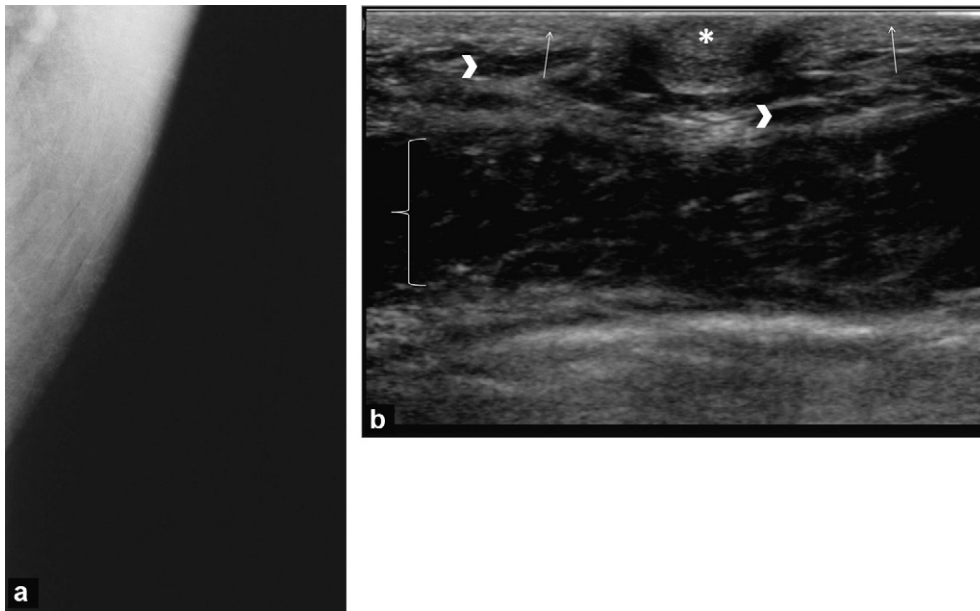
From birth up to puberty, breast tissue is identical in both sexes. During puberty in boys, levels of oestrogens do increase (stimulating the growth of breast tissue) but more importantly there is a major increase in testosterone levels (antagonising the effects of oestrogen). This means that there is a temporary proliferation of breast ducts and stroma, followed by involution of these ducts. The terminal lobular units do not develop in the male breast due to an absence of progesterone. Cooper's ligaments are also absent in the male breast [1].

Gynaecomastia is a very common benign pathology (found in up to 55% of male breasts in series of autopsy specimens) [4]. It is an increase in breast size due to a proliferation of breast ducts and stromal tissue secondary to an increased oestrogen to testosterone ratio. There are numerous aetiologies for these common physiological and

hormonal changes in adolescent boys and men over the age of 60; they can also arise secondary to endocrine disease, some kinds of neoplasms, systemic disease, or medications (Boxed text 1) [3,5,6].

### Boxed text 1 The main causes of gynaecomastia [3,6].

- Physiological:
  - Senescence,
  - Puberty.
- Endocrine:
  - Klinefelter Syndrome,
  - Hypogonadism,
  - Hypothyroidism.
- Systemic disease:
  - Cirrhosis,
  - Chronic renal failure.
- Tumours:
  - Testicular tumours,
  - Adrenal carcinoma,
  - Pituitary adenoma,
  - Hepatocellular carcinoma.
- Toxicity, medications:
  - Alcohol,
  - Cannabis,
  - Digoxin,
  - Cimetidine,
  - Thiazide diuretics,
  - Omeprazole,
  - Tricyclic antidepressants,
  - Spironolactone,
  - Diazepam,
  - Anabolic-androgen steroids,
  - Exogenous oestrogens.
- Idiopathic.



**Figure 1.** Normal breast imaging in a man: a: a mammogram attempt, oblique view: only the pectoral muscle is visible; b: sonogram of a normal male breast demonstrating the nipple (star), hyperechoic skin (arrows), a few hypoechoic fatty lobules (arrowheads), and pectoral muscle (bracket).

## Clinical examination

Gynaecomastia is often easy to diagnose on clinical examination, presenting as a firm, mobile mass centred under the areola that can be painful, especially if it has developed recently [5,7]. It is usually bilateral and asymmetrical (84%), but it can be unilateral (14%), or bilateral and symmetrical (2%). It is important to examine the patient's testicles, as a number of testicular pathologies and especially tumours can cause gynaecomastia. Even if the gynaecomastia is benign, in which case it will not usually require any specific management, the associated pain can be disabling and may require treatment (for example, use of a topical gel containing testosterone). It can have a very significant psychological impact on patients, especially adolescent boys, and may lead to mastectomy.

## Imaging

Three radiological patterns of gynaecomastia have been described [1,3,7]:

- the nodular pattern, which is seen in the florid early phase: the mammogram shows a disc-shaped, homogenous, well-circumscribed opacity that may have some posterior irregularities. Sonography demonstrates a hypoechoic mass beneath the nipple surrounded by fatty tissue (Fig. 2);
- the dendritic pattern, which is seen in the irreversible, chronic, fibrotic phase: the mammogram shows a non-homogenous wedge-shaped opacity with its apex in the retro-areolar region, and with posterior linear extensions radiating into the deep adipose tissue, predominating in the upper outer quadrant. Sonography shows a wedge-shaped hypoechoic area centred on the nipple with irregular posterior margins that extend into the echogenic fibrous breast tissue (Figs. 3 and 4);
- the diffuse glandular pattern: this consists of an overall increase in breast size that presents identically on mammography and sonography to the female dense heterogeneous breast (Fig. 5).

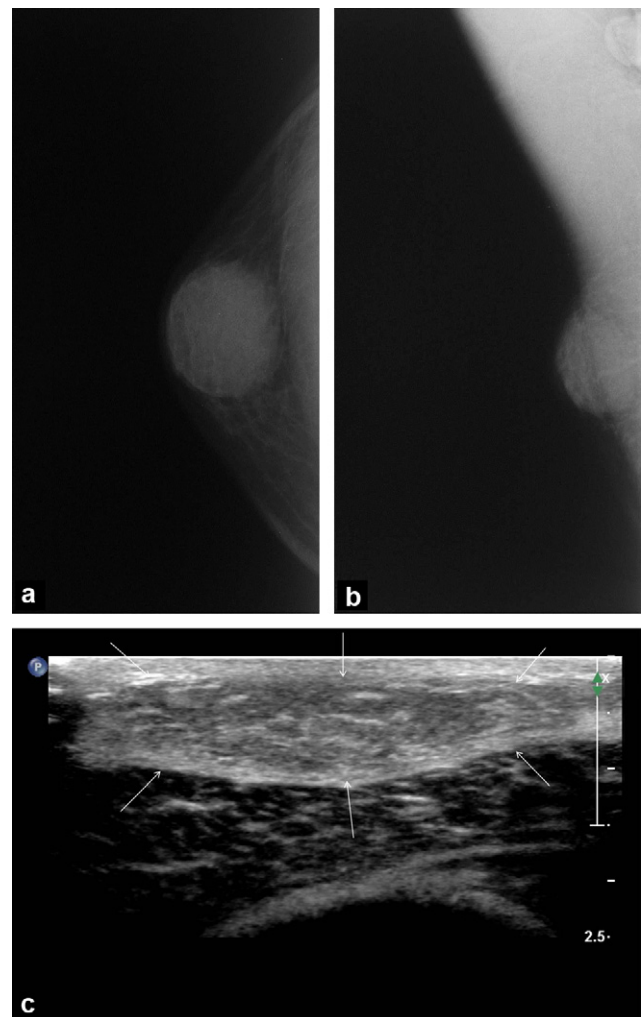
## Differential diagnosis

The main differential diagnosis of gynaecomastia is lipomastia (or pseudogynaecomastia), which is the excessive subcutaneous deposition of adipose tissue. The diagnosis is usually made clinically based on the presentation of bilaterally increased breast volume that is soft in consistency, with no clearly demarcated retro-areolar mass [5]. On imaging, no radio-opaque structures are demonstrated [6,8] (Fig. 6).

## Breast cancer

### Background

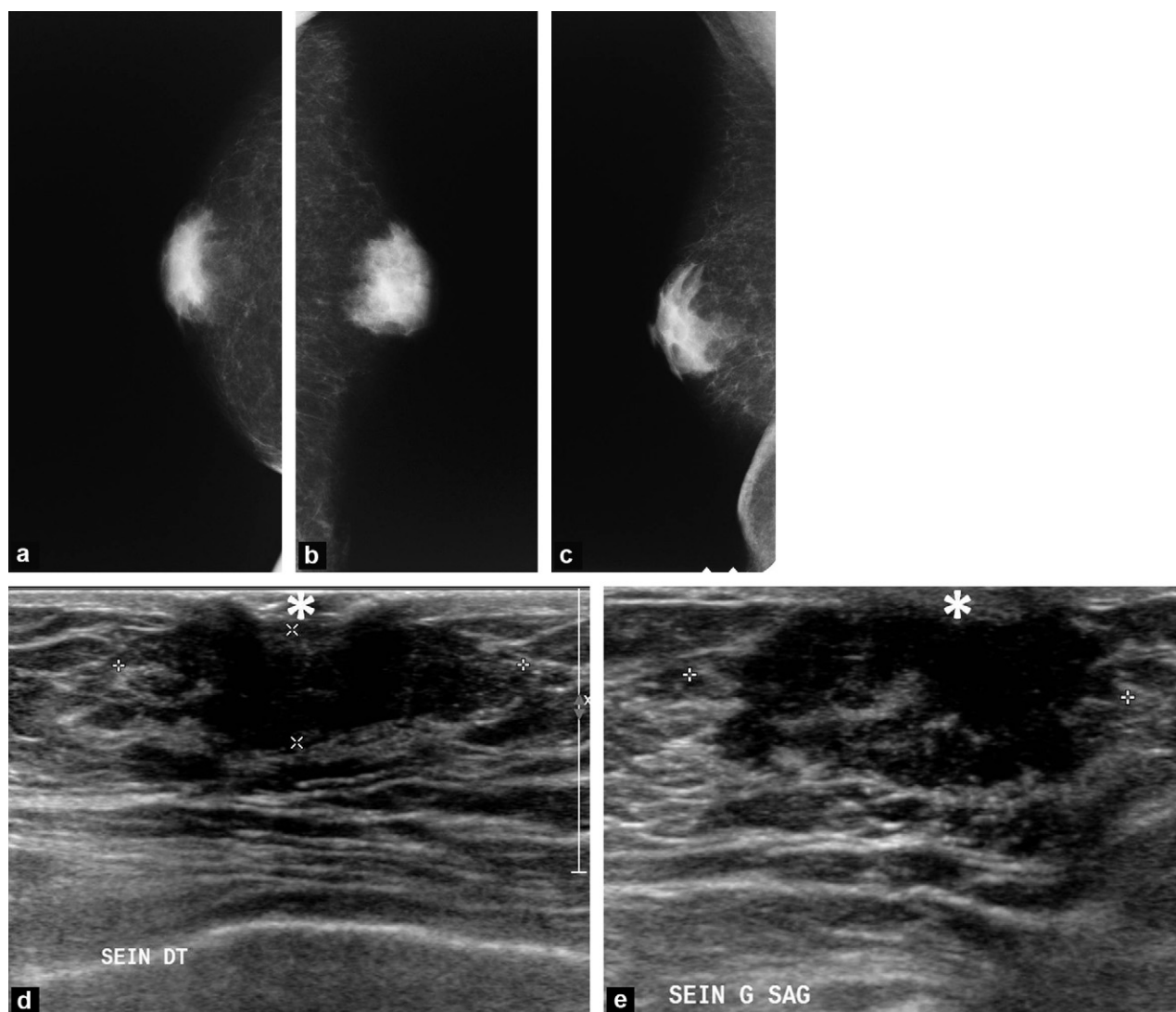
Breast cancer in men is rare, with an annual incidence in Europe of 1 in 100,000. Fewer than 1% of all patients with breast cancer are men [4,9]. It mainly occurs in elderly patients, peaking in incidence at age 71 [4].



**Figure 2.** Nodular pattern gynaecomastia. A 22-year-old male patient who was being monitored for cystic fibrosis. Progressive appearance of a painful mass behind the right nipple. Mass with low density centred on the nipple with clear anterior margins, while the posterior margins are less well-circumscribed: a: anteroposterior view of the right breast; b: oblique view of the right breast; c: sonogram of the right breast: slightly hypoechoic area in the retro-areolar breast (arrows), no suspicious mass. A microbiopsy demonstrated that gynaecomastia was present with no signs of malignancy.

Most of the risk factors (Boxed text 2) are suggestive of changes in the ratio of oestrogens to androgens. This means that an increased risk is seen in patients with Klinefelter syndrome (relative risk of 50), testicular abnormalities, cirrhosis, and those who are obese [10]. If the patient has a history of chest radiotherapy, this also increases the risk of breast cancer. Although the risk factors for gynaecomastia are similar, it is not linked to an increased risk of cancer.

There is a familial predisposition, with 20% of men with breast cancer having a family history of breast cancer in first degree female relatives [4]. The genetic risk may be due to mutations in highly penetrant genes, especially mutations of the *BRCA2* gene; the risk linked to mutations in the *BRCA1* gene is less significant and has been described only recently. One study in an American population estimated



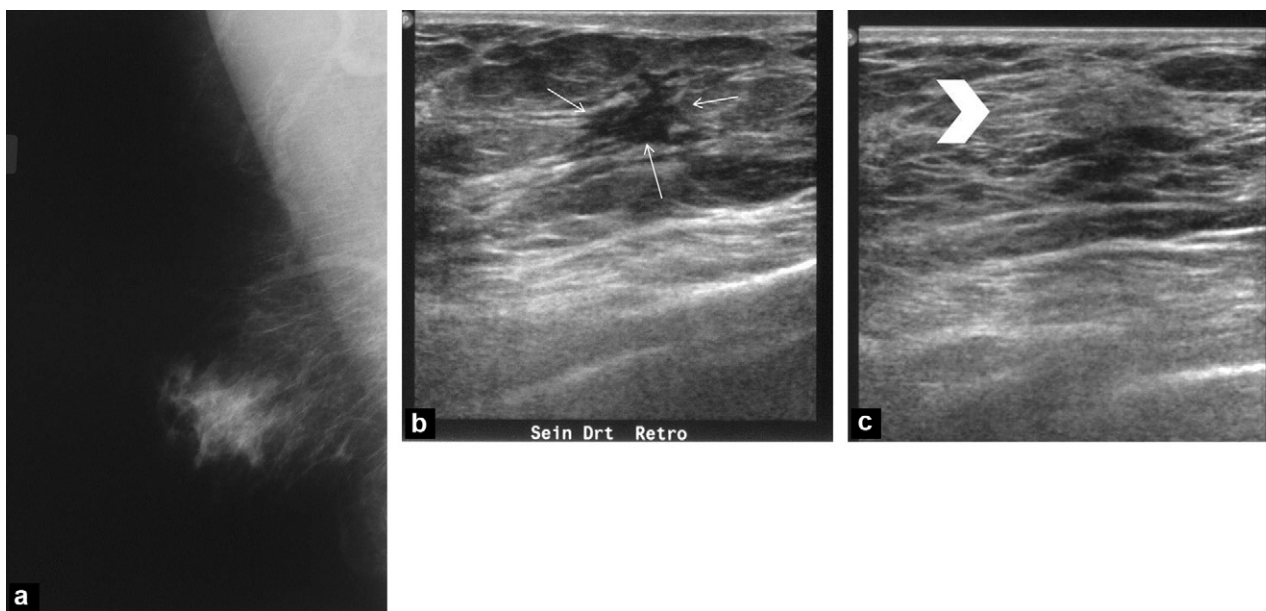
**Figure 3.** Dendritic pattern gynaecomastia: A 63-year-old patient presented with enlarged breasts on both sides, while being followed for cirrhosis complicated by hepatocellular carcinoma: a: anteroposterior view of the right breast; b: anteroposterior view of the left breast; c: oblique view of the right breast. Non-homogenous bilateral opacities with apices behind the nipple and posterior extensions into the fatty tissue; d: sonogram of the right breast; e: sonogram of the left breast: hypoechoic structures (arrows) centred on the nipples (stars), with irregular posterior margins extending into the echogenic fibrous tissue. A microbiopsy demonstrated that gynaecomastia was present with no signs of malignancy.

the cumulative risk of male breast cancer at age 70 to be 6.8% for carriers of a mutation of the *BRCA2* gene and 1.2% for carriers of a mutation to the *BRCA1* gene [11]. Depending on the population studied, between 4 and 40% of men with breast cancer carry the mutation of the *BRCA2* gene and between 0 and 11% carry the mutation of the *BRCA1* gene [4,12]. If a male family member has breast cancer this is therefore a risk factor for the mutation and this alone may be an indication for a referral for an oncological genetics consultation [13–15]. The *Current National Comprehensive Network* recommends breast monitoring for men carrying these genetic mutations, which should include teaching them to self-examine the breast, twice-yearly clinical monitoring, and scheduling an initial mammogram to be followed by annual repeat mammography if gynaecomastia or breast density is seen on the first mammogram [16].

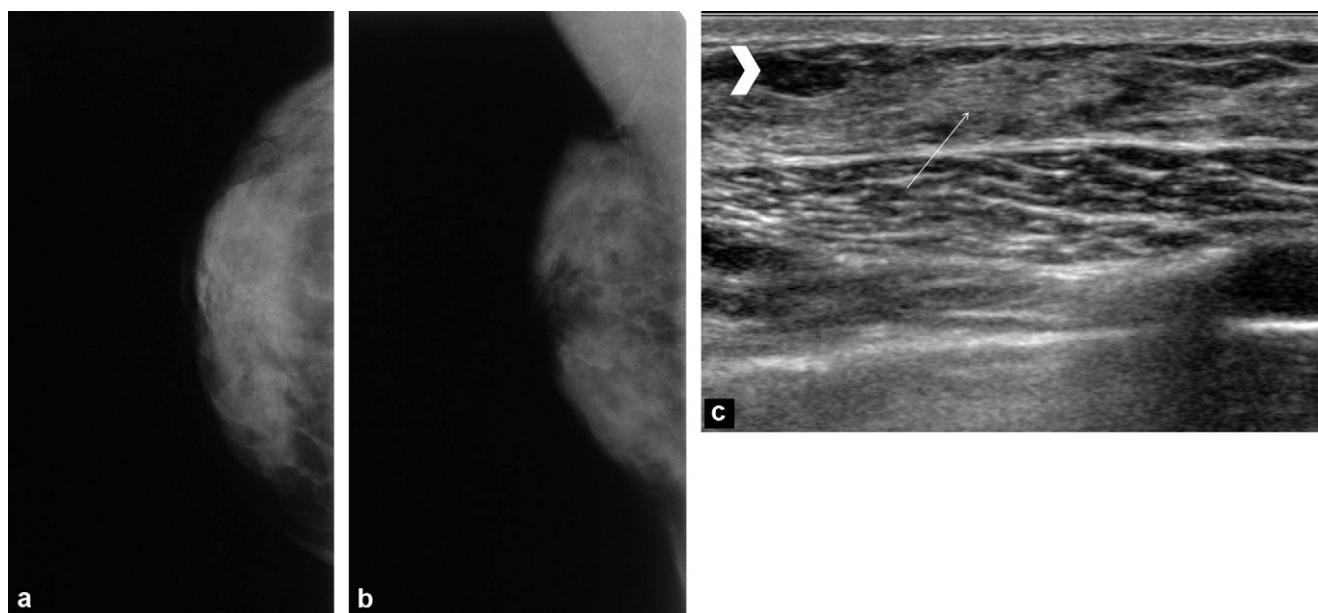
The histological type encountered most often is invasive ductal carcinoma, which accounts for almost 90% of cases. Ductal carcinoma in situ accounts for 10% of cases, with papillary carcinoma making up 75% of these. Lobular carcinoma is very rare (1%) because of the absence of a differentiated terminal lobular unit in the normal male breast, even in males with gynaecomastia, and the vast majority of cases of this type arise in patients with Klinefelter syndrome (XXY). Over 90% of tumours are hormone receptor positive. The prognosis based on histology is similar to that identified for women of an identical age [4,10,17].

### Clinical examination

The diagnosis of breast cancer is very often clinically evident [18]. The most common presentation is a non-painful



**Figure 4.** Dendritic pattern gynaecomastia: painful mass behind the right nipple that has been present for 4 months in a 58-year-old male patient: a: oblique mammogram of the right breast: the features of the area behind the nipple are identical to those of a woman with type II breast density; b and c: sonogram of the right breast: hypoechoic wedge-shaped image with its apex behind the nipple and irregular margins (arrows), within the hyperechoic breast (arrowhead).

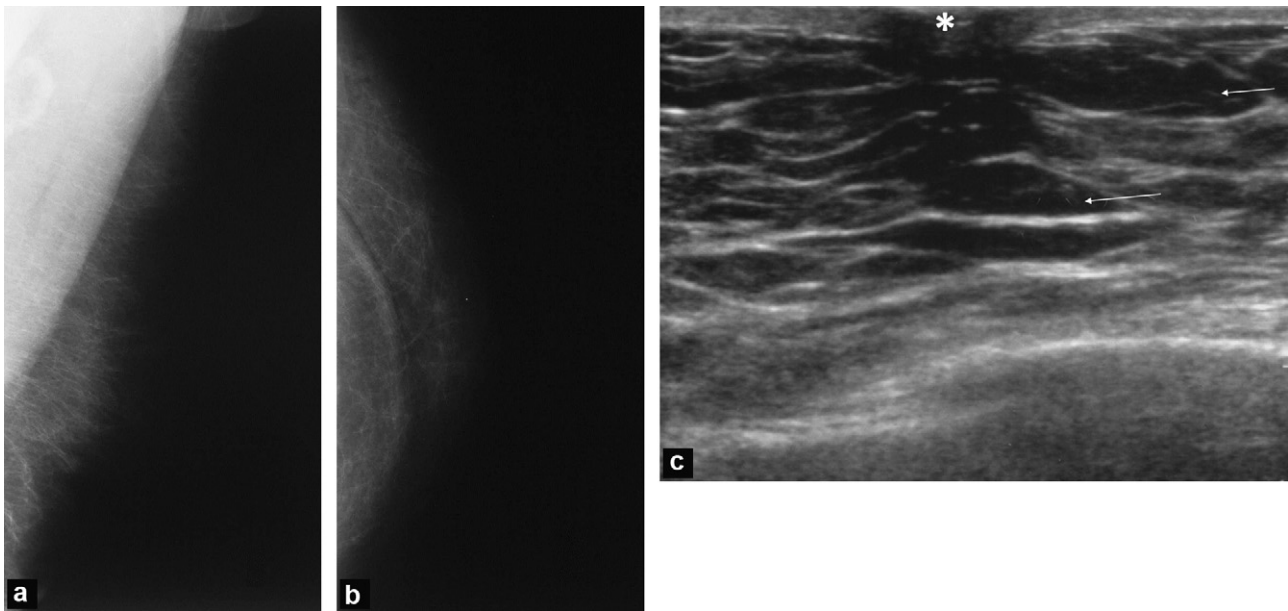


**Figure 5.** Diffuse glandular pattern gynaecomastia. A 25-year-old male patient presenting an isolated hypertrophy to the right breast that he had known for 3 years: identical features to those seen in a woman with type 4 breast density: a: anteroposterior mammogram of the right breast; b: oblique mammogram of the right breast; c: sonogram of the right breast: presence of hyperechoic fibrous breast tissue (arrow), a few hypoechoic fatty lobules (arrowhead).

indurated mass (75% of cases). This is highly suspicious of cancer if it is peripheral to the nipple (Fig. 8a). The nipple is affected relatively early on, and this kind of involvement can present as retraction, ulceration, or discharge. Regional cutaneous metastases are possible (Fig. 7). Due to the rarity and lack of understanding of this pathology, diagnosis is often delayed, with over 40% of cancers being diagnosed at stages 3 or 4 [4].

## Imaging

The mammogram usually shows a dense mass without calcifications (Figs. 8–10). It very often has spiculated, indistinct, or microlobulated margins, although they can be circumscribed [9]. The mass is usually situated in the retro-areolar region, as male breast cancer often originates in the central ducts. A peripheral mass is highly suspicious for malignancy



**Figure 6.** Lipomastia. Patient presenting a longstanding increase in size to both breasts with no palpable mass: a: oblique mammogram of the left breast; b: and anteroposterior mammogram of the left breast. Tissue density demonstrates fatty tissue only; c: sonogram of the left breast: only hypoechoic fatty lobules (arrow) are present below the nipple (star).

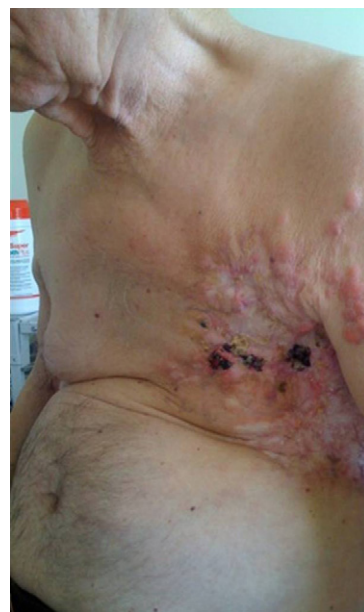#### Boxed text 1 Risk factors for breast cancer in men [4,10,14].

- Advanced age.
- Genetic factors:
  - Klinefelter syndrome,
  - Mutations of the genes *BRCA2* > *BRCA1*.
- History of chest irradiation.
- Occupational exposure:
  - Heat,
  - Exhaust gas.
- Taking oestrogen.
- Testicular disease:
  - Cryptorchidism,
  - Congenital inguinal hernia,
  - Orchiectomy,
  - Testicular trauma.
- Cirrhosis.
- Obesity.
- Alcohol.

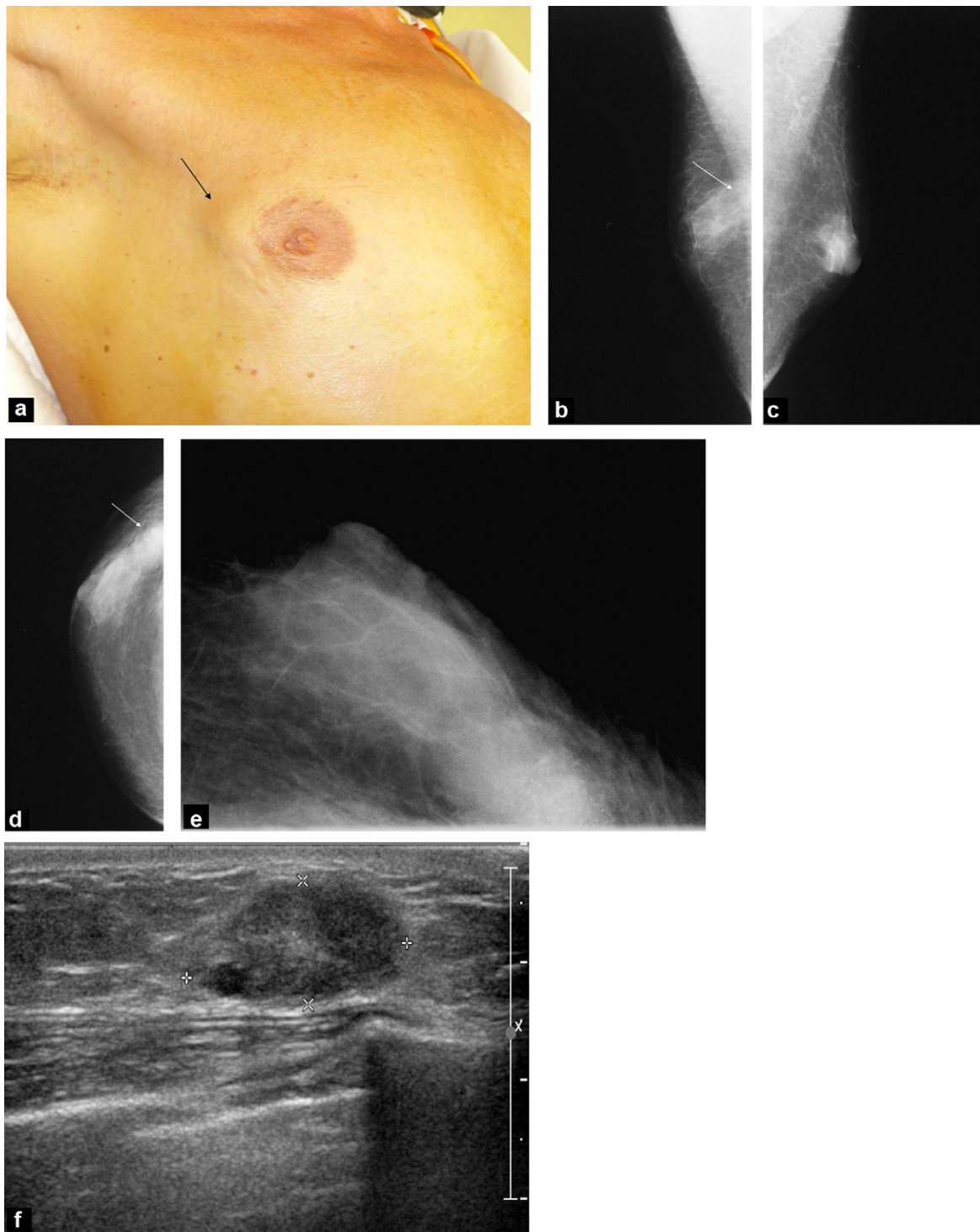
because it cannot be gynaecomastia [1,6,8]. The presence of microcalcifications is less common than it is in female breast cancers and when they do present, they are generally coarser, more widespread, and more rarely linear (Fig. 8b–e) [6,7]. The kinds of microcalcifications that are not particularly suspicious in women (for example nodular calcifications) are often malignant lesions in men [7,9]. Associated signs such as nipple retraction, cutaneous thickening, and axillary lymphadenopathies are often found, and these are seen in much smaller lesions in men than in women, due to the smaller breast size of men [1].

Similar signs are demonstrated on sonography as those seen in breast cancers of the same histological type presenting in women. The most commonly described finding

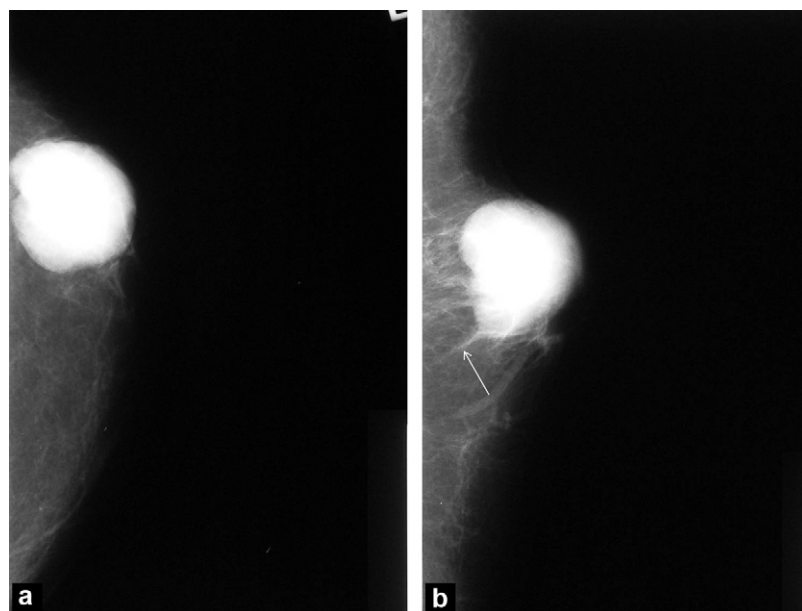
is an irregularly-shaped mass that is hypoechoic with angular, microlobulated, or spiculated margins (Fig. 8 f) [1,19]. Sonography may be useful to pinpoint the position of the mass in relation to the nipple: a lesion that appears to be retro-areolar on mammography may turn out to be peripheral on sonography [1]. A complex cystic mass is highly suspicious in a man and will require surgery irrespective of the cytopathology or biopsy results [1,19]. Sonography is useful to assess local disease spread, as it allows any spread into the cutaneous tissue, nipple, or pectoral muscle to be visualised, as well as demonstrating whether there are



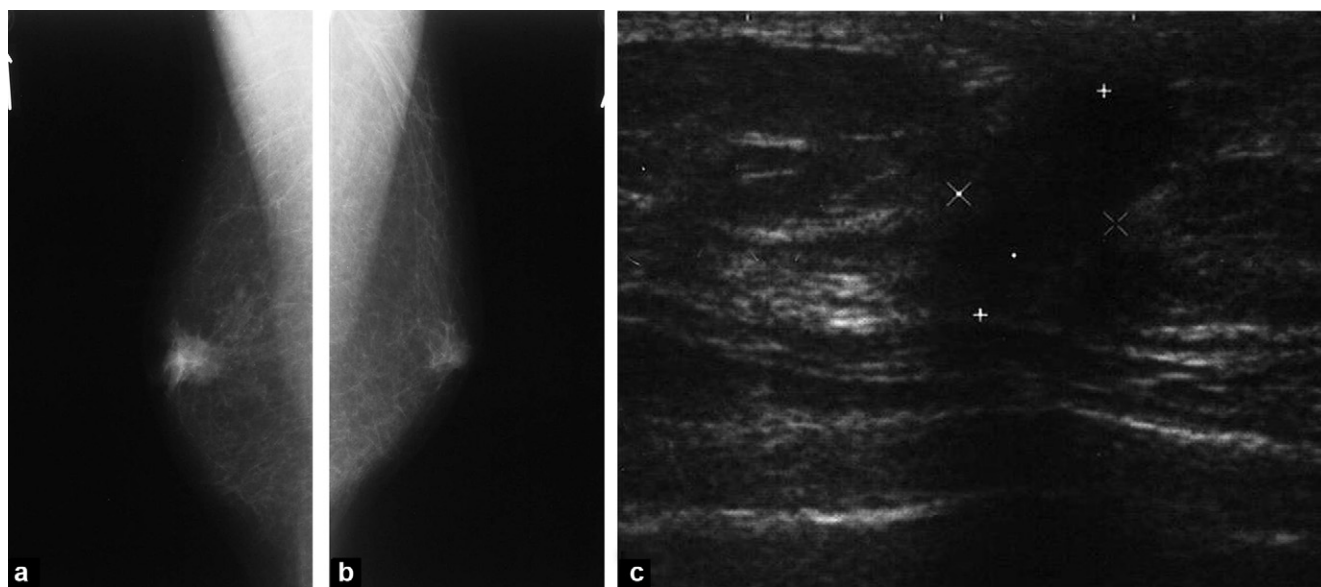
**Figure 7.** Ductal carcinoma of the left breast with cutaneous metastases.



**Figure 8.** Invasive ductal carcinoma. A 57-year-old male patient presenting an indurated tumefaction of the left breast that had developed over 2 years: a: the peripheral nature of the nodule noted on clinical examination (arrow) is suggestive of malignancy; b: oblique mammogram of the right breast; c: oblique mammogram of the left breast; d: anteroposterior mammogram of the right breast: bilateral dendritic pattern gynaecomastia and presence of a deep mass with indistinct and poorly circumscribed margins, classed as ACR 5, in the upper outer quadrant of the right breast (arrows); e: magnified anteroposterior image focusing on the outer quadrants of the right breast: presence of numerous nodular, amorphous microcalcifications within the mass; f: sonogram: heterogeneous mass of tissue that is slightly hypoechoic, with poorly circumscribed margins and no posterior acoustic changes, situated in the upper outer quadrant.



**Figure 9.** Invasive ductal carcinoma: a: anteroposterior mammograms of the left breast; b: oblique mammogram of the left breast: dense mass with irregular, spiculated posterior margins (arrow) that is peripheral to the nipple, classed as ACR 5.



**Figure 10.** Invasive ductal carcinoma. A 68-year-old male patient attending due to retraction of the right nipple that had developed over several weeks: a: oblique mammogram of the right breast; b: oblique mammogram of the left breast; right breast: mass behind the nipple with irregular and spiculated margins; left breast: small amount of retro-areolar residual glandular tissue; c: correlation on sonography: irregular hypoechoic mass with a vertical long axis and a posterior shadow cone.

multicentric lesions, and detecting enlarged axillary lymph nodes (present in almost 50% of cases) [1,7,9]. If there are no suspicious lymph nodes found on clinical examination or sonography, this may mean that the sentinel lymph node biopsy technique can be used, and this has shown encouraging results in men whilst avoiding the morbidity of axillary node clearance [4,14,20].

The use of MRI has not been widely studied in male breast cancer. One study involving 17 patients showed that signs of malignancy or benign lesions were identical to those in

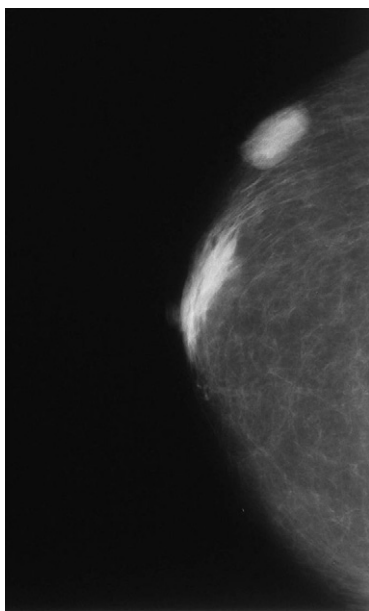
breast lesions in women [21]. MRI currently has no recognised indication for investigating male breast cancer.

## Differential diagnosis

### Benign lesions

The diagnosis of nodular or dendritic pattern gynecomastia is usually made clinically (context, mobile non-indurated mass, often painless, no nipple discharge, no associated signs). Imaging in gynecomastia always demonstrates a





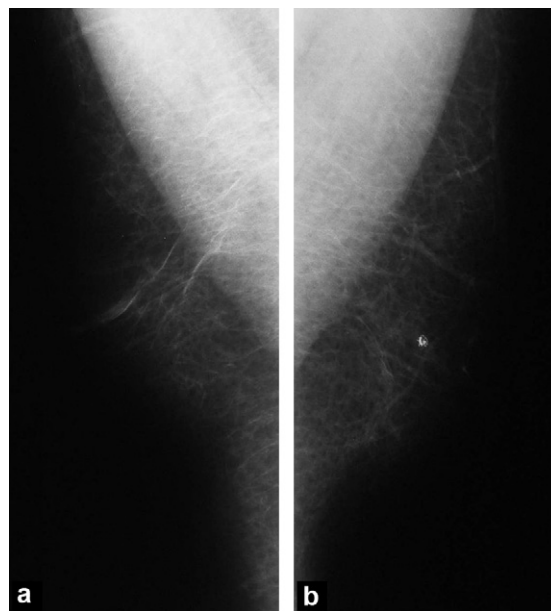
**Figure 11.** Inflammatory subcutaneous nodule without tumour cells in a 75-year-old patient with chronic renal failure. Anteroposterior mammogram of the right breast: dense oval external mass with circumscribed margins.

lesion centred on the nipple with no associated signs (Figs. 2–5) [1].

A lipoma will present on mammography as a well-circumscribed, radiolucent image, while sonography will show a slightly hyperechoic oval mass that is often encapsulated [1].

Epidermal inclusion cysts are keratin deposits in an obstructed hair follicle. The mammogram will show a dense, well-circumscribed, superficial, oval mass, which appears on sonography as a hypoechoic mass with posterior enhancement. On sonography, the lesion always maintains continuity with the epidermis, meaning that it can be differentiated from potentially malignant cysts in men [1,7].

A retro-areolar abscess is a rare lesion that is frequently chronic and is associated with mammary duct ectasia. On



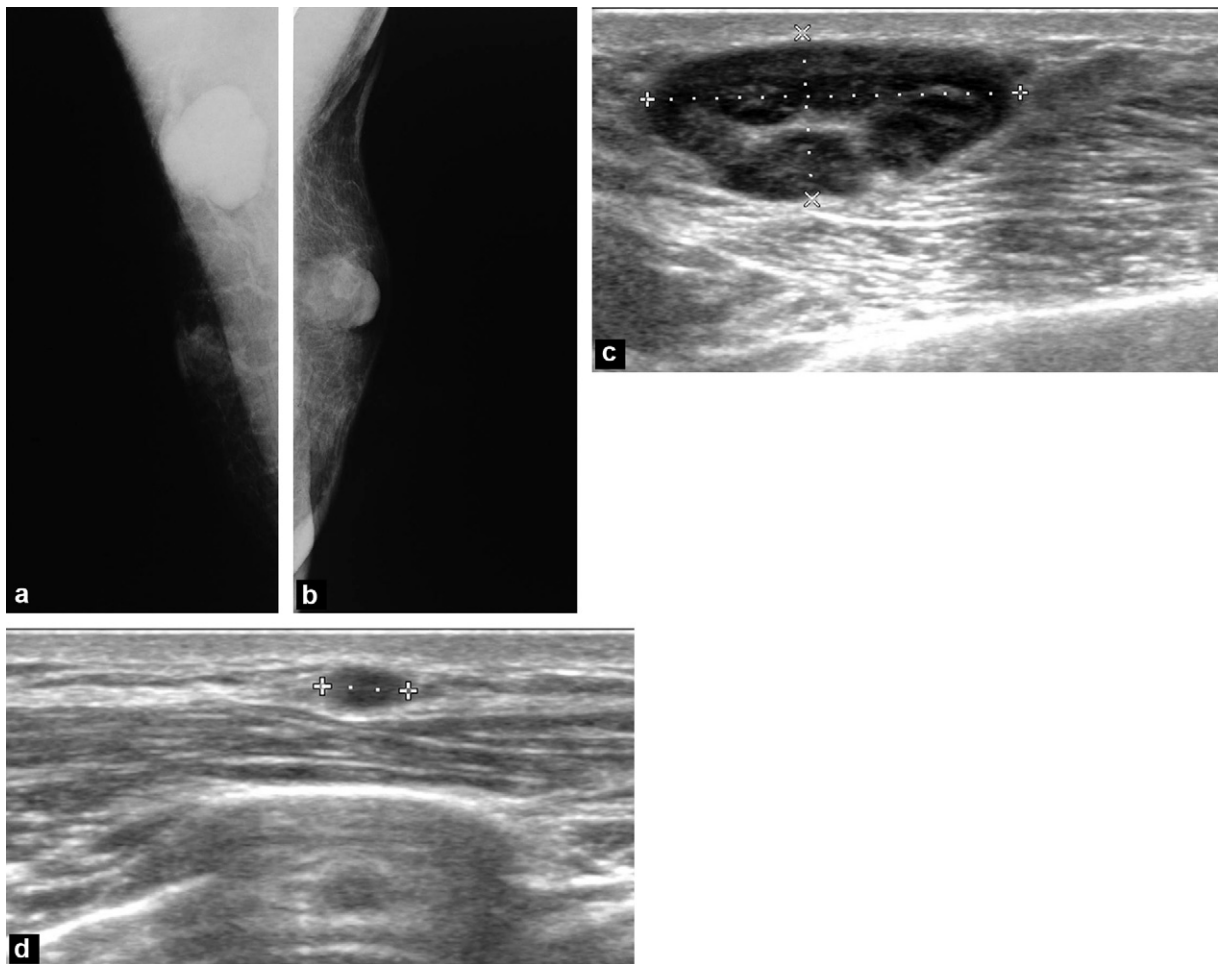
**Figure 12.** Benign calcification: a: oblique mammogram of the right breast; b: oblique mammogram of the left breast: bilateral lipomastia. Benign macrocalcification of the left breast.

imaging, it appears as a hypoechoic mass with poorly circumscribed margins that may be associated with cutaneous thickening. It is difficult to differentiate from a malignant lesion and a biopsy is usually required. It often recurs after surgical excision [7].

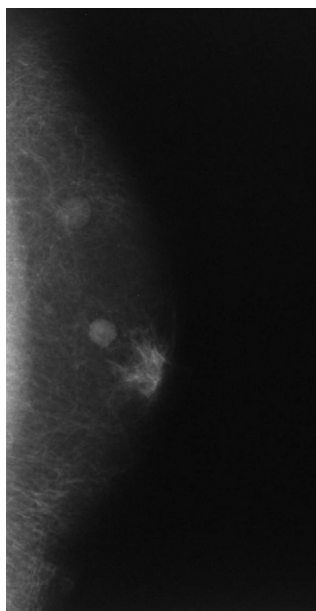
All benign lesions described in women can also be found in men and the features are similar (Figs. 11-13) [1,8]: fat necrosis, pseudoangiomatous stromal hyperplasia (often associated with gynaecomastia), papilloma, intramammary lymph nodes, inflammatory lesions etc.

### Malignant lesions

Breast metastases from cancers elsewhere in the body are rare. They usually originate from prostate or lung cancers, melanoma, or lymphoma. They multiply readily and are round and well-circumscribed (Fig. 14) [7].



**Figure 13.** Enlarged axillary lymph nodes and intramammary lymph node. Patient with severe atopic dermatitis and multiple enlarged lymph nodes: a: oblique mammogram of the right breast: Very enlarged axillary lymph node; b: oblique mammogram of the left breast: dense, oval mass with circumscribed margins that correlates on pathological anatomy investigations to a dermatopathic intramammary lymph node; c: sonogram of the right axilla: Enlarged lymph nodes presenting cortical thickening; d: sonogram of the left breast region next to the nipple: hypochoic oval mass with circumscribed margins and no posterior beam attenuation (dermatopathic intramammary lymph node).



**Figure 14.** Lymph node metastases from a melanoma to the left arm in a 64-year-old male. Oblique mammogram of the left breast: two round masses, one of which is a dense mass with microlobulated margins behind the nipple, and the other is in the upper outer quadrant, is less dense, and has indistinct posterior margins.

## Conclusion

Most breast symptoms seen in men relate to benign processes (gynaecomastia, lipomastia) that the clinician will suspect based on the history and clinical examination. Imaging is then able to back up the diagnosis but it does not provide much additional diagnostic information. The diagnosis of a malignant lesion can often be clinically evident, and it has not been established whether preoperative imaging studies are useful.

There is currently no consensus on the indications for imaging when faced with a breast abnormality in a male patient, nor on the type of examination that should be carried out first. Sonography can assist in diagnosis when gynaecomastia is suspected on clinical examination, especially in young males, but to our knowledge there has been no evaluation of sonography only or as a first line investigation into a clinical abnormality. Mammography should not be carried out automatically, but rather it should be reserved for when the clinical diagnosis is uncertain, and for patients in whom several diagnoses may be possible. In the vast majority of cases it is able to differentiate gynaecomastia from malignant lesions [1]. A bilateral examination must be carried out because the factors that predispose a patient to gynaecomastia and to cancer affect both breasts [1]. Imaging is also useful for guiding biopsies, for assessing local disease spread of malignant lesions, and to look for enlarged axillary lymph nodes if use of the sentinel node biopsy technique is being considered. The imaging investigations report can be presented in the same way as is done for women, using the American College of Radiology (ACR) classification of images according to how pathologically suspicious they are. Munn has put forward a series of actions to

be taken when faced with a palpable breast lesion in a male patient [22]:

- patients who present a dominant mass, ulceration, or inflammatory changes should undergo biopsy from the outset;
- for patients whose clinical examination is suggestive of gynaecomastia: If they are under the age of 40 and have no risk factors for breast cancer, imaging is not required. If the patient is aged over 40 or he presents risk factors for breast cancer, a mammogram will be carried out to confirm a diagnosis of gynaecomastia or lipomastia;
- for patients who present an indurated or firm mass that is not typical of gynaecomastia a mammogram may be useful and, depending on the results, biopsy samples may be taken. If the patient is over 40 years old and/or has risk factors, a biopsy may be indicated from the outset with or without other imaging investigations.

## Disclosure of interest

The authors declare that they have no conflicts of interest concerning this article.

## References

- [1] Chen L, Chantra PK, Larsen LH, et al. Imaging characteristics of malignant lesions of the male breast. *Radiographics* 2006;26:993–1006.
- [2] Hines SL, Yasrebi M, Tan WW, Perez EA, DePeri ER. The role of mammography in male patients with breast symptoms. *Mayo Clin Proc* 2007;82:297–300.
- [3] Appelbaum AH, Evans GFF, Levy KR, Amir Khan RH, Schumpert TD. Mammographic appearances of male breast disease. *Radiographics* 1999;19:559–68.
- [4] Fentiman IS, Fourquet A, Hortobagyi GN. Male breast cancer. *Lancet* 2006;367:595–604.
- [5] Johnson RE, Murad MH. Gynecomastia: pathophysiology, evaluation, and management. *Mayo Clin Proc* 2009;84:1010–5.
- [6] Cooper RA, Gunter BA, Ramamurthy L. Mammography in men. *Radiology* 1994;191:651–6.
- [7] Günhan-Bilgen I, Bozkaya H, Üstün EE, Memis A. Male breast disease: clinical, mammographic, and ultrasonographic features. *Eur J Radiol* 2002;43:246–55.
- [8] Chantra PK, So GJ, Wollman JS, Bassett LW. Mammography of the male breast. *AJR Am J Roentgenol* 1995;164:853–8.
- [9] Mathew J, Perkins GH, Stephens T, Middleton LP, Yang WT. Primary breast cancer in men: clinical, imaging, and pathologic findings in 57 patients. *AJR Am J Roentgenol* 2008;191:1631–9.
- [10] Giordano SH, Buzdar AU, Hortobagyi GN. Breast cancer in men. *Ann Intern Med* 2002;137:678–87.
- [11] Tai YC, Domchek S, Parmigiani G, Chen S. Breast cancer risk among male BRCA1 and BRCA2 mutation carriers. *J Natl Cancer Inst* 2007;99:1811–4.
- [12] Mohamad HB, Appfelstaedt JP. Counseling for male BRCA mutation carriers: a review. *Breast* 2008;17:441–50.
- [13] Eisinger F, Bressac B, Castaigne D, et al. Identification et prise en charge des prédispositions héréditaires aux cancers du sein et de l’ovaire (mise à jour 2004). *Bull Cancer* 2004;91:219–37.
- [14] Ottini L, Palli D, Rizzo S, Federico M, Bazan V, Russo A. Male breast cancer. *Crit Rev Oncol Hematol* 2010;73:141–55.
- [15] Korde LA, Zujewski JA, Kamin L, et al. Multidisciplinary meeting on male breast cancer: summary and research recommendations. *J Clin Oncol* 2010;28:2114–22.

- [16] National Comprehensive Cancer Network. Practice Guidelines in Oncology - v.1.2010. Hereditary Breast and/or Ovarian Cancer. <http://www.nccn.org>, 2010.
- [17] Cutuli B, Le-Nir CC-S, Serin D, et al. Male breast cancer. Evolution of treatment and prognostic factors. Analysis of 489 cases. *Crit Rev Oncol Hematol* 2010;73:246–54.
- [18] Hanavadi S, Monypenny IJ, Mansel RE. Is mammography overused in male patients? *Breast* 2006;15:123–6.
- [19] Yang WT, Whitman GJ, Yuen EHY, Tse GMK, Stelling CB. Sonographic features of primary breast cancer in men. *AJR Am J Roentgenol* 2001;176:413–6.
- [20] Flynn LW, Park J, Patil SM, Cody 3rd HS, Port ER. Sentinel lymph node biopsy is successful and accurate in male breast carcinoma. *J Am Coll Surg* 2008;206:616–21.
- [21] Morakkabati-Spitz N, Schild HH, Leutner CC, von Falkenhäusen M, Lutterbey GT, Kuhl CK. Dynamic contrast-enhanced breast MR imaging in men: preliminary results. *Radiology* 2006;238:438–45.
- [22] Munn S. When should men undergo mammography? *AJR Am J Roentgenol* 2002;178:1419–20.