



ORIGINAL ARTICLE

# Anterior cervical discectomy versus posterior keyhole foraminotomy in cervical radiculopathy

Wael M. Moussa \*

Department of Neurosurgery, Faculty of Medicine, Alexandria University, Egypt

Received 21 February 2012; accepted 21 April 2012

Available online 21 July 2012

## KEYWORDS

Cervical;  
Discectomy;  
Keyhole foraminotomy

**Abstract Introduction:** Cervical disc prolapse is a common disorder that results in spinal cord compression causing myelopathy or nerve root compression causing radiculopathy or both. For a posterolateral cervical disc prolapse causing radiculopathy, the common surgical approach used nowadays is the anterior approach to the cervical column. However, this is associated with many complications; some of them are devastating for example, carotid artery injury and cord injury. Therefore, the use of a simpler approach for the posterolateral disc prolapse is needed. The posterior approach making a keyhole foraminotomy is simpler.

**Aim of the work:** The aim of this work was to evaluate the role of posterior keyhole foraminotomy for the treatment of cervical radiculopathy caused by posterolateral cervical disc prolapse as compared to the anterior approach for cervical discectomy.

**Methods:** A retrospective study included 20 patients diagnosed with posterolateral cervical disc prolapse causing radiculopathy and they were divided into two groups each composed of 10 patients, group (1) had cervical anterior discectomy and group (2) had posterior cervical keyhole foraminotomy.

**Results:** Cervical posterior keyhole foraminotomy (group (2)) had much better results than the cervical anterior discectomy (group (1)). The duration of surgery was shorter in group (2) than in group (1). Also, the postoperative complications including dysphagia, hemiparesis and myelopathy were present only in group (1). The postoperative improvement was better in group (2) than in group (1) and the postoperative hospital stay was shorter in group (2) than in group (1).

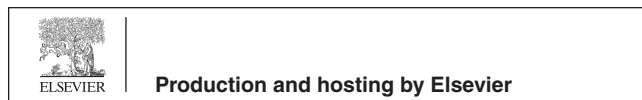
**Conclusion:** As compared to cervical anterior discectomy, cervical posterior keyhole foraminotomy is a safe and effective approach for surgical treatment of posterolateral cervical disc prolapse causing nerve root compression resulting in brachialgia. Cervical keyhole foraminotomy has a shorter duration of surgery, less incidence of complications, less duration of postoperative hospital stay and a better improvement in symptoms.

© 2012 Alexandria University Faculty of Medicine. Production and hosting by Elsevier B.V. All rights reserved.

\* Tel.: +20 1001156408.

E-mail address: waelmossa@yahoo.com

Peer review under responsibility of Alexandria University Faculty of Medicine.



## 1. Introduction

Cervical disc prolapse is a common disorder that may compress the spinal cord causing myelopathy or the nerve root causing radiculopathy.<sup>1-3</sup> Common current surgical practice for cervical disc prolapse causing radiculopathy is to remove the prolapsed disc through an anterior cervical approach with or without insertion of a graft at the site of the removed disc.<sup>4-6</sup> Anterior cervical discectomy with or without fusion has been commonly used for cervical disc disease since the description by Smith and Robinson in 1958.<sup>7-9</sup>

Anterior approach has many disadvantages. The trajectory to the anterior cervical spine has many important structures, such as the carotid arteries, the oesophagus and the recurrent laryngeal nerves, injury to any of them can cause devastating complications.<sup>10-12</sup>

Posterior approach has emerged as a better alternative to the anterior approach for the treatment of cervical radiculopathy caused by posterolateral cervical disc prolapse.<sup>13-15</sup> The approach is easier with no vital structures in the trajectory to the cervical lamina. It takes less time and is less expensive because it does not require any artificial grafts during the surgery.<sup>16-19</sup>

## 2. Aim of the work

The aim of this work was to evaluate the role of posterior keyhole foraminotomy for the treatment of cervical radiculopathy caused by posterolateral cervical disc prolapse as compared to the anterior approach for cervical discectomy.

## 3. Patients and methods

This was a retrospective study; the data were collected from the archive of patients' data. This study included 20 patients presented with brachialgia caused by cervical disc prolapse.

The patients were divided into two groups:

Group (1): Ten patients who had anterior cervical discectomy.

Group (2): Ten patients who had posterior keyhole foraminotomy.

*Preoperatively*, patients were submitted to the following:

Complete history-taking.

Complete general and neurological examination.

Investigations in the form of:

Laboratory investigations.

Radiological investigations, in the form of plain X-ray and magnetic resonance imaging of the cervical spine.

*Intraoperatively*, 10 patients had anterior cervical discectomy and the other ten patients had posterior cervical keyhole foraminotomy. The C-arm was used as a guide to the correct cervical level in all cases of cervical anterior discectomy but was used in some cases of cervical posterior keyhole foraminotomy according to surgeon's preference. In these cases, identification of the correct level was done by counting the spinous processes starting from C2 spinous process downwards and the

level was later confirmed by finding the prolapsed disc that coincides with the MRI findings. The keyhole foraminotomy was done by removing part of the lamina above the prolapsed disc and part of the lamina below the prolapsed disc and widening of the neural foramen of the root using a Kerrison exposing an ample part of the nerve root. The nerve root was then retracted from its axilla, pushing it upwards thus exposing the prolapsed disc, which was then removed using a No. 11 scalpel and a small rongeur.

For cervical anterior discectomy group, insertion of a graft (an autograft from the iliac crest or a synthetic cage graft) at the site of the discectomy was done according to surgeon's preference

*Postoperatively*, patients were followed clinically for up to six months and radiological follow-up was done when indicated.

The confidentiality of the patients was kept and ethical concerns were met.

### 3.1. Statistical analysis

Data were presented as numbers and percentages.

## 4. Results

The most common age group was 18–30 years in both cervical anterior discectomy and cervical keyhole foraminotomy groups and the incidence of patients decreased with advancing age. This was shown in Table 1.

As regards the sex of patients, in both patients' groups, males were more common than females as shown in Table 2.

The most common level of cervical disc prolapse was C5–6 (60% in cervical anterior discectomy group and 50% in cervical keyhole foraminotomy group) followed by C4–5 and finally by C6–7. This was shown in Table 3.

Single cervical level disc prolapse (Figs. 1 and 2) was the most common finding as regards the number of levels prolapsed followed by two levels of prolapse and then by three levels of prolapse as shown in Table 4.

The average duration of surgery significantly increased in cervical anterior discectomy group as compared to the cervical keyhole foraminotomy group. Thirty percent of cervical keyhole foraminotomy group had a surgical duration of less than 1 h while none of the cervical anterior discectomy group had this duration. This was shown in Table 5.

As regards the postoperative complications, they were significantly more frequent and more serious in the cervical anterior discectomy group than the cervical keyhole foraminotomy group. None of the cervical keyhole foraminotomy group patients had infection, dysphagia, myelopathy or hemiparesis postoperatively as shown in Table 6.

Postoperative improvement of brachialgia was more pronounced in cervical keyhole foraminotomy group which had a 70% excellent category as compared to 40% excellent category in cervical anterior discectomy group patients as shown in Table 7.

The postoperative hospital stay was significantly shorter in cervical posterior foraminotomy group (70% less than two days) than the cervical anterior discectomy group (40% less than two days) as shown in Table 8.

**Table 1** Age of the patients under study.

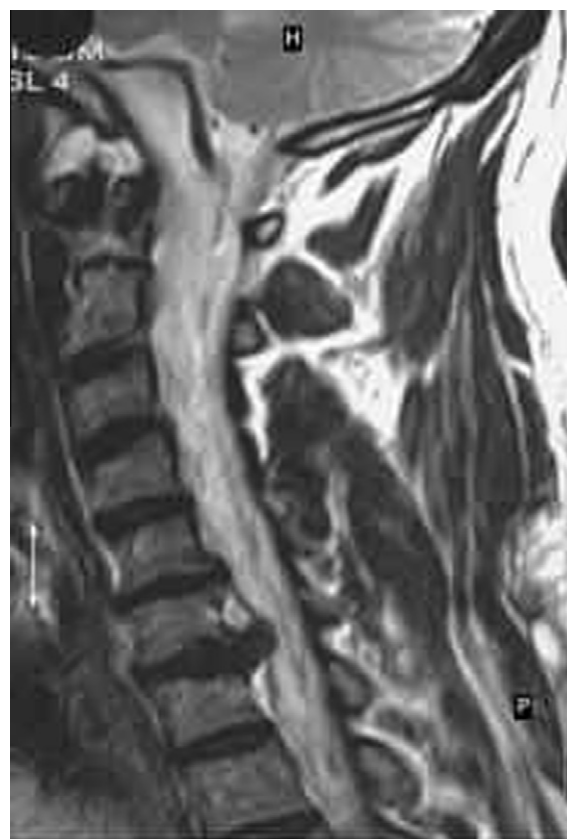Age category of patients (years)	Cervical anterior group		Cervical keyhole foraminotomy	
	No.	%	No.	%
18–30	6	60	5	50
30–45	3	30	3	30
45–60	1	10	2	20
Total	10	100	10	100

**Table 2** Sex of patients under study.

Sex	Cervical anterior group		Cervical keyhole foraminotomy	
	No.	%	No.	%
Males	7	70	6	60
Females	3	30	4	40
Total	10	100	10	100

**Table 3** Level of cervical discectomy.

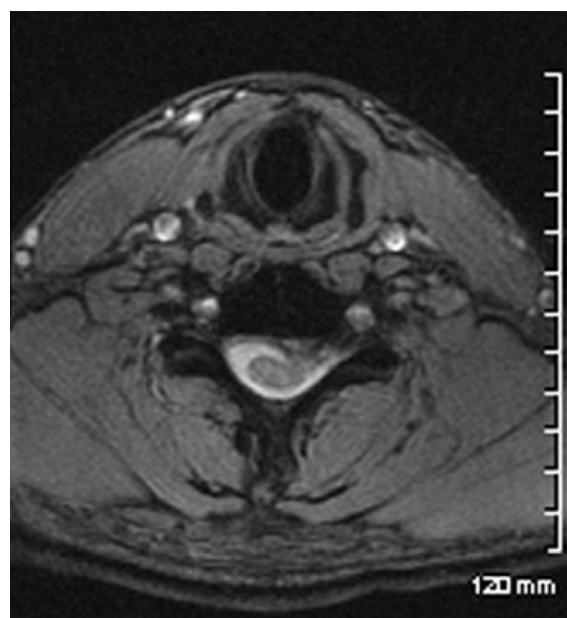
Level of cervical disc prolapse	Cervical anterior discectomy		Cervical keyhole foraminotomy	
	No.	%	No.	%
C4–5	3	30	3	30
C5–6	6	60	5	50
C6–7	1	10	2	20
Total	10	100	10	100

**Figure 1** Preoperative MRI of the cervical spine, T2-weighted image, sagittal section showing a posterolaterally prolapsed C6–7 disc.

## 5. Discussion

Cervical disc prolapse causing brachialgia is a common clinical diagnosis.<sup>20,21</sup> Conservative treatment is advocated as a first line therapy. If the patient did not respond to medical treatment, surgical treatment is advocated.<sup>22–24</sup> Cervical anterior discectomy has been and is still the commonest approach to excise the prolapsed cervical disc causing nerve root compression manifesting clinically as brachialgia.<sup>25–27</sup> This may or may not be associated with insertion of a graft.<sup>28,29</sup> However, because of the important anatomical structures encountered in this approach, many complications; some of them are devastating, were reported.<sup>30–32</sup> These include oesophageal injury causing fistula formation or mediastinitis which could be fatal, carotid artery injury causing extensive bleeding or brain infarction, recurrent laryngeal nerve injury and spinal cord injury.<sup>33–35</sup> This redirected the attention to the posterior cervical approach as a simpler approach for discectomy of the posterolateral cervical disc prolapse to relieve brachialgia.<sup>36,37</sup>

This study included 20 patients complaining of brachialgia caused by posterolateral cervical disc prolapse causing compression of the nerve root and not responding to conservative treatment. They were divided into two groups each included 10 patients: group (1) was operated by the cervical anterior approach and group (2) was operated using the cervical poster-

**Figure 2** A preoperative axial MRI, T2-weighted image of the cervical spine, showing a left posterolateral disc prolapse of the C4–5 disc.

**Table 4** Number of levels operated.

Number of levels operated	Cervical anterior discectomy		Cervical keyhole foraminotomy	
	No.	%	No.	%
Single level	7	70	6	60
Two levels	2	20	3	30
Three levels	1	10	1	10
Total	10	100	10	100

**Table 5** Average duration of surgery.

Average duration of surgery in hours	Cervical anterior discectomy		Cervical keyhole foraminotomy	
	No.	%	No.	%
Less than one hour	0	0	3	30
One to two hours	3	30	6	60
More than two hours	7	70	1	10
Total	10	100	10	100

**Table 6** Postoperative complications.

Postoperative complication	Cervical anterior discectomy (n = 10)		Cervical keyhole foraminotomy (n = 10)	
	No.	%	No.	%
Infection	1	10	0	0
Neck pain after one month of surgery	4	40	2	20
Dysphagia	3	30	0	0
Myelopathy	2	20	0	0
Hemiparesis	1	10	0	0

**Table 7** Postoperative improvement of brachialgia.

Extent of postoperative improvement	Cervical anterior discectomy		Cervical keyhole foraminotomy	
	No.	%	No.	%
Excellent	4	40	7	70
Good	2	20	2	20
Fair	3	30	1	10
Poor	1	10	0	0
Total	10	100	10	100

**Table 8** Duration of postoperative hospital stay.

Duration of postoperative hospital stay in days	Cervical anterior discectomy		Cervical keyhole foraminotomy	
	No.	%	No.	%
Less than two days	4	40	7	70
From two to four days	4	40	2	20
More than four days	2	20	1	10
Total	10	100	10	100

ior keyhole foraminotomy approach. Young age group was predominant in our study constituting 60% in group (1) and 50% in group (2) (Table 1). This may be because soft disc prolapse causing posterolateral root compression is commoner in young age group.<sup>38,39</sup> C5–6 disc prolapse was the commonest in both groups (60% in group (1), and 50% in group (2)) which was in agreement with the literature as regards the commonest cervical disc prolapse level in the population<sup>40</sup> (Table 3).

Single level cervical disc prolapse was the commonest (70% in group (1) and 60% in group (2)) followed by two levels and then three levels disc prolapse (Table 4). This also was in agreement with statistics in the general population.<sup>41</sup> As regards the duration of surgery, there was a significantly lower duration of surgery in group (2) than those in group (1). Surgical duration of less than 1 h was recorded in 60% of cases of group (2) which was not recorded in group (1). One to two hours duration of surgery was present in 30% of cases in group (1) and 60% of cases in group (2), while 70% of cases in group (1) had more than 2 h surgery as compared to 10% of cases in group (2) (Table 5). This significantly shorter operative duration in cervical posterior foraminotomy as compared to cervical anterior discectomy is probably due to the shorter trajectory with the absence of significant anatomical structures that required careful dissection and the constant use of the C-arm in all cervical anterior discectomy cases as compared to the infrequent use of the C-arm in the cervical foraminotomy cases. This was in agreement with the results of most other authors.<sup>42</sup>

As regards the postoperative complications, they were significantly fewer in the cervical keyhole foraminotomy cases as compared to the anterior approach cases. The only complication was neck pain in 20% of cases that resolved after six months of surgery. Otherwise, it was reported that the cervical anterior discectomy had 10% infection rate, 40% neck pain, 30% dysphagia, 20% myelopathy and 10% hemiparesis (Table 6). The increased infection rate could be due to the longer operative time. The dysphagia due to oesophageal retraction and the myelopathy was probably due to a tight cervical canal in these two cases causing cord trauma. However, these were temporary and resolved completely after three months of surgery. Excessive retraction on the carotid arteries was probably the cause of infarction causing hemiparesis that improved completely in one case and partially in the other. These results were in agreement to the results of other authors.<sup>43</sup>

Again, the improvement in brachialgia in group (2) was better than those in group (1). Seventy percent of patients in group (2) had excellent improvement of brachialgia as compared to 40% in group (1). Forty percent of cases in group (1) had fair or poor improvement as compared to only 10% in group (2) (Table 7). The better improvement in brachialgia in cervical keyhole foraminotomy approach as compared to cervical anterior discectomy was reported by other authors.<sup>18,22,44</sup>

Cervical keyhole foraminotomy cases (group (2)) had a shorter postoperative hospital stay than cervical anterior discectomy cases (group (1)). Seventy percent of group (2) had postoperative hospital stay less than two days as compared to 40% in group (1). Sixty percent of cases in group (1) stayed at hospital postoperatively for more than two days as compared to 30% of cases in group (2) (Table 8). This difference

in the length of postoperative hospital stay was also reported by other authors.<sup>15,22,35</sup>

From this study we concluded that the cervical posterior keyhole foraminotomy is safer and a more effective approach for surgical treatment of posterolateral cervical disc prolapse causing nerve root compression resulting in brachialgia than the cervical anterior discectomy. Cervical keyhole foraminotomy had a shorter duration of surgery, less incidence of complications, less duration of postoperative hospital stay and a better improvement in symptoms. We recommend the use of cervical posterior keyhole foraminotomy approach as the first choice in cases of posterolateral cervical disc prolapse causing brachialgia.

## References

- Davis RA. A long-term outcome study of 170 surgically treated patients with compressive cervical radiculopathy. *Surg Neurol* 1996;**46**(6):523–30, 530–3.
- Woertgen C. Prognostic factors of posterior cervical disc surgery: a prospective, consecutive study of 54 patients. *Neurosurgery* 1997;**40**(4):724–8.
- Silveri CP. Cervical disk disease and the keyhole foraminotomy: proven efficacy at extended long-term follow up. *Orthopedics* 1997;**20**(8):687–92.
- Kumar GR, Maurice-Williams RS, Bradford R. Cervical foraminotomy: an effective treatment for cervical spondylotic radiculopathy. *Br J Neurosurg* 1998;**12**(6):563–8.
- An HS. Spinal disorders at the cervicothoracic junction. *Spine* 1994;**19**(22):2557–64.
- Baba H. Laminoplasty with foraminotomy for coexisting cervical myelopathy and unilateral radiculopathy: a preliminary report. *Spine* 1996;**21**(2):196–202.
- Baba H. Laminoplasty following anterior cervical fusion for spondylotic myeloradiculopathy. *Int Orthop* 1994;**18**(1):1–5.
- Burke TG, Caputy A. Microendoscopic posterior cervical foraminotomy: a cadaveric model and clinical application for cervical radiculopathy. *J Neurosurg* 2000;**93**:126–9.
- Debois V. Soft cervical disc herniation. Influence of cervical spinal canal measurements on development of neurologic symptoms. *Spine* 1999;**24**(19):1996–2002.
- Ebraheim NA. The projection of the cervical disc and uncinat process on the posterior aspect of the cervical spine. *Surg Neurol* 1999;**51**(4):363–7.
- Grieve JP. Results of posterior cervical foraminotomy for treatment of cervical spondylitic radiculopathy. *Br J Neurosurg* 2000;**14**(1):40–3.
- Grundy PL, Germon TJ, Gill SS. Transpedicular approaches to cervical uncovertebral osteophytes causing radiculopathy. *J Neurosurg* 2000;**93**(Suppl. 1):21–7.
- Koshu K, Tominaga T, Yoshimoto T. Spinous process-splitting laminoplasty with an extended foraminotomy for cervical myelopathy. *Neurosurgery* 1995;**37**(3):430–4.
- Roh SW. Endoscopic foraminotomy using MED system in cadaveric specimens. *Spine* 2000;**25**(2):260–4.
- Snow RB, Weiner H. Cervical laminectomy and foraminotomy as surgical treatment of cervical spondylosis: a follow-up study with analysis of failures. *J Spinal Disord* 1993;**6**(3):245–50.
- Tan LC. Medial cervical facetectomy for radiculopathy due to foraminal stenosis: 71 personal consecutive cases. *J Clin Neurosci* 1999;**6**(3):207–11.
- Tanaka N et al. The anatomic relation among the nerve roots, intervertebral foramina, and intervertebral discs of the cervical spine. *Spine* 2000;**25**(3):286–91.
- Ullman JS, Camins MB, Post KD. Complications of cervical disk surgery. *Mt Sinai J Med* 1994;**61**(3):276–9.
- Wirth FP. Cervical discectomy. A prospective analysis of three operative techniques. *Surg Neurol* 2000;**53**(4):340–6.
- Woertgen C. Long term outcome after cervical foraminotomy. *J Clin Neurosci* 2000;**7**(4):312–5.
- Çağlar YŞ, Bozkurt M, Kahilogullari G, Tuna H, Bakir A, Torun F, et al. Keyhole approach for posterior cervical discectomy: experience on 84 patients. *Minim Invasive Neurosurg* 2007;**50**(1):7–11.
- Parker WD. Cervical laminoforaminotomy. *J Neurosurg* 2002;**96**(Suppl. 2):254–61.
- Heary RF, Ryken TC, Matz PG, Anderson PA, Groff MW, Holly LT, et al. Resnick DK; Cervical laminoforaminotomy for the treatment of cervical degenerative radiculopathy. *J Neurosurg Spine* 2009;**11**(2):198–202.
- Adamson TE. The impact of minimally invasive cervical spine surgery. Invited submission from the Joint Section Meeting on Disorders of the Spine and Peripheral Nerves, March 2004. *J Neurosurg Spine* 2004;**1**:43–6.
- Burke TG, Caputy A. Microendoscopic posterior cervical foraminotomy: a cadaveric model and clinical application for cervical radiculopathy. *J Neurosurg* 2000;**93**:126–9.
- Chang JC, Park HK, Bea HG, Cho SJ, Choi SK, Byun PJ. Morphometric measurement of the anatomical landmark in anterior cervical microforaminotomy. *J Korean Neurosurg Soc* 2006;**39**:340–6.
- Chen BH, Natarajan RN, An HS, Andersson GB. Comparison of biomechanical response to surgical procedures used for cervical radiculopathy: posterior keyhole foraminotomy versus anterior foraminotomy and discectomy versus anterior discectomy with fusion. *J Spinal Disord* 2001;**14**:17–20.
- Clarke MJ, Ecker RD, Krauss WE, McClelland RL, Dekutoski MB. Same-segment and adjacent-segment disease following posterior cervical foraminotomy. *J Neurosurg Spine* 2007;**6**:5–9.
- Fehlings MG, Gray RJ. Posterior cervical foraminotomy for the treatment of cervical radiculopathy. *J Neurosurg Spine* 2009;**10**:343–4.
- Fessler RG, Khoo LT. Minimally invasive cervical microendoscopic foraminotomy: an initial clinical experience. *Neurosurgery* 2002;**51**:S37–45.
- Gala VC, O'Toole JE, Voyadzis JM, Fessler RG. Posterior minimally invasive approaches for the cervical spine. *Orthop Clin North Am* 2007;**38**:339–49.
- Grieve JP, Kitchen ND, Moore AJ, Marsh HT. Results of posterior cervical foraminotomy for treatment of cervical spondylitic radiculopathy. *Br J Neurosurg* 2000;**14**:40–3.
- Hilton Jr DL. Minimally invasive tubular access for posterior cervical foraminotomy with three-dimensional microscopic visualization and localization with anterior/posterior imaging. *Spine J* 2007;**7**:154–8.
- Hosono N, Yonenobu K, Ono K. Neck and shoulder pain after laminoplasty. A noticeable complication. *Spine* 1996;**21**:1969–73.
- Ishihara H, Kanamori M, Kawaguchi Y, Nakamura H, Kimura T. Adjacent segment disease after anterior cervical interbody fusion. *Spine J* 2004;**4**:624–8.
- Jagannathan J, Sherman JH, Szabo T, Shaffrey CI, Jane JA. The posterior cervical foraminotomy in the treatment of cervical disc/osteophyte disease: a single-surgeon experience with a minimum of 5 years' clinical and radiographic follow-up. *J Neurosurg Spine* 2009;**10**:347–56.
- Krupp W, Schattke H, Mücke R. Clinical results of the foraminotomy as described by Frykholm for the treatment of lateral cervical disc herniation. *Acta Neurochir (Wien)* 1990;**107**:22–9.
- O'Toole JE, Eichholz KM, Fessler RG. Minimally invasive cervical foraminotomy and decompression of stenosis. In: Scuderi GR, Tria AJ, editors. *Minimally invasive surgery in orthopedics*. New York: Springer; 2009. p. 561–8.
- Ratliff JK, Cooper PR. Cervical laminoplasty: a critical review. *J Neurosurg* 2003;**98**:230–8.

40. Roh SW, Kim DH, Cardoso AC, Fessler RG. Endoscopic foraminotomy using MED system in cadaveric specimens. *Spine* 2000;**25**:260–4.
41. Ruetten S, Komp M, Merk H, Godolias G. Full-endoscopic cervical posterior foraminotomy for the operation of lateral disc herniations using 5.9-mm endoscopes: a prospective, randomized, controlled study. *Spine* 2008;**33**:940–8.
42. Saringer WF, Reddy B, Nobauer-Huhmann I, Regatschnig R, Reddy M, Tschabitscher M, et al. Endoscopic anterior cervical foraminotomy for unilateral radiculopathy: anatomical morphometric analysis and preliminary clinical experience. *J Neurosurg* 2003;**98**:171–80.
43. Tumialán LM, Ponton RP, Gluf WM. Management of unilateral cervical radiculopathy in the military: the cost effectiveness of posterior cervical foraminotomy compared with anterior cervical discectomy and fusion. *Neurosurg Focus* 2010;**28**:E17.
44. Zdeblick TA, Zou D, Warden KE, McCabe R, Kunz D, Vanderby R. Cervical stability after foraminotomy. A biomechanical in vitro analysis. *J Bone Joint Surg Am* 1992;**74**:22–7.