


Available online at www.sciencedirect.com

ScienceDirect

journal homepage: <http://www.pediatr-neonol.com>

ORIGINAL ARTICLE

Effects of Domperidone on QT Interval in Children with Gastroesophageal Reflux Disease



Thitima Ngoenmak^{a,b}, Suporn Treepongkaruna^a,
Yuthapong Buddharaksa^b, Anant Khositseth^{a,*}

^a Department of Pediatrics, Faculty of Medicine, Ramathibodi Hospital, Mahidol University, Bangkok 10400, Thailand

^b Department of Pediatrics, Faculty of Medicine, Naresuan University, Phitsanulok 65000, Thailand

Received Nov 11, 2014; received in revised form Jan 24, 2015; accepted Mar 20, 2015

Available online 4 June 2015

Key Words

children;
domperidone;
gastroesophageal
reflux disease;
QT interval

Background: Domperidone has been widely used in children with gastroesophageal reflux disease (GERD). Studies on the effects of domperidone on corrected QT interval (QTc) in young children are limited. Our aim was to study the effect of domperidone on the repolarization abnormalities assessed by electrocardiogram (ECG) in young children.

Methods: ECG was performed in children <2 years of age before and after taking domperidone orally 0.3 mg/kg three times/day for at least a 1 week period. Each ECG was reviewed and QT, RR, and T_{peak} to T_{end} intervals (TpTe) were measured to calculate the QTc and TpTe/QT ratio.

Results: A total of 22 patients (12 male) with a median age of 8.5 months (1–24 months) were enrolled. Most patients (59.1%) were under 1 year of age. The median baseline QTc (410 milliseconds, 350–450 milliseconds) was not significantly different from the QTc after taking domperidone (410 milliseconds, 320–560 milliseconds), $p = 0.159$. Only two patients showed a QTc increase ≥ 450 milliseconds. The baseline TpTe interval and TpTe/QT (105 milliseconds, 60–170 milliseconds and 0.27 milliseconds, 0.15–0.43 milliseconds) were significantly greater than the TpTe interval and TpTe/QT in children after taking domperidone (90 milliseconds, 60–140 milliseconds and 0.22 milliseconds, 0.15–0.29 milliseconds), $p = 0.001$ and 0.004, respectively.

Conclusions: Our data demonstrate that domperidone treatment over a short-term period in children <2 years of age did not lengthen QTc significantly; however, QTc increased ≥ 450 milliseconds in two patients with concomitant lansoprazole. Routine baseline and follow-up ECG may not be necessary in each individual case receiving only domperidone.

Copyright © 2016, Taiwan Pediatric Association. Published by Elsevier Taiwan LLC. This is an open access article under the CC BY-NC-ND license (<http://creativecommons.org/licenses/by-nc-nd/4.0/>).

* Corresponding author. Department of Pediatrics, Faculty of Medicine, Ramathibodi Hospital, Mahidol University, 270 Rama VI Road Ratchathewi, Bangkok 10400, Thailand.

E-mail address: anant.kho@mahidol.ac.th (A. Khositseth).

<http://dx.doi.org/10.1016/j.pedneo.2015.03.015>

1875-9572/Copyright © 2016, Taiwan Pediatric Association. Published by Elsevier Taiwan LLC. This is an open access article under the CC BY-NC-ND license (<http://creativecommons.org/licenses/by-nc-nd/4.0/>).

1. Introduction

Domperidone is a dopamine-2 receptor antagonist^{1–3} and affects the chemoreceptor trigger zone on the fourth ventricle outside the blood brain barrier and the motor function of the stomach and small intestine. In contrast to metoclopramide, domperidone does not cross the blood brain barrier; therefore, neurological side effects such as dystonic reaction are rare. Domperidone is broadly prescribed for acute vomiting, gastroparesis and gastroesophageal reflux disease (GERD), since its safety profiles are more acceptable than metoclopramide and cisapride. The study of domperidone treatment at the dose of 0.3 mg/kg/dose in 13 newborns demonstrated no serious side effects.² However, Rocha and Barbosa⁴ reported a QT prolongation in a 4-month-old infant receiving a high dose of 0.6 mg/kg three times/day. In addition, domperidone caused QT prolongation in patients who received concomitant treatment with ketoconazole.⁵ There were few research studies of the side effects on electrocardiogram (ECG) in children and the results were controversial. Djeddi et al⁶ reported QT prolongation in 31 infants with gastroesophageal reflux treated with domperidone. The study by Günlemez et al⁷ showed no difference of corrected QT before and after domperidone therapy in 40 premature infants, except for two babies who developed corrected QT interval (QTc) prolongation. The aim of our study was to determine the cardiac effect of short-term oral domperidone on the repolarization abnormalities assessed by measuring QTc and T_{peak} to T_{end} (TpTe) interval on ECG.

2. Patients and methods

Children who were aged <2 years with suspected symptoms of GERD and who required domperidone therapy at a single university hospital were enrolled. Informed consent was obtained from the parents of all patients before enrolment. Domperidone was given at the dose of 0.3 mg/kg before meals three times/day. A 12-lead ECG using paper speed at 25 mm/s or 50 mm/s was obtained in each child at baseline before starting domperidone and at 1 week following domperidone administration. All ECGs were performed without sedation, but all children lay calmly in their mothers' laps or on beds in a nonagitated state.

2.1. Measurements and calculations

Each ECG was reviewed by a pediatric cardiologist (YB) blinded to the clinical setting. The QT interval, defined as the interval from the beginning of the Q wave to the end of the T wave, the RR interval, defined as the interval from the preceding R wave to the consecutive R wave, and the TpTe interval, defined as the interval from the peak of the T wave to the end of the T wave, were measured in lead II.

The QTc was calculated from Bazett's formula⁸ as the QT interval in seconds divided by the square root of the RR interval in seconds. The prolonged QTc was defined as QTc >440 milliseconds for infants <1 year of age and >450 milliseconds for children aged 1–5 years.⁹ The normal TpTe interval was 62.4 ± 11 milliseconds (39–97 milliseconds) for children <1 year of age and 67.6 ± 9.2 milliseconds (43–89

milliseconds) for children aged 1–5 years.¹⁰ The prolonged TpTe interval was defined as TpTe/QT > 0.21.¹⁰ QTc, TpTe interval, and TpTe/QT were compared between, before, and after taking domperidone. Potential factors influencing the effects, such as age, dosage, pre-existing disease, and concomitant medicines, were also evaluated.

2.2. Statistical analysis

Descriptive statistics were calculated and analyzed to express mean, standard deviation (SD), median, range, maximum and minimum value, frequency, percentage, and distribution. Multiple logistic regressions and the Mann-Whitney test were used to find the risk factors related to an abnormal ECG.

3. Results

Twenty-two patients (12 male, 54.6%) with symptoms suspected of GERD were enrolled. The median age was 8.5 months (range 1–24 months) and median weight of 6.3 kg (range 3.2–13.8 kg). Most patients (59.1%) were <1 year old. Concomitant medications consisted of lansoprazole, phenobarbital, vigabatrin, nitrazepam, and vitamins. Seventeen patients received lansoprazole while five patients did not receive this medication. The associated diseases consisted of epilepsy, heart disease, thyrotoxinemia, iron deficiency anemia, cerebral palsy, and hepatitis (Table 1).

The median baseline QTc before taking domperidone was 410 milliseconds (range 350–450 milliseconds). The median QTc after taking domperidone was 410 milliseconds (range 320–450 milliseconds), which was not significantly different from the baseline ($p = 0.159$). At baseline, only one patient had a QTc of 450 milliseconds. After taking domperidone, her QTc decreased to 400 milliseconds. When the QTc at baseline and after domperidone therapy was compared in each individual patient, an increase from the baseline was seen in eight patients (36%), but only two patients showed an increase in QTc ≥450 milliseconds (Figure 1). Two had a baseline QTc of 420 milliseconds and 440 milliseconds, and after domperidone their QTc increased to 450 milliseconds (Figure 2). Subgroup analysis demonstrated that no factors were associated with increased QTc ≥ 450 milliseconds, including age, sex, pre-existing disease, and concomitant medicines. Interestingly, two out of 17 patients receiving lansoprazole showed QTc ≥450 milliseconds after domperidone therapy. In

Table 1 Underlying diseases and concomitant medications.

Underlying diseases	N (%)	Medications	N (%)
Seizure	1 (7.14)	Lansoprazole	17 (62.96)
Thyroid disease	1 (7.14)	Phenobarbital	2 (7.4)
Iron deficiency	2 (14.29)	Vigabatrin	1 (3.7)
Chronic liver disease	1 (7.14)	Nitrazepam	1 (3.7)
Heart disease	2 (14.29)	Multivitamin	6 (22.22)
Cerebral palsy	7 (50.0)		

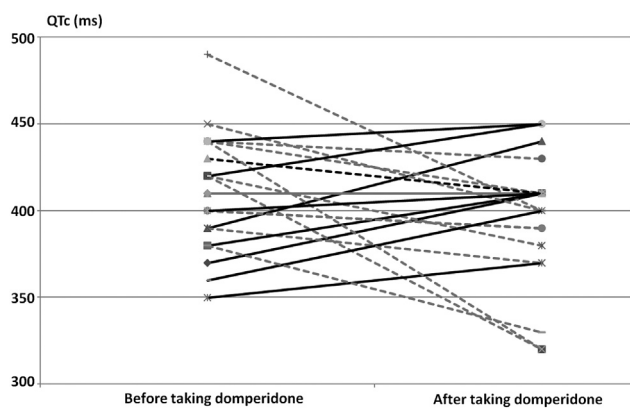


Figure 1 Linear graph comparing corrected QT interval (QTc) in milliseconds before and after taking domperidone in each patient.

contrast, none of the five patients without lansoprazole had QTc ≥ 450 milliseconds after domperidone therapy.

The median baseline TpTe interval and TpTe/QT before taking domperidone were 105 milliseconds (range 60–170 milliseconds) and 0.27 milliseconds (range 0.15–0.43

milliseconds), respectively. Interestingly, the median TpTe interval and TpTe/QT after taking domperidone were 90 milliseconds (range 60–140 milliseconds) and 0.22 milliseconds (range 0.15–0.34 milliseconds), which were significantly less than before taking domperidone, $p = 0.001$ and 0.004 , respectively. The TpTe interval (Figure 3) and TpTe/QT (Figure 4) decreased after taking domperidone in most patients.

4. Discussion

Currently, domperidone is widely prescribed for children < 2 years old with GERD. Although proton pump inhibitors are the treatment of choice for GERD in children, prokinetics may be of benefit to some patients who do not have an adequate therapeutic response to proton pump inhibitors. When prokinetics are indicated, domperidone is preferred, due to an awareness of the side effects of the others. Rocha and Barbosa⁴ reported prolongation of the QT interval after oral use of high-dose domperidone in a 4-month-old infant, which was normalized after discontinuation. The authors recommended obtaining 12 ECGs both before and after taking domperidone. Djeddi et al⁶

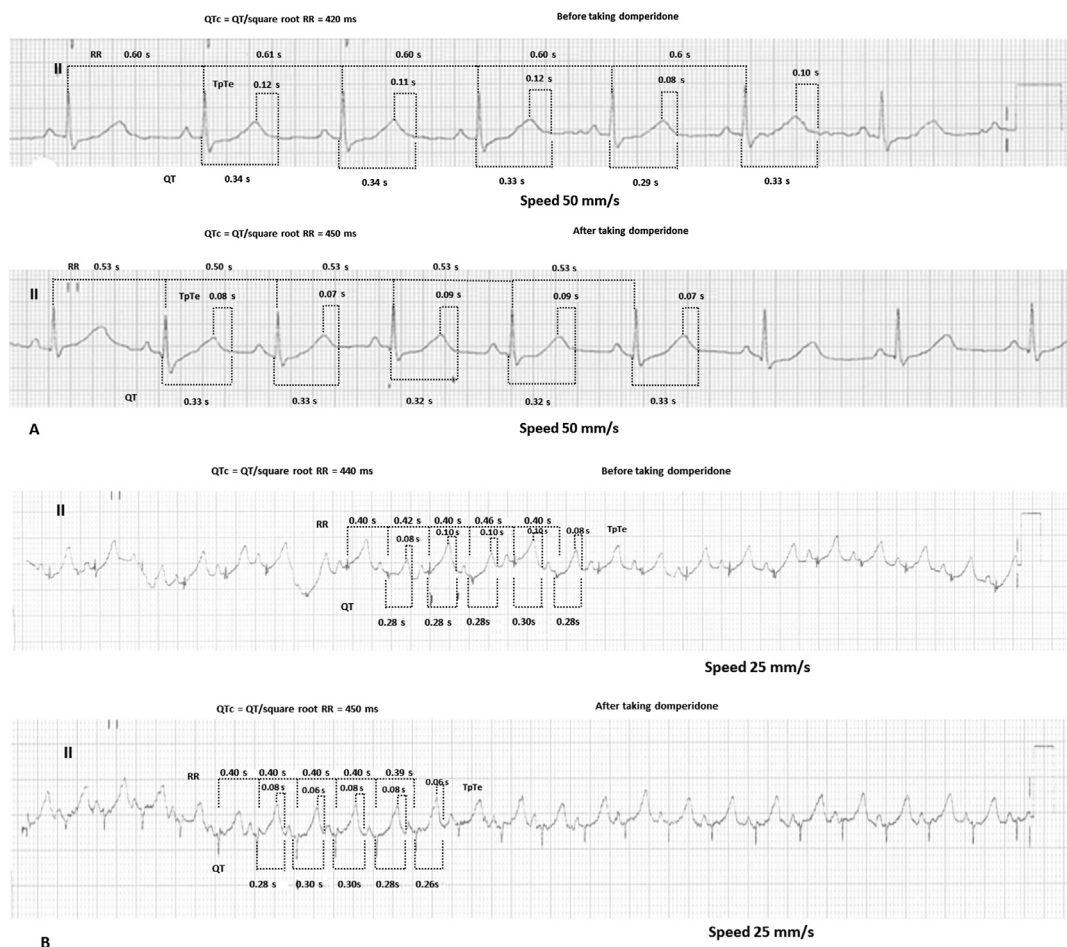


Figure 2 Electrocardiogram tracing showing measurement of T_{peak} to T_{end} (TpTe), QT, and RR interval in lead II. (A) One patient with corrected QT interval (QTc) increased from 420 milliseconds to 450 milliseconds; (B) one patient with QTc increased from 440 milliseconds to 450 milliseconds.

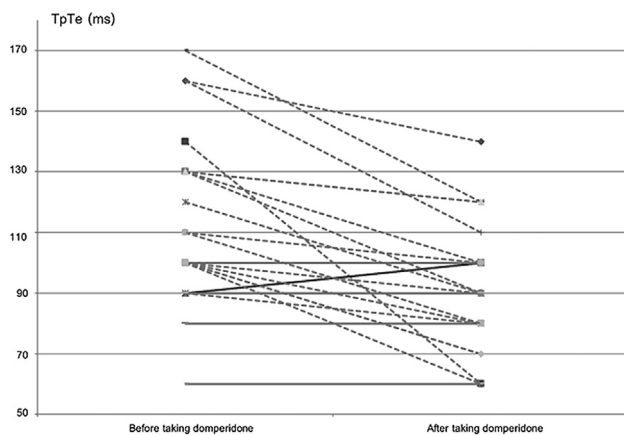


Figure 3 Linear graph comparing T_{peak} to T_{end} interval (TpTe) in milliseconds before and after taking domperidone in each patient.

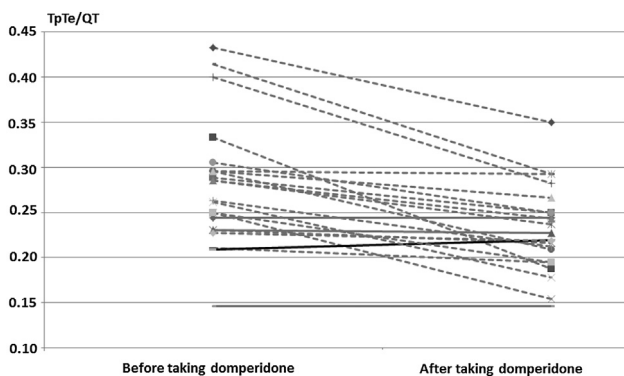


Figure 4 Linear graph comparing T_{peak} to T_{end} interval/QT interval ratio (TpTe/QT) before and after taking domperidone in each patient.

reported that QTc increased more than 12 milliseconds in 48% of 31 infants treated with domperidone. The risk factors for domperidone-induced QTc prolongation identified in this study were advanced gestational age and hyperkalemia. Günlemez et al⁷ demonstrated that domperidone therapy in modest doses (0.25 mg/kg four times/day) in premature infants was safe except in two out of 40 infants who developed QTc prolongation above 450 milliseconds without clinical arrhythmia. The potential risk factors were inconclusive. In our cohort study on the effect of short-term oral domperidone, QTc after taking domperidone was not significantly different from baseline QTc before taking domperidone. However, eight of 22 patients (36%) receiving domperidone had increased QTc, although the percentage increase of QTc in most cases was small and the QTc interval was <450 milliseconds in most patients (20/22, 91%). Only two of 22 patients (9%) had QTc \geq 450 milliseconds after taking domperidone, increasing from 420 milliseconds and 440 milliseconds to 450 milliseconds, respectively. Interestingly, both patients had concomitant lansoprazole therapy. The ratio of patients developing QTc \geq 450 milliseconds was not significantly different between patients with and without lansoprazole therapy. This might be due to the small number of patients without

lansoprazole therapy. Nevertheless, these findings may also indicate that domperidone could have some cardiac effects in some selected patients and caution should be exercised especially with concomitant use of lansoprazole.

The TpTe interval is an index of transmural dispersion of repolarization and spatial dispersion of repolarization index. Prolongation of this interval has been reported to predispose to life-threatening ventricular arrhythmias in long QT syndrome, polymorphic catecholaminergic ventricular tachycardia, Brugada syndrome, and short QT syndrome, and it could be an indicator of increased risk of sudden cardiac death.^{10–14} Measurement of the TpTe interval in such children may be an indicator for potential ventricular arrhythmias.^{15–18} The long TpTe interval has been associated with cardiac arrhythmia.^{15,17} Interestingly, the TpTe/QT ratio has been shown to be an electrocardiographic index of arrhythmogenesis. There were increased chances of cardiac arrhythmia and ventricular tachycardia in patients with long QT syndrome, Brugada syndrome, short QT syndrome, and in those with organic heart diseases such as acute myocardial infarction, if their TpTe/QT values in lead II were greater than the 98th percentile or 0.21¹⁰ despite normal QTc.^{16,17,19} Functional reentry is the underlying mechanism for arrhythmogenesis associated with an increased TpTe/QT ratio.¹² The studies on TpTe interval and TpTe/QT ratio in children taking domperidone are very limited. Most patients had baseline TpTe interval and TpTe/QT ratio higher than the referenced values.¹⁰ Surprisingly, our study demonstrated that TpTe interval and TpTe/QT in lead II after taking domperidone were significantly shorter than those of the baseline. Bieganska et al²⁰ recently reported TpTe intervals in 131 healthy children (64 girls) aged 2.3 to 18.5 years (mean 9.1 years) from all leads of ECG and found that TpTe intervals varied significantly between individual leads, the longest one being in lead V₃, and the shortest in leads III and V₁. TpTe dispersion varied from 6 milliseconds to 80 milliseconds. In most leads, higher TpTe/QT ratios were seen in boys regardless of age. The TpTe intervals lengthened with lowering heart rate.²⁰ It was recommended that the TpTe interval should be measured in precordial leads.²⁰ We believe that the interpretation of TpTe interval and TpTe/QT should be carefully concluded, since little information for these parameters has been reported in the pediatric population, especially during infancy.

Experimental study has demonstrated that domperidone can prolong cardiac repolarization by blocking the rapid component (I_{kr}) of the delayed rectifier potassium current.²¹ The cardiac electrophysiological effects are similar to those of cisapride.²¹ Excessive I_{kr} block may lead to triggering tachyarrhythmia and sudden death.²² Pediatricians should be aware of potential cardiac side effects of domperidone particularly when prescribing high doses, or using concomitant medications known to increase QT interval, and drugs that inhibit P450 enzyme, which are important for drug clearance.²²

5. Conclusions

In summary, domperidone treatment over a short-term period in children <2 years of age did not significantly

lengthen QTc. Based on the results of the current study, the routine baseline and follow-up ECG may not be generally necessary in each individual case receiving only domperidone. However, further studies with larger sample sizes are required to confirm this suggestion.

Conflicts of interest

The authors declare no conflicts of interest.

Acknowledgments

The authors would like to acknowledge staff and teams of the Division of Pediatric Cardiology, Department of Pediatrics for performing the ECGs, Mrs. Umaporn Audomsub, Research Center at Faculty of Medicine, Ramathibodi Hospital, Mahidol University, and Mrs. Sasinipa Srikanlayaniwart at the Faculty of Medicine, Naresuan University for statistical analysis. This study was financially supported by a Research Funding Grant from the Faculty of Medicine Ramathibodi Hospital, Mahidol University.

References

- Reddymasu SC, Soykan I, McCallum RW. Domperidone: review of pharmacology and clinical applications in gastroenterology. *Am J Gastroenterol* 2007;102:2036–45.
- Cresi F, Marinaccio C, Russo MC, Miniero R, Silvestro L. Short-term effect of domperidone on gastroesophageal reflux in newborns assessed by combined intraluminal impedance and pH monitoring. *J Perinatol* 2008;28:766–70.
- Champion M, Hartnett M, Yen M. Domperidone, a new dopamine antagonist. *CMAJ* 1986;135:457–61.
- Rocha CM, Barbosa MM. QT interval prolongation associated with the oral use of domperidone in an infant. *Pediatr Cardiol* 2005;26:720–3.
- Boyce MJ, Baisley KJ, Warrington SJ. Pharmacokinetic interaction between domperidone and ketoconazole leads to QT prolongation in healthy volunteers: a randomized, placebo-controlled, double-blind, crossover study. *Br J Clin Pharmacol* 2012;73:411–21.
- Djeddi D, Kongolo G, Lefaix C, Mounard J, Léké A. Effect of domperidone on QT interval in neonates. *J Pediatr* 2008;153:663–6.
- Günlemez A, Babaoğlu A, Arisoy AE, Türker G, Gökalp AS. Effect of domperidone on the QTc interval in premature infants. *J Perinatol* 2010;30:50–3.
- Bazett HC. An analysis of the time-relations of electrocardiograms. *Heart* 1920;7:353–70.
- Johnson JN, Ackerman MJ. QTc: how long is too long? *Br J Sports Med* 2009;43:657–62.
- Benatar A, Carbonez K. Behavior of the electrocardiographic T peak to end interval in childhood. *Ann Noninvasive Electrocardiol* 2010;15:11–6.
- Topilski I, Rogowski O, Rosso R, Justo D, Copperman Y, Glikson M, et al. The morphology of the QT interval predicts torsade de pointes during acquired bradyarrhythmias. *J Am Coll Cardiol* 2007;49:320–8.
- Gupta P, Patel C, Patel H, Narayanaswamy S, Malhotra B, Green JT, et al. T(p-e)/QT ratio as an index of arrhythmogenesis. *J Electrocardiol* 2008;41:567–74.
- Antzelevitch C. Drug-induced spatial dispersion of repolarization. *Cardiol J* 2008;15:100–21.
- Yan GX, Shimizu W, Antzelevitch C. Characteristics and distribution of M cells in arterially-perfused canine left ventricular wedge preparations. *Circulation* 1998;98:1921–7.
- Ophof T, Coronel R, Janse MJ. Is there a significant transmural gradient in repolarization time in the intact heart? Repolarization gradients in the intact heart. *Circ Arrhythm Electrophysiol* 2009;2:89–96.
- Xue J, Gao W, Chen Y, Han X. Identify drug-induced T wave morphology changes by a cell-to electrocardiogram model and validation with clinical trial data. *J Electrocardiol* 2009;42:534–42.
- Yan GX, Antzelevitch C. Cellular basis for the normal T wave and the electrocardiographic manifestations of the long-QT syndrome. *Circulation* 1998;98:1928–36.
- Hlaing T, DiMino T, Kowey PR, Yan GX. ECG repolarization waves: Their genesis and clinical implications. *Ann Noninvasive Electrocardiol* 2005;10:211–23.
- Erikssen G, Liestøl K, Gullestad L, Haugaa KH, Bendz B, Amlie JP. The terminal part of the QT interval (T peak to T end): a predictor of mortality after acute myocardial infarction. *Ann Noninvasive Electrocardiol* 2012;17:85–94.
- Bieganowska K, Sawicka-Parobczyk M, Bieganowski M, Piskorski J. T_{peak}-T_{end} interval in 12-lead electrocardiogram of healthy children and adolescents T_{peak}-T_{end} interval in childhood. *Ann Noninvasive Electrocardiol* 2013;18:344–51.
- Drolet B, Rousseau G, Daleau P, Cardinal R, Turgeon J. Domperidone should not be considered a no-risk alternative to cisapride in the treatment of gastrointestinal motility disorders. *Circulation* 2000;102:1883–5.
- Priori SG. Exploring the hidden danger of noncardiac drugs. *J Cardiovasc Electrophysiol* 1998;9:1114–6.