

Arterial Reconstruction for Subclavian Obstructive Disease: a Comparison of Extrathoracic Procedures

J. A. van der Vliet, H. W. Palamba, D. M. Scharn, S. F. S. van Roye and F. G. M. Buskens.

Department of Surgery, St. Radboud University Hospital, Nijmegen, The Netherlands

Objectives: Comparison of the immediate and long-term results of three different extrathoracic arterial reconstruction procedures for subclavian obstructive disease.

Design: Retrospective analysis of 51 extrathoracic subclavian artery reconstructions in 49 patients performed in a single centre over an 18-year period (mean follow-up 64 months, range 3–192).

Methods: Carotid–subclavian bypass (CSB, n=21), subclavian–carotid transposition (SCT, n=21) and subclavian–subclavian or axillo–axillary cross-over bypass (COB, n=9) was performed. Upper extremity ischaemic complaints were present in 45/49 patients (92%) and vertebrobasilar insufficiency in 25/49 patients (51%). Symptom relief, improvement of haemodynamic parameters and graft patency were compared.

Results: Operation time was significantly shorter ($p < 0.001$, t -test) in SCT (80 ± 5 min) compared to CSB (112 ± 7 min) and COB (116 ± 6 min). Symptom relief and improvement of haemodynamic parameters were similar for all groups. There were no differences in morbidity rate and there was no mortality. The cumulative patency of SCT was significantly better with 100% at 2, 5 and 10 years postoperatively compared to CSB (75.6%, 62.6% and 52.2%, respectively) ($p < 0.005$, log-rank test) and COB (76.5%, 63.7% and 63.7%, respectively) ($p < 0.02$, log-rank test). There was a tendency for a better patency in prosthetic grafts as compared to autologous vein grafts in CSB (NS, log-rank test).

Conclusions: Satisfactory immediate and long-term results were obtained with all of the above techniques. When technically feasible, SCT is the procedure of choice for extrathoracic arterial reconstruction in subclavian obstructive disease.

Introduction

Atherosclerotic obstruction of the subclavian artery is relatively rare and due to a rich brachiocephalic collateral circulation rarely causes symptoms. However, an occlusion or stenosis of a subclavian artery can occasionally cause upper extremity ischaemia, vertebrobasilar insufficiency or both. In these circumstances surgical or radiological intervention is indicated. The surgical intervention of choice is extrathoracic subclavian revascularisation.¹ The three operative approaches currently in use are the carotid–subclavian bypass (CSB),^{2–4} the direct subclavian–carotid anastomosis or transposition (SCT)^{5–8} and the subclavian–subclavian or axillo–axillary cross-over bypass (COB).⁹ Satisfactory results have been obtained with each of these techniques, but comparative studies are few. This report presents the analysis of a single centre experience with extrathoracic subclavian arterial reconstruction, in which all of the above tech-

niques have been applied. The aim of the study was to compare the immediate and long-term results of these procedures.

Patients and Methods

In an 18-year period from 1976 to 1993 51 extrathoracic subclavian artery reconstructions were carried out in 49 patients. The hospital records of these patients were studied retrospectively to determine the presenting clinical signs and symptoms, results of the preoperative evaluation, details of the operation, complications and immediate and long-term results.

The mean follow-up was 64 months (range 3–192). There were 22 men and 27 women with a mean (\pm SEM) age of 52 ± 2 years. Risk factors for atherosclerosis were prevalent. Tobacco use was recorded in 78%, hypertension in 33%, ischaemic cardiac disease in 14%, ischaemic cerebral disease in 6% and diabetes mellitus in 2%. Upper extremity ischaemic complaints were present in 45/49 patients (92%) and vertebrobasilar insufficiency in 25/49

Please address all correspondence to: J. Adam van der Vliet, MD, PhD, Department of Surgery, St. Radboud University Hospital, P.O. Box 9101, 6500 HB Nijmegen, The Netherlands.

Table 1. Indications for arterial reconstruction in subclavian obstructive disease

	SCT	CSB	COB	All
UEI	12	9	3	24 (47%)
VBI	1	1	2	4 (8%)
UEI + VBI	7	6	3	16 (31%)
UEI + hemispheric	1	2	1	4 (8%)
VBI + hemispheric	–	1	–	1 (2%)
UEI + angina pectoris	–	1	–	1 (2%)
Asymptomatic	–	1	–	1 (2%)
Total	21	21	9	51 (100%)

SCT, subclavian carotid transposition; CSB, carotid-subclavian bypass; COB, cross-over bypass; UEI, Upper extremity ischaemia; VBI, vertebrobasilar insufficiency.

patients (51%) (Table 1). Additional signs of hemispheric involvement were recorded in 5/49 patients (10%). One patient had upper extremity ischaemic complaints as well as angina pectoris due to a coronary-subclavian steal 4 years after an internal mammary-coronary artery bypass.¹⁰ Left sided symptoms were present in 36/51 (71%), right-sided in 10/51 (20%) and bilateral subclavian involvement occurred in 5/51 (10%).

On physical examination a bruit was noticed in 7/31 patients (23%) and a decreased or absent radial artery pulse in 43/47 patients (91%). The mean difference in brachial artery systolic blood pressure (excluding patients with bilateral disease) was 52 ± 5 mmHg. Angiography showed that obstructive lesions in multiple aortic arch branches were present in 26/49

Table 2. Distribution of obstructive lesions on angiography

	SCT	CSB	COB	All
Left SCA	18	14	4	36 (70%)
Right SCA	2	5	3	10 (20%)
Both SCA	1	2	2	5 (10%)
Ipsilateral CA	2	2	1	5 (10%)
Contralateral CA	–	1	–	1 (2%)
Bilateral CA	2	3	1	5 (10%)
Vertebral artery	3	4	–	7 (14%)
Innominate artery	–	2	–	2 (4%)
Radial artery	1	1	–	2 (4%)

SCT, subclavian carotid transposition; CSB, carotid-subclavian bypass; COB, cross-over bypass; SCA, subclavian artery; CA, carotid artery.

patients (53%) (Table 2). In 32/51 cases (63%) there was a subclavian stenosis of greater than 50% and in 17/51 cases (33%) an occlusion. Congenital malformations were present in two patients. In three patients a previously constructed aortic-subclavian bypass and in two a CSB were found to be occluded.

The postoperative management included intravenous heparin administration until satisfactory anti-

coagulation was established with oral coumarin derivatives. The oral anticoagulants were replaced by low-dose acetylsalicylic acid 3 to 6 months after operation. Follow-up angiograms were performed only when clinically indicated. Reconstructive failures were defined as reappearance of a brachial systolic blood pressure difference > 20 mmHg with or without recurrence of symptoms or signs of occlusion at angiography.

The patency data were assessed with the life table method and statistical analysis was performed by means of log-rank and *t*-tests when appropriate.

Results

In 21 cases an SCT, in 21 a CSB and in nine cases a COB was performed. The choice of the operative procedure mainly depended on the preference of the vascular surgeon. In five instances the anatomy at operation prevented the construction of a planned SCT and a CSB was performed instead. Four of the patients in the SCT group required a subclavian endarterectomy. Venous autografts were used as a conduit in 15/21 cases (71%) and prosthetic grafts in 6/21 cases (29%) of the CSB group. In the COB group venous autografts were used in 8/9 cases. In seven patients (14%) a concomitant ipsilateral internal carotid endarterectomy was carried out.

With the exclusion of patients with combined procedures, the mean operation time was significantly shorter ($p < 0.001$, *t*-test) in SCT (80 ± 5 min) compared to CSB (112 ± 7 min) and COB (116 ± 6 min). Initial clinical improvement with total relief of upper extremity ischaemic complaints and/or vertebrobasilar insufficiency was observed in all patients. Immediately postoperatively the mean brachial artery systolic blood pressure difference was reduced to 7 ± 2 mmHg (Table 3). The perioperative increase in arm blood pressure was significantly less ($p < 0.05$, *t*-test) in the CSB group than in the SCT group.

Table 3. Mean pre- and postoperative brachial artery systolic blood pressure difference (mmHg)

	SCT	CSB	COB	All
Recordings (n)	20	18	7	45
Preoperative	56.8 ± 6.6	42.8 ± 6.1	60.0 ± 19.7	51.7 ± 4.9
Postoperative	3.8 ± 1.3	9.2 ± 3.0	9.3 ± 3.8	6.8 ± 1.5
Improvement*	53.0 ± 6.2	33.6 ± 6.2	50.7 ± 19.1	44.9 ± 4.8

SCT, subclavian carotid transposition; CSB, carotid-subclavian bypass; COB, cross-over bypass.

* SCT vs CSB = $p < 0.05$ (*t*-test), SCT vs COB = $p < 0.9$, NS (*t*-test), CSB vs COB = $p < 0.3$, NS (*t*-test).

Early (<30 days) postoperative complications necessitating additional intervention did not occur and there was no mortality. The morbidity was evenly distributed between the groups and consisted of transient hemispheric symptoms ($n = 4$), phrenic nerve lesions ($n = 5$) with a permanent hemidiaphragmatic paralysis in one patient, temporary recurrent laryngeal nerve dysfunction ($n = 5$), transient ipsilateral Horner syndrome ($n = 5$), partial brachial plexus lesions ($n = 4$) with long-standing sensory complaints in two patients and a thoracic duct fistula ($n = 1$). No reconstructive failures occurred within 30 days following operation. Five patients died during follow-up after a mean interval of 8 years (range 2–13) following operation.

The cumulative graft patency is shown in Fig. 1. In the SCT group the primary patency rate was 100% at 10 years after operation. In the CSB group two late reinterventions were recorded. Venous graft stenoses were treated in two patients with a patch plasty at 6 months and 8 years postoperatively. The assisted patency rates in the CSB group were 75.6% at 1 and 2 years, 62.6% at 5 years and 52.2% at 10 years after operation. For the COB group the primary patency rates were 76.5%, 76.5%, 63.7% and 63.7%, respectively. There was a statistically significant difference between the patency of the SCT group and the CSB group ($p < 0.005$, log-rank), as well as the COB group ($p < 0.02$, log-rank). No difference was recorded between the patencies of the CSB and COB groups ($p = 0.9$, log-rank). Fig. 2 shows the patency rates of CSB according to graft material. There was a tendency

for a better patency in prosthetic grafts as compared to autologous vein grafts, however, no statistical difference was found ($p < 0.2$, log-rank).

Discussion

Extrathoracic arterial reconstruction for subclavian obstructive disease can be performed with satisfactory results using various techniques.¹ Although local anatomy may preclude the construction of a SCT, this technique has several appealing characteristics.⁵⁻⁸ The reconstruction is carried out with one single end-to-side vascular anastomosis without the use of graft material. It restores a physiological flow pattern in the subclavian and vertebral arteries by transforming the proximal common carotid artery into a brachiocephalic trunk. The procedure allows for an eversion endarterectomy of the subclavian as well as the proximal vertebral artery and eliminates a possible source of emboli by excluding the diseased proximal subclavian artery. The use of an intraoperative shunt has been recommended in some cases,¹¹ but deemed unnecessary by most authors.^{1,7} Earlier concerns over the development of a subclavian-carotid steal following SCT have been disproved by both experimental and clinical data.^{1,7,12,13} The construction of a side-to-side anastomosis between the subclavian and common carotid arteries, as described by Edwards and Wright,¹⁴ requires less dissection, but negates several of the above advantages.

For more extensive obstructive lesions a CSB can be used. The reconstruction can be performed without the sometimes difficult dissection of the proximal subclavian artery. As two separate vascular anastomoses are required, the operative time is usually

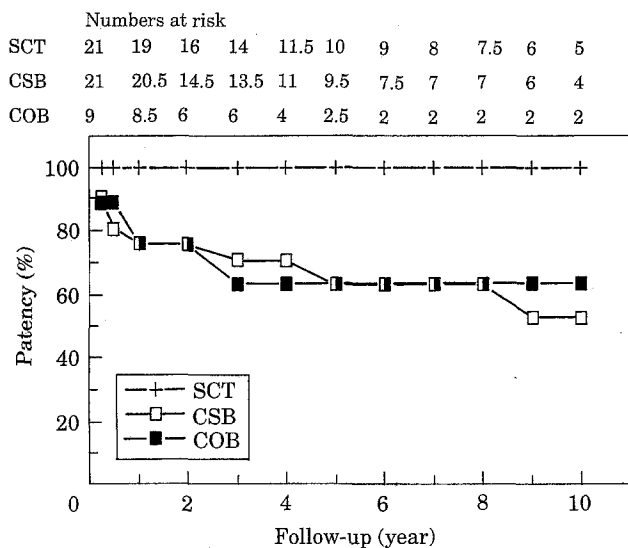


Fig. 1. Cumulative patency of subclavian artery reconstruction. SCT, subclavian carotid transposition; CSB, carotid-subclavian bypass; COB, cross-over bypass. SCT vs CSB = $p < 0.005$ (log-rank), SCT vs COB = $p < 0.02$ (log-rank), CSB vs COB = $p < 0.9$, NS (log-rank).

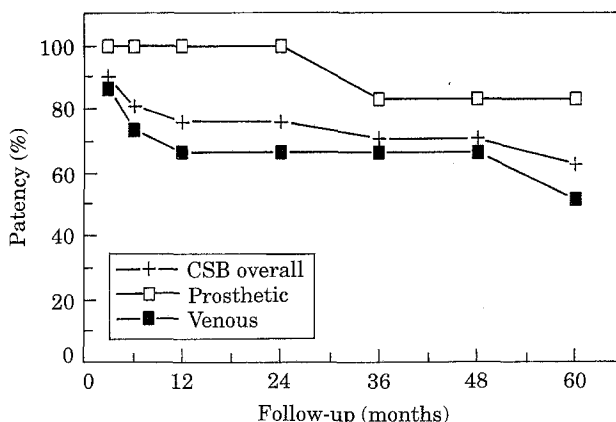


Fig. 2. Cumulative patency of carotid-subclavian bypass (CSB) according to graft material. Prosthetic vs venous = $p < 0.2$, NS (log-rank).

longer than in SCT. Controversy exists over the choice of graft material in CSB. In accordance with the present study most authors report better results with the use of prosthetic grafts.^{1,2} Sterpetti *et al.*¹⁵ on the other hand recorded a more favourable outcome with vein grafts. As involvement of multiple aortic arch branches is not uncommon in patients with obstructive subclavian disease, it is important that both the CSB and the SCT techniques allow for concomitant endarterectomy of the ipsilateral internal carotid artery without extensive additional dissection.

The COB is a safe and technically undemanding procedure, that can be performed under local anaesthesia.⁹ It has an advantage over SCT and CSB in that it is performed without any manipulation of the common carotid artery.¹⁶ The COB can be positioned cervically or subcutaneously across the sternum, where it may interfere with the performance of a median sternotomy for subsequent coronary artery surgery or cause skin erosions.^{1,16}

A lesion of the brachial plexus is the most frequent complication following COB. This complication is also encountered with the other techniques of subclavian revascularisation, as is illustrated in the present study. The cervical exploration in SCT and CSB also carries the risk of damage to the recurrent laryngeal and phrenic nerves, as well as the sympathetic nerve chain, causing Horner's syndrome.^{1,4,5,7,15-17} Embolic or thrombotic carotid complications occur infrequently with the latter techniques.^{1,2,4,6,11,15,16} In the present study the majority of the recorded complications were of a transient nature and required no additional intervention. Graft infections were not encountered. The absence of mortality in most series shows that extrathoracic subclavian reconstructions can be performed with low risk in patients with severe atherosclerosis.¹ Initial symptom relief is similar in all of the above reconstructive techniques. In the present study, however, the improvement of the non-invasive haemodynamic parameters was less following CSB.

Comparative patency studies are few and all of them have been performed retrospectively. AbuRahma and coworkers¹⁷ compared the results of CSB and axillo-axillary COB with prosthetic grafts and found a better patency rate in CSB. Mingoli and coworkers¹⁶ used mainly autologous vein grafts in their series of axillo-axillary COB and recorded a similar patency with CBS in the absence of ipsilateral carotid stenosis. Two comparative studies on SCT and CSB have been performed. Kretschmer and coworkers¹⁸ recorded a superior patency rate for SCT. A 100% long-term patency for SCT was also reported by Sterpetti *et al.*¹⁵ Although no significant difference was

found in patency rates, a late progressive deterioration of the haemodynamic status following CSB was documented in their series. The operative time was significantly shorter for SCT as compared to CSB, which is in accordance with the findings of the present study.

In a review of the literature on subclavian reconstruction Criado¹ showed that, in a total series of 787 operations, the most favourable results were obtained with SCT. The long-term results of the present study are also clearly in favour of the SCT technique. It is therefore concluded that, when technically feasible, SCT is the procedure of choice for extrathoracic arterial reconstruction in subclavian obstructive disease.

Acknowledgements

The authors thank Dr Cees J. van der Linden for his assistance with the statistical analysis and Dr R. Jan A. Goris, Dr Peter H. M. Reemst, Dr Fred C. W. Sloopmans, and Dr Ronald J. Zijlstra for their suggestions in the preparation of this manuscript.

References

- 1 CRIADO FJ. Extrathoracic management of aortic arch syndrome. *Br J Surg* 1982; 69(Suppl.): 45-51.
- 2 ZIOMEK S, QUINONES-BALDRICH WJ, BUSUTTL RW, BAKER JD, MACHLEDER HI, MOORE WS. The superiority of synthetic arterial grafts over autologous veins in carotid-subclavian bypass. *J Vasc Surg* 1986; 3: 140-145.
- 3 DEFRAIGNE JO, REMY D, CREEMERS E, LIMET R. Carotid-subclavian bypass with or without carotid endarterectomy. *Acta Chir Belg* 1990; 90: 248-254.
- 4 PERLER BA, WILLIAMS GM. Carotid-subclavian bypass - a decade of experience. *J Vasc Surg* 1990; 12: 716-723.
- 5 LERUT J, SANDMANN W. Subclavian-carotid transposition. *Acta Chir Belg* 1983; 83: 270-275.
- 6 SANDMANN W, KNIEMEYER HW, JAESCHOCK R, HENNERICI M, AULICH A. The role of subclavian-carotid transposition in surgery for supra-aortic occlusive disease. *J Vasc Surg* 1987; 5: 53-58.
- 7 WEIMANN S, WILLEIT H, FLORA G. Direct subclavian-carotid anastomosis for the subclavian steal syndrome. *Eur J Vasc Surg* 1987; 1: 305-310.
- 8 DIETRICH EB, KOOPOT R. Simplified operative procedure for proximal subclavian arterial lesions: direct subclavian-carotid anastomosis. *Am J Surg* 1981; 142: 416-421.
- 9 ROSENTHAL D, ELLISON RG, CLARK MD *et al.* Axilloaxillary bypass: Is it worthwhile? *J Cardiovasc Surg* 1988; 29: 191-195.
- 10 VAN SON JAM, AENGEVAEREN WR, SKOTNICKI SH, BARENTSZ JO, VAN DE WAL HJ, BUSKENS FGM. Diagnosis and management of the coronary-subclavian steal syndrome. *Eur J Cardiothorac Surg* 1989; 3: 565-567.
- 11 MEHIGAN JT, BUCH WS, PIPKIN RD, FOGARTY TJ. Subclavian-carotid transposition for the subclavian steal syndrome. *Am J Surg* 1978; 136: 15-20.
- 12 LORD RS, EHRENFELD WK. Carotid-subclavian bypass: A haemodynamic study. *Surgery* 1969; 66: 521-526.
- 13 COOK CH, STEMMER EA, CONOLLY JE. Effect of peripheral resistance on carotid blood flow after carotid-subclavian bypass. *Arch Surg* 1972; 105: 9-13.

- 14 EDWARDS WH, WRIGHT RS. Surgical therapy in subclavian occlusive disease. *Am J Surg* 1972; **123**: 689–693.
- 15 STERPETTI AV, SCHULTZ RD, FARINA C, FELDHAUS RJ. Subclavian artery revascularisation: A comparison between carotid-subclavian artery bypass and subclavian-carotid transposition. *Surgery* 1989; **106**: 624–632.
- 16 MINGOLI A, FELDHAUS RJ, FARINA C, SCHULTZ RD, CAVALLARO A. Comparative results of carotid-subclavian bypass and axilloaxillary bypass in patients with symptomatic subclavian disease. *Eur J Vasc Surg* 1992; **6**: 26–30.
- 17 ABURAHMA AF, ROBINSON PA, KHAN JH, BOLAND JP. Brachiocephalic revascularisation: A comparison between carotid-subclavian artery bypass and axilloaxillary bypass. *Surgery* 1992; **112**: 84–91.
- 18 KRETSCHMER G, TELEKY B, MAROSI L *et al.* Obliterations of the proximal subclavian artery: to bypass or to anastomose? *J Cardiovasc Surg* 1991; **32**: 334–349.

Accepted 26 October 1994