


Contents lists available at [ScienceDirect](http://ScienceDirect)

## Asian Pacific Journal of Tropical Medicine

journal homepage: [www.elsevier.com/locate/apjtm](http://www.elsevier.com/locate/apjtm)

Document heading doi:

# A case of advanced mycosis fungoides with comprehensive skin and visceral organs metastasis: sensitive to chemical and biological therapy

Yi-Qian Liu<sup>#</sup>, Wei-You Zhu<sup>#</sup>, Yong-Qian Shu, Yan-Hong Gu<sup>\*</sup>

Department of Oncology, the First Affiliated Hospital of Nanjing Medical University, Nanjing 210029, P.R.China

## ARTICLE INFO

## Article history:

Received 15 January 2012

Received in revised form 15 March 2012

Accepted 15 May 2012

Available online 20 August 2012

## Keywords:

Mycosis fungoides

Cutaneous T-cell lymphoma

Chemotherapy

## ABSTRACT

Mycosis fungoides is a common cutaneous T-cell lymphoma, which is usually characterized by chronic, indolence progression, with absence of typical symptoms in early stage, metastasis to lymph nodes, bone marrow and visceral organs in later stage and ultimately progression to systemic lymphoma. It can result in secondary skin infection which is a frequent cause of death. At present, no curative therapy existed. Therapeutic purpose is to induce remission, reduce tumor burden and protect immune function of patients. A case of patient with advanced severe mycosis fungoides receiving CHOP plus interferon  $\alpha$ -2a was reported here, with disease-free survival of 7 months and overall survival of over 17.0 months, and current status as well as developments of mycosis fungoides were briefly introduced.

## 1. Introduction

Mycosis granuloma is also known as mycosis fungoides (MF) which was named due to similarity of shape between skin nodules in this disease and mushroom instead of fungal infection, originally described by French dermatologist, Alibert, in 1806. MF is the most common type in primary cutaneous T-cell lymphoma (CTCL), accounting for 60% of new cases of CTCL, which generally progress slowly and could invade lymph nodes, bone marrow and visceral organs, eventually, develop to systemic lymphoma in later stage. The involvement of important visceral organs including lung, liver, kidney, pancreas, *etc.* occurred in 20% of patients with severe skin lesions who would died due to secondary skin infection[1–3]. Patient age at a peak presentation ranged from 55 to 60 years and female–male ratios was 1.6–2.3:1.

## 2. Case report

A 40-year-old woman was admitted because of generalized plaque and mass with pruritus for four years and getting worse for half a year on August 6th, 2009. The patient experienced pruritic plaque on her back in July 2005 and was diagnosed as ‘eczema’ by local hospital. Symptoms were not improved after topical corticosteroid therapy. Enlarged cervical lymph nodes were presented and lymph node biopsy indicated reactive hyperplasia in 2006. Generalized plaques and mass got worse in January 2009 and a head and facial biopsy showed mycosis fungoides (Figure 1), immunohistochemistry showed CD4 (++) , CD68 scattered (+). Bacterial culture of head exudate indicated: *Staphylococcus aureus*. She obtained improvement after receiving antimicrobial agents and symptomatic treatment. The patient experienced acute pancreatitis due to compression and invasion of a mass in the pancreatic head on July 9th, 2009 and obtained improvement after receiving antimicrobial and enzymes inhibitor therapy in Nanjing First Hospital. The results of PPD, blood culture,

\*: Corresponding author: Yan-Hong Gu, Ph.D., Department of Oncology, the First Affiliated Hospital of Nanjing Medical University, 300# Guangzhou Road, Nanjing 210029, P.R.China.

Tel: +86–25 68136428

E-mail: [guluer@163.com](mailto:guluer@163.com).

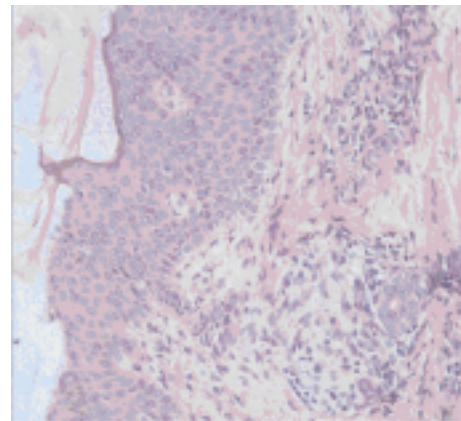
Foundation project: The work was supported by the Jiangsu province Natural Science Foundation of China (No. BK2010579).

#: These authors have equal contributions.

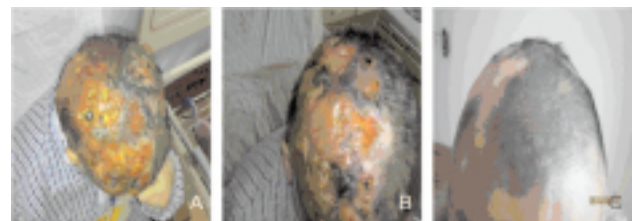sputum culture and hydrothorax culture were negative in hospital and no tumor cell was detected in hydrothorax. The bone marrow cytology test in our hospital on July 30th, 2009 indicated granulocyte series hyperplasia, erythrocyte series slight hyperplasia and megacaryocyte series hyperplasia with clusters of platelet. Physical examination revealed generalized red or dark-red plaque and mass in various size of range from pigeon egg to goose egg on face and head, trunk and limbs, with partial fusion, rupture and exudate. Enlarged retroauricular and axillary lymph nodes were palpable and the large one was 3 cm × 4 cm in size. Pitting edema of right lower extremity existed without tenderness.

This patient received intensively local care after hospitalization immediately. Washing out local exudates by topical saline every day, anti-infection with mupirocin ointment used in the area of ulcerate, intravenous infusion of vancomycin and other active anti infection, as well as supportive care were used to treat this patient. On August 12th, 2009, modified CHOP chemotherapy (cyclophosphamide 0.6 d1,8 + vincristine 2 mg d1,8 + epirubicin 30 mg d1,8 + prednisone 15 mg po. bid d1–14) plus polyethyleneglycol interferon  $\alpha$ -2a (Pegasys 180  $\mu$ g qw) was administrated to this patient. After one week treatment, tumor on head and face regressed apparently, and exudate from ulceration was also obviously reduced. On Aug 26th, this patient got a fever of 39.2 °C, WBC:  $0.3 \times 10^9/L$ , and was regarded as grade IV myelosuppression. Then, we used G-CSF, GM-CSF and infused 10  $\mu$  leukocyte suspension to increase white blood cells. Meanwhile, the patient received active anti infection treatment, intensive care, ultraviolet disinfection in the ward regularly, as well as rigorous observation. After treated with these prompt supportive cares, the patient was improved. After two cycles of chemotherapy, the reexamination of PET/CT showed apparent tumor regression, pleural and pericardial effusion disappeared and the patient was evaluated with partial remission on September 30th, 2009. In cycle 3 and 4, the patient occurred grade IV leucopenia and thrombocytopenia with fever and received G-CSF plus GM-CSF to increase white blood cells, IL-11 to increase platelet, immunoglobulin for supportive care and platelet as well as leukocyte suspension. After treated with these supportive cares, the disease improved. On December 31st, 2009, the patient experienced dizziness and plantar numbness without vomiting. Brain MR showed flake abnormal signal shadow near left cerebellar and trigone of bilateral ventricle, local brain edema, regarded as intracerebral lymphoma invasion. The patient was infused with MTX 15 mg, dexamethasone 3 mg through lumbar puncture on December 31st, 2009 and January 7th, 2010, respectively, without any toxicities. The examination of cerebrospinal fluid routine test and biochemistry was normal, no tumor cells were detected by exfoliative cytological examination. The patient began the 5th cycle of chemotherapy on January 20th, 2010 with semustine 0.2 d1 + teniposide 50 mg d2–4 + dexamethasone 10 mg d2–4. On February 25th, 2010, while compared with the result of PET/CT examination on September 30th,

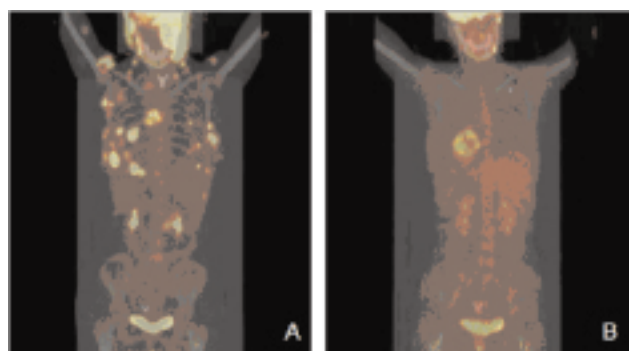
2010, reexamination of PET/CT showed FDG metabolism of right upper neck residual lymph node decreased, the FDG metabolism of other residual lymph nodes and residual plaque shadow in the right front upper pericardium did not increase, thickening subcutaneous tissue of head and neck was relieved. All these results indicated this treatment was effective. The result of cerebrospinal fluid routine test was normal. Because of effective treatment outcome, the patient received 6th cycle of consolidation chemotherapy on February 25th with MeCCNU 0.2 g d0 + VM-26: 50 mg d1–5 + DEX: 20 mg d1–5. The patients had finished six cycles of chemotherapy until April 30th 2010. Tumor was shrinking over 90%, pleural and pericardial effusion disappeared (Figure 2–4). Until last follow up date of January 24th, 2011, the patient was still alive.



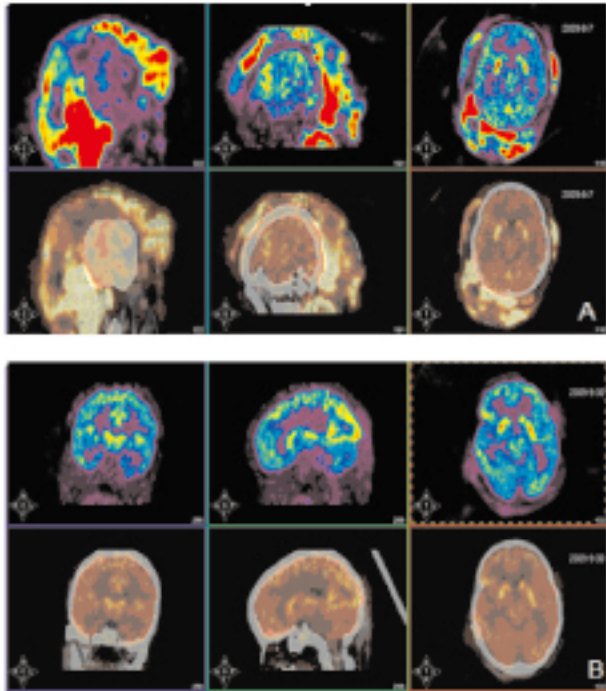
**Figure 1.** HE section, tumor cells invaded the superficial dermis ( $\times 200$ ).



**Figure 2.** Change of skin lesions on head. A: before chemotherapy; B: One week after the first chemotherapy; C: After 5 cycles of chemotherapy.



**Figure 3.**  $^{18}F$ -FDG PET indicated that the FDG uptake of the tumor was decreased remarkably and the patient obtained partial remissions after 2 cycles of chemotherapy. A: Before chemotherapy (Aug.7th, 2009); B: After chemotherapy (Sep. 30th, 2009).



**Figure 4.** Change of head lesions on PET/CT. FDG metabolism of skin lesions on head decreased, the tumor was shrinking over 90%. A: Before chemotherapy (Aug.7th, 2009); B: After chemotherapy (Sep. 30th, 2009).

### 3. Discussion

MF is the most common form of cutaneous T-cell lymphoma, accounting for 60% of new cases, with an increase in incidence<sup>[4]</sup>. The cause of this disease is unclear to date, possibly related to heredity, viral infection, environment, occupational factor, drugs and *etc.* Histopathology: (1) Non-specific period: absence of specific changes and main features characterized as telangiectasia in dermal papilla layer, epithelial cell swelling and perivascular inflammatory cell infiltration. (2) Infiltration stage: infiltrate cells located in the epidermis mainly including heteromorphous reticular cells (mycosis cells), neutrophils, eosinophils, lymphocytes and tissue cells and *etc.* and presence of oval-shaped, gyral-shaped or irregular mycosis cells that are slightly larger than normal lymphocytes and had hyperchromatic, irregularly contoured nuclei as well as karyomitosis, and round microabscess in the epidermis which had diagnostic significance. (3) Tumor stage: tumor cells proliferation into groups invading dermis layer and even subcutaneous tissue and muscle. Clinical manifestations: The course of MF could last for a long time and skin lesions were variably present, which could be similar to various skin diseases, therefore, the diagnosis of MF was usually confirmed many years after the initial appearance of skin symptoms. This disease is generally divided into 3 stages: patch stage, plaque stage and tumor stage. In patch stage, skin lesion is atypical and non-specific, which is similar to dermatitis, eczema, psoriasis and *etc.* In plaque stage, skin lesion evolves into irregular invasive plaque, and clinically differential

diagnosis includes actinic reticulosis, cutaneous pseudo-T-cell lymphoma, large-plaque parapsoriasis, lymphomatoid papulosis, alopecia mucinosa, Ki-1 positive anaplastic large cell lymphoma, peripheral T-cell lymphoma, and *etc.*<sup>[5,6]</sup>. In tumor stage, tumors present as hemispherical, fungating or irregular shape, soft and reddish-brown mass. Patient will feel intolerable pain if rupture occurs. Ulcerative lesions usually cause infection and secondary sepsis which are the most common cause of death resulted from MF. Diagnosis: it is not difficult to confirm diagnosis according to history, clinical features and biopsy. Heteromorphous reticular cell and microabscess in the epidermis are the main evidences of histopathological diagnosis. Treatment: Recently, no curative therapy for MF existed. The objective of treatment is to induce remission, reduce tumor burden as far as possible, meanwhile, and protect immune function of patients. Early treatment for this disease could obtain better outcome and therapeutic approaches include: 1) Electron beam irradiation: electron irradiation of local or systemic skin is one of the basic treatment methods; 2) Immunotherapy: the response rate of interferon treatment can approach 50%, with common dose of 3-6 Mu, thrice every week, by intramuscular or subcutaneous injection; 3) Local drug treatment: traditional treatment including topical corticoid, chemotherapeutic drugs (nitrogen mustard, carmustine, *etc.*) 4) Light therapy: UVB (ultraviolet irradiation) or PUVA (psoralen+UVA)<sup>[7]</sup>, extracorporeal photopheresis. 5) Systemic chemotherapy: restricted to recurrent, local chemotherapy failure or lymph node and visceral invasion patient. Lower dose of methotrexate and single gecitabine<sup>[8]</sup>, polyethyleneglycol adriamycin are effective. Response rate of combination chemotherapy was 81%, median response duration range from 5 to 41 months, and commonly used regimens included CVP, CHOP, CAVE and *etc.* CHOP could provide high response rate.

This patient initially presented skin symptoms in 2005, and was definitely diagnosed with mycosis fungoides by biopsy and immunohistochemistry in June, 2009. It was difficult to clinically establish a diagnosis of MF due to absence of specific symptoms. When general drugs were ineffective for refractory rash accompanying with intractable pruritus, examinations of histopathology and immunohistochemistry should be performed as early as possible. Biopsy should be repeated, if necessary, to confirm diagnosis when prior biopsy did not obtained definite result<sup>[9]</sup>. This patient was in tumor stage when she was admitted to hospital, with generalized skin, lymph nodes and visceral organs involvement. There were many unfavourable factors during treatment period as follow: This patient had a history of acute pancreatitis within a month prior to admission, which was possibly related to tumor suppression and invasion, however, acute pancreatitis could occurred again at any time during treatment period; Generalized rupture and exudation were present on systemic skin, causing infection and recurrent high fever during hospitalization; this patient experienced severe hypoproteinemia, with albumin of 21.1 g/L, bilateral moderate pleural effusion and pericardial effusion; Grade 4 myelosuppression, febrile neutropenia, secondary infection and septic shock frequently occurred during chemotherapy. For the rare, severe case, we collected and consulted relevant professional knowledge and clinical case report. Firstly, we strengthened local care, closely

cooperated with department of hematology and dermatology, and then established CHOP-based chemotherapy and systemic treatment; During treatment period, we actively communicated with the patient, closely observed disease progression and timely adjusted treatment regimen; After treatment, discharge guidance and close follow-up were performed. Significant head tumor shrinking was observed after one week treatment through reasonable arrangement and treatment. The patient obtained partial remissions after 2 cycles of chemotherapy. Most tumors regressed after 6 cycles of chemotherapy, with good quality of life and progression-free survival of 7 months. Overall survival of the patient was more than 17 months until last follow-up date of January 24th, 2011. For this patient with advanced and severe MF, CHOP in combination with interferon  $\alpha$ -2a effectively controlled disease, improved quality of life and prolonged survival time.

Recently, with the development of biological techniques, new styles of target drugs bring new hope to MF treatment. These new drugs include bexarotene, denileukin, diftitox, vorinostat, zanolimumab and alemtuzumab. Bexarotene is a novel retinoid that is specifically selective for retinoid X receptors to regulate cellular proliferation, differentiation and apoptosis. The oral and external (1%) formulation of Bexarotene were approved by the FDA in 1999 and 2000, respectively, for conventional method failure patients with early stage of cutaneous T cell lymphoma. Denileukin diftitox is an engineered protein combining interleukin-2 and diphtheria toxin which can bind to high affinity interleukin-2 receptors (CD25) expressed in some leukemias and lymphomas malignant cells. In a Phase III clinical study, this drug was administrated to patients after other treatment failure and obtained overall response rate of 30% as well as median response duration of 6.9 months<sup>[10]</sup>. Vorinostat is a histone deacetylase inhibitor. Histone deacetylase inhibitor is an intensive inducer of histone deacetylation, cell cycle arrest and apoptosis. In a IIB study, Seventy four patients with persistent, progressive or refractory CTCL were treated with vorinostat, with overall response rate and median time to progression of 29.7% and 4.9 months, respectively. This drug is the first HDAC inhibitor approved for CTCL indication. Zanolimumab, an anti-CD4 antibody, and alemtuzumab, an anti-CD52 antibody, have shown promising efficacy for advanced MF<sup>[11]</sup>. Otherwise, other new drugs including pentostatin, temozolomide and bortezomib also have certain therapeutic effect<sup>[12,13]</sup>.

For refractory or advanced disease, high-dose chemotherapy in combination with autologous stem cell transplantation (SCT) is used to treat patient with CTCL. However, this treatment provide limited clinical benefits, with short-term remissions and high relapse rate, therefore, it is used but with decreasing frequency. There were only case report and small study on allogeneic SCT treatment for advanced MF. Data from the study about allogeneic SCT indicated that graft-versus-T cell lymphoma effect existed, with long-term remissions in highly selected patients. Currently, except allogeneic SCT, there is no definite treatment that could provide long-term remissions or cure for patients with advanced MF. Moreover, clinical trial of new drug was also alternative treatment option for all patients with recurrent or advanced disease.

## Conflict of interest statement

We declare that we have no conflict of interest.

## Acknowledgments

We would like to acknowledge the doctors in Pathology Department in the First Affiliated Hospital with Nanjing Medical University.

## References

- [1] Kaplanski G, Koeppel MC, Deharo C, Durand JM, Andrac L, Sayag J. Secondary pancreatic involvement of mycosis fungoides detected by a clinically palpable mass. *Dermatology* 1994; **189**: 406-408.
- [2] Shiozawa E, Shiokawa A, Shibata M, Nakada T, Yamochi-Onizuka T, Saito B, et al. Autopsy case of CD4/CD8 cutaneous T-cell lymphoma presenting disseminated pagetoid reticulosis with aggressive granulomatous invasion to the lungs and pancreas. *Pathol Int* 2005; **55**: 32-39.
- [3] Gottlieb K, Anders K, Kaya H. Obstructive jaundice in a patient with mycosis fungoides metastatic to the pancreas. EUS findings. *JOP* 2008; **9**: 719-724.
- [4] Trautinger F, Knobler R, Willemze R, Peris K, Stadler R, Laroche L, et al. EORTC consensus recommendations for the treatment of mycosis fungoides/Sezary syndrome. *Eur J Cancer* 2006; **42**: 1014-1030.
- [5] Sarveswari KN, Yesudian P. The conundrum of parapsoriasis versus patch stage of mycosis fungoides. *Indian J Dermatol Venereol Leprol* 2009; **75**: 229-235.
- [6] Olsen E, Vonderheid E, Pimpinelli N, Willemze R, Kim Y, Knobler R, et al. Revisions to the staging and classification of mycosis fungoides and Sezary syndrome: a proposal of the International Society for Cutaneous Lymphomas (ISCL) and the cutaneous lymphoma task force of the European Organization of Research and Treatment of Cancer (EORTC). *Blood* 2007; **110**: 1713-1722.
- [7] Querfeld C, Rosen ST, Kuzel TM, Kirby KA, Roenigk HH Jr, Prinz BM, et al. Long-term follow-up of patients with early-stage cutaneous T-cell lymphoma who achieved complete remission with psoralen plus UV-A monotherapy. *Arch Dermatol* 2005; **141**: 305-311.
- [8] Buhl T, Bertsch HP, Kaune KM, Mitteldorf C, Schön MP, Kretschmer L. Low-dose gemcitabine efficacious in three patients with tumor-stage mycosis fungoides. *Clin Lymphoma Myeloma* 2009; **9**: E21-E24.
- [9] Reichman O, Sobel JD, Bentley G. Chronic vulvar fissure—a rare manifestation of mycosis fungoides. *J Low Genit Tract Dis* 2010; **14**: 65-67.
- [10] Olsen E, Duvic M, Frankel A, Kim Y, Martin A, Vonderheid E, et al. Pivotal phase III trial of two dose levels of denileukin diftitox for the treatment of cutaneous T-cell lymphoma. *J Clin Oncol* 2001; **19**: 376-388.
- [11] Lundin J, Hagberg H, Repp R, Cavallin-Stahl E, Freden S, Juliusson G, et al. Phase 2 study of alemtuzumab (anti-CD52 monoclonal antibody) in patients with advanced mycosis fungoides/Sezary syndrome. *Blood* 2003; **101**: 4267-4272.
- [12] Tani M, Fina M, Alinari L, Stefoni V, Baccarani M, Zinzani PL. Phase II trial of temozolomide in patients with pretreated cutaneous T-cell lymphoma. *Haematologica* 2005; **90**: 1283-1284.
- [13] Zinzani PL, Musuraca G, Tani M, Stefoni V, Marchi E, Fina M, et al. Phase II trial of proteasome inhibitor bortezomib in patients with relapsed or refractory cutaneous T-cell lymphoma. *J Clin Oncol* 2007; **25**: 4293-4297.