

PUBLISHED VERSION

I.M. Zdziarski, J.W. Edwards, J.A. Carman, J.I. Haynes
GM crops and the rat digestive tract: a critical review
Environment International, 2014; 73:423-433

© 2014 The Authors. Published by Elsevier Ltd. This is an open access article under the CC BY-NC-ND license (<http://creativecommons.org/licenses/by-nc-nd/3.0/>).

Originally published at:
<http://doi.org/10.1016/j.envint.2014.08.018>

PERMISSIONS

<http://creativecommons.org/licenses/by-nc-nd/3.0/>



Attribution-NonCommercial-NoDerivs 3.0 Unported (CC BY-NC-ND 3.0)

This is a human-readable summary of (and not a substitute for) the [license](#).

[Disclaimer](#)

You are free to:

Share — copy and redistribute the material in any medium or format

The licensor cannot revoke these freedoms as long as you follow the license terms.

Under the following terms:



Attribution — You must give **appropriate credit**, provide a link to the license, and **indicate if changes were made**. You may do so in any reasonable manner, but not in any way that suggests the licensor endorses you or your use.



NonCommercial — You may not use the material for **commercial purposes**.



NoDerivatives — If you **remix, transform, or build upon** the material, you may not distribute the modified material.

No additional restrictions — You may not apply legal terms or **technological measures** that legally restrict others from doing anything the license permits.

<http://hdl.handle.net/2440/95716>



Review

GM crops and the rat digestive tract: A critical review



I.M. Zdziarski ^a, J.W. Edwards ^b, J.A. Carman ^{b,c,*}, J.I. Haynes ^a

^a Discipline of Anatomy and Pathology, School of Medical Sciences, University of Adelaide, SA 5005, Australia

^b Health and the Environment, School of the Environment, Flinders University, Bedford Park, SA 5042, Australia

^c Institute of Health and Environmental Research (IHER), P.O. Box 155, Kensington Park, SA 5068, Australia

ARTICLE INFO

Article history:

Received 3 April 2014

Accepted 29 August 2014

Available online 20 September 2014

Keywords:

Genetically modified crop

Rat feeding study

Long-term feeding studies

Histopathology

Gastrointestinal tract

ABSTRACT

The aim of this review is to examine the relationship between genetically modified (GM) crops and health, based on histopathological investigations of the digestive tract in rats. We reviewed published long-term feeding studies of crops containing one or more of three specific traits: herbicide tolerance via the *EPSPS* gene and insect resistance via *cry1Ab* or *cry3Bb1* genes. These genes are commonly found in commercialised GM crops. Our search found 21 studies for nine (19%) out of the 47 crops approved for human and/or animal consumption. We could find no studies on the other 38 (81%) approved crops. Fourteen out of the 21 studies (67%) were general health assessments of the GM crop on rat health. Most of these studies (76%) were performed after the crop had been approved for human and/or animal consumption, with half of these being published at least nine years after approval. Our review also discovered an inconsistency in methodology and a lack of defined criteria for outcomes that would be considered toxicologically or pathologically significant. In addition, there was a lack of transparency in the methods and results, which made comparisons between the studies difficult. The evidence reviewed here demonstrates an incomplete picture regarding the toxicity (and safety) of GM products consumed by humans and animals. Therefore, each GM product should be assessed on merit, with appropriate studies performed to indicate the level of safety associated with them. Detailed guidelines should be developed which will allow for the generation of comparable and reproducible studies. This will establish a foundation for evidence-based guidelines, to better determine if GM food is safe for human and animal consumption.

© 2014 The Authors. Published by Elsevier Ltd. This is an open access article under the CC BY-NC-ND license (<http://creativecommons.org/licenses/by-nc-nd/3.0/>).

Contents

1. Introduction	424
1.1. Background	424
1.2. Unintended effects and the need for animal feeding studies	424
1.3. The importance of studying the gastrointestinal tract	424
2. Methods	424
3. Results	424
4. Discussion	425
4.1. Review of the methods	425
4.2. Selection of endpoints	425
4.3. Lack of transparency in results	427
4.4. Relevance of OECD guidelines in the evaluation of the safety of consuming GM crops	430
4.5. Have enough studies been conducted to adequately state that GM crops are safe for human and animal consumption?	430
5. Conclusions	432
Acknowledgements	432
References	432

Abbreviations: EFSA, European Food Safety Agency; FAO, Food and Agricultural Organisation; FSANZ, Food Standards Australia New Zealand; GI, gastrointestinal; GM, genetically modified; H&E, haematoxylin and eosin; LM, light microscopy; OECD, Organisation for Economic Cooperation and Development; RR, Roundup Ready; TEM, transmission electron microscopy; WHO, World Health Organisation.

* Corresponding author at: Institute of Health and Environmental Research (IHER), P.O. Box 155, Kensington Park, SA 5068, Australia. Tel.: +61 408 480 944.
E-mail address: judyacarman@ozemail.com.au (J.A. Carman).

1. Introduction

1.1. Background

Genetically modified (GM) or transgenic crops have been grown for human and animal consumption since the 1990s (Clive and Krattiger, 1996). There are currently over 200 different GM crops with various traits approved for human and animal consumption in many countries (ISAAA, 2013). Despite this, feeding studies examining the effects of GM crops on animal and human health are relatively scarce (Domingo, 2000; Domingo and Bordonaba, 2011; Snell et al., 2012).

1.2. Unintended effects and the need for animal feeding studies

The two most common methods of producing GM crops are through *Agrobacterium*-mediated transformation and microparticle bombardment (also known as microparticle acceleration or biolistics) (Wilson et al., 2006). A common criticism is that these processes are imprecise. In both processes, the insertion site of the new DNA is random (Altpeter et al., 2005; Wilson et al., 2006) and more than one copy of the DNA fragment may be inserted into the target genome (Christou, 1992; Gasson, 2003). This can affect gene expression in a positive or negative manner, for example, by causing gene suppression or gene silencing (Altpeter et al., 2005; Dai et al., 2001). In microparticle bombardment, the extra copies of the inserted DNA can be scrambled, inverted or incomplete (Altpeter et al., 2005). In addition, in microparticle bombardment, the site of insertion may undergo further recombination (Altpeter et al., 2005; Christou et al., 1988; Windels et al., 2001). For these reasons, the toxicity or nutritional value of the GM crop should be assessed as a whole.

Transgenic crops are produced through the insertion of a gene cassette, which consists of the desired trait genes, as well as several other genes such as viral promoter and marker genes. These genes tend to be truncated or shortened versions, which may even have gene sequence changes (ISAAA, 2013; Padgett et al., 1995; Vaeck et al., 1987). The effect of these genes acting together is not often determined or even required (FAO/WHO, 2000; FSANZ, 2007).

At present, establishing substantial equivalence is the only generally required safety assessment (FAO/WHO, 2000; FSANZ, 2007). Substantial equivalence relies on the premise that the safety of GM food can be assessed through a comparison with compounds or organisms of known safety. The purpose of the test for substantial equivalence is to identify possible hazard areas, which become the focus of further assessment (FSANZ, 2007; König et al., 2004). The test for substantial equivalence examines the individual characters and not the GM crop as a whole. For example, it assesses the toxicity of the new protein the plant has been designed to produce, such as an insecticidal protein or a protein conferring herbicide tolerance. Based on the safe history of consumption of that protein in its wild-type form, the protein is deemed safe (Kuiper et al., 2001). If the test for substantial equivalence shows no differences outside what could be obtained through natural variation, then food regulators may not require further examinations (Schilter and Constable, 2002). This type of general safety assessment does not consider that the genes present in the novel food may be additional or different from what is anticipated (Padgett et al., 1995; Vaeck et al., 1987; Wilson et al., 2006). It does not take into account the alteration of the protein gene sequence prior to insertion or the possibility that the protein gene sequence may have been altered due to the transformation process, although the latter has recently been incorporated into the European Food Safety Agency (EFSA) assessment processes (EFSA, 2008). Hence, we argue that GM crops should undergo thorough safety evaluations that do not simply consider the GM food as being composed of several substances of known safety, but as a novel entity, the safety of which needs to be evaluated as a whole.

Double- or multi-trait stacked crops are becoming more and more common (Clive, 2013). These are obtained either through more than

one trait being inserted into one crop, or through cross-breeding of two or more GM crops (ISAAA, 2013). Many food regulators do not require any studies to be done on crops containing several stacked genes if all the genes in the stack have previously been individually approved for use in the same kind of plant (EFSA, 2010; FSANZ, 2010). However, the effect of two or more traits acting together is unknown. For example, two insecticidal proteins, when ingested together, may have a potentiating or synergistic effect (Schnepf et al., 1998). In real-life scenarios, animals and humans most probably consume GM material and products of various traits in a single meal. Therefore, it is suggested that long-term animal feeding studies be performed to investigate the toxicity of crops possessing more than one trait to investigate the toxicity of feed containing more than one GM component.

1.3. The importance of studying the gastrointestinal tract

The digestive tract is the first site of contact for any ingested compound. It follows that if a compound is toxic, the first signs of toxicity may be visible in the gastrointestinal (GI) tract. Furthermore, since the stomach and the intestines are the sites of longest residence for any ingested product, these should become the most important sites for the evaluation of an ingested compound's toxicity. It is difficult to assess damage to the digestive tract purely on macroscopic grounds (Morini and Grandi, 2010), therefore a histopathological analysis should be part of the investigation.

2. Methods

The purpose of this literature review was to examine the relationship between GM crops and histopathological observations in rats. The search only included crops possessing one or more of three specific traits which are commonly found in commercialised GM crops: herbicide tolerance via the *EPSPS* gene, and insect resistance via *cry1Ab* or *cry3Bb1* genes. A list of crop event names was first generated (Table 1) based on GM approval databases (CERA, 2012; FSANZ, 2011b; ISAAA, 2013) and publications, such as literature reviews (Domingo, 2007; Domingo and Bordonaba, 2011; Magaña-Gómez and De La Barca, 2009; Pusztai et al., 2003; Snell et al., 2012). The search used PubMed, Google Scholar and Embase to find studies that were published before April 2013. The search was restricted to published studies. Reports, such as EFSA reports, were not included since they do not contain detailed histopathological results. The keywords used were rat, rats, *rattus* and the specific crop event line name (Table 1). To make results comparable with each other, the search was limited to long-term rat feeding studies of no less than 90 days duration. The search excluded multigenerational studies, unless there was a histopathological investigation in the first generation of rats. No language limit was set. For non-English publications, help was obtained with their translation and accurate understanding.

3. Results

The search yielded 21 published studies (Table 2) with an additional two re-analyses of raw data of some of these studies (de Vendomois et al., 2009; Seralini et al., 2007). The re-analyses concentrated only on the blood, serum and urine test results. (These publications are not counted nor listed in the tables or figures since they are not original feeding studies). Eighteen (86%) out of the 21 studies investigated crops that have been approved for human and/or animal consumption somewhere in the world (Table 1). These 18 studies investigated only nine out of the 47 approved GM crops (19%) known to possess at least one of the traits of interest. No published rat-feeding studies could be found for the remaining 38 (81%) approved crops. Of all the 21 studies found, 12 (57%) generally assessed the long-term effect of GM feed on rat health (Hammond et al., 2004, 2006a,b; Healy et al., 2008; Qi et al., 2012; Sakamoto et al., 2007, 2008; Schröder et al., 2007; Seralini et al., 2012; Tutel'ian et al., 2008, 2010; Wang et al., 2002), whilst seven

(33%) examined specific outcomes — signs of allergic or immunological reactions (Kroghsbo et al., 2008; Teshima et al., 2000), effects of a GM diet on the blood, urine and liver (Tutel'ian et al., 1999, 2001), fate of the inserted DNA (Zhu et al., 2004), comparison of GM soy versus conventional soy and its nutritional impact (Daleprane et al., 2009), and the impact of a soy diet, be it GM or non-GM, on aortic wall remodelling (Daleprane et al., 2010).

The majority of the studies found were published in the last decade (Figs. 1 and 2). The earliest study was published in 1995, which was of a GM tomato that was probably never commercially grown (Noteborn et al., 1995). The study investigated the effect of the insecticidal protein cry1Ab, on its own or in the GM tomato, on various mammalian digestive systems. However, at the time of publication, the researchers had not yet performed a histopathological analysis of the effect of the GM crop on rat health.

The earliest published study on an approved crop was in 1999 (Tutel'ian et al., 1999) (Fig. 2), which was four years after that crop had been approved for human and animal consumption. This study only investigated the blood, urea and the liver of animals fed GM soy. The first study that generally assessed the long-term effect of GM feed on rat health was in 2002 (Wang et al., 2002). It investigated a GM rice (KMD1) that is approved for commercial use only in China. This approval was granted seven years after the Wang et al. (2002) study was published (Chen et al., 2011). Two other studies also investigated this crop (Kroghsbo et al., 2008; Schröder et al., 2007), both of which were published prior to the approval. The remaining 16 (76%) published studies found in this review were published after the crops had been approved for human and/or animal consumption. Half of these were performed at least nine years after the approval was granted.

Five studies based their methodology on the Organisation for Economic Cooperation and Development (OECD) guidelines for the testing of chemicals — OECD Guideline 408: repeated dose 90 day oral toxicity study (OECD, 1981, 1998). Fourteen studies indicated that the digestive tract was investigated histopathologically, but no details were given as to what analyses were performed. The only details most often provided were that tissue samples were processed, paraffin embedded, and sections were cut and stained with haematoxylin and eosin (H&E). Sections were then assessed using light microscopy (LM). Seralini et al. (2012) indicated that sections were stained with HES, but failed to specify whether this abbreviation meant haematoxylin and eosin, haematoxylin eosin safran/saffron or haematoxylin erythrosine saffron stain. Seralini et al. (2012) also indicated that if any tumours were observed, they were processed for transmission electron microscopy (TEM). There was no mention if tumours were observed in the GI tract.

Six of the studies indicate that a pathologist or veterinary pathologist performed the histopathological analysis. Five studies provided some form of results of their analyses, whilst most limited their results section to a statement that overall there were no treatment-related or diagnostically-significant observations.

Overall, all the studies examining the GI tract concluded that there were no toxicological or pathological changes observed that could be related to feeding GM crops to rats.

4. Discussion

The digestive tract is the first site of contact with the body of any ingested food. Therefore, if a novel food is toxic to the body, signs of toxicity may be present in the GI tract. Often these changes may only be detectable by histopathological analysis and not macroscopic observations (Morini and Grandi, 2010).

4.1. Review of the methods

Whilst 14 out of the 21 studies reviewed (67%) indicated that organs of the digestive tract were collected for histopathological examination, none of the methods sections in these publications included any details

as to the nature of the histopathological examination. Several of the studies (Hammond et al., 2004, 2006a,b; Healy et al., 2008; Qi et al., 2012; Zhu et al., 2004) simply stated that a pathologist or veterinary pathologist performed the analysis, but no mention was given as to what these analyses entailed, for example what pathological parameters were used or what was measured and why. The exception appears to be a study by Teshima et al. (2000) who stated that the morphology of the small intestine mucosa was assessed, in particular the composition of goblet cells and intraepithelial lymphocytes. According to the authors, the analysis was based on a chapter in an immunotoxicology textbook (Kawabata, 1996). However, that chapter did not mention the purpose or even how the investigation of the small intestine should appear. In particular, it did not include the definition of what constitutes abnormal or diseased, such as, what changes in goblet cell population would indicate a pathology.

A paper that appears to be well-structured and thorough was the Tutel'ian et al. (2008) study published in Russian. The methods section clearly stated that the morphometric analysis of the internal organs was conducted according to textbook guidelines (Avtandilov, 1982, 1990) and results were compared according to guidelines set out by Stefanov (1985). The two Russian textbooks (Avtandilov, 1982, 1990) are manuals on how to conduct quantitative research to obtain a meaningful assessment of morphological changes. In other words, the Tutel'ian et al. (2008) study appears to be thorough and well set out, especially since detailed results are provided for the analyses. However, the publication lacks basic information. It does not specify the number of rats used in the study and it does not list which organs were collected for the histopathological analyses. Results seem to imply that the ileum was the only section of the GI tract to be analysed. A more thorough study would have investigated other sections of the GI tract to more accurately ensure that the GM crop did not have any adverse effects.

Another Russian study (Tutel'ian et al., 2010) also appears to be properly conducted. Its safety assessment is based on the Tutel'ian et al. (2008) study, which implies that the same rigorous morphometric analysis was also utilised. However, even this publication lacks key information. For example, the paper indicated that the morphometric analysis was conducted on the small intestine and colon, but results were only reported for the small intestine. In addition, the publication does not specify which section of the small intestine these results pertain to. This lack of detail in both Russian papers makes it difficult to determine the veracity of the results. It also makes it difficult to reproduce and further the study or to compare these studies to others. Indeed, in all the published papers, a lack of uniformity in the analytical approach as well as documentation of the methods and results makes any comparison or assessment of adequacy or inadequacy of the studies difficult.

4.2. Selection of endpoints

A major flaw in all the studies reviewed was the lack of any definition of toxicity or signs of pathology. Of all the studies generally assessing rat health on a GM diet, not one explained how the study would adequately show that the crop is safe for human and/or animal consumption. Furthermore, all the studies reviewed failed to justify or give reason for the choice of methods used. Yet, most studies concluded that the investigation did not reveal any meaningful differences between animals fed the GM or non-GM feed. One study even stated that “since no meaningful differences were observed, no further microscopic examinations were deemed necessary” (Hammond et al., 2004). However, the absence of meaningful differences in a preliminary investigation does not mean that further analysis would not find meaningful differences. In addition, the authors did not support this statement with proof since they provided few details as to what their microscopic examinations entailed or found. Therefore, they give very little evidence that their study adequately assessed the safety of consuming the GM crop.

Another common remark in these publications was that all changes observed were not diagnostically significant, were within the normal range, or are common to this strain and age of rat. The six studies that

made this remark gave little evidence to support this conclusion (Hammond et al., 2004, 2006a,b; Healy et al., 2008; Qi et al., 2012; Teshima et al., 2000). Most gave no evidence at all. For example, Qi et al.

Table 1
Literature search: list of GM crop event names that were used in the search for published studies. Year of approval for animal and/or human consumption of each event name and number of publications found per event.

Crop type	Event name (other name and/or code name) ^{a,b}	Number of published long-term rat feeding studies	Year approved for food and/or feed ^c
Roundup Ready (RR) or glyphosate-tolerant crops:			
<i>Crops containing EPSPS genes</i>			
Alfalfa/Lucerne	J101 (MON-00101-8)	0	2004
	J163 (MON-00163-7)	0	2004
Canola	GT200 (RT200, MON89249-2)	0	1997
	GT73 (RT73, MON737)	0	1994
	MON88302 (MON-88302-9)	0	2012
	ZSR500 (ZSR500 x GT73)	0	1997
	ZSR502 (ZSR502 x GT73)	0	1997
	ZSR503 (ZSR503 x GT73)	0	1997
Corn/Maize	GA21 (MON00021-9)	1 ^d	2000
	HCEM485	0	2012
	NK603 (MON-00603-6)	2	2000
	MON832	0	1996
	MON87427 (MON-87427-7)	0	2012
Cotton	GHB614 (BCS-GH205)	0	2008
	MON1445 (MON1445-2)	0	1995
	MON1698 (MON89383-1)	0	1995
	MON88913 (MON88913-8)	0	2005
Creeping bentgrass	ASR368 (SGM-36800-2) ^e	0	2003
Potato	RBMT22-082 (RBMT22-82, NMK-89896-6)	0	1998
	RBMT22-186	0	1998
	RBMT22-238	0	1998
	RBMT22-262	0	1998
Soybean	40-3-2 (GTS 40-3-2, MON04032-6)	4	1995
	FG-72 (MST-FG072-2)	0	2012
	MON87705 (MON87705-6)	0	2011
	MON87708 (MON87708-9)	0	2011
	MON87769	0	2011
	MON89788 (MON89788-1)	1 ^f	2007
	Glyphosate-tolerant ^g	3 ^g	NA
	305423 x 40-3-2 (DP305423 x GTS40-3-2, DP-305423-1 x MON-04032-6) ^b	1	2010
Sugar beet	GTS B77 (T9100152, SY-GTSB-77-8)	0	1998
	H7-1 (KM71-4)	0	2003
Wheat	MON71800 (MON-71800-3)	0	2004
Insect resistant or Bt crops:			
<i>Crops containing Cry3Bb1 and EPSPS genes</i>			
Corn/Maize	MON88017 (MON-88017-3) ^h	2 ^h	1996
<i>Crops containing Cry3Bb1 genes</i>			
Corn/Maize	MON863 (MON-00863-5)	1	2001
<i>Crops containing Cry1Ab genes</i>			
Corn/Maize	5307 (SYN-05307-1)	0	2012
	Bt10	0	1995
	Bt11 (x 4334CBR, x 4634CBR, SYN-Bt011-1)	0	1996
	Bt176 (176, SYN-EV176-9)	0	1995
Cotton	COT67B (IR67B, SYN-IR67B-1,)	0	2009
	GFM Cry1A (GTL-GFM311-7)	0	Cultivation only (2006)
	GK12	0	Cultivation only (1997)
	T303-3 (BCS-GH003-6)	0	Cultivation only (2012)
	T304-40 (BCS-GH004-7)	0	2010
Rice	Tarom molaii + cry1ab	0	2004
	KMD 1 rice (Kemengdao 1, TR30)	3	2009
	GM Shanyou 63	0	2009
	Hauhui-1/TT51-1	0	Cultivation only (2009)
Tomato	RLE13-0009 ⁱ	1	No approval info. ⁱ
	RLE6-1000 ⁱ	0	No approval info. ⁱ
<i>Crops containing Cry1Ab and EPSPS genes</i>			
Corn/Maize	MON801 (MON80100)	0	1996
	MON802 (MON-80200-7)	0	1997
	MON809 (PH-MON-809)	0	1996
	MON810 (MON-00810-6)	2 ^d	1996
	Number of GM crop event lines studied	10 ^{f,h}	9 approved
	Total number of GM crop event lines	53 ^{f,h}	47 approved
	Total number of published studies found	21	19 approved

(2012) referenced a study by Tang et al. (2012) to support their notion that “microscopic observations occurred spontaneously in Sprague–Dawley rats of this age.” However, the referenced study made no mention of microscopic observations occurring spontaneously and the study did not even use Sprague–Dawley rats.

A very common statement found in the reviewed studies was that since the lesions or changes were observed in both groups, they were not deemed to be diet-related (Healy et al., 2008; Sakamoto et al., 2007, 2008; Wang et al., 2002). For example, in two studies (Hammond et al., 2006b; Sakamoto et al., 2007), there was a brief mention of gastric gland dilatations being observed in both the GM and non-GM fed groups. Gland dilatations can occur in aged rats (Frantz et al., 1991), but they can also be a pathological occurrence for example in alendronate-induced injury (Şener et al., 2004), ulcer healing (Tarnawski et al., 1991) or underlying neoplastic lesions (Frantz et al., 1991). In these pathologies, the dilatations are large, they may sometimes extend into the submucosa and they may become dysplastic (Kikuchi et al., 2010). In the two publications (Hammond et al., 2006b; Sakamoto et al., 2007), no specific details are mentioned, for example, the size of these dilatations, whether the treatment group had larger dilatations than the other group, whether the affected area was more widespread in one group than the other, or if the cells lining the dilatations had a specific staining property or shape common only to one group. If a pathology is seen, regardless of whether it occurs in both groups, further analysis should be performed to determine the nature of the occurrence and to completely rule-out disease. Furthermore, whilst the incidence of a pathology may be equal in both groups, the degree or severity may vary. Therefore, it is always important to record and report the severity of a pathology. For example, an animal may be prone to a certain pathology (e.g. Sprague–Dawley rats are known to spontaneously develop certain neoplastic lesions) (Chandra et al., 1992; Kaspereit and Rittinghausen, 1999), but it is possible that the GM component may increase the severity or risk of this development. In addition, the type of crop fed may cause a pathology. For example, soy is known to have adverse effects on bone and the digestive tract (Godlewski et al., 2006; Piastowska-Ciesielska and Gralak, 2010). Therefore, feeding soy would naturally cause changes to the gut, but the GM component may increase the severity of these changes. Hence, detailed histopathological and morphometric analyses are needed to completely rule out the GM crops' involvement in the development of the lesion or pathological condition. In other words, it is not sufficient to say that the GM food is safe if incidences of a pathology or lesion are equal in both groups. Further testing should be carried out to completely rule out the GM component's involvement in the development of the pathological incidence(s).

Another common conclusion made was that no changes were seen that could be considered treatment, test-article, or test-substance related, or toxicologically relevant. However, the six studies that made this conclusion did not define treatment-related or toxicologically relevant. (Hammond et al., 2006a,b; Healy et al., 2008; Qi et al., 2012; Wang et al., 2002; Zhu et al., 2004). Therefore, they did not provide clearly defined criteria by which to judge if a given tissue was normal or not, and

if abnormal, whether the abnormality was toxicologically relevant and/or treatment-related. Some food regulators, such as Food Standards Australia New Zealand (FSANZ, 2007) describe GM food as novel food. In other words, they recognise that no definition yet exists for toxicologically relevant or test-substance related changes. However, by applying the test for substantial equivalence, food regulators argue that an existing compound or plant of known toxicity can be used to evaluate or predict the action of a novel compound or food such as a GM crop (FSANZ, 2007; König et al., 2004; Kuiper and Kleter, 2003). If so, defining what is toxicologically relevant or test-substance related should be a simple task. Consequently, the published studies should have been able to supply the definition and evidence that the results showed no treatment-related or toxicologically relevant changes.

If an existing compound can't predict the action of a GM crop on animal health, further investigation would be necessary. Known toxicity of single components of the GM crop may not define an overall toxicity of the entire crop. It is not clear whether the test for substantial equivalence is sufficient because it does not take into account the changes that could arise from the transformation process: (1) through the random insertion of the genes, (2) through the genetic alterations made to the transferred genes as a result of the transformation process, (3) through the genetic alterations made to the plant as a result of the transformation process (Wilson et al., 2006), (4) through the insertion of several traits or genes into one crop or (5) through the alteration made to the genes encoding the desired trait prior to the transformation.

4.3. Lack of transparency in results

Several of the reviewed publications do not adequately report their results. Some do not even provide any results (Table 2). For example, the paper by Zhu et al. (2004) not only lacks a detailed methods section, but also limits its histopathological results to a simple statement that “although some slight lesions (such as slightly dilated alveolus cavity, pelvic dilation of the kidneys, slight disconnection of myocardial fibre and collapse of jejunum villi) occurred in rats examined, they were not treatment related.” Such a statement could imply that other changes may have been observed, but are not reported. Furthermore, this study does not mention the incidence or severity of any histopathological changes, including whether they occurred in the treatment or non-treatment group. For example, they do not state how many rats showed collapsed jejunum villi and whether these were more prevalent in one group or whether the collapsed villi were more severe in one group. A lack of transparency in results does not allow other researchers to judge whether a certain finding is pathologically relevant. Another paper (Tutel'ian et al., 2010) indicated that they had performed a morphometric analysis of the small and large intestines, but they did not report the colon results. A lack of transparency is also evident in two other studies: 1) Hammond et al. (2004) report the findings from “only those tissues with an incidence of 2 or more findings”; and 2) Healy et al. (2008) state that “findings in

Notes to Table 1

- ^a Each line contains one crop. Succeeding names are the other names given to the crop event name and/or the crop's code name.
- ^b GM crop hybrids are not listed in the table, unless the crop is listed in databases as a single event name. An exception is the GM soybean line 305423 × 40-3-2, since a feeding study publication was found during the search for publications.
- ^c The year that the crop was first approved somewhere in the world for human and/or animal consumption.
- ^d One publication contained results for two feeding studies — one on MON810 corn and the other on GA21 corn. As these are two separate feeding studies they have been counted as two published studies.
- ^e ASR368 creeping bentgrass is solely intended for the production of turfgrass in golf courses, but it can be used as livestock feed (CERA, 2012).
- ^f One study generating two published reports. The first reported the results for the analysis of morphological, haematological, and biochemical parameters and system biomarkers (Tutel'ian et al., 2010). The second reported the allergenic potential and immunoreactivity, as well as looked for signs of genotoxicity (Tyshko et al., 2010). Since the reports are of the same study, they have been counted as one published study.
- ^g The GM crop or event name was not listed in three publications. The GM crop studied contained the *EPSPS* gene, which confers glyphosate tolerance. This was not counted as a separate event line in the final number of GM crop event lines studied nor in the total number of GM crop event lines.
- ^h One study generating two published reports. The first reported the results for the analysis of morphological, haematological, and biochemical parameters and system biomarkers (Tutel'ian et al., 2008). The second reported the allergenic potential and immunoreactivity, as well as looked for signs of genotoxicity (Tyshko et al., 2008). Since the reports are of the same study, they have been counted as one published study.
- ⁱ The Bt tomatoes may never have been released. The feeding study by Noteborn et al. (1995) looked at the effect of only RLE13-0009 on the rat. The effect of RLE6-10001 was not investigated in the rat, but in other laboratory animals.

Table 2
Summary of published studies in order of trait and publication date.

Study	GM component (event or crop name)	Duration	Purpose of study	No. of rats/treatment group	Histopathology performed and analysis of GI tract	Histopathological results for GI tract	Feeding study guidelines
<i>EPSPS</i>							
Tutel'ian et al. (1999)	1.25 g/rat/day of GM soy (RR soy)	5 months	To investigate the blood, urea and liver of animals fed GM soy	Not stated	No histopathology performed	NA	
Teshima et al. (2000)	30% GM soy	15 weeks	Study of the immune system of rats and mice	5	Payer's patches collected for histopathology, specific area of the small intestine not mentioned. Histopathological examination of H&E stained sections assessed structure of crypt and composition of cells (especially goblet cells and intraepithelial lymphocytes) according to Kawabata (1996). However, Kawabata did not contain guidelines as to how this assessment should be performed and what observations would be considered to be abnormal. No other details were provided as to how the histopath. assessment/analysis was performed.	No difference of crypt structure or goblet cell frequency. Results for intraepithelial lymphocytes were not stated. No actual data of any analyses were shown. Conclusion: No diagnostically significant abnormalities observed in the mucosa of the small intestine.	
Tutel'ian et al. (2001)	3 g/rat/day of GM corn (GA21)	6 months	To investigate the blood, urea and liver of animals fed GM corn GA21 or GM corn MON810	Not stated	No histopathology performed	NA	
Zhu et al. (2004)	30–90% GM soy (RR soy)	13 weeks	Nutritional assessment and fate of DNA	10	Stomach and intestine collected for histopathology. Sections stained with H&E and examined by board-certified pathologist using LM. However, no details were given as to what histopath. analyses were performed.	Collapse of jejunum villi was observed, but actual incidence, including incidence in treatment and/or non-treatment group is not reported. No actual data of any analyses were shown. Conclusion: No treatment related differences seen.	
Hammond et al. (2004)	11–33% GM corn (NK603)	13 weeks	General study to assess the effect of the GM corn on rat health	20	Stomach, duodenum, jejunum, ileum, colon, and rectum collected for histopathology. Sections stained with H&E and examined by a board-certified pathologist using LM. However, no details were given as to what histopath. analyses were performed.	Incidence of microscopic findings was only listed for those tissues with an incidence of 2 or more findings. No mention of any GI tract observations. Conclusion: According to the examining pathologist, appearance of tissue was within normal limits. Microscopic changes observed were those that are typically seen in rats of this age and strain.	Modified from OECD 408 (1981)
Sakamoto et al. (2007)	30% GM soy (RR soy)	26 and 52 weeks	General study to assess the effect of the GM soy on rat health	10	Stomach and intestines collected for histopathology. Sections stained with H&E. However, no details were given as to what histopath. analyses were performed. The method used for the eosinophil and goblet cell counts in the jejunum was described in a table caption.	Pathological findings showed no meaningful differences between rats fed GM or non-GM soybeans. Relatively detailed results given for histological findings including eosinophil and goblet cell counts for jejunum. Gastric gland, dilatation of slight grade was observed in all groups. Conclusion: No obvious differences observed between GM and non-GM fed rats.	
Sakamoto et al. (2008)	30% GM soy (RR soy)	52 and 104 weeks	General study to assess the effect of the GM soy on rat health	50	Stomach and intestines collected for histopathology. Sections stained with H&E. However, no details were given as to what histopath. analyses were performed.	Detailed results given of the incidence of neoplastic and non-neoplastic lesions observed. No incidence or increase in incidence of any specific type of neoplastic or non-neoplastic lesions in GM fed group in both genders and there were no lesions reported in the GI tract. Conclusion: No meaningful differences between rats fed GM and non-GM soy.	
Daleprane et al. (2009)	10% GM soy	15 months (455 days)	Nutritional study – study of growth and haematology of rats on GM soy, non-GM soy or conventional diet	10	No histology performed	NA	

Daleprane et al. (2010)	10% GM soy	15 months (455 days)	Health of the aorta of rats on GM soy, non-GM soy or conventional diet	10	Histology of the aorta	NA	
Tutel'ian et al. (2010)	38% GM soy (MON89788)	30 and 180 days	General study to assess the effect of the GM soy on rat health	50	Safety of the GM crop was examined as in Tutel'ian et al. (2008). Review of macro- and microscopic examinations according to textbook guidelines (Lillie, 1969). Morphometric analysis of the small intestine and colon performed with the aid of computer programme AxioVision. No other information was provided as to what other organs were collected and what histopath. analyses were performed.	Detailed results were given of morphometric analysis of the small intestine, but which section of the small intestine these results pertain to, was not mentioned. No results given for morphometric analysis of the colon. Conclusion: Morphological analysis did not reveal toxic effect of GM soy.	
Seralini et al. (2012)	11%, 22% and 30% GM corn (NK603)	2 years	General study to assess the effect of the GM corn on rat health	10	Oesophagus, stomach, duodenum, jejunum, ileum, Payer's patches, and colon collected for histopathology. Sections stained with HES. However, no details of what histopath. analyses were performed.	Results for histopathological analysis of GI tract were not provided.	
Qi et al. (2012)	7.5%, 15% and 30% GM soy (305423 × 40-3-2)	90 days	General study to assess the effect of the GM soy on rat health	10	Stomach, duodenum, jejunum, and ileum collected for histopathology. Sections stained with H&E and examined by a pathologist from the Chinese Academy of Medical Sciences. However, no details of what histopath. analyses were performed.	No observations or results listed for GI tract. Conclusion: No test-substance related observations.	
Cry3Bb1 and EPSPS Healy et al. (2008)	11–33% GM corn (MON88017)	13 weeks	General study to assess the effect of the GM corn on rat health	20	Stomach, duodenum, jejunum, ileum, colon, and rectum collected for histopathology. Sections stained with H&E and examined by board-certified veterinary pathologist using LM. However, no details of what histopath. analyses were performed.	Results table provided with microscopic findings, however findings for tissues that had an incidence of 1/20 were not reported. No mention of any GI tract results/observations. Conclusion: No test-article related lesions.	Modified from OECD 408 (1998)
Tutel'ian et al. (2008)	11 g/rat/day of GM corn (MON88017)	30 and 180 days	General study to assess the effect of the GM corn on rat health	Not stated	Review of macro- and microscopic examinations according to textbook guidelines (Lillie, 1969) with the morphometric analyses performed on the internal organs according to Avtandilov (1982, 1990) and Stefanov (1985). List of organs collected for histopath. analysis was not provided.	Detailed results are given of morphometric analysis of ileum. No mention of results for any other area of the GI tract. Conclusion: Morphological analysis did not confirm any toxic effect of GM corn.	
Cry3Bb1 Hammond et al. (2006b)	11–33% GM corn (MON863)	90 days	General study to assess the effect of the GM corn on rat health	20	Stomach, duodenum, jejunum, ileum, colon, and rectum collected for histopathology. Histopath. examination was performed by a pathologist at Covance laboratories. However, no details were provided as to what histopath. methods were used including what stains were used and what analyses were performed.	Parasitism was observed in the rectum and glandular dilatation was observed in the stomach of animals in both GM and non-GM groups. The severity/degree of the parasitism or glandular dilatation was not mentioned. Conclusion: Differences if seen were not considered to be test article related.	Modified from OECD 408 (1981)
Cry1Ab Noteborn et al. (1995)	10% GM tomato (RLE13-0009)	91 days	Study to see if the Cry1Ab protein on its own or in the GM tomato acts on mammals in a similar way as on target insect guts	12	Histological analysis was still in progress at the time of publication.	NA	
Tutel'ian et al. (2001)	3 g/rat/day GM corn (MON810)	6 months	To investigate the blood, urea and liver of animals fed GM corn GA21 or GM corn MON810	Not stated	No histopathology performed	NA	
Wang et al. (2002)	19–64% GM rice (KMD1)	14 weeks (90 days)	General study to assess the effect of the GM rice on rat health	20	Stomach, duodenum, jejunum, ileum, colon, and rectum collected for histopathology. Sections were stained with H&E. However, no details of what histopath. analyses were performed.	No mention of any GI tract observations. Conclusion: No toxicologically relevant changes.	

Table 2 (continued)

Study	GM component (event or crop name)	Duration	Purpose of study	No. of rats/treatment group	Histopathology performed and analysis of GI tract	Histopathological results for GI tract	Feeding study guidelines
Hammond et al. (2006a)	11–33% GM corn (MON810)	90 days	General study to assess the effect of the GM rice on rat health	20	Methods section indicates that histopathological examination was performed in the same manner as Hammond et al. (2004). No other details provided. Stomach (fore and glandular), duodenum, jejunum, ileum, caecum, colon, and rectum collected for histopathology. Sections stained with H&E. "Main focus of histopathological examination was on intestinal tract and related organs", but no specific details given as to the type of analyses performed. No histopathology performed	No mention of any GI tract observations. Conclusion: No treatment-related observations.	Modified from OECD 408 (1981)
Schröder et al. (2007)	60% GM rice (KMD1)	90 days	General study to assess the effect of the GM rice on rat health	16 (10 used in histopath. examination)		No mention of any pathological findings in the GI tract. Conclusion: No dose-related changes were observed in the intestinal tract and related organs.	OECD 408 (1981) with modifications ^a
Krogsho et al. (2008)	60% GM rice (KMD1)	28 and 90 day	Immuno study	10		NA	

^a Modifications from Consultation Meeting of Experts on Sub-chronic and Chronic Toxicity Testing (1995).

other tissues with an incidence of 1/20 are not reported." Neither of these papers provided a full account of pathologies present. Furthermore, Hammond et al. (2004) do not clearly state whether "incidence" pertains to two incidences per tissue or per rat. Such a lack of information does not ensure that the study and its results are reproducible or even comparable.

4.4. Relevance of OECD guidelines in the evaluation of the safety of consuming GM crops

Five of the published studies indicate that OECD 408 guidelines were used to assist in planning the study (Table 2). The OECD 408 guidelines are designed to test for carcinogenicity of compounds. The guidelines provide details on how such a feeding study should be conducted, including information on sample size, duration etc. However, the guidelines do not specify the histopathological analysis that should be performed. For example, what histopathological parameters should be used to detect or measure the carcinogenicity of a compound. Whilst it's our view that histopathological methods to determine carcinogenicity are well established in the scientific community, the effect of GM feed on animal health is not. In addition, the carcinogenic potential of a GM crop is not, and should not be, the only pathology investigated. Therefore, there is a question as to whether these OECD guidelines are relevant to investigation of the safety of consuming GM crops. Whilst they may be used as a starting point, it is our view that guidelines should be established specifically for GM crops. Since GM food is considered to be a novel food, the guidelines should list details for a thorough investigation that includes a histopathological analysis of the gut and other organs. In other models of GI tract damage, such as mucositis (Howarth et al., 1996; Logan et al., 2009; Sukhotnik et al., 2008), neonatal adjustment of piglets to normal diet (Godlewski et al., 2009; Strzalkowski et al., 2007), or in gastric biopsies (Fenoglio-Preiser, 1998; Staibano et al., 2002), the analytical method is detailed and specific, listing the changes that need to be investigated and the microscopic techniques and morphometric analyses that need to be used. For example, mitosis, apoptosis and autophagy are known to be good indicators of mucosal regeneration in the small intestine following injury. Therefore, immunohistochemistry with in-tissue cytometry looking at the expression of markers for mitosis (Ki67), apoptosis (caspase 3) and autophagy (MAP 1 LC3) can be used to assess mucosal regeneration (Godlewski et al., 2009). In mucositis-induced models, the investigation of the degree of damage regularly requires not only detailed quantitative histological analyses to be conducted (Howarth et al., 1996; Logan et al., 2009; Sukhotnik et al., 2008), but also immunohistochemistry for markers of apoptosis (caspase 3), cell proliferation (BrdU) (Sukhotnik et al., 2008), and pro-inflammatory cytokines (such as TNF, IL-1 β and IL-6) (Logan et al., 2009). Such vigorous analyses allow for a more precise assessment of possible pathological changes, whilst at the same time decreasing the chance of subtle changes being overlooked. Therefore, it is our view that in the investigation of the safety of GM crops on animal and human health, such a vigorous and in-depth approach should also be implemented.

4.5. Have enough studies been conducted to adequately state that GM crops are safe for human and animal consumption?

Genetically modified crops have been approved for human and animal consumption for nearly 20 years (Clive and Krattiger, 1996) yet the debate about their safety continues. Fifty-three crops are known to possess at least one of the genes investigated in this review (herbicide tolerance via the *EPSPS* gene and insect resistance via the *cry1Ab* or *cry3Bb1* genes). Forty-seven of these crops have been approved for animal and/or human consumption, yet published toxicity studies could be found for only nine of these crops (19%) (Table 1). Of greater concern is that for eight of these crops, publications appeared after the crop had been approved for human and/or animal consumption. We understand that other studies may exist that are commercial in confidence, but these

Number of published feeding studies and number of event lines approved for food and/or feed per year

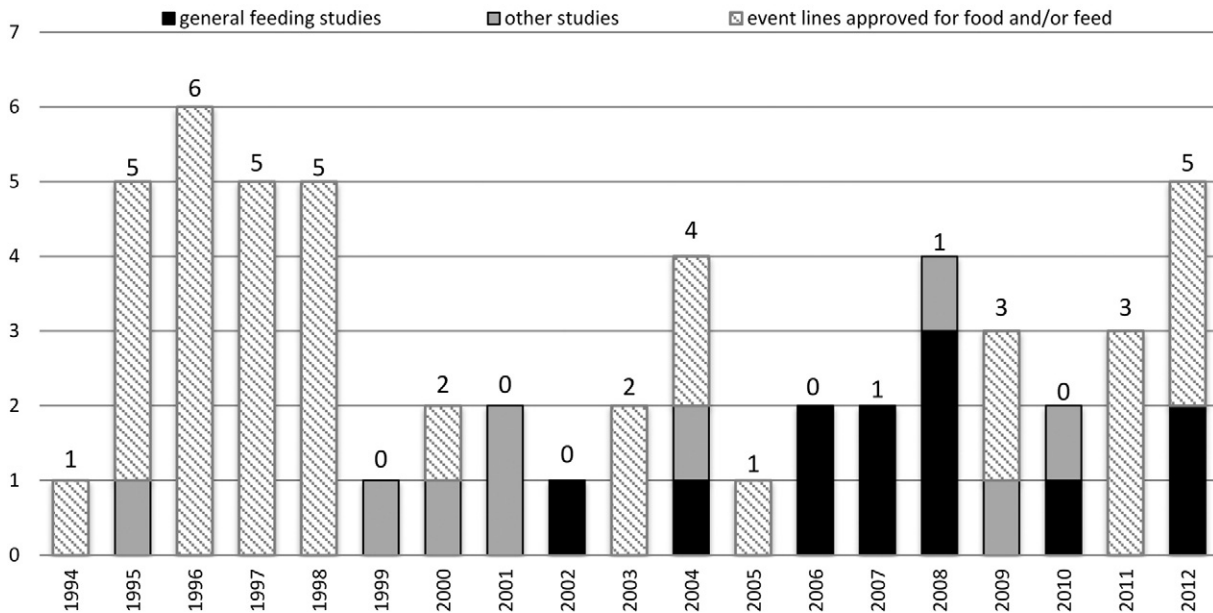


Fig. 1. Number of publications looking at the effects of feeding rats GM crops long-term and number of event lines approved each year for human and/or animal consumption. Studies researched the effects of ingesting GM crops that possessed the traits for herbicide tolerance (via the *EPSPS* gene) and insect resistance (via the *cry1Ab* or *cry3Bb1* genes). Studies investigating the general long-term effect of GM feed on rat health are indicated in black. Other studies investigating certain specific effect of GM feed on rats are indicated in grey. Striped bars indicate the number of GM crop event lines possessing the traits for herbicide tolerance (via the *EPSPS* gene) and insect resistance (via the *cry1Ab* or *cry3Bb1* genes) that were approved each year somewhere in the world for human and/or animal consumption. The number of approvals per year is shown as the number above the bar. The year of approval for each event line is only counted once, being the first time the crop was approved somewhere in the world.

studies are not accessible to the scientific community. Other than the few studies mentioned in the EFSA reports, where histopathological results were not reported, our review of the published literature wasn't able to identify or locate any reported safety evaluations performed on rats on these eight crops prior to their approval. Our literature review

also did not identify or locate published reports on rats for the remaining 38 crops.

The present review limited the search to only include feeding studies done on rats so that the results may be comparable. It is possible that more studies may be found if the search were to be extended to other

Number of event lines approved vs number of these event lines with published studies

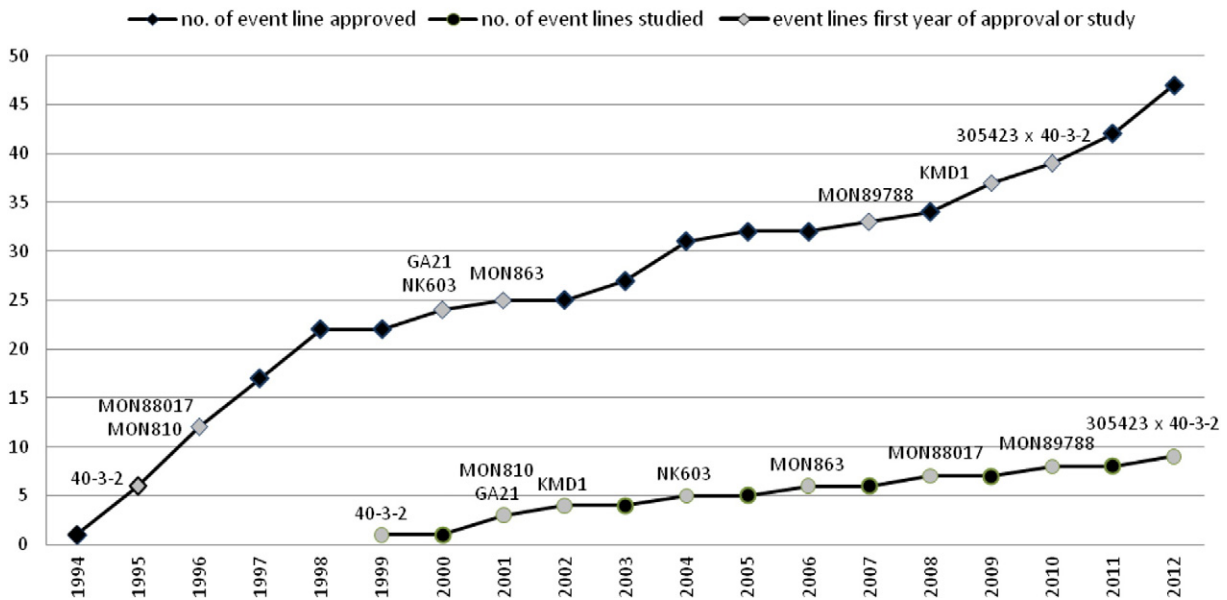


Fig. 2. The number of approved GM crops in the world for human and/or animal consumption (◆) and the number of approved GM crop lines with published studies investigating the effects of long-term feeding of these crops (●). Each crop was counted once when the first study appeared investigating that crop. The year of approval is the year that the crop was first approved somewhere in the world.

animals. However, based on what has been found for rat studies, it is unlikely that any additional studies would involve a thorough safety investigation and a detailed report of all of the 47 approved GM crops possessing one or more of the three traits. Moreover, the rat model is the accepted OECD standard for toxicological studies of this type.

Whilst the safety of a GM crop is primarily and sometimes solely evaluated by government food regulators using the test for substantial equivalence, this is likely to be inadequate to fully assess the safety of the crop for reasons stated above. Animal feeding studies provide a more thorough method of investigating the unintended effects of the GM process or the unintended effects of ingesting GM crop components. Animal feeding studies can identify target organs as well as predict the chronic toxic effect of an ingested compound (OECD, 2008).

5. Conclusions

The evidence reviewed here demonstrates an incomplete picture regarding the toxicity (and safety) of GM crops consumed by humans and animals. The majority of studies reviewed lacked a unified approach and transparency in their methodology and results, making it impossible to properly review or repeat these studies. Furthermore, such lack of detail makes it difficult to generate evidence-based guidelines to aid in the delivery of an optimum safety assessment process for GM crops for animal and human consumption.

When considering how a better risk assessment could be done, it is important to consider systems established for other novel substances that may generate unintended effects. For example, the registration of pharmaceutical products requires an examination of both benefits and risks associated with their use and a complete assessment of those benefits and risks to establish whether the products are appropriate for general use at a range of doses. We argue that each GM crop should be assessed using similar methods, where a GM crop is tested in the form and at the rates it will be consumed by animals and people.

Whilst this provides for an effective general approach, there are additional issues for assessing GM crops that need to be taken into account. For example, the process of developing GM crops may generate unintended effects. Furthermore, the plant developed is a novel entity with genes, regulatory sequences and proteins that interact in complex ways. Therefore, the resultant plant should be assessed as a whole so that any pleiotropic effects can also be assessed. As a result, long-term animal feeding studies should be included in risk assessments of GM crops, together with thorough histopathological investigations using a variety of methods to better detect subtle changes or the beginning or presence of pathologies. Such robust and detailed studies will then make it possible to put evidence-based guidelines in place, which will substantially help to determine the safety of GM crops for human and animal consumption.

Acknowledgements

We thank N Shinoda and P Ho for their help with publications in Japanese, as well as HB Zdziarska and JB Bierla for their help with publications in Russian.

We thank M Draper for his assistance in formulating detailed automated searches in PubMed and Embase.

We thank RJ Gibson and P Keane for proofreading drafts.

References

- Altpeter F, Baisakh N, Beachy R, Bock R, Capell T, Christou P, et al. Particle bombardment and the genetic enhancement of crops: myths and realities. *Mol Breed* 2005;15:305–27.
- Avtandilov GG. [Introduction to quantifying pathological morphology] *Medicine, Moscow*; 1982 (in Russian).
- Avtandilov GG. [Medical morphometry. Manual] *Medicine, Moscow*; 1990 (in Russian).
- CERA. GM crop database. Washington D.C.: Center for Environmental Risk Assessment (CERA). ILSI Research Foundation; 2012 [http://cera-gmc.org/index.php?action=gmc_crop_database].
- Chandra M, Riley MI, Johnson D. Spontaneous neoplasms in aged Sprague–Dawley rats. *Arch Toxicol* 1992;66:496–502.
- Chen M, Shelton A, Ye GY. Insect-resistant genetically modified rice in China: from research to commercialization. *Annu Rev Entomol* 2011;56:81–101.
- Christou P. Genetic transformation of crop plants using microprojectile bombardment. *Plant J* 1992;2:275–81.
- Christou P, McCabe DE, Swain WF. Stable transformation of soybean callus by DNA-coated gold particles. *Plant Physiol* 1988;87:671–4.
- Clive J. Global status of commercialized biotech/GM crops: 2013. ISAAA brief No. 46. Ithaca: ISAAA; 2013.
- Clive J, Krattiger AF. Global review of the field testing and commercialization of transgenic plants, 1986 to 1995: the first decade of crop biotechnology. Ithaca: ISAAA; 1996.
- Dai S, Zheng P, Marmey P, Zhang S, Tian W, Chen S, et al. Comparative analysis of transgenic rice plants obtained by *Agrobacterium*-mediated transformation and particle bombardment. *Mol Breed* 2001;7:25–33.
- Daleprane JB, Feijó TS, Boaventura GT. Organic and genetically modified soybean diets: consequences in growth and in hematological indicators of aged rats. *Plant Foods Hum Nutr* 2009;64:1–5.
- Daleprane JB, Chagas MA, Vellarde GC, Ramos CF, Boaventura GT. The impact of non- and genetically modified soybean diets in aorta wall remodeling. *J Food Sci* 2010;75:T126–31.
- de Vendomois JS, Roullier F, Cellier D, Seralini GE. A comparison of the effects of three GM corn varieties on mammalian health. *Int J Biol Sci* 2009;5:706–26.
- Domingo JL. Health risk of GM foods: many options but few data. *Science* 2000;288:1748–9.
- Domingo JL. Toxicity studies of genetically modified plants: a review of the published literature. *Crit Rev Food Sci Nutr* 2007;47:721–33.
- Domingo JL, Bordonaba JG. A literature review on the safety assessment of genetically modified plants. *Environ Int* 2011;37:734–42.
- EFSA (European Food Safety Agency). Opinion of the scientific panel on genetically modified organisms on application (reference EFSA-GMO-NL-2006-36) for the placing on the market of the glyphosate-tolerant genetically modified soybean MON89788, for food and feed uses, import and processing under regulation (EC) no 1829/2003 from Monsanto. *EFSA J* 2008;758:1–23.
- EFSA (European Food Safety Agency). Scientific opinion on application (EFSA-GMO-CZ-2008-62) for the placing on the market of insect resistant and herbicide tolerant genetically modified maize MON 89034 × 1507 × MON 88017 × 59122 and all sub-combinations of the individual events as present in its segregating progeny, for food and feed uses, import and processing under regulation (EC) no 1829/2003 from Dow AgroSciences and Monsanto. *EFSA J* 2010;8(1781). [1737 pp.].
- FAO/WHO (Food and Agricultural Organisation of the United Nations/World Health Organisation). Safety aspects of genetically modified foods of plant origin. Report of a joint FAO/WHO expert consultation on foods derived from biotechnology (29 May–2 June, 2000). Geneva; 2000.
- Fenoglio-Preiser C. Creating a framework for diagnosing the benign gastric biopsy. *Curr Diagn Pathol* 1998;5:2–6.
- Frantz J, Betton G, Cartwright M, Crissman J, Macklin A, Maronpot R. Proliferative lesions of the non-glandular and glandular stomach in rats. *Guides for toxicologic pathology*. Washington: STP/ARP/AFIP; 1991.
- FSANZ (Food Standards Australia New Zealand). The role of animal feeding studies in the safety assessment of genetically modified foods. Report of a workshop hosted by Food Standards Australia New Zealand (Friday 15th June 2007). Canberra: FSANZ; 2007.
- FSANZ (Food Standards Australia New Zealand). Food derived from GM plants containing stacked genes. <http://www.foodstandards.gov.au/consumer/gmfood/stackedgene/Pages/default.aspx>, 2010.
- FSANZ (Food Standards Australia New Zealand). GM current applications and approvals. Genetically modified (GM) foods. <http://www.foodstandards.gov.au/consumerinformation/gmfoods/gmcurrentapplication1030.cfm>, 2011.
- Gasson M. The safety evaluation of genetically modified foods. In: D'Mello JPF, editor. *Food safety: contaminants and toxins*. Wallingford: CABI Publishing; 2003.
- Godlewski MM, Slazak P, Zabielski R, Piastowska A, Garlak MA. Quantitative study of soybean-induced changes in proliferation and programmed cell death in the intestinal mucosa of young rats. *J Physiol Pharmacol* 2006;57(Suppl. 7):125–33.
- Godlewski MM, Bierla JB, Strzalkowski A, Martinez-Puig D, Pajak B, Kotunia A, et al. A novel cytometric approach to study intestinal mucosa rebuilding in weaned pigs fed with dietary nucleotides. *Livest Sci* 2009;123:215–20.
- Hammond BG, Dudek R, Lemen JK, Nemeth M. Results of a 13 week safety assurance study with rats fed grain from glyphosate tolerant corn. *Food Chem Toxicol* 2004;42:1003–14.
- Hammond B, Dudek R, Lemen JK, Nemeth MA. Results of a 90-day safety assurance study with rats fed grain from corn borer-protected corn. *Food Chem Toxicol* 2006a;44:1092–9.
- Hammond B, Lemen J, Dudek R, Ward D, Jiang C, Nemeth M, et al. Results of a 90-day safety assurance study with rats fed grain from corn rootworm-protected corn. *Food Chem Toxicol* 2006b;44:147–60.
- Healy C, Hammond B, Kirkpatrick J. Results of a 13-week safety assurance study with rats fed grain from corn rootworm-protected, glyphosate-tolerant MON 88017 corn. *Food Chem Toxicol* 2008;46:2517–24.
- Howarth GS, Francis GL, Cool JC, Xu X, Byard RW, Read LC. Milk growth factors enriched from cheese which ameliorate intestinal damage by methotrexate when administered orally to rats. *J Nutr* 1996;126:2519–30.
- ISAAA. ISAAA's GM approval database. <http://www.isaaa.org/gmapprovaldatabase/>, 2013.
- Kaspareit J, Rittinghausen S. Spontaneous neoplastic lesions in Harlan Sprague–Dawley rats. *Exp Toxicol Pathol* 1999;51:105–7.
- Kawabata TK. Immunotoxicology of the gastrointestinal tract. In: Holsapple MP, Smialowicz RJ, editors. *Experimental immunotoxicology*. CRC Press; 1996. p. 143–55.

- Kikuchi M, Nagata H, Watanabe N, Watanabe H, Tatemichi M, Hibi T. Altered expression of a putative progenitor cell marker DCAMK1 in the rat gastric mucosa in regeneration, metaplasia and dysplasia. *BMC Gastroenterol* 2010;10:65.
- König A, Cockburn A, Crevel RWR, Debruyne E, Grafstroem E, Hammerling U, et al. Assessment of the safety of foods derived from genetically modified (GM) crops. *Food Chem Toxicol* 2004;42:1047–88.
- Krogsho S, Madsen C, Poulsen M, Schröder M, Kvist PH, Taylor M, et al. Immunotoxicological studies of genetically modified rice expressing PHA-E lectin or Bt toxin in Wistar rats. *Toxicology* 2008;245:24–34.
- Kuiper HA, Kleter GA. The scientific basis for risk assessment and regulation of genetically modified foods. *TIFS* 2003;14:277–93.
- Kuiper HA, Kleter GA, Noteborn HPJM, Kok EJ. Assessment of the food safety issues related to genetically modified foods. *Plant J* 2001;27:503–28.
- Lillie RD. *Histopathological techniques and practical histochemistry*. Moscow: Mir; 1969.
- Logan RM, Stringer AM, Bowen JM, Gibson RJ, Sonis ST, Keefe DM. Is the pathobiology of chemotherapy-induced alimentary tract mucositis influenced by the type of mucotoxic drug administered? *Cancer Chemother Pharmacol* 2009;63:239–51.
- Magaña-Gómez JA, De La Barca AM. Risk assessment of genetically modified crops for nutrition and health. *Nutr Rev* 2009;67(1):1–16.
- Morini G, Grandi D. Methods to measure gastric mucosal lesions in the rat. *Curr Protoc Toxicol* 2010. [Chapter 21: Unit 21.2.1–15].
- Noteborn HPJM, Bienenmann-Ploum ME, van den Berg JHJ, Alink GM, Zolla L, Reynaerts A, et al. Safety assessment of the *Bacillus thuringiensis* insecticidal crystal protein CRYIAB(b) expressed in transgenic tomatoes. In: Engel K-H, Takeoka GR, Teranishi R, editors. *Genetically modified foods: safety issues*. Washington: American Chemical Society; 1995.
- OECD (Organisation for Economic Co-operation and Development). Test no. 408: repeated dose 90-day oral toxicity study in rodents, guideline for the testing of chemicals. Paris: OECD; 1981.
- OECD (Organisation for Economic Co-operation and Development). Test no. 408: repeated dose 90-day oral toxicity study in rodents, guideline for the testing of chemicals. Paris: OECD; 1998.
- OECD (Organisation for Economic Co-operation and Development). Test no. 452: chronic toxicity studies. Guideline for the testing of chemicals. Paris: OECD; 2008.
- Padgett SR, Kolacz KH, Delannay DB, LaVallee BJ, Tinius CN, Rhodes WK, et al. Development, identification, and characterization of glyphosate-tolerant soybean line. *Crop Sci* 1995;35:1451–61.
- Piastowska-Ciesielska AW, Gralak MA. Influence of a low dose of dietary soybean on bone properties and mineral status in young rats. *Biofactors* 2010;36:451–8.
- Pusztai A, Bardocz S, Ewen SW. Genetically modified foods: potential human health effects. In: D'Mello JPF, editor. *Food safety: contaminants and toxins*. Wallingford: CABI Publishing; 2003.
- Qi X, He X, Luo Y, Li S, Zou S, Cao S, et al. Subchronic feeding study of stacked trait genetically-modified soybean (305423 × 40-3-2) in Sprague–Dawley rats. *Food Chem Toxicol* 2012;50:3256–63.
- Sakamoto Y, Tada Y, Fukumori N, Tayama K, Ando H, Takahashi H, et al. A 52-week feeding study of genetically modified soybeans in F344 rats. *J Food Hyg Soc Jpn* 2007;48:41–50. [in Japanese].
- Sakamoto Y, Tada Y, Fukumori N, Tayama K, Ando H, Takahashi H, et al. A 104-week feeding study of genetically modified soybeans in F344 rats. *J Food Hyg Soc Jpn* 2008;49:272–82. [in Japanese].
- Schilter B, Constable A. Regulatory control of genetically modified (GM) foods: likely developments. *Toxicol Lett* 2002;127:341–9.
- Schnepf E, Crickmore N, Van Rie J, Lereclus D, Baum J, Feitelson J, et al. *Bacillus thuringiensis* and its pesticidal crystal proteins. *Microbiol Mol Biol Rev* 1998;62:775–806.
- Schröder M, Poulsen M, Wilcks A, Krogsho S, Miller A, Frenzel T, et al. A 90-day safety study of genetically modified rice expressing Cry1Ab protein (*Bacillus thuringiensis* toxin) in Wistar rats. *Food Chem Toxicol* 2007;45:339–49.
- Şener G, Paskaloglu K, Kapucu C, Cetinel S, Contuk G, Ayanoğlu-Dülger G. Ocreotide ameliorates alendronate-induced gastric injury. *Peptides* 2004;25:115–21.
- Seralini GE, Cellier D, de Vendomois JS. New analysis of a rat feeding study with a genetically modified maize reveals signs of hepatorenal toxicity. *Arch Environ Contam Toxicol* 2007;52:596–602.
- Seralini GE, Clair E, Mesnage R, Gress S, Defarge N, Malatesta M, et al. Long term toxicity of a Roundup herbicide and a Roundup-tolerant genetically modified maize. *Food Chem Toxicol* 2012;50:4221–31. [Retracted and republished as: Seralini, G.E.; Clair, E.; Mesnage, R.; Gress, S.; Defarge, N.; Malatesta, M., et al., 2014. Republished study: long-term toxicity of a Roundup herbicide and a Roundup-tolerant genetically modified maize. *Environ. Sci. Eur.* 26 (1): 14].
- Snell C, Bernheim A, Berge J-B, Kuntz M, Pascal G, Paris A, et al. Assessment of the health impact of GM plant diets in long-term and multigenerational animal feeding trials: a literature review. *Food Chem Toxicol* 2012;50:1134–48.
- Staubano S, Rocco A, Mezza E, De Rosa G, Budillon G, Nardone G. Diagnosis of chronic atrophic gastritis by morphometric image analysis. A new method to overcome the confounding effect of the inflammatory infiltrate. *J Pathol* 2002;198:47–54.
- Stefanov SB. Visual classification during quantitative comparison of images. *Arkh Anat Gistol Embriol* 1985;88:78–83. [in Russian].
- Strzalkowski AK, Godlewski MM, Hallay N, Kulasek G, Gajewski Z, Zabielski R. The effect of supplementing sow with bioactive substances on neonatal small intestinal epithelium. *J Physiol Pharmacol* 2007;58:115–22.
- Sukhotnik I, Shehadeh N, Coran AG, Mogilner JG, Karry R, Shamian B, et al. Oral insulin enhances cell proliferation and decreases enterocyte apoptosis during methotrexate-induced mucositis in the rat. *JPGN* 2008;47:115–22.
- Tang M, Xie T, Cheng W, Qian L, Yang S, Yang D, et al. A 90-day safety study of genetically modified rice expressing rhIGF-1 protein in C57BL/6J rats. *Transgenic Res* 2012;21:499–510.
- Tarnawski A, Douglass TG, Stachura J, Krause WJ. Quality of gastric ulcer healing: histological and ultrastructural assessment. *Aliment Pharmacol Ther* 1991;5(Suppl. 1):79–90.
- Teshima R, Akiyama H, Okunuki H, Sakushima J-i, Goda Y, Onodera H, et al. Effect of GM and non-GM soybeans on the immune system of BN rats and B10A mice. *J Food Hyg Soc Jpn* 2000;41:188–93.
- Tutel'ian VA, Kravchenko LV, Lashneva NV, Avren'eva LI, Guseva GV, Sorokina E, et al. Medical and biological evaluation of safety of protein concentrate from genetically-modified soybeans. *Biochemical studies. Vopr Pitan* 1999;68:9–12. [in Russian].
- Tutel'ian VA, Kravchenko LV, Sorokina E, Korolev AA, Avren'eva LI, Guseva GV, et al. Medical and biological assessment of the safety of genetically modified corn lines MON 810 and GA 21: a toxicological–biochemical study. *Vopr Pitan* 2001;70:28–31. [in Russian].
- Tutel'ian VA, Gapparov MM, Avren'eva LI, Aksiuk IN, Guseva GV, Kravchenko LV, et al. Medical and biological safety assessment of genetically modified maize event MON 88017. Report 1. Toxicological–hygienic examinations. *Vopr Pitan* 2008;77:4–12. [in Russian].
- Tutel'ian VA, Gapparov MG, Avren'eva LI, Guseva GV, Zhminchenko VM, Kravchenko LV, et al. Medical and biological safety assessment of genetically modified soybean event MON 89788. Report 1. Toxicological–hygienic examinations. *Vopr Pitan* 2010;79:4–12. [in Russian].
- Tyshko NV, Britsina MV, Gmoshinskii IV, Zhanataev AK, Zakharova NS, Zorin SN, et al. Medical and biological safety assessment of genetically modified maize event MON 88017. Report 2. Genotoxicologic, immunologic and allergologic examinations. *Vopr Pitan* 2008;77:13–7. [in Russian].
- Tyshko NV, Britsina MV, Gmoshinskii IV, Zakharova NS, Zorin SN, Mazo VK, et al. Medical and biological safety assessment of genetically modified soybean event MON 89788. Report 2. Genotoxicologic, immunologic and allergologic examinations. *Vopr Pitan* 2010;79:13–7. [in Russian].
- Vaeck M, Reynaerts A, Hofte H, Jansens S, De Beuckeleer M, Dean C, et al. Transgenic plants protected from insect attack. *Nature* 1987;328:33–7.
- Wang Z-h, Wang Y, Cui H-r, Xia Y-w, Altosaar I, Shu Q-y. Toxicological evaluation of transgenic rice flour with a synthetic cry1Ab gene from *Bacillus thuringiensis*. *JSFA* 2002;82:738–44.
- Wilson AK, Latham JR, Steinbrecher RA. Transformation-induced mutations in transgenic plants: analysis and biosafety implications. *Biotechnol Genet Eng Rev* 2006;23:209–37.
- Windels P, Taverniers I, Depicker A, Van Bockstaele E, De Loose M. Characterisation of the Roundup Ready soybean insert. *Eur Food Res Technol* 2001;213:107–12.
- Zhu Y, Li D, Wang F, Yin J, Jin H. Nutritional assessment and fate of DNA of soybean meal from roundup ready or conventional soybeans using rats. *Arch Anim Nutr* 2004;58:295–310.