

1 **PI-RADS v2 - What you need to know**

2

3 Tristan Barrett MD¹, Baris Turkbey², Peter L. Choyke².

4

5 ¹Department of Radiology, Addenbrooke's Hospital and the University of Cambridge,
6 Cambridge, CB2 0QQ, UK

7

8 ²Molecular Imaging Program, Center for Cancer Research, National Cancer Institute,
9 Bethesda, MD 20892.

10

11 **Journal: Clinical Radiology**

12 **Accepted 25/06/2015**

13

14 Corresponding author:

15 Tristan Barrett

16 Email: tristan.barrett@addenbrookes.nhs.uk

17 Phone: (44) 01223 336895, Fax: (44) 01223 330915

18

19 TB is supported the National Institute for Health Research (NIHR) Cambridge Biomedical
20 Research Centre.

21

22 **Key words:** PI-RADS, Prostate cancer, MRI, Guidelines

23

24

1 Introduction

2
3
4
5
6
7
8
9
10
11
12
13
14
15
16
17
18
19
20
21
22
23
24
25
26
27
28
29
30
31
32
33
34
35
36
37
38
39
40
41
42
43
44
45
46
47

Prostate cancer is the second leading cause of cancer death in men and its incidence is expected to double by 2030 due to the aging global population [1]. The traditional diagnostic tests employed for detection of prostate cancer, namely prostate-specific antigen (PSA) and transrectal ultrasound (TRUS) guided biopsy lack sensitivity and specificity. The former is specific to the prostate gland but not to prostate cancer and the latter can miss approximately 30% of tumours and under-estimate tumour aggressiveness in around a third of cases [2, 3]. Imaging was initially employed for loco-regional staging with MRI and distant staging with CT or bone scintigraphy in patients with biopsy proven cancer. However, more recent advances in MR technology and the incorporation of functional sequences alongside anatomical imaging, termed multiparametric (mp) MRI, have improved our ability to both detect and characterize prostate tumours. MR imaging for biopsy guidance has been shown to improve accuracy of tumour detection and grading [4, 5], and MRI is now seen as an essential step prior to enrollment on active surveillance programmes [6]. As a result, some authors even suggest that MRI should replace TRUS biopsy as the initial diagnostic test for prostate cancer to enable guidance of subsequent biopsy [7].

This change in practice is reflected in the updated 2014 NICE guidelines, which recommend more widespread use of MRI in the work-up of prostate cancer [6]. A recently published report from the National Prostate Cancer Audit revealed that while 99% of trusts in England that provide prostate cancer services have access to onsite MR imaging, only 75% provide mpMRI [8]. In addition, interpretation of prostate MRI entails a steep learning curve [9, 10] and requires regular reporting and audit in order to maintain reporting standards [11].

The European Society of Urogenital Radiology (ESUR) in 2012 established clinical guidelines for the acquisition, interpretation and reporting of multi-parametric MRI of the prostate in order to facilitate a greater level of standardization and consistency [12]. These recommendations, popularly referred to as Prostate Imaging Reporting and Data System (PI-RADS), were based on literature evidence and consensus expert opinion and were modelled on similar efforts in mammography (BI-RADS) that led to the transformation of breast cancer care. A number of studies have subsequently validated PI-RADS in certain research and clinical setting, however, experience has highlighted some limitations, in part due to technical improvements and also changes in clinical practice. A joint steering committee formed by the American College of Radiology (ACR), ESUR, and the non-profit organisation AdMeTech Foundation, have recently attempted to update and improve on the original proposals. PI-RADS Version-2 was officially launched at RSNA 2014, and is now available on-line [13].

Herein, we summarise the main features of PI-RADS v2, explore the background evidence that form the basis of the recommendations, and highlight the key differences with PI-RADS v1 for the benefit of those already familiar with the original.

45 Format and scope

The incorporation of the American College of Radiology into the consortium results in the

1 subtle change to US-English, from the UK-English of the original European-based ESUR
2 guidelines. The format is also fundamentally different, with the original being a 12-page
3 article published in a peer-reviewed journal, whilst PI-RADS-v2 is a 55-page PDF document
4 available on-line. This is necessary to meet the intended aims of being a “living” document
5 that has scope to evolve with the accrual of clinical experience and scientific data; indeed
6 some sections such as report templates and sample protocols remain listed as “under
7 construction” on the earliest iteration.

8
9 The mention of PI-RADS tends to invoke thoughts of the proposed scoring system, but in
10 truth the original document was far more than this, with information on risk stratification in
11 prostate cancer, enrolment criteria for active surveillance programmes, recommendations
12 on MRI protocol parameters, and how to report findings. The format of v2 allows it to be
13 even more comprehensive, with detailed background information including an overview of
14 normal anatomy and benign findings, and a lexicon of terminology with relevant definitions.

15
16 PI-RADS-v2 is more explicit in its scope and aims. It is designed to promote global
17 standardization and diminish variation in the acquisition, interpretation, and reporting of
18 prostate mpMRI examinations. Unlike the original document which struck a compromise by
19 suggesting both “minimal” and “optimal” requirements, v2 only proposes to establish
20 minimal technical parameters that should result in an acceptable mpMRI examination. A
21 further aim that differs from v1 is to facilitate the use of MRI data for targeted biopsy, a
22 reflection of the recent evolution of clinical practice [14]. Common to both, although more
23 explicitly stated in v2, the guidelines are not intended for MRI application in the setting of
24 suspected post-therapy recurrent prostate cancer, nor progression during surveillance,
25 although they could be easily adopted for the latter. Unlike the original, separate protocols
26 for “detection”, “staging” and “node and bone” are not suggested, rather a common
27 protocol is presented, and MRI for evaluation of the skeletal system is explicitly not covered.

28
29 A combined MRI and biopsy definition of “significant” prostate cancer is proposed based on
30 recent clinical experience [15, 16]: Gleason score ≥ 7 (including 3+4 with prominent but not
31 predominant Gleason 4 component), and/or volume $\geq 0.5\text{cc}$, and/or extraprostatic
32 extension (EPE). This is relevant to the stated aims of improving detection of significant
33 cancer, whilst increasing confidence in calls of benign or insignificant disease, in order to
34 reduce unnecessary biopsies and treatment.

35 36 37 **MRI Acquisition**

38
39 PI-RADS-v1 recommended the combination of high-resolution T2-weighted images (T2WI),
40 and at least two functional MRI techniques, which could be diffusion-weighted imaging
41 (DWI), dynamic contrast-enhance (DCE), or MR spectroscopy imaging (MRSI). In version-2
42 MRSI is no longer recommended for PI-RADS assessment, with mpMRI consisting of
43 anatomical imaging, DWI, and DCE alone. It is further noted that if functional imaging with
44 both DWI and DCE is absent or inadequate, the MRI assessment should be limited to
45 staging.

46
47 *Pre-procedure*

1 Minimum expected requirements are explicitly stated now for providing a relevant clinical
2 history, namely recent PSA level and PSA history, family history, previous treatment, digital
3 rectal examination findings, and biopsy status and result. PI-RADS-v1 recommended waiting
4 at least 4-6 weeks between biopsy and MRI. The new version recommends waiting at least 6
5 weeks when the purpose is for staging, but acknowledges that there may be no need for
6 post-biopsy imaging delay if the primary purpose of the exam is to detect and characterize
7 clinically significant cancer within the gland, based on the superior specificity of DWI
8 utilizing high b-values [17].
9

10 *Patient preparation*

11 It is acknowledged that at present there is a lack of consensus regarding issues of patient
12 preparation. Antispasmodic agents are considered beneficial but not essential and use can
13 be decided locally, based on considerations of cost, drug availability and potential for
14 adverse drug reactions. An endorectal coil (ERC) is not routinely recommended, although
15 with older generation 1.5T MRI systems, an ERC may be indispensable for achieving
16 diagnostic quality imaging [18]. The patient should evacuate the rectum just prior to the
17 MRI exam to minimise the presence of stool and rectal air which can lead to susceptibility
18 artefact and distortion on DWI. If significant air is noted on initial imaging, consideration
19 should be given to performing the remainder of the examination in a prone position or
20 attempts made to decompress the rectum. Although in some centres abstention from
21 ejaculation 72 hours prior to scanning is employed to maintain seminal vesicle distention, a
22 benefit for this is not established and is therefore not recommended.
23

24 *MR Protocols*

25 In contradistinction to the original guidance, v2 proposes just one protocol for MR imaging
26 of the prostate, with no separate parameters offered for 1.5T protocols. 3.0T is considered
27 superior to 1.5T, however, both 1.5T and 3.0T can provide adequate and reliable diagnostic
28 exams when acquisition parameters are optimized and appropriate contemporary
29 technology is employed. 1.5T should be used for patients with implants that are MR
30 conditional at 1.5T but not at 3.0T, or where artefact from implants such as hip
31 replacements will compromise imaging at 3.0T.
32

33 There is also a strong recommendation that the imaging plane angle, location, and slice
34 thickness are identical for all sequences. If image quality of any sequence is suboptimal,
35 measures should be taken to repeat the sequence. The technical parameters recommended
36 for T2, DWI and DCE sequences are summarized in **Table 1**, a brief overview of the key
37 points for each sequence and changes is given below.
38

39 Anatomical imaging

40 Axial T1W images remain essential to assess for biopsy-related haemorrhage. These can be
41 with or without fat suppression and should match the other axial sequences, although lower
42 spatial resolution may be employed. Multiplanar T2WI should incorporate the axial, sagittal,
43 and coronal planes; the “detection” protocol in v1 only recommended axial and sagittal
44 imaging. 3D axial acquisitions may be used, however, in-plane resolution may be lower than
45 the equivalent 2D acquisition and these should therefore be used as an adjunct to, rather
46 than a replacement for 2D imaging.
47

1 Diffusion-weighted imaging

2 DWI should incorporate a minimum of two b-values and a mono-exponential model of
3 signal decay, which is in contrast to the original PI-RADS where at least 3 b-values were
4 recommended, with prescribed values of 0, 100 and 800–1000 s/mm². This is set as the
5 minimum requirement and if only two b-values are acquired, the lowest should be 50-100
6 sec/mm² (not b-0) and the highest should be 800-1000 sec/mm². In addition, the acquisition
7 of “high b-value” images is recommended, utilising a b-value of at least 1400 sec/mm², or up
8 to 2000 sec/mm², if SNR remains adequate. The original v1 recommended using the ≥800
9 sec/mm² as the “high b-value” series for interpretation purposes. However, despite these
10 changes, the recommendations for ADC maps essentially remain the same with exclusion of
11 any b-0 data to avoid pseudo-perfusion effects [19], and utilizing a high b-value of no
12 greater than 1000 s/mm² for calculation purposes.

13 Dynamic contrast-enhanced MRI

14 PI-RADS-v2 now recommends a fat-suppressed sequence to improve lesion conspicuity;
15 subtraction can be used as a replacement or as a post-processing adjunct in cases of biopsy-
16 related haemorrhage. The most widely used method of assessing DCE is visual assessment
17 of each slice by cine loop or manually scrolling, and there is currently insufficient evidence
18 to recommend the routine use of pharmacodynamic (PD) analysis. Parametric maps can be
19 calculated depending on local preference, but any suspicious findings should always be
20 confirmed on the source images. An injection rate of 2-3 ml/s should be employed, with a
21 temporal resolution of <10 seconds and preferably <7 seconds in order to depict focal early
22 enhancement. This differs from the original guidelines of a 15 seconds temporal resolution,
23 with a higher temporal resolution of <10 s suggested when PD analysis is to be performed.
24 Whilst version 1 stated the minimum length of acquisition post-injection in order to detect
25 washout as being 5 minutes, v2 simply states a total observation time of ≥2minutes, this
26 relates to the de-emphasis of PD analysis that requires longer acquisition periods for DCE.
27
28
29

30 **MRI Interpretation**

31
32 It is emphasised that the assigned PI-RADS-v2 score is based solely on mpMRI findings and
33 does not take into account clinical factors that may be of key relevance such as PSA, clinical
34 history, or previous biopsy results. As such reporters may choose to use a Likert scale of
35 probability to reflect these factors (**Figure 1**). Typically an overall PI-RADS score of 4 or 5
36 means a biopsy is recommended. Subtle changes have been made to the 5-point scoring
37 systems for T2WI findings in the PZ and TZ and for diffusion-weighted imaging findings
38 (**Table 2**). DCE-MRI has changed from a 5-point scale to simply being either “positive” or
39 “negative”. Additionally, at the end of the document, example images are provided for all
40 PI-RADS categories for each of the three sequences in both the PZ and TZ.
41

42 The concept of a “dominant sequence” is formally introduced. DWI is the key sequence for
43 the PZ, and T2WI predominates in the TZ. Simplified guidance tables help to emphasize this
44 interpretation and how to assign the final PI-RADS-v2 score (**Table 3**), essentially the
45 dominant sequence score is the final score for 1, 2, 4, or 5 and for scores of 3, the secondary
46 sequence (DCE in PZ and DWI in TZ) may change the score from 3 to 4. The system proposed
47 helps provide some clarity, as previous authors have used PI-RADS-v1 in a variety of ways:

1 using a Likert system based on PI-RADS descriptors [20], employing a summed PI-RADS score
2 from all sequences with a cut-off [21-23], or using an average score [24]. Early studies have
3 already been performed assessing the PI-RADS-v2 system [25], and it will be interesting to
4 test inter-observer variation and outcomes compared to final pathology.

5 6 T2-weighted Scoring

7 Anatomical imaging was previously the mainstay of prostate MRI and axial T2WI remains
8 the key sequence for local staging, including extracapsular extension and seminal vesicle
9 invasion, and for the assessment of the transition zone. If the T2WI PI-RADS score in the TZ
10 is 3, this can be upgraded to a score of 4 if DWI, the secondary sequence, shows strong
11 restricted diffusion (category 4, 5). However, it is noted that diffusion is often reduced in
12 BPH nodules so caution should be exercised in this setting. T2WI findings in the peripheral
13 zone lack specificity, low signal can be due acute or chronic prostatitis, post-inflammatory
14 scars and atrophy, haemorrhage, and previous treatment, as well as tumour [26]. As a
15 result, DWI is the dominant sequence used in the PZ. It should be emphasized that in the
16 normal PZ, it is unusual for diffusion to be very restricted in conditions other than cancer.

17
18 The main change in the T2WI scoring system relates to category 4 and 5. Previously lesions
19 needed to show either a suspicion for early (capsular bulging or broad contact) or
20 established extra-capsular extension (ECE) to reach a score of 5. In the updated system, the
21 criteria retain the latter, but replace the former with a size cut-off of 1.5 cm (**Figure 2**). Of
22 note, the use of the terms “erased charcoal” to described TZ tumours and “organised chaos”
23 to describe the normal transition zone appearance due to BPH on T2 have been dropped
24 from the summary scoring system. These somewhat evocative terms are however retained
25 within the text of the article and it is sensible for the reader to keep them in mind when
26 interpreting the T2 sequences. The description of TZ tumours having a lenticular or “tear-
27 drop” shape [27] is retained. A formal definition of what constitutes category 3 findings is
28 provided for PZ and TZ alongside the original article’s slightly ambiguous statement of not
29 otherwise being in categories 1, 2, 4, or 5.

30 31 Diffusion-weighted imaging Scoring

32 Non-cancerous nodules of BPH can contain stroma or have a high cellular density and can
33 therefore demonstrate restricted diffusion [28], thus DWI is the secondary sequence to T2
34 for TZ interpretation. DWI is however the main sequence for interpretation of the PZ, with
35 DCE the secondary sequence, thus a DWI score of 3 in the PZ can be upgraded to category 4
36 if the matching DCE is positive. The scoring system for DWI in categories 2-5 has changed
37 considerably compared to version 1 (**Table 2**). As with the T2WI scoring, the distinction
38 between categories 4 and 5 is based on a size cut-off of 1.5cm or features of ECE, this offers
39 consistency between the two dominant sequences.

40
41 It is emphasized that absolute ADC values should be used with caution as these can vary
42 substantially depending on the value and number of b-values selected, the magnet strength,
43 the vendor, and inter-patient variability [29-31]. PI-RADS-v2 does however suggest that an
44 ADC threshold of 750-900 $\mu\text{m}^2/\text{sec}$ can be used for differentiation between benign and
45 malignant prostate tissues in the PZ. It is also recommended that ADC maps are consistently
46 viewed with the same contrast windowing, set to adequately portray clinically significant
47 prostate cancers as markedly hypointense on ADC maps. Clearly these will need to be

1 tailored to the particular scanner and advice from radiologists who have experience with a
2 similar magnet may be helpful. In our experience, using a window width of $1400 \mu\text{m}^2/\text{sec}$
3 and window level of $1400 \mu\text{m}^2/\text{sec}$ sets the grey-scale range from $700 - 2100 \mu\text{m}^2/\text{sec}$, with
4 potentially significant ADC values of $<700 \mu\text{m}^2/\text{sec}$ therefore appearing as “black”.

6 Dynamic contrast-enhanced MRI Scoring

7 The interpretation of DCE and the application of its results have changed significantly from
8 version 1. Although the role of DCE-MRI appears downplayed, PIRADS-v2 explicitly states
9 that DCE should be included in all prostate mpMRI examinations to avoid missing some
10 small but significant tumours [32]. Additionally, in situations when one of the other
11 sequences is non-diagnostic, DCE can be helpful in assessing risk.

12
13 Considerable effort was previously expended in v1 looking at “curvology” of contrast wash-
14 in and wash-out from the prostate and prostatic lesions. Three curve patterns are described:
15 Type I, progressive enhancement, Type II, plateau of enhancement, and Type III, contrast
16 washout. Curve typing works well in breast imaging where Type I is considered benign (only
17 8.9% of tumours demonstrate this pattern), Type II is intermediate probability, and a Type III
18 curve is considered malignant (only 5.5% of benign lesions show this pattern) [33]. PI-RADS-
19 v1 endorsed the visual assessment of specific curve types along with focality and asymmetry
20 of enhancement in order to create a 5-point DCE score. However, the enhancement
21 characteristics of prostate show great heterogeneity: BPH nodules are often hypervascular
22 (**Figure 3**), the absence of early enhancement usually adds little information, and diffuse
23 enhancement can be seen in the setting of prostatitis. Furthermore, there is little evidence
24 in the literature to support the qualitative use of curve types for identifying prostate cancer
25 [34]. Indeed Hansford, et al [35] recently showed that despite good inter-observer
26 agreement on curve-type assignment, curvology cannot reliably differentiate prostate
27 cancer from benign prostate tissue, with the majority of tumours demonstrating Type 2
28 enhancement curves (**Figure 4**).

29
30 As a result, PI-RADS-v2 does not consider the type of curve important, with DCE only classed
31 as “positive” in the presence of focal enhancement that corresponds to a suspicious finding
32 on T2 and/or DWI. DCE is considered the secondary sequence for the PZ, and lesions scoring
33 3 on DWI can be upgraded to category 4 overall if DCE is positive. DCE may also be helpful in
34 prioritization when multiple lesions are present in the same patient, or for identification of
35 the index lesion. Although DCE-MRI has no role to play in the transition zone in the presence
36 of good quality T2WI and DWI, it can be utilized as a secondary sequence if DWI evaluation
37 in part or all of the gland is technically compromised.

38
39 Although DCE-MRI is often the key sequence for identifying recurrent disease after previous
40 focal or whole-gland treatment [36-38], PI-RADS v2 is specifically aimed at assessment of
41 treatment naïve patients.

43 Staging

44 T2-weighted imaging is the key sequence for determining the “T-stage” of tumours.
45 Distinction between T1 and T2 disease and their subsets is less important than determining
46 organ-confined (T1-2 disease) versus extra-prostatic extension (T3a disease), seminal vesicle
47 involvement (T3b), or invasion of the pelvic side wall or other organs (T4 disease). Although

1 some work suggests DWI may help in the detection of ECE [39], this benefit may partially
2 relate to more confident tumour localization; clearly initial identification of the tumour
3 using anatomical and functional sequences is an aid to accurate staging. In version 1 extra-
4 prostatic involvement (T3a/b) was also scored on a five-point scale and, although a formal
5 scale is no longer employed, the features to look for are retained.

6
7 Imaging features suggesting extra-prostatic extension include overt ECE, capsular bulging or
8 irregularity, broad capsular contact (>1.0 cm), filling in of the retroprostatic angle, and
9 asymmetry or invasion of the neurovascular bundles. Recent work has demonstrated that
10 the degree of tumour contact length with the capsule is a better predictor than both
11 pathological tumour volume and clinical nomograms: capsular contact >2cm demonstrated
12 an accuracy of 82% for predicting ECE, whereas with contact <1cm the chance of ECE was
13 <5% [40].

14
15 The MRI features of seminal vesicle invasion (SVI) are low T2W signal, restricted diffusion,
16 abnormal contrast enhancement, obliteration of the angle between the seminal vesicle and
17 prostatic base, and demonstration of contiguous tumour extension. Three patterns of SVI
18 have been described: Type I, direct spread along the ejaculatory ducts, Type II, direct
19 invasion from tumour through the capsule into the seminal vesicles, and Type III, metastasis
20 from a remote non-contiguous primary in the prostate. Ohori *et al* in 1993 demonstrated
21 SVI as being Type I in 26%, Type II in 33%, combined Types I and II in 28%, and Type III in
22 13% of cases [41]. A more recent study showed an almost equal split between Type I and II,
23 but with no Type III disease [42]. Although the type of seminal vesicle invasion may not be
24 clinically relevant and is not routinely reported by pathologists [43], it is worth noting the
25 relative rarity of Type III involvement if the tumour is confidently identified in a location
26 remote from the base or the confluence with the ejaculatory ducts at the verumontanum.

27
28 Unlike version 1, there is no dedicated “nodes and bones” protocol, as the imaged
29 population will be expected to have either organ-confined or locally advanced disease. At
30 least one sequence should employ a field-of-view (FOV) that permits evaluation of lymph
31 nodes up to the level of the aortic bifurcation. MRI assessment of lymph nodes remains
32 limited to morphological features and size, with nodes >8mm in short axis regarded as
33 suspicious. DWI is not considered a reliable discriminator between benignity and metastatic
34 involvement; normal nodes can have an impeded diffusion due to their high cellularity, and
35 lymph nodes have a relatively long T2 relaxation time and will therefore appear as high
36 signal intensity structures on b-value DWI [44]. This latter property can be exploited by
37 using the high b-value sequence as a means of identifying and mapping out nodes [45],
38 which can then be evaluated on the anatomical sequences. The imaged bones should be
39 reviewed for metastases, and again the high b-value imaging may aid conspicuity (**Figure 5**).

40 41 42 **MRI Reporting**

43
44 The original PI-RADS article stated the use of a structured reporting scheme was preferred.
45 The benefits of proforma-type reporting have been championed [46], and this is consistent
46 with the RSNA radiology reporting initiative for improving reporting practices. PI-RADS v2
47 has provision for example template reports in Appendix I, but these remain “under

1 construction”.

2

3 Lesions with a PI-RADS score of 3, 4, or 5 should be reported, up to a maximum of four. The
4 index (dominant) lesion should be identified. This is defined as the lesion with the highest
5 PIRADS score, if this is assigned to two or more lesions, the index lesion should be the
6 largest lesion, or the one that shows EPE. The minimum requirement is to report the largest
7 dimension of a suspicious finding on an axial image, if the largest dimension is derived from
8 the sagittal and/or coronal images, this measurement and plane should also be reported.

9 Consistent with the predominant sequences previously described, PZ lesions should be
10 measured on ADC maps and TZ lesions measured on T2W. Unless direct lesion volumetry is
11 available, overall gland volume should be recorded using the ellipse formula (maximum AP
12 diameter) x (maximum transverse diameter) x (maximum longitudinal diameter) x 0.52.

13

14 Lesion location should be reported according to the sector map to enable localization of
15 findings and as a visual aid for subsequent biopsy and/or treatment planning. Either a paper
16 copy or scanned electronic version of the map should be used for recording. PI-RADS-v1
17 suggested a minimum requirement of dividing the prostate into 16 regions, with an optimal
18 requirement of 27 regions. The updated recommendations are 36 sectors for the prostate,
19 with an additional two for the seminal vesicles and one for the external urethral sphincter.

20

21 Although there was no diagrammatic representation in the original paper, the
22 recommendations were based on the scheme proposed by Dickinson et al [47] and
23 developed from earlier work by Villers, et al [48] and Haffner, et al [49]. Herein, the gland is
24 separated into left and right and medial and lateral at the level of the apex, mid, and base.
25 There is further division into anterior and posterior by the “17-mm line”, which is based on
26 the likely reach of a 20 mm transrectal biopsy needle. An interim update by Barentsz, et al
27 [50] proposed the 36-sector partition, with additional division of the anterior stroma levels
28 into left and right and further splitting the transition zone into anterior and posterior above
29 and below the 17-mm line. For PI-RADS v2, a new diagram has been drawn based on the
30 earlier work, which now incorporates the central zone (**Figure 6**), but includes only
31 alphabetic abbreviations in contradistinction to the alphanumeric labels of the earlier
32 schemes.

33

34

35 **Conclusions**

36 PI-RADS version 2 offers a comprehensive overview of the role of multiparametric MRI for
37 the initial assessment of prostate cancer (**Table 4**). The diagnostic work-up and treatment of
38 prostate cancer continues to progress rapidly, and the nature of PI-RADS v2 as a “living” on-
39 line document will allow it to adapt and match this clinical evolution. It is now the task of
40 the imaging community to test the validity of PI-RADS v2 including its sensitivity and
41 specificity for clinically significant disease, its reproducibility among readers with different
42 experience levels and between centres, and its role in active surveillance decisions. As a
43 living document, there is no doubt that version 3 is already in its earliest stages.

44

45

46

47

1 **References**

2
3
4
5
6
7
8
9
10
11
12
13
14
15
16
17
18
19
20
21
22
23
24
25
26
27
28
29
30
31
32
33
34
35
36
37
38
39
40
41
42
43
44
45
46
47

[1] Maddams J, Utley M, Møller H. Projections of cancer prevalence in the United Kingdom, 2010-2040. *Br J Cancer*. 2012; 107(7):1195-202

[2] Levine MA, Ittman M, Melamed J, Lepor H. Two consecutive sets of transrectal ultrasound guided sextant biopsies of the prostate for the detection of prostate cancer. *J Urol* 1998; 159(2):471-475

[3] Kvåle R, Møller B, Wahlqvist R, et al. Concordance between Gleason scores of needle biopsies and radical prostatectomy specimens: a population-based study. *BJU Int*. 2009; 103(12):1647-54

[4] Pinto PA, Chung PH, Rastinehad AR, et al. Magnetic Resonance Imaging/Ultrasound Fusion Guided Prostate Biopsy Improves Cancer Detection Following Transrectal Ultrasound Biopsy and Correlates With Multiparametric Magnetic Resonance Imaging. *J Urol* 2011; 186(4):1281-1285

[5] Moore CM, Robertson NL, Arsanious N, et al. Image-guided prostate biopsy using magnetic resonance imaging-derived targets: a systematic review. *Eur Urol* 2013; 63(1):125-140.

[6] National Institute for Health and Care Excellence. Prostate cancer: diagnosis and treatment. Clinical guideline 175 (Update of clinical guideline 58). 2014. *Last accessed 14/4/2015*
<http://www.nice.org.uk/guidance/cg175/evidence/cg175-prostate-cancer-full-guideline3>

[7] Ahmed HU, Kirkham A, Arya M, et al. Is it time to consider a role for MRI before prostate biopsy? *Nat Rev Clin Oncol*. 2009; 6(4):197-206

[8] National Prostate Cancer Audit First Year Annual Report – Organisation of Services and Analysis of Existing Clinical Data. London: The Royal College of Surgeons of England, 2014. *Last accessed 14/4/2015*
http://www.npca.org.uk/wp-content/uploads/2014/11/NPCA-Annual-Report-FINAL-10_11_14.pdf

[9] Gaziev G, Wadhwa K, Barrett T, et al. Defining the Learning Curve for multi-parametric MRI of the prostate using MRI-TRUS fusion guided transperineal prostate biopsies as a validation tool. *BJU Int*. 2014 Aug 7. doi: 10.1111/bju.12892. [Epub ahead of print]

[10] Akin O, Riedl CC, Ishill NM, Moskowitz CS, Zhang J, Hricak H. Interactive dedicated training curriculum improves accuracy in the interpretation of MR imaging of prostate cancer. *Eur Radiol*. 2010; 20(4):995-1002

[11] Kirkham AP, Haslam P, Keanie JY, et al. Prostate MRI: who, when, and how? Report from a UK consensus meeting. *Clin Radiol*. 2013; 68(10):1016-23

- 1 [12] Barentsz JO, Richenberg J, Clements R, et al. ESUR prostate MR guidelines 2012. Eur
2 Radiol. 2012; 22(4):746-57
3
- 4 [13] ACR, ESUR, AdMeTech Foundation, 2014. Prostate Imaging and Reporting and Data
5 System: Version 2. Last accessed 14/4/2015
6 [http://www.acr.org/~media/ACR/Documents/PDF/QualitySafety/Resources/PIRADS/PIRAD](http://www.acr.org/~media/ACR/Documents/PDF/QualitySafety/Resources/PIRADS/PIRADS%20V2.pdf)
7 [S%20V2.pdf](http://www.acr.org/~media/ACR/Documents/PDF/QualitySafety/Resources/PIRADS/PIRADS%20V2.pdf)
8
- 9 [14] Siddiqui MM, Rais-Bahrami S, Turkbey B, et al. Comparison of MR/ultrasound fusion-
10 guided biopsy with ultrasound-guided biopsy for the diagnosis of prostate cancer. JAMA.
11 2015; 313(4):390-7
12
- 13 [15] Turkbey B, Mani H, Aras O, et al. Prostate cancer: can multiparametric MR imaging help
14 identify patients who are candidates for active surveillance? Radiology. 2013; 268(1):144-52
15
- 16 [16] Bott SR, Ahmed HU, Hindley RG, Abdul-Rahman A, Freeman A, Emberton M. The index
17 lesion and focal therapy: an analysis of the pathological characteristics of prostate cancer.
18 BJU Int. 2010 Dec; 106(11):1607-11
19
- 20 [17] Barrett T, Vargas HA, Akin O, Goldman DA, Hricak H. Value of the hemorrhage exclusion
21 sign on T1-weighted prostate MR images for the detection of prostate cancer. Radiology.
22 2012; 263(3):751-7
23
- 24 [18] Turkbey B, Merino MJ, Gallardo EC, et al. Comparison of endorectal coil and
25 nonendorectal coil T2W and diffusion-weighted MRI at 3 Tesla for localizing prostate cancer:
26 correlation with whole-mount histopathology. J Magn Reson Imaging. 2014; 39(6):1443-8
27
- 28 [19] Le Bihan D, Breton E, Lallemand D, Aubin ML, Vignaud J, Laval-Jeantet M. Separation of
29 diffusion and perfusion in intravoxel incoherent motion MR imaging. Radiology 1988;
30 168:497-505
31
- 32 [20] Lawrence EM, Tang SY, Barrett T, et al. Prostate cancer: performance characteristics of
33 combined T₂W and DW-MRI scoring in the setting of template transperineal re-biopsy using
34 MR-TRUS fusion. Eur Radiol. 2014; 24(7):1497-505
35
- 36 [21] Renard-Penna R1, Mozer P, Cornud F, et al. Prostate Imaging Reporting and Data
37 System and Likert Scoring System: Multiparametric MR Imaging Validation Study to Screen
38 Patients for Initial Biopsy. Radiology. 2015 Jan 19:140184. [Epub ahead of print]
39
- 40 [22] Vaché T, Bratan F, Mège-Lechevallier F, Roche S, Rabilloud M, Rouvière O.
41 Characterization of prostate lesions as benign or malignant at multiparametric MR imaging:
42 comparison of three scoring systems in patients treated with radical prostatectomy.
43 Radiology. 2014; 272(2):446-455
44
- 45 [23] Renard-Penna R, Mozer P, Cornud F, et al. Prostate Imaging Reporting and Data System
46 and Likert Scoring System: Multiparametric MR Imaging Validation Study to Screen Patients
47 for Initial Biopsy. Radiology. 2015; 275(2):458-68

- 1
2 [24] Kuru TH, Roethke MC, Rieker P, et al. Histology core-specific evaluation of the European
3 Society of Urogenital Radiology (ESUR) standardised scoring system of multiparametric
4 magnetic resonance imaging (mpMRI) of the prostate. *BJU Int.* 2013; 112(8):1080-7
5
6 [25] Muller BG, Shih JH, Sankineni S, et al. Inter-observer agreement and accuracy of the
7 revised Prostate Imaging - Reporting and Data System (PI-RADS) for interpreting
8 multiparametric MRI of the prostate. *Radiology* 2015. *In Press*
9
10 [26] Rosenkrantz AB, Taneja SS. Radiologist, be aware: ten pitfalls that confound the
11 interpretation of multiparametric prostate MRI. *AJR Am J Roentgenol.* 2014; 202(1):109-20
12
13 [27] Akin O, Sala E, Moskowitz CS, et al. Transition zone prostate cancers: features,
14 detection, localization, and staging at endorectal MR imaging. *Radiology.* 2006; 239(3):784-
15 92
16
17 [28] Oto A, Kayhan A, Jiang Y, et al. Prostate cancer: differentiation of central gland cancer
18 from benign prostatic hyperplasia by using diffusion-weighted and dynamic contrast-
19 enhanced MR imaging. *Radiology.* 2010; 257(3):715-23
20
21 [29] Thörmer G, Otto J, Reiss-Zimmermann M, et al. Diagnostic value of ADC in patients with
22 prostate cancer: influence of the choice of b values. *Eur Radiol.* 2012; 22(8):1820-1828
23
24 [30] Litjens GJ, Hambroek T, Hulsbergen-van de Kaa C, Barentsz JO, Huisman HJ. Interpatient
25 variation in normal peripheral zone apparent diffusion coefficient: effect on the prediction
26 of prostate cancer aggressiveness. *Radiology* 2012; 265(1):260-266
27
28 [31] Sasaki M, Yamada K, Watanabe Y, et al. Variability in absolute apparent diffusion
29 coefficient values across different platforms may be substantial: a multivendor, multi-
30 institutional comparison study. *Radiology* 2008; 249:624–630
31
32 [32] Iwazawa J, Mitani T, Sassa S, Ohue S. Prostate cancer detection with MRI: is dynamic
33 contrast-enhanced imaging necessary in addition to diffusion-weighted imaging? *Diagn*
34 *Interv Radiol.* 2011; 17(3):243-8
35
36 [33] Kuhl CK, Mielcareck P, Klaschik S, et al. Dynamic breast MR imaging: are signal intensity
37 time course data useful for differential diagnosis of enhancing lesions? *Radiology.* 1999;
38 211(1):101-10
39
40 [34] Ren J, Huan Y, Wang H, et al. Dynamic contrast-enhanced MRI of benign prostatic
41 hyperplasia and prostatic carcinoma: correlation with angiogenesis. *Clin Radiol* 2008;
42 63(2):153–159
43
44 [35] Hansford BG, Peng Y, Jiang Y, et al. Dynamic Contrast-enhanced MR Imaging Curve-type
45 Analysis: Is It Helpful in the Differentiation of Prostate Cancer from Healthy Peripheral
46 Zone? *Radiology.* 2015; 275(2):448-57
47

- 1 [36] Haider MA, Chung P, Sweet J, et al. Dynamic contrast-enhanced magnetic resonance
2 imaging for localization of recurrent prostate cancer after external beam radiotherapy. *Int J*
3 *Radiat Oncol Biol Phys.* 2008; 70(2):425-30
4
- 5 [37] Barrett T, Davidson SR, Wilson BC, Weersink RA, Trachtenberg J, Haider MA. Dynamic
6 contrast enhanced MRI as a predictor of vascular-targeted photodynamic focal ablation
7 therapy outcome in prostate cancer post-failed external beam radiation therapy. *Can Urol*
8 *Assoc J.* 2014; 8(9-10):E708-14
9
- 10 [38] Rouvière O, Girouin N, Glas L, et al. Prostate cancer transrectal HIFU ablation: detection
11 of local recurrences using T2-weighted and dynamic contrast-enhanced MRI. *Eur Radiol.*
12 2010; 20(1):48-55
13
- 14 [39] Lawrence EM, Gallagher FA, Barrett T, et al. Preoperative 3-T diffusion-weighted MRI
15 for the qualitative and quantitative assessment of extracapsular extension in patients with
16 intermediate- or high-risk prostate cancer. *AJR Am J Roentgenol.* 2014; 203(3):W280-6
17
- 18 [40] Vlatkovic L, Svindland A, Eggesbø HB, et al. Predictive value of magnetic resonance
19 imaging determined tumor contact length for extracapsular extension of prostate cancer. *J*
20 *Urol.* 2015; 193(2):466-72
21
- 22 [41] Ohori M, Scardino PT, Lapin SL, Seale-Hawkins C, Link J, Wheeler TM. The mechanisms
23 and prognostic significance of seminal vesicle involvement by prostate cancer. *Am J Surg*
24 *Pathol.* 1993; 17(12):1252-61
25
- 26 [42] Roethke M, Kaufmann S, Kniess M, et al. Seminal vesicle invasion: accuracy and analysis
27 of infiltration patterns with high-spatial resolution T2-weighted sequences on endorectal
28 magnetic resonance imaging. *Urol Int.* 2014; 92(3):294-9
29
- 30 [43] Berney DM1Wheeler TM, Grignon DJ, et al; ISUP Prostate Cancer Group. International
31 Society of Urological Pathology (ISUP) Consensus Conference on Handling and Staging of
32 Radical Prostatectomy Specimens. Working group 4: seminal vesicles and lymph nodes. *Mod*
33 *Pathol.* 2011; 24(1):39-47
34
- 35 [44] Glazer GM, Orringer MB, Chenevert TL, et al. Mediastinal lymph nodes: relaxation
36 time/pathologic correlation and implications in staging of lung cancer with MR imaging.
37 *Radiology.* 1988; 168(2):429-31
38
- 39 [45] Qayyum A. Diffusion-weighted imaging in the abdomen and pelvis: concepts and
40 applications. *Radiographics.* 2009; 29(6):1797-810
41
- 42 [46] Kahn CE Jr, Langlotz CP, Burnside ES, et al. Toward best practices in radiology reporting.
43 *Radiology.* 2009; 252(3):852-856
44
- 45 [47] Dickinson L, Ahmed HU, Allen C, et al. Magnetic resonance imaging for the detection,
46 localisation, and characterisation of prostate cancer: recommendations from a European
47 Consensus Meeting. *Eur Urol* 2011; 59:477–494

1
2
3
4
5
6
7
8
9
10
11
12
13
14
15
16
17

[48] Villers A, Lemaitre L, Haffner J, Puech P. Current status of MRI for the diagnosis, staging and prognosis of prostate cancer: implications for focal therapy and active surveillance. *Curr Opin Urol.* 2009; 19(3):274-82

[49] Haffner J, Lemaitre L, Puech P, et al. Role of magnetic resonance imaging before initial biopsy: comparison of magnetic resonance imaging-targeted and systematic biopsy for significant prostate cancer detection. *BJU Int.* 2011; 108(8 Pt 2):E171-8

[50] Barentsz J, Villers A, Schouten M. ESUR prostate MR guidelines. Author reply. *Eur Radiol.* 2013; 23(8):2322-3

1 **Tables**

2

<ul style="list-style-type: none"> • T2-weighted imaging (axial, sagittal, coronal planes) <ul style="list-style-type: none"> - Field-of-view: 12-20 cm to encompass the entire prostate gland and seminal vesicles - 3 mm slice thickness, 0 mm gap - In-plane resolution: $\leq 0.7\text{mm}$ (phase) x $\leq 0.4\text{mm}$ (frequency)
<ul style="list-style-type: none"> • Diffusion-weighted imaging (axial plane) <ul style="list-style-type: none"> - Free-breathing spin echo EPI sequence combined with spectral fat saturation is recommended - Slice thickness to match T2WI - TE: ≤ 90 msec; TR : > 3000 msec - Field-of-view: 16-22 cm - In plane dimension: $\leq 2.5\text{mm}$ phase and frequency - At least 2 b-values should be acquired in three orthogonal directions. If only 2 b-values are utilised, these should be 50-100 s/mm² (low) and 800-1000 s/mm² (high) - “High b-value” acquisition with b-1400 – 2000 s/mm², depending on achievable quality of SNR - ADC map calculation: low b-value should be ≥ 50 sec/mm², high b-value should be > 800 s/mm², up to a maximum of 1000 s/mm²
<ul style="list-style-type: none"> • Dynamic contrast-enhanced MRI (axial plane) <ul style="list-style-type: none"> - Fat-saturated 2D or 3D T1 gradient echo (GRE) sequence; 3D is preferred - Slice thickness to match T2WI - Injection rate: 2-3 ml/sec - TR / TE: $< 100\text{msec}$ / $< 5\text{msec}$ - In-plane dimension: $\leq 2\text{mm}$ X $\leq 2\text{mm}$ - Temporal resolution: ≤ 10 sec (< 7 sec is preferred) - Pharmacodynamic analysis does not have to be performed

3 **Table 1. Acquisition protocols: Technical parameters**

4

5

Score Criteria	
T2W for Peripheral Zone	
1	Uniform high signal intensity
2	Linear, wedge shaped, or geographic areas of lower SI, usually not well demarcated
3	Heterogeneous signal intensity or non-circumscribed, rounded, moderate hypointensity. Or other not in categories 1/2 or 4/5 [Intermediate, not 1/2 or 4/5]
4	Circumscribed, homogenous moderate hypointense focus/mass confined to prostate and < 1.5 cm in greatest dimension [No size stated]
5	Same as 4 but $\geq 1.5\text{cm}$ in greatest dimension or definite ECE/invasive behavior [Broad > 1.5 cm capsule contact]
T2W for Transition Zone	
1	Heterogeneous intermediate SI [Used terms well-defined margins and “organised chaos”]
2	Circumscribed hypointense or heterogeneous encapsulated nodule(s) (BPH)

[Used well-marginated]	
3	Heterogeneous signal intensity with obscured margins. Or other not in categories 1/2 or 4/5 [Intermediate, not 1/2 or 4/5]
4	Lenticular or non-circumscribed, homogeneous, moderately hypointense, and <1.5 cm in greatest dimension [No size stated. Used term "erased charcoal sign"]
5	Same as 4, but ≥ 1.5cm in greatest dimension or definite ECE /invasive behavior [Involving the anterior fibromuscular stroma or the anterior horn of the PZ]
Diffusion-weighted Imaging	
1	No abnormality (i.e. normal) on ADC and high b-value DWI
2	Indistinct hypointense on ADC [Also diffuse hyper SI on ≥b800 image; no focal features]
3	Focal mildly/moderately hypointense on ADC and isointense/ mildly hyperintense on high b-value DWI [Intermediate, not 1/2 or 4/5]
4	Focal markedly hypointense on ADC and markedly hyperintense on high b-value DWI; <1.5cm in greatest dimension [Iso-intense on high b-value. No size stated]
5	Same as 4 but ≥1.5cm in greatest dimension or definite ECE / invasive behaviour [Focal, hyper SI on the high b-value images with reduced ADC]
Dynamic contrast-enhanced MRI	
-	No early enhancement OR Diffuse enhancement not corresponding to a focal finding on T2 and/or DWI OR Focal enhancement corresponding to a lesion demonstrating features of BPH on T2WI
+	Focal AND Earlier than or contemporaneously with enhancement of adjacent normal prostatic tissues AND Corresponds to suspicious finding on T2 and/or DWI

1 **Table 2. PI-RADS v-2 scoring systems.** Differences from version 1 stated in parentheses; ECE
2 = Extra-Capsular Extension, BPH = Benign Prostatic Hypertrophy, ADC = apparent diffusion
3 co-efficient, DWI = Diffusion-Weighted Imaging
4
5

Peripheral Zone			
DWI score (Dominant sequence)	DCE score (Secondary sequence)	T2WI score	Overall PIRADS-v2 score
1	Any	Any	1
2	Any	Any	2
3	- ve	Any	3
3	+ ve	Any	4
4	Any	Any	4
5	Any	Any	5
Transition Zone			
T2WI score (Dominant sequence)	DWI score (Secondary sequence)	DCE score	Overall PIRADS-v2 score
1	Any	Any	1
2	Any	Any	2

3	≤4	Any	3
3	5	Any	4
4	Any	Any	4
5	Any	Any	5

1 **Table 3. Guidance for assignment of overall PIRADS-v2 score**

2
3

• Format and scope

- Intended as a “living” web-based document that will evolve with clinical practice
- Explicitly only for initial MRI examination, not for follow-up in Active Surveillance or assessment post-treatment
- Only proposes minimal technical parameters for an acceptable mpMRI examination, with the previous “optimal” parameters omitted

• MRI Acquisition

- Spectroscopy is no longer used for PIRADS assessment
- No delay in MRI post-biopsy if the primary purpose is to detect and characterize “clinically significant” cancer
- Anti-peristaltic medications recommended but no longer considered essential
- Single MRI protocol recommended, in contrast to original “detection”, “staging” and “node and bone” protocols

• Interpretation

- PI-RADS-v2 score is based solely on mpMRI findings and does not take into account clinical factors
- Typically an overall PI-RADS score of 4 or 5 means a biopsy should be considered in this region, but the score does not explicitly state recommendations for management
- DWI is the dominant sequence for interpretation in the PZ, T2WI predominates for TZ assessment
- The secondary sequences are DCE in the PZ and DWI in the TZ. If the primary sequence has a PI-RADS score of 3, the secondary sequence may change the category to 4.
- For category 5 assessment in both the transition zone and peripheral zone, lesions must be more than 1.5 cm in size or demonstrate extraprostatic or invasive changes
- ADC maps should be consistently viewed with the same contrast windowing. Absolute ADC values should be interpreted with caution.
- For DCE-MRI interpretation, the presence of focal enhancement is important rather than the type of curve
- T2WI remains key for the purposes of staging

• Reporting

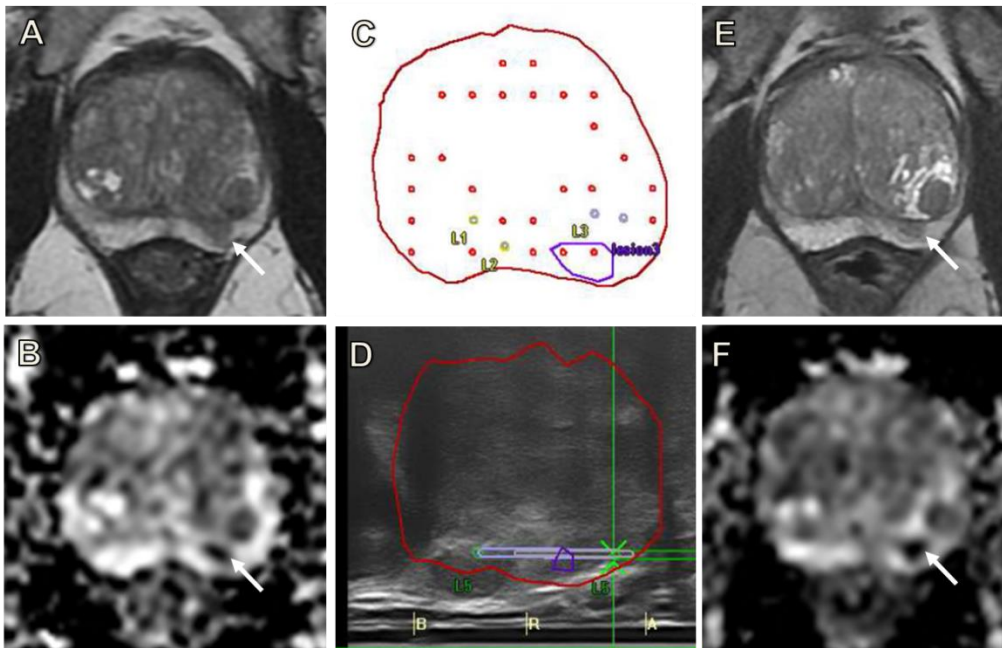
- Structured reports are recommended. Examples are yet to be provided
- Lesions with an overall PI-RADS score ≥3 should be reported, up to a maximum of 4 lesions, with the index lesion identified
- The maximal axial dimensions of a lesion should be reported using the ADC map as reference for PZ lesions and T2WI for TZ lesions
- Sector Maps consist of 36 prostatic regions, compared to 16 (minimal) and 27 (optimal) in v1. The gland is again divided into anterior and posterior by the “17-mm line”, based on the likely reach of a 20 mm transrectal biopsy needle
- The new schema incorporates the central zone and includes only alphabetic rather than alphanumeric abbreviations

4 **Table 4. Summary of key differences proposed in PIRADS-v2**

5

1 **Figure legends**

2



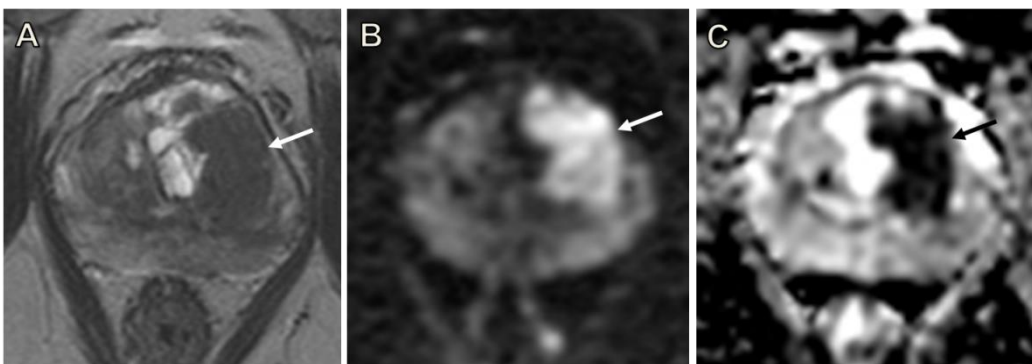
3

4 **Figure 1. Importance of clinical context**

5 60 year old referred for raised PSA. Axial T2WI (A) demonstrates a focal lesion in the left mid
6 PZ (arrows), with matching restricted diffusion (B); PI-RADS score 4. Subsequent
7 transperineal fused US-MRI targeted-biopsy is planned (C), with sagittal US image
8 confirming needle placement in the lesion (D). Histology confirms high-grade PIN. MRI
9 repeated at 18 months shows no change in the previously sampled lesion (E, F). Although
10 the PI-RADS score is based solely on mpMRI findings and remains 4, when taking account of
11 clinical context, the report conclusion would more appropriately state that clinically
12 significant cancer is unlikely to be present.

13

14

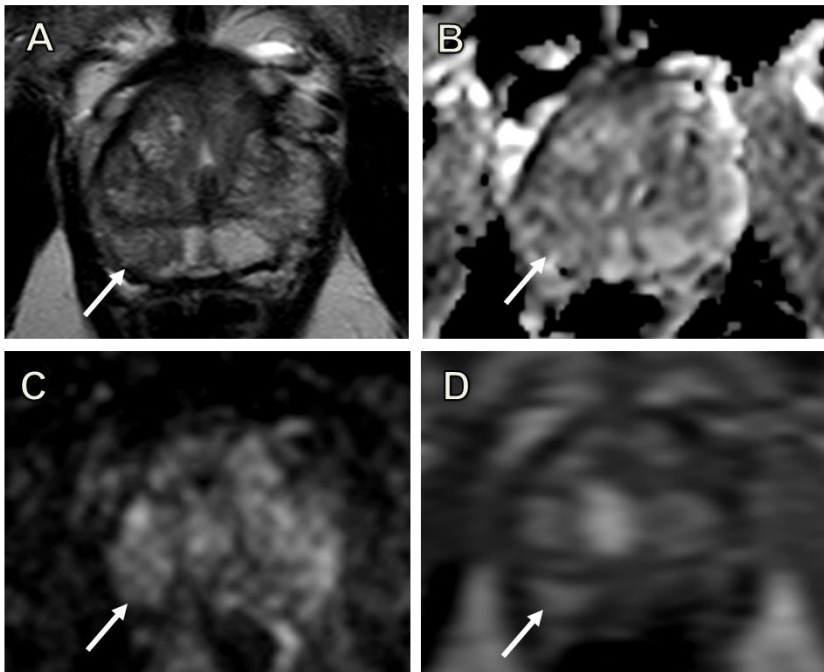


15

16 **Figure 2. Differences in T2 scoring for high probability targets**

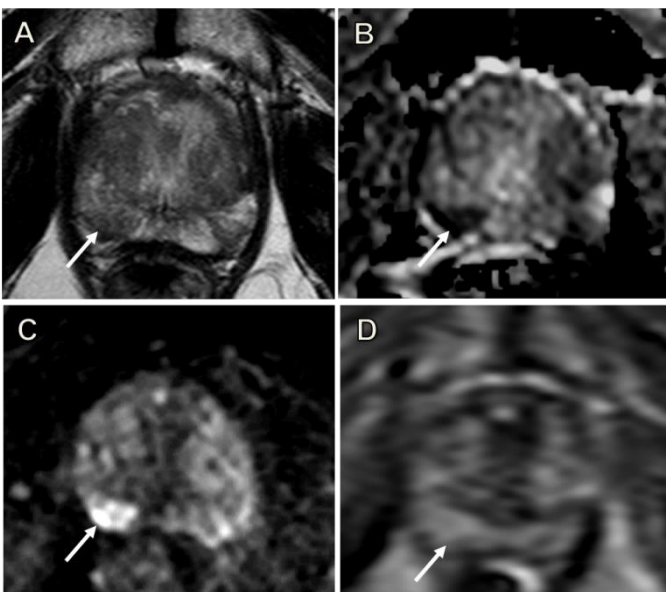
17 77 year-old patient with a PSA of 17 ng/ml. A: T2WI imaging shows a large (2.5 x 1.5 cm)
18 lesion centred in the left transition zone at the level of the mid gland (arrow), with matching
19 restricted diffusion (B, C). PI-RADS v1 scores: 4 for T2 as no features of ECE and no broad
20 capsular contact, 5 for DWI. PI-RADS v2 overall score 5: T2 is the dominant sequence and
21 the lesion is >1.5 cm, despite no features of ECE. Subsequent targeted biopsy confirms
22 Gleason 4+5 disease (90% core involvement) in the left medial mid gland and Gleason 5+5
23 (60% involvement) in the left posterior lateral gland.

1
2



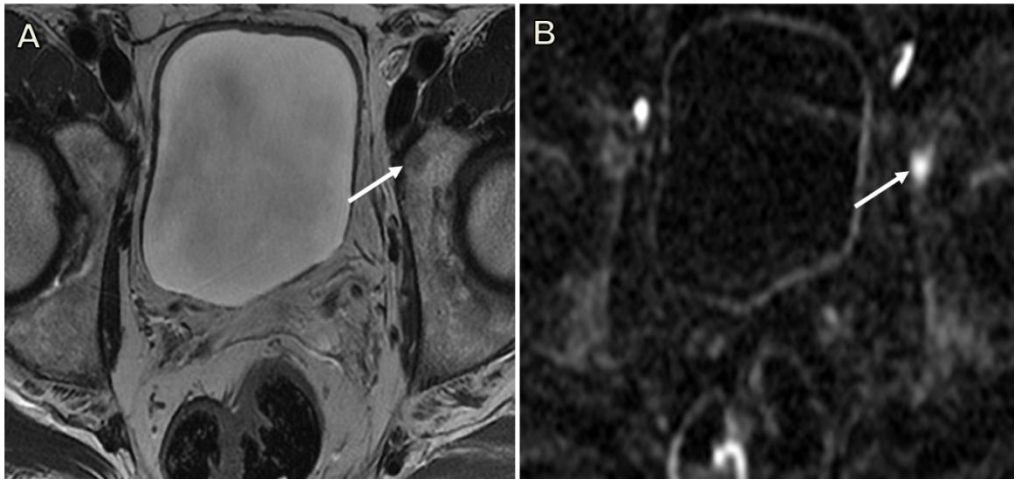
3
4 **Figure 3. False-positive DCE result, correctly classed as low probability for tumour with PI-**
5 **RADS v2 criteria**

6 63 year-old man, serum PSA = 2.31 ng/ml. A: T2WI imaging shows an area of intermediate
7 signal with geographical features in the right mid/apex PZ (arrows) with no matching
8 restricted diffusion (B,C). The region shows focal early enhancement on DCE-MRI (arrow in
9 D), with a Type III curve. PI-RADS v1 scores: 2 for T2, 2 for DWI, 5 for DCE, summed score =
10 9. PI-RADS v2 overall score 2 (DWI is the dominant PZ sequence) despite being “positive” for
11 DCE. Targeted biopsy of this region was benign.
12

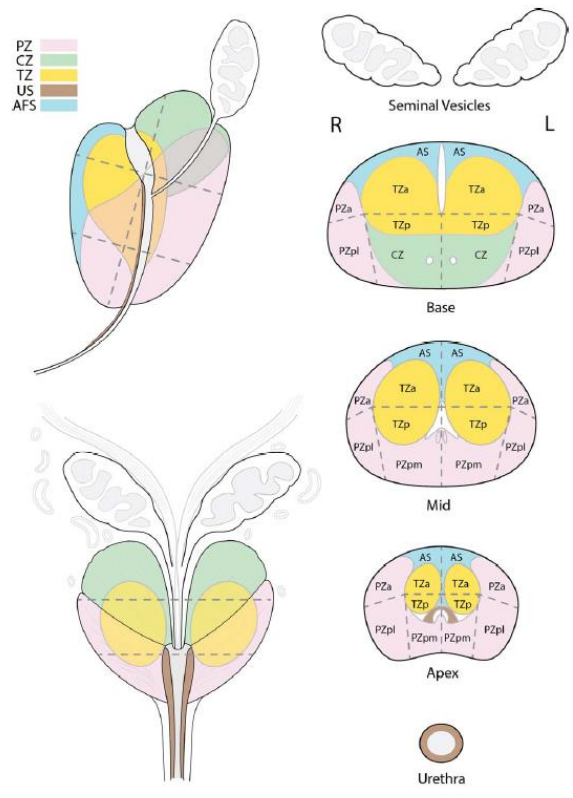


13
14 **Figure 4. False-negative DCE, correctly evaluated as likely tumour using PI-RADS v2 criteria**
15 60 year-old patient with a PSA of 4.48 ng/ml. A: T2WI imaging shows a focal area of
16 intermediate/low signal the right mid/apex PZ (arrows), with marked matching restricted
17 diffusion (B, C). The region shows diffuse, but no focal or early enhancement on DCE-MRI

1 (arrow in D), with a Type I curve. PI-RADS v1 scores: 3 for T2, 5 for DWI, 1 for DCE, summed
 2 score = 9. PI-RADS v2 overall score 5 (DWI is the dominant PZ sequence) despite being
 3 “negative” for DCE. Targeted biopsy demonstrated a Gleason 3+3 tumour in 10% of the
 4 cores.
 5
 6



7
 8 **Figure 5. High b-value images aid detection of bone metastases**
 9 68 year old with rising PSA, two years post prostatectomy. A: axial T2-weighted imaging
 10 shows a subtle low intensity area in the left acetabulum (arrow). B: Axial b-1400 diffusion-
 11 weighted sequence; the lesion demonstrates restricted diffusion and appears more
 12 conspicuous on these high b-value images.
 13
 14



15
 16 **Figure 6. Sector maps for division of prostatic regions**

1 PI-RADS v2 schema incorporating the central zone and utilizing alphabetic abbreviations; PZ
2 = peripheral zone, TZ = transition zone, a = anterior, p = posterior, pm = postero-medial, pl =
3 postero-lateral, AS = anterior stroma. *Used with Permission David Rini ©, Johns Hopkins*
4 *University .*