

Available online at www.sciencedirect.com

Annals of Diagnostic Pathology 15 (2011) 221–224

Annals of
DIAGNOSTIC
PATHOLOGY

Original Contributions

Botryoid odontogenic cyst: A clinicopathologic study of 10 cases

Pedro Paulo de Andrade Santos, DDS, MSc, Valéria Souza Freitas, DDS, MSc,
 Roseana de Almeida Freitas, DDS, PhD, Leão Pereira Pinto, DDS, PhD,
 Lélia Batista de Souza, DDS, PhD*

Postgraduation Program in Oral Pathology, Federal University of Rio Grande do Norte, Natal, RN, Brazil

Abstract

Botryoid odontogenic cyst is a rare multilocular variant of lateral periodontal cysts. In this study, a series of 10 cases of botryoid odontogenic cysts retrieved from the archives of the Postgraduation Program in Oral Pathology, Federal University of Rio Grande do Norte (Brazil), were reviewed for epidemiologic data, clinical presentation, radiographic and histopathologic characteristics, treatment, and recurrence.

© 2011 Elsevier Inc. All rights reserved.

Keywords:

Botryoid odontogenic cyst; Recurrent botryoid cyst; Lateral periodontal cyst; Multicystic variant

1. Introduction

Botryoid odontogenic cyst (BOC) is a multicystic variant of lateral periodontal cysts (LPCs) and was first described by Weathers and Waldron [1] in 1973. The histogenesis of LPC and BOC remains uncertain, although a number of possible sources of odontogenic epithelium, including the rests of Malassez and reduced enamel epithelium, have been ruled out as candidates [2].

Botryoid odontogenic cyst preferentially involves the mandibular premolar-canine area, followed by the anterior region of the maxilla [3]. Adults older than 50 years are the most affected group [4]. Although most of the reported cases of BOC have shown a multilocular radiolucency, some authors demonstrated that this lesion frequently presents as a unilocular radiographic image, thus, resembling a variety of other odontogenic cysts or neoplastic conditions [5].

Botryoid cysts are characterized by multiple cystic spaces and variations in the thickness of the epithelial lining, accompanied by epithelial protrusions into the lumen [6]. Glycogen-containing clear cells may also be present, they lack mucus-producing cells, mucous pools, crypts, intrae-

pitheial microcysts, ductlike structures, or “hobnail” cells. The same reasoning would be true for LPC, which are essentially botryoid cysts with a single space [7,8]. The present article reports 10 additional cases of BOC, and the literature is reviewed regarding clinicopathologic aspects, differential diagnosis, therapeutic management, and recurrence of this rare odontogenic cyst.

2. Case reports

Ten cases of BOC were identified in the archives of the Postgraduation Program in Oral Pathology, Federal University of Rio Grande do Norte (Brazil). The clinical and radiographic characteristics of all cases are summarized in Table 1 and are illustrated in Figs. 1 and 2. Histopathologic features are summarized in Table 2 and are illustrated in Figs. 3 to 7.

3. Discussion

Botryoid odontogenic cyst is an unusual and controversial pathologic condition. By definition, LPC is a nonkeratinized developmental cyst that occurs in alveolar bone along the lateral aspect of a vital tooth. In this respect, BOC could be defined as a “multilocular variant of LPC” [9,10].

* Corresponding author. Departamento de Odontologia, Universidade Federal do Rio Grande do Norte, Av. Senador Salgado Filho, 1787-Lagoa Nova, Natal-RN CEP 59056-000, Brazil. Tel.: +55 84 3215 4138; fax: +55 84 3215 4138.

E-mail address: leliasouza@dod.ufrn.br (L.B. de Souza).

Table 1
Clinicopathologic features in 10 cases of BOC

Case	Age	Sex	Jaw	Segment distribution	Size (cm)	Duration	Clinical symptoms	Biopsy	Radiographic appearance	Recurrence
1	82 y	Male	Mandible	Anterior	2	4 y	Asymptomatic	Incisional	Multilocular	Present
2	73 y	Male	Mandible	Posterior	2	9 y	Symptomatic	Incisional	Multilocular	Absent
3	74 y	Male	Mandible	Posterior	3.5	10 y	Symptomatic	Excisional	Multilocular	Present
4	83 y	Male	Mandible	Anterior	2	5 y	Asymptomatic	Excisional	Unilocular	Absent
5	34 y	Male	Mandible	Posterior	2.5	NA	Symptomatic	NA	Unilocular	Absent
6	54 y	Male	Mandible	Anterior	1.5	NA	Symptomatic	Excisional	Multilocular	Present
7	60 y	Female	Maxilla	Posterior	3.2	2 y	Symptomatic	Excisional	NA	Absent
8	49 y	Female	Mandible	Anterior-posterior	8	NA	Symptomatic	Excisional	Multilocular	Absent
9	34 y	Female	Maxilla	Anterior	1.6	2 y	Asymptomatic	Excisional	Unilocular	Absent
10	55 y	Male	Mandible	Anterior-posterior	2.5	6 y	Symptomatic	Excisional	Multilocular	Present

NA indicates not available. Segment distribution: anterior (mesial to the distal surface of the canine), premolar (between the distal surface of the canine and the mesial surface of the first molar), and posterior (distal to the mesial surface of the first molar) for each of the maxillary and mandibular jaws.

Analysis of the 10 BOC cases studied here showed a wide range in patient age from 34 to 83 years, with a mean age of 59.8 years. A male predominance was observed: 7 (70%) patients were males and 3 (30%) were females.

With respect to the site affected, 8 (80%) cases involved the mandible and 2 (20%) the maxilla. In the mandible, BOC was found in the anterior region in 3 cases, in the posterior region in 3, and in the anteroposterior region in 2. The anterior and posterior maxillary regions were involved in one case each.

Clinically, BOC manifested as a slow-growing lesion, which was symptomatic in 7 (70%) of the 10 cases and asymptomatic in 3 (30%). This odontogenic cyst measures 1.5 to 8.0 cm in diameter (mean, 2.88 cm). The reported duration varies from 2 to 10 years (Table 1).

The initial clinical diagnosis of BOC was ameloblastoma in 4 (40%) of the 10 cases, BOC in 2 (20%), radicular cyst in 2 (20%), residual cyst in 1 (10%), and odontogenic keratocyst in 1 (10%).

Lateral periodontal cyst accounts for 0.8% of all central (intraosseous) cysts of the jaw bones [11]. This lesion develops in alveolar bone along the lateral aspect of an erupted vital tooth [12]. Clinical symptoms are usually absent, and the diagnosis is made by radiographic examina-

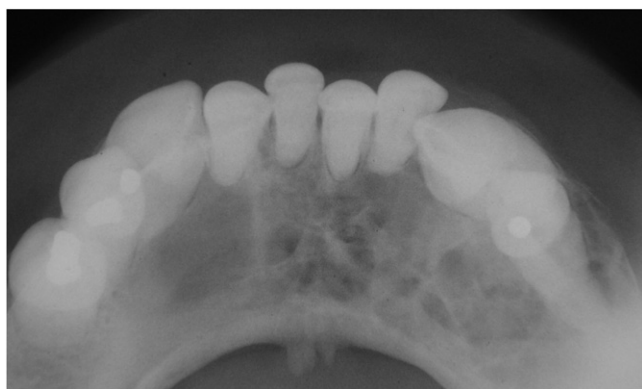

Fig. 1. Radiograph showing a multilocular cystic lesion extending from the root of the right premolar to the left premolar in case 1.

tion [2,12]. Lateral periodontal cyst appears as a solitary, well-defined interradicular radiolucency [2].

One feature that distinguishes BOC from LPC is the larger size of the former [13] because LPC has a limited growth potential. The importance of the differentiation between LPC and BOC is due to the histologic multilocular aspect of the latter that renders this lesion more expansive, thereby, increasing the possibility of recurrence because its complete surgical removal is more difficult [13,14].

In the present study, radiographic data were available for 9 of the 10 patients with BOC. Multilocular radiolucencies were detected in 6 cases (Fig. 1) and unilocular radiolucencies in 3. The differential diagnosis for a multilocular radiolucency within the jaws includes numerous conditions. Odontogenic keratocyst and ameloblastoma are the most common, with both lesions exhibiting a preference for the posterior mandible. Central giant cell granuloma also frequently affects the posterior mandible, although this tumor tends to involve anterior portions of the jaws. Less common conditions that can be included in the differential diagnosis are odontogenic myxoma, ameloblastic fibroma,

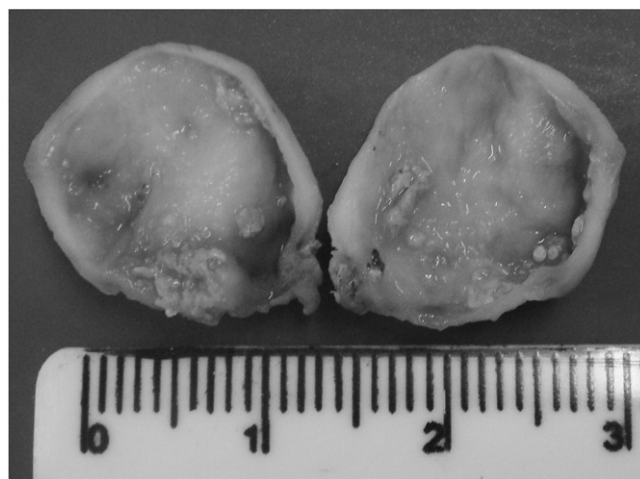

Fig. 2. Macroscopic examination of case 6 revealed the presence of a main cystic cavity and other smaller cysts.

Table 2
Histopathologic analysis of 10 cases

Histopathologic findings	No. of cases	%
Multicystic histologic appearance	10	100
Thin, nonkeratinized squamous or cuboidal epithelium lining	10	100
Focal epithelial plaques	10	100
Clear vacuolated cells	3	30
Microcysts	4	40
Hyalinization juxtaepithelial	7	70
Absence of inflammation	8	80

central odontogenic fibroma, and intraosseous mucoepidermoid carcinoma. A variety of other rare conditions, such as odontogenic tumors, odontogenic cysts, and other benign lesions, may also appear as a multilocular radiolucency. Because this radiographic pattern is not specific, a biopsy and histopathologic examination are required to reach a definitive diagnosis [15].

Macroscopic examination of case 6 revealed the presence of a main cystic cavity and other smaller cysts. The cyst measured 1.5 × 1.0 cm in diameter (Fig. 2).

Follow-up data were available for all 10 cases of BOC. Recurrence was observed in 4 cases, with the same patients undergoing several surgical procedures.

The main histopathologic findings of the 10 cases of BOC (Table 2) were a multicystic histologic appearance (Fig. 3) in all 10 (100%), subepithelial hyalinization (Fig. 4) in 7 (70%), squamous cuboidal epithelium consisting 2 or 3 layers in 10 (100%), focal epithelial plaques (Fig. 5) in 10 (100%), microcysts (Fig. 6) in 4 (40%), clear vacuolated cells (Fig. 7) in 3 (30%), and absence of inflammation in 8 (80%).

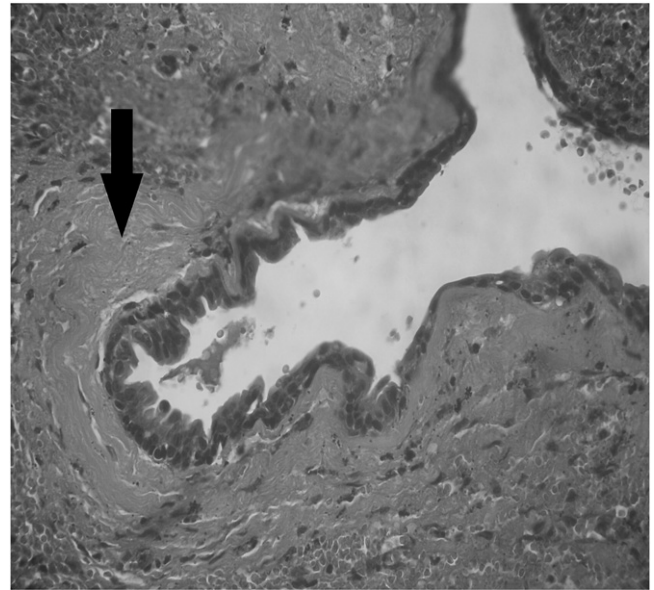


Fig. 4. Botryoid odontogenic cyst showing juxtaepithelial hyalinization (arrow) in case 4 (400×).

4. Conclusion

In conclusion, BOC is a rare multicystic variant of LPC, which is commonly observed in adults older than 50 years. A high recurrence rate (40%) was observed in the present study, with size and multilocular pattern probably being the main factors associated with recurrence. All cases presented multiple cysts, squamous cuboidal epithelium consisting of 2 or 3 layers, and focal epithelial plaques. Long-term follow-up of patients diagnosed with BOC is necessary.

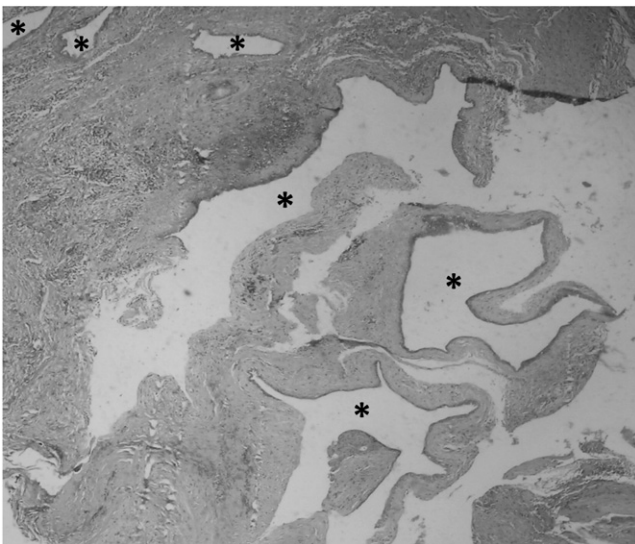


Fig. 3. Botryoid odontogenic cyst containing multiple cystic spaces (asterisks) in case 3 (40×).

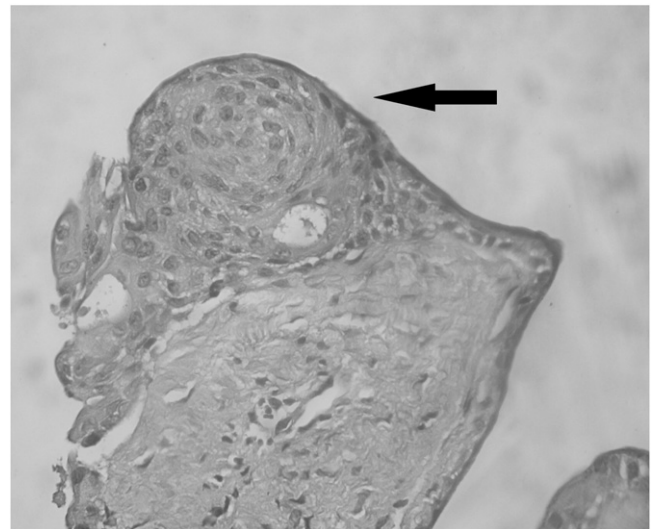


Fig. 5. Botryoid odontogenic cyst showing whirlpool-like thickening (arrow) of the epithelial layer in case 3 (400×).

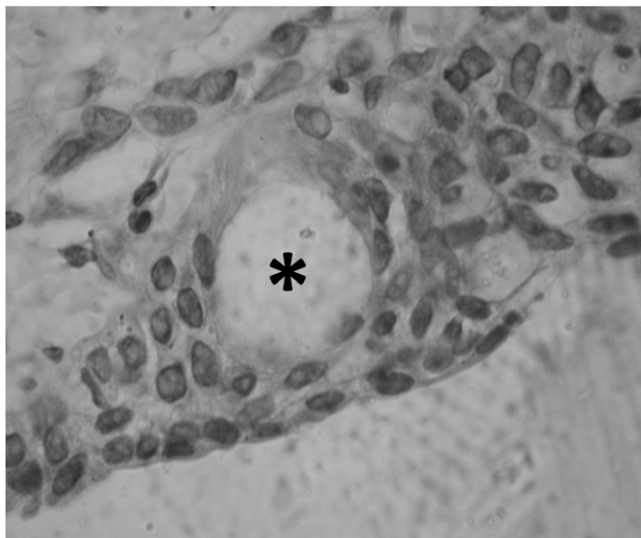


Fig. 6. Microcyst formation (asterisk) in the epithelial layer of BOC in case 2 (1000 \times).

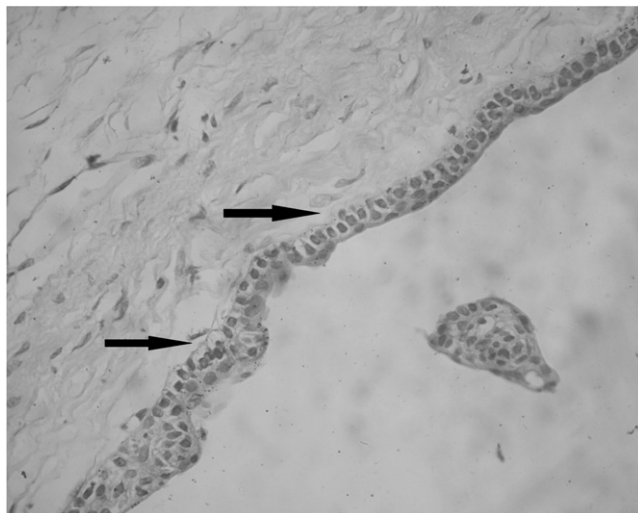


Fig. 7. Botryoid odontogenic cyst presenting clear cells in the basal layer (arrows) in case 7 (400 \times).

References

- [1] Weathers DR, Waldron CA. Unusual multilocular cysts of the jaws (botryoid odontogenic cyst). *Oral Surg Oral Med Oral Pathol* 1973;36(2):235-41.
- [2] Carter LC, Carney YL, Perez-Pudlewski D. Lateral periodontal cyst: multifactorial analysis of a previously unreported series. *Oral Surg Oral Med Oral Pathol* 1996;81:210-6.
- [3] Padayache A, Van Wyk CW. Two cystic lesions with features of both the botryoid odontogenic cyst and the central mucoepidermoid tumor: sialo-odontogenic cyst? *J Oral Pathol* 1987;16:499-504.
- [4] Üçok Ö, Günhan Ö, Üçok C, Dogan N, Baykul T. Botryoid odontogenic cyst: report of a case with extensive epithelial proliferation. *Int J Oral Maxillofac Surg* 2005;34:693-5.
- [5] Albuquerque Junior RLC, Pereira JC, Fakhouri R, Lessa Filho LS. Cisto odontogênico botrióide: relato de um caso. *RBPO* 2005;4(1):12-6.
- [6] Gurol M, Burkes Jr EJ, Jacoway J. Botryoid odontogenic cyst: analysis of 33 cases. *J Periodontol* 1995;66:1069-73.
- [7] Kerezoudis NP, Donta-Bakoyianni C, Siskos G. The lateral periodontal cyst: etiology, clinical significance and diagnosis. *Endod Dent Traumatol* 2000;16:144-50.
- [8] Kaplan I, Anavi Y, Hirshberg A. Glandular odontogenic cyst: a challenge in diagnosis and treatment. *Oral diseases* 2008;14:575-81.
- [9] Méndez P, Junquera L, Gallego L, Baladrón J. Botryoid odontogenic cyst: clinical and pathological analysis in relation to recurrence. *Med Oral Patol Oral Cir Bucal* 2007;12(8):E594-E598.
- [10] Jadu ST, Pharoah MJ, Bradley G, Psutka D. Hybrid botryoid odontogenic cyst—glandular odontogenic cyst of the mandible. *Oral Surg Oral Med Oral Pathol Oral Radiol Endod* 2008;105(4):e52-3.
- [11] Altini M, Shear M. The lateral periodontal cyst: an update. *J Oral Pathol Med* 1992;21(6):245-50.
- [12] Mendes RA, Van der Waal I. An unusual clinicoradiographic presentation of a lateral periodontal cyst—report of two cases. *Med Oral Patol Oral Cir Bucal* 2006;11(2):E185-E187.
- [13] de Sousa SO, Campos AC, Santiago JL, Jaeger RG, de Araujo VC. Botryoid odontogenic cyst: report of a case with clinical and histogenetic considerations. *Br J Oral Maxillofac Surg* 1990;28(4):275-6.
- [14] Ramer M, Valauri D. Multicystic lateral periodontal cyst and botryoid odontogenic cyst: multifactorial analysis of previously unreported series and review of literature. *NYSDJ* 2005;71(4):47-51.
- [15] Chi AC, Neville BW, Klinger BJ. A multilocular radiolucency. *J Am Dent Assoc* 2007;138:1102-3.